



ORIGINAL ARTICLE

Tissue expression, serum and salivary levels of vascular endothelial growth factor in patients with HNSCC[☆]



Azadeh Andisheh-Tadbir^a, Marzieh Hamzavi^a, Gita Rezvani^a,
Mohammad Javad Ashraf^b, Mohammad Javad Fattahi^c, Bijan Khademi^{c,d},
Fereshteh Kamali^{a,*}

^a Department of Oral and Maxillofacial Pathology, School of Dentistry, Shiraz University of Medical Sciences, Shiraz, Iran

^b Department of Pathology, School of Medicine, Shiraz University of Medical Sciences, Shiraz, Iran

^c Shiraz Institute for Cancer Research, Shiraz University of Medical Sciences, Shiraz, Iran

^d Department of Otolaryngology, Khalili Hospital, Shiraz University of Medical Sciences, Shiraz, Iran

Received 21 July 2013; accepted 9 March 2014

Available online 13 August 2014

KEYWORDS

Vascular endothelial growth factors;
Squamous cell carcinoma;
Serum;
Saliva

Abstract

Introduction: Vascular endothelial growth factor is thought to be an important angiogenic factor involved in tumor growth, progression, and metastasis.

Objective: The present study evaluated the relation between tissue expression, serum and salivary levels of vascular endothelial growth factor in head and neck squamous cell carcinomas, and their correlation with clinicopathologic features.

Methods: Samples were collected from 30 patients with head and neck squamous cell carcinomas and 24 healthy volunteers. Immunohistochemical analysis was used for tissue expression and enzyme-linked immunosorbent assay was employed to measure serum and salivary levels.

Results: No vascular endothelial growth factor staining was observed in normal tissues, whereas vascular endothelial growth factor expression was seen in 6 patients (20%). Mean serum level of VEGF was 83.7 ± 104.47 in patients and 50.04 ± 32.94 in controls. Mean salivary level of vascular endothelial growth factor was 174.41 ± 115.07 in patients and 149.58 ± 101.88 in controls. No significant difference was found by Mann–Whitney test between controls and patients ($p = 0.411$, $p = 0.944$, respectively). No correlation was found between vascular endothelial growth factor tissue expression and its serum and salivary level.

[☆] Please cite this article as: Andisheh-Tadbir A, Hamzavi M, Rezvani G, Ashraf MJ, Fattahi MJ, Khademi B, et al. Tissue expression, serum and salivary levels of vascular endothelial growth factor in patients with HNSCC. Braz J Otorhinolaryngol. 2014;80:503–7.

* Corresponding author.

E-mail: feresh.876@yahoo.com (F. Kamali).

PALAVRAS-CHAVE

Fatores de crescimento endotelial vascular; Carcinoma de células escamosas; Soro; Saliva

Conclusion: Overexpression of vascular endothelial growth factor was found in head and neck squamous cell carcinoma patients, suggesting its role in the pathogenesis of head and neck squamous cell carcinoma, but no relation was found between tissue expression, serum levels, and salivary levels of this marker.

© 2014 Associação Brasileira de Otorrinolaringologia e Cirurgia Cérvico-Facial. Published by Elsevier Editora Ltda. All rights reserved.

Expressão tecidual, soro e níveis salivares de VEGF em pacientes com carcinoma de células escamosas de cabeça e pescoço

Resumo

Introdução: Acredita-se que o fator de crescimento vascular endotelial (FCEV) seja um importante fator angiogênico envolvido no crescimento, na progressão e na metástase tumoral.

Objetivo: O presente estudo avalia a relação entre a expressão tecidual e os níveis séricos e salivares do FCEV em carcinomas de células escamosas da cabeça e pescoço (CCECPs) e sua correlação com aspectos clinicopatológicos.

Método: Foram coletadas amostras de 30 pacientes com CCECP e de 24 voluntários saudáveis. Utilizamos análise imuno-histoquímica para a expressão tecidual e ELISA para determinação dos níveis séricos e salivares.

Resultados: Não foi observada coloração para FCEV nos tecidos normais, enquanto que foi observada expressão de FCEV em seis pacientes (20%). O nível sérico médio de FCEV foi $83,7 \pm 104,47$ em pacientes e $50,04 \pm 32,94$ em controles. O nível salivar médio de FCEV foi de $174,41 \pm 115,07$ em pacientes e $149,58 \pm 101,88$ em controles. Não foi observada diferença significativa pelo teste de Mann-Whitney entre controles e pacientes (respectivamente, $p=0,411$, $p=0,944$). Não foi observada relação entre a expressão tecidual de FCEV e seus níveis séricos e salivares.

Conclusão: A expressão elevada de FCEV foi observada em pacientes com CCECP, e isso sugere seu papel na patogênese de CCECP, mas não foi observada relação entre a expressão tecidual e os níveis séricos e salivares desse marcador.

© 2014 Associação Brasileira de Otorrinolaringologia e Cirurgia Cérvico-Facial. Publicado por Elsevier Editora Ltda. Todos os direitos reservados.

Introduction

Angiogenesis is an important phenomenon in the development of tumors and metastasis, which is created by secretion of several growth factors by means of tumor cells and tumor surroundings. Although tumor development is a multiple phase process, angiogenesis is necessary for tumor growth and metastasis.^{1,2} Vascular endothelial growth factor (VEGF) is known to be a fundamental regulator of angiogenesis that accelerates cellular proliferation, vascular permeability, and endothelial cell migration, as well as functioning as an apoptosis inhibitor.³ VEGF is a heparin binding glycoprotein and its gene is located on chromosome 6.¹ This protein is the most important of VEGF family and has a role in vascular permeability.⁴ Inhibition of VEGF activity leads to diminished growth and decreased tumor progression, which suggests that it has an important role in initiation of tumor angiogenesis.⁵ Furthermore, it has been determined that hypoxia can increase VEGF expression, and that VEGF overexpression leads to angiogenesis in the hypoxic area of tumors.⁶

VEGF is expressed in several malignant tumors, which indicates its important role in the process of angiogenesis.

Over-expression of VEGF has been found in solid tumors, such as those of the colon, kidney, breast, brain, pancreas, bladder, ovary, stomach, lung, and oral cavity.⁷

Regarding the role of VEGF in the angiogenic process, the aim of this study was to investigate the expression, serum and salivary levels of this marker in patients with head and neck squamous cell carcinoma (HNSCC).

Methods

In this cross-sectional study, 30 patients with HNSCC (21 males and nine females), who were referred to Khalili and Chamran Hospitals of Shiraz University of Medical Sciences, were examined. The control group consisted of 24 healthy individuals (16 male and eight females) who were matched with the patients group in terms of age and sex.

Those suffering from any systematic disease, active infection, autoimmune disease, inflammatory disease, or periodontal problems were excluded from the study. As for the patients group, those who had a history of radiotherapy, chemotherapy, or other cancers were excluded.

H&E slides were examined in patients with HNSCC and those with sufficient tissue were selected for immunohistochemical (IHC) studies. Clinical information of patients, including age, sex, tumor location, tumor size, metastasis stage and grade, as well as tobacco consumption habits, were collected from the patients' records. The Ethics Committee of Shiraz University of Medical Sciences approved the study and all patients signed an informed consent.

To prepare serum, 5 cm³ of blood was drawn from the patients' veins, who were NPO for 12 h, in the morning before surgery. The blood samples were immediately centrifuged at 3000 rpm for 10 min. The serum was then separated and stored at -80 °C until analysis.⁸

In order to collect saliva, unstimulated whole saliva samples were collected from the patients, who were NPO for 12 h, in the morning before surgery.

The patients were asked to refrain from eating, drinking, and smoking for 30 min. Then, the patients' lips were cleaned and each patient rinsed his/her mouth with water. Approximately 5–10 mL saliva was collected from every patient. After centrifugation of the samples (2600 × g, 15 min, 40 °C), they were then stored at -80 °C until use.⁹

Serum and saliva analysis

Concentration of VEGF was measured using enzyme-linked immunosorbent assay (ELISA) (Bender Med. Systems GmbH – Germany), according to the manufacturer's instructions.

Immunohistochemical staining

IHC staining was performed by using the EnVision® Labeled Peroxidase System (DAKO, Carpinteria, CA, USA). All samples were fixed in 10% buffered formalin and were embedded in paraffin. Sections with 4 μm thickness were prepared, deparaffinized in xylene, rehydrated in graded alcohol, and washed with distilled water. Antigen retrieval was performed by using DAKO cytomation target retrieval solution with pH=9, for 20 min. Internal peroxidase activity was inhibited by 3% H₂O₂. Tissue sections were then incubated for 30 min with the anti-VEGF antibody (mouse anti-human; DAKO Corporation – Denmark) at a 1:25 dilution. Normal samples were stained with the same amount of antibody used for staining tumor tissues. Omission of the primary antibody was employed as negative control, while pyogenic granuloma was used as positive control. Brown cytoplasmic staining for VEGF was considered as positive.

The stained slides were initially scanned at low magnification. For the slides showing heterogeneous staining, the regions with higher staining were studied. Five fields were randomly chosen, 500 cells were counted, and the percentage of staining was calculated. The extent of staining was classified as: 0 if 0–10% of tumor cells were stained, 1 if 11–25% of tumor cells were stained, 2 if 26–50% were stained, and 3 if more than 50% were stained.

Statistical analysis

After entering the data into the statistical software (SPSS 18.0), the normality of the data was first examined using the

Table 1 Clinicopathological profile of 30 head and neck squamous cell carcinoma patients.

Clinicopathological profile	n (%)
<i>Gender</i>	
Male	21 (70%)
Female	9 (30%)
<i>Tumor size</i>	
T1	12 (40%)
T2	18 (60%)
<i>Regional lymph node involvement</i>	
N0	27 (90%)
N1	3 (10%)
<i>Distant metastasis</i>	
M0	30 (100%)
<i>TNM stage</i>	
I	11 (36.7%)
II	16 (53.3%)
III	3 (10%)
<i>Histological grade</i>	
I (well-diff.)	8 (26.7%)
II (moderately-diff.)	18 (60%)
III (poorly-diff.)	4 (13.3%)
<i>Location</i>	
Larynx	22 (73.3%)
Oral cavity	8 (26.7%)

Kolmogorov–Smirnov test. As the variables under study were not normally distributed, Mann–Whitney, Kruskal–Wallis, and chi-squared tests were used in order to compare the two groups. Differences were considered significant at $p < 0.05$.

Results

Description of variables

The present study was performed on 30 patients with HNSCC (21 males and nine females) with a mean age of 56.76 ± 12.46 years. Clinicopathologic characteristics of the patients are shown in Table 1.

No VEGF staining was observed in normal tissues, whereas VEGF expression was observed in six patients (20%); four had scores of 1 and two had scores of 2. VEGF expression was not seen around keratin pearls (Figs. 1 and 2).

The results indicated that the tissue expression of VEGF between cases and controls showed a significant difference ($p: 0.023$), such that it was higher in the HNSCC group than the controls. There was no apparent correlation in VEGF expression with the clinicopathological features, such as stage, tumor size, nodal status, and histological grade.

The mean serum level of VEGF was 83.7 ± 104.47 in patients and 50.04 ± 32.94 in controls. The mean salivary level of VEGF was 174.41 ± 115.07 in patients and 149.58 ± 101.88 in controls. No significant difference was found by Mann–Whitney test between controls and patients ($p = 0.411$, $p = 0.944$, respectively).

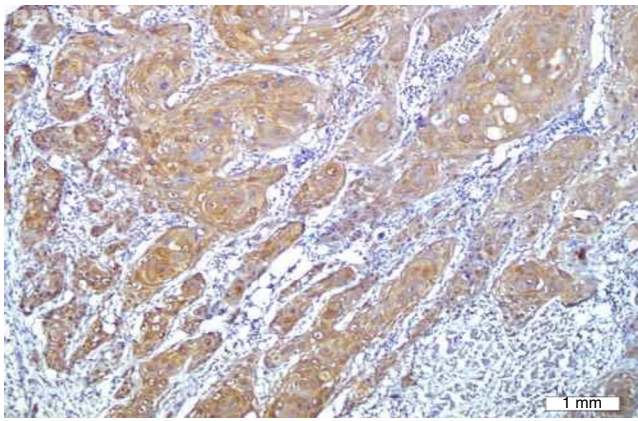


Figure 1 Cytoplasmic staining of vascular endothelial growth factor in squamous cell carcinoma (200 \times).

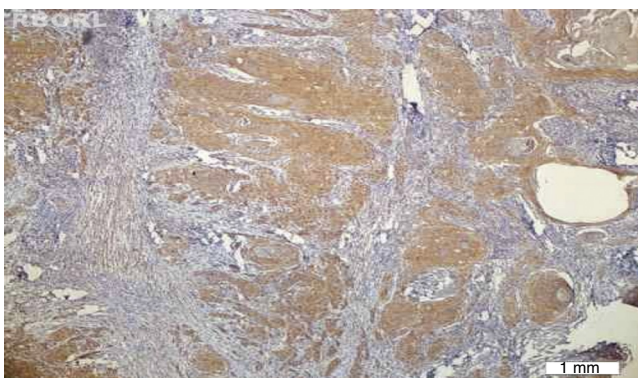


Figure 2 Vascular endothelial growth factor expression was negative around keratin pearls (100 \times).

No significant correlation was found by Mann–Whitney test between VEGF tissue expression and its serum and salivary levels ($p=0.517$, $p=0.716$, respectively). The relationships between serum and salivary levels of VEGF and other variables such as age, sex, M, N, T, grade, and stage were separately examined, and no significant relationship was found between serum or salivary levels and the mentioned variables.

Discussion

VEGF has been recognized as an effective factor for induction of angiogenesis and is a potent mitogen for endothelial cells.¹⁰ In the present study, the expression of VEGF was seen in 20% of tumor samples, while none of the tissues of control group were positive, and there was significant difference regarding the expression of VEGF. The increased expression of VEGF in the present study is in accordance with the other studies which were performed on oral SCC and HNSCC.^{10–12} However, the rate of expression of VEGF in the present study was low compared to other studies, which may be due to few patients in this study when compared to other studies. The relationship between the expression of VEGF and the parameters such as tumor differentiation, lymph nodes metastasis, and depth of invasion has been investigated in different studies.¹³ The results regarding the investigation of relationship between the expression of VEGF and

the above-mentioned factors in HNSCC were different. Tse et al.¹⁴ found that there was no relationship between VEGF expression and histopathologic grade and location of tumor, but that increased VEGF expression resulted in decreased survival rate. Kyzas et al.¹⁵ found no relationship between the expression of VEGF, grade, and stage of head and neck carcinoma. They declared that the expression of VEGF in benign lesions was greater than in carcinomas and dysplasia; in addition, they found that the expression of VEGF has a key role in adjusting the normal physiologic condition of the mucosa. In this study, there was no relationship between the VEGF expression and clinicopathologic factors. Controversies and different findings may be due to few samples, different grading of VEGF expression, variety of tumors with regard to the primary location, and the different stages of the patients between the present study and other studies. In the present study, most of the patients were in stages I and II. In this study, serum level of VEGF in patient group was slightly higher than control group; nonetheless, this difference was not significant ($p>0.05$). In contrast in the other studies, increased serum level of VEGF was observed in the patient group.^{7,16} A strong relation was seen between VEGF serum level and HNSCC in patients with advanced stages.¹⁷ In fact, in the other studies, the majority of patients were in advanced stages, different from the present study in which the majority of patients were in stages I and II without distant metastasis. Thus, it is more accurate to compare this study with similar studies such as that of Wu and Meyer.^{18,19} In their study, most of the patients were in stages I and II, and most of the lesions were located in the larynx. No significant elevation in VEGF level was observed in their study. In the current study, there was no relation between the VEGF serum level and clinicopathologic factors, while in the study conducted by Shang et al.,⁸ elevated level of VEGF was present in patients with lymph node metastasis. However, in a study by Meyer et al.,¹⁸ which is quite similar to the present study regarding the selection of samples, the stage, and location (samples of larynx were investigated), there was no relationship between the circulating VEGF level and clinicopathologic factors. Saliva is one of the body fluids which is easily accessible and its preparation is noninvasive. It is known as the “mirror of body”, and its application was investigated in the diagnosis of systemic diseases and tumor markers.²⁰ Saliva is identified as a source of VEGF. It has been demonstrated that physiologic and pathologic angiogenesis in oral mucosa and salivary tissues is regulated by salivary VEGF.²¹ The presence of VEGF in the saliva of normal patients suggests the important role of VEGF in maintaining the homeostasis of mucous membranes.²² In the present study, the VEGF salivary level in patients with HNSCC was higher than that of the control group, but there was no statistically significant difference. In a study by Upile et al.,²³ the salivary level of VEGF165 was examined, and the results demonstrated that the VEGF salivary and serum levels in patients were significantly higher than those of the control group. In their study, the level of VEGF165 was investigated by immunoassay, while in the current study, the salivary levels of various isoforms of VEGF was investigated by ELISA; this difference may result from the diversity in the measurement of isoforms. In the present study, there was no relationship between the salivary level of VEGF and clinicopathologic factors. In the study by Upile et al.,²³ the

relationship between the VEGF salivary level and clinicopathologic factors was not investigated. In reviewing the article, the present authors did not find any studies which investigated the relationship between the salivary level of VEGF and clinicopathologic factors.

Conclusion

In the present study, overexpression of VEGF was found in HNSCC patients, which suggests its role in the pathogenesis of HNSCC, but no relation was found between the tissue expression, serum level, and salivary level of this marker.

Conflicts of interest

The authors declare no conflicts of interest.

Acknowledgements

The authors would like to thank the Vice-Chancellery for Research of Shiraz University of Medical Sciences for providing financial support for this study (Grant#90-5551). This manuscript is relevant to the post graduate thesis of Dr. Marzieh Hamzavi.

References

- Sullu Y, Gun S, Atmaca S, Karagoz F, Kandemir B. Poor prognostic clinicopathologic features correlate with VEGF expression but not with PTEN expression in squamous cell carcinoma of the larynx. *Diagn Pathol.* 2010;35:35–40.
- Smith B, Smith GL, Carter D, Sasaki CT, Haffty B. Prognostic significance of vascular endothelial growth factor protein levels in oral and oropharyngeal squamous cell carcinoma. *J Clin Oncol.* 2000;18:2046–52.
- Khaled M, Le A, Duong H, Wu Y, Zhang Q, Messadi DV. Correlation between VEGF and HIF-1 α expression in human oral squamous cell carcinoma. *Exp Mol Pathol.* 2004;76:143–52.
- Michael JC, John D, Taro M, Lena CW. VEGF-receptor signal transduction. *Biochem Sci.* 2003;28:488–94.
- Kim KJ, Li B, Winer J, Armanini M, Gillett N, Phillips HS, et al. Inhibition of vascular endothelial growth factor-induced angiogenesis suppresses tumour growth in vivo. *Nat Lond J.* 1993;362:841–4.
- Shweiki D, Itin A, Soffer D, Keshet E. Vascular endothelial growth factor induced by hypoxia may mediate hypoxia-initiated angiogenesis. *Nat Lond J.* 1992;359:843–5.
- Liu CJ, Chang KW, Lin SC, Cheng HW. Presurgical serum levels of matrix metalloproteinase-9 and vascular endothelial growth factor in oral squamous cell carcinoma. *Oral Oncol.* 2009;45:920–5.
- Shang ZJ, Li JR, Li ZB. Upregulation of serum and tissue vascular endothelial growth factor correlates with angiogenesis and prognosis of oral squamous cell carcinoma. *J Oral Maxillofac Surg.* 2007;65:17–21.
- Brooks MN, Wang J, Li Y, Zhang R, Elashoff D, Wong DT. Salivary protein factors are elevated in breast cancer patients. *Mol Med Rep.* 2008;1:375–8.
- Connolly DT, Heuvelman DM, Nelson R. Tumor vascular permeability factor stimulates endothelial cell growth and angiogenesis. *J Clin Invest.* 1989;84:1470–89.
- Gazzar RE, Macluskey M, Williams H, Ogdan GR. Vascularity and expression of vascular endothelial growth factor in oral squamous cell carcinoma, resection margins, and nodal metastases. *Br J Oral Maxillofac Surg.* 2006;44:193–7.
- Shang ZJ, Li JR, Li ZB. Circulating levels of vascular endothelial growth factor in patients with oral squamous cell carcinoma. *Int J Oral Maxillofac Surg.* 2002;31:495–8.
- Li C, Shintani S, Terakado N, Klosek SK, Ishikawa T, Nakashiro K. Microvessel density and expression of vascular endothelial growth factor, basic fibroblast growth factor, and platelet-derived endothelial growth factor in oral squamous cell carcinomas. *Int J Oral Maxillofac Surg.* 2005;34:559–65.
- Tse GM, Chan WH, Yu KH, King AD, Wong KT, Chen GG, et al. Strong immunohistochemical expression of vascular endothelial growth factor predicts overall survival in head and neck squamous cell carcinoma. *Surg Oncol.* 2007;14:3558–65.
- Kyzas PA, Stefanou D, Batistatou A, Agnant NJ. Prognostic significance of VEGF immunohistochemical expression and tumor angiogenesis in head and neck squamous cell carcinoma. *J Cancer Res Clin Oncol.* 2005;131:624–30.
- Friedrich RE, Klapdor R, Hagel C, Bartel-Friedrich S. VEGF in sera of oral and oropharyngeal squamous cell carcinoma patients. *Anticancer Res.* 2010;30:1765–6.
- Cheng SJ, Lee JJ, Kok SH, Chou CH, Chang HH, Yang H. Expression of vascular endothelial growth factor is significantly associated with progression and prognosis of oral squamous cell carcinomas in Taiwan. *J Formos Med Assoc.* 2011;110:50–7.
- Meyer F, Samson E, Pierre D, Duchesne T, Liu G, Bairati I. Serum prognostic markers in head and neck cancer. *Clin Cancer Res.* 2010;16:1008–15.
- Ryuto M, Ono M, Izumi H, Yoshida S, Weich HA, Kohno K, et al. Induction of vascular endothelial growth factor by tumor necrosis factor alpha in human glioma cells. *J Biol Chem.* 1996;271:28220–8.
- Teles RP, Likhari V, Socransky SS, Haffajee AD. Salivary cytokine levels in chronic periodontitis and in periodontally healthy subjects. *J Periodont Res.* 2009;44:411–7.
- Taichman NS, Cruchley AT, Fletcher LM, Hagi-Pavli EP, Paleolog EM, Abrams WR, et al. Vascular endothelial growth factor in normal human salivary glands and saliva: a possible role in the maintenance of mucosal homeostasis. *Lab Invest J Tech Method Pathol.* 1998;78:869–75.
- Wu X, Zhao H, Do KA, Johnson MM, Dong Q, Hong WK, et al. Serum levels of insulin growth factor (IGF-I) and IGF-binding protein predict risk of second primary tumors in patients with head and neck cancer. *Clin Cancer Res.* 2004;10:3988–95.
- Upile T, Jerjes W, Kafas P, Harini S, Singh SU, Guyer M, et al. Salivary VEGF: a non-invasive angiogenic and lymphangiogenic proxy in head and neck cancer prognostication. *Int Arch Med.* 2009;2:1–4.