



CASE REPORT

Extramedullary relapse of acute myeloid leukemia mimicking a necrotizing external otitis: could mononuclear leukocyte scintigraphy be the best diagnostic method?☆



Recidiva extramedular de leucemia mieloide aguda mimetizando otite externa necrotizante: a cintigrafia com leucócitos mononucleares pode ser o melhor método diagnóstico?

**Roberta Laurindo^a, Sergio Souza^{b,*}, Jaqueline Moura^a, Shiro Tomita^a,
Lea Barbosa da Fonseca^b, Bianca Gutfilen^b**

^a Service of Otolaryngology, Department of Clinical Medical, Hospital Universitário Clementino Fraga Filho, Universidade Federal do Rio de Janeiro (UFRJ), Rio de Janeiro, RJ, Brazil

^b Department of Radiology, Laboratório de Marcação de Células e Moléculas, Universidade Federal do Rio de Janeiro (UFRJ), Rio de Janeiro, RJ, Brazil

Received 26 January 2015; accepted 23 April 2015
Available online 7 September 2015

Introduction

Necrotizing external otitis (NEO) is an invasive infectious disease involving the cartilaginous and/or bony external auditory canal (EAC) that particularly affects immunocompromised patients.¹ Patients usually present with unrelenting otalgia that is disproportionate to the clinical signs and purulent otorrhea. The diagnosis of NEO is based on a combination of clinical, laboratory, and imaging findings.² Current tools used to diagnose NEO include

computed tomography (CT), magnetic resonance imaging (MRI), and scintigraphy. The combination of radiological and radionuclide exams is crucial in both, the initial diagnosis and the follow-up of treatment response.

Case report

A 19-year-old man diagnosed with acute myeloid leukemia (AML) in remission presented with severe otalgia, aural fullness, right facial palsy (scoring V on the House-Brackmann scale). Otoscopic findings included, edema of the posterior wall of the external ear canal and otorrhea. Diagnosis of NEO was considered, and the patient was treated empirically with imipenem for 12 days. The patient had a poor response to imipenem, leading the medical team to replace it for cefepime. Even after the change of the treatment regimen the patient's symptoms did not show any improvement.

☆ Please cite this article as: Laurindo R, Souza S, Moura J, Tomita S, da Fonseca LB, Gutfilen B. Extramedullary relapse of acute myeloid leukemia mimicking a necrotizing external otitis: could mononuclear leukocyte scintigraphy be the best diagnostic method? Braz J Otorhinolaryngol. 2016;82:487–90.

* Corresponding author.

E-mail: sergioalsouza@gmail.com (S. Souza).

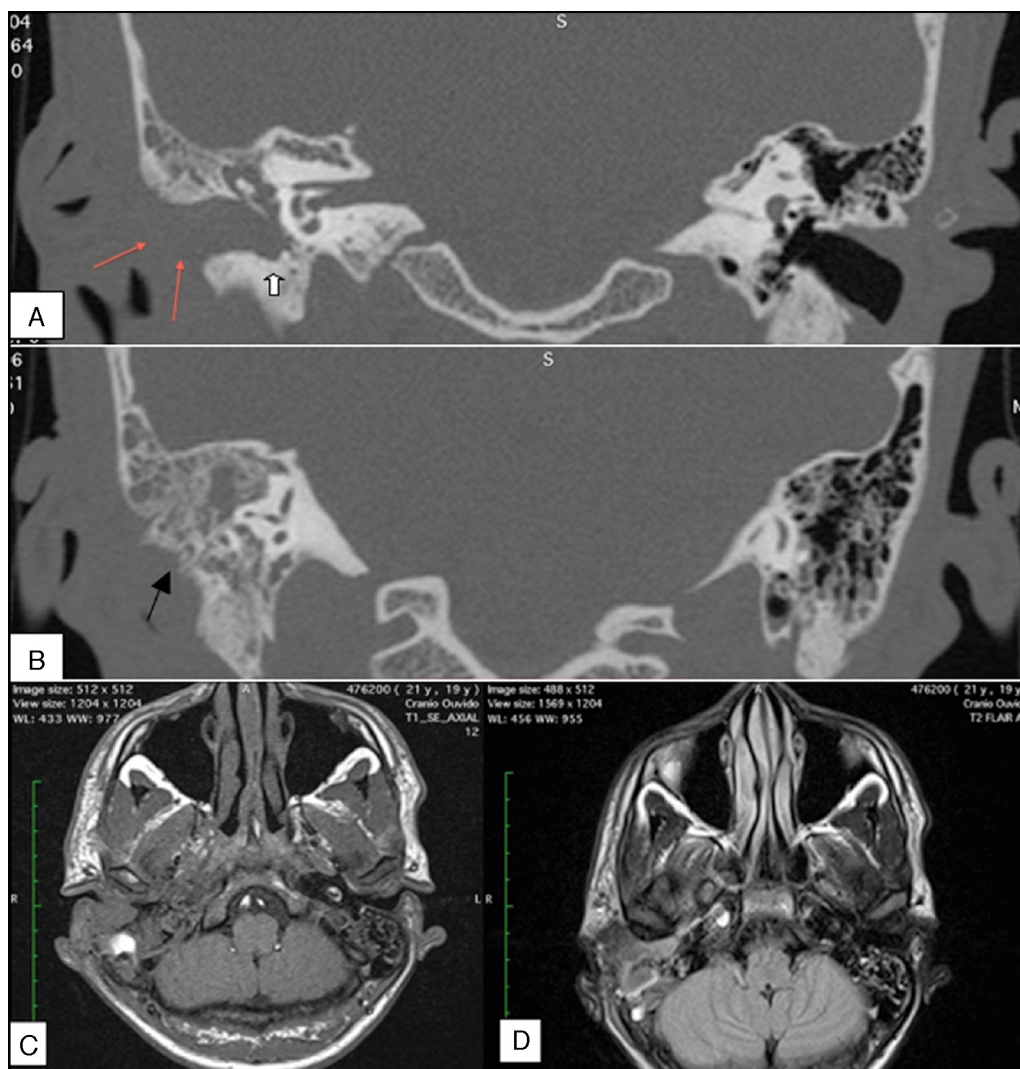


Figure 1 High-resolution coronal computed tomography images of the mastoids (A and B). (A) Erosion of the posterior wall of the external auditory canal (EAC; white arrow) and thickening and enhancement of the soft tissue in the region of the EAC (red arrow). (B) Erosion of the mastoid cortex (black arrow) and destruction of the bony septae. Magnetic resonance imaging of the mastoids (C and D). (C) Axial, T1-weighted image demonstrating infiltration of the soft tissues around the EAC, subcutaneous tissue, and parotid gland. (D) Axial, T2-Flair image showing the tympanic and mastoid cavity, with tissue contrast uptake spreading anteroinferiorly.

Complementary exams revealed high reactive C-protein levels and opacification of mastoid cells and middle ear in CT images, which was associated with erosion of the posterior wall of the EAC (Fig. 1A and B). T2-weighted MRI revealed gadolinium enhancement inside the tympanic cavity and around the carotid canal, extending to the ear pavilion and adjacent soft tissues (Fig. 1C and D). The findings of ^{99m}Tc -MDP bone scintigraphy were consistent with an inflammatory/infectious process occurring in the temporal bone. However, ^{99m}Tc -mononuclear leukocyte scintigraphy did not show any evidence of an inflammatory process.

Given these results and the fact that symptoms were present after 6 weeks of antibiotic therapy, the medical team considered the hypothesis that the patient had a neoplastic disease (Fig. 2). Consequently, the patient underwent a tympanomastoidectomy. Myeloid sarcoma (MS), a type of extramedullary recurrence of AML, was confirmed

by histopathological study. There were no signs of disease in the bone marrow. We initiated a chemotherapy protocol and observed rapid improvement in terms of pain and by otoscopy. The facial palsy regressed to scoring III on the House-Brackmann scale after the treatment. Heterologous transplantation was recommended, and the patient completely recovered.

Discussion

MS is a rare condition characterized by the occurrence of one or more tumors composed of immature myeloid cells in an extramedullary site. This disease rarely affects the temporal bone, and it is most commonly found in bones, soft tissue, skin, and the central nervous system.³ Symptoms of MS of the temporal bone include hearing loss, vertigo, facial

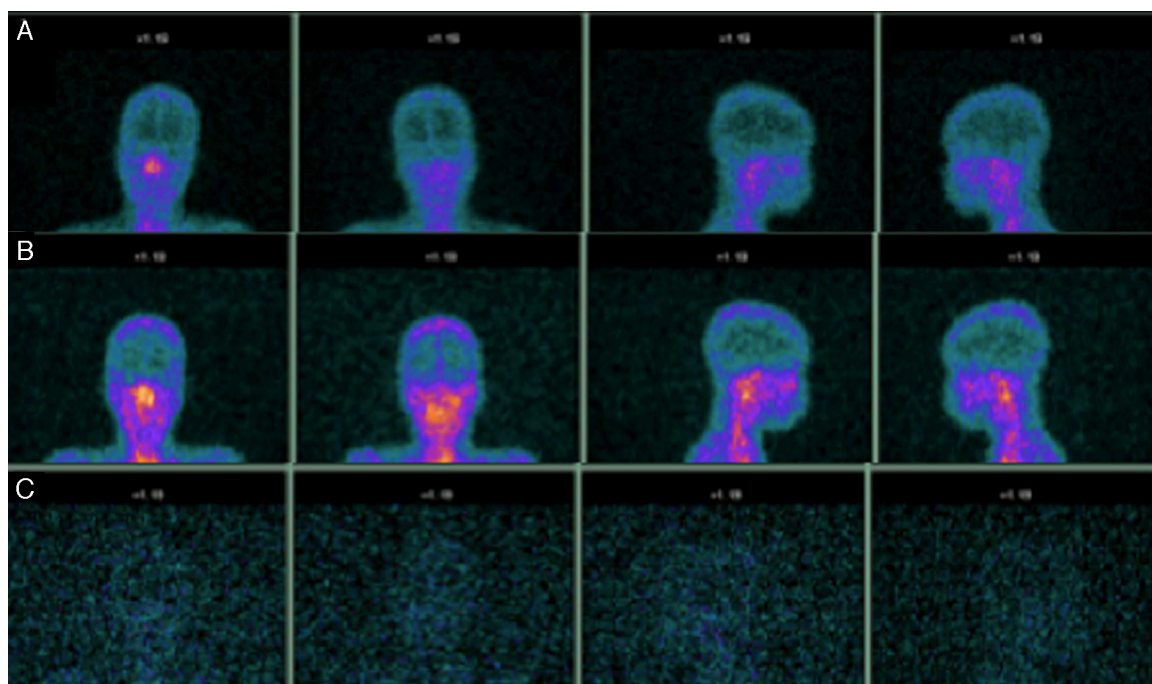


Figure 2 ^{99m}Tc -mononuclear leukocyte scintigraphy (A–C). Planar scintigraphs from one, three, and 24 h after labeled mononuclear leukocyte administration indicate no uptake along the mastoid topography over time.

palsy, tinnitus, ear fullness, ear pain, and retrauricular and external auditory canal swelling that can mimic otomastoiditis or NEO. Imaging findings in the early stages of NEO are frequently subtle, and even in advanced cases, the imaging findings may not be recognized as NEO unless the diagnosis is already under consideration.

Nuclear imaging plays a major role in the diagnosis and follow-up of patients who have NEO. In fact, bone scans using ^{99m}Tc -MDP provide better information about inflammation because they highlight areas with osteoblastic activity. A bone scan can show positive results before apparent radiological changes occur and may be useful in early detection of the disease. However, ^{99m}Tc -MDP is not specific for infection, as it can also be positive in malignant disease and does not detect soft tissue spread without bone involvement.⁴ Bone scans also remain positive after the disease is resolved and are not useful for monitoring response to treatment. Gallium-67 scintigraphy has been shown to be 70% sensitive and 93% specific to diagnose osteomyelitis; thus, it is the investigative technique of choice for monitoring response to treatment. CT is highly effective at defining the extent of bony destruction in the ear canal wall or the base of skull by delineating normal fat planes and bone cortices, and the importance of CT for diagnosing NEO is well-established. MRI is considered more sensitive than CT for delineating soft tissue planes. Most skull base abnormalities exhibit a low signal on T1-weighted images and a high signal on T2-weighted images.⁵

^{99m}Tc -mononuclear leukocyte scintigraphy is used to diagnosis infection, osteomyelitis, graft rejection, and fever of unknown origin. It is still considered the gold standard for chronic posttraumatic or postoperative osteomyelitis.^{6,7} To the best of the authors' knowledge, this is the first time

that a patient with suspected NEO has undergone ^{99m}Tc -mononuclear leukocyte scintigraphy. In this case, the bone scintigraphy was positive, CT demonstrated erosion of the bone in the ear canal wall, and MRI was compatible with an inflammatory response. The only finding that did not corroborate an inflammatory/infectious etiology was the ^{99m}Tc -mononuclear leukocyte scintigraphy, which was more compatible with a neoplastic etiology.

Conclusion

NEO has a variety of clinical presentations and, consequently, a broad range of radiological appearances. In the case reported here, the clinical findings and most of the radiological examinations led this group to diagnose the patient with NEO and to initiate treatment. The ^{99m}Tc -mononuclear leukocyte scintigraphy was the only radiological examination that more closely aligned with the eventual histopathological findings. Additional studies are underway to determine if leukocyte scintigraphy could be a better option for diagnosing NEO than other methods more commonly applied in clinical practice.

Conflicts of interest

The authors declare no conflicts of interest.

References

1. Chandler JR. Malignant external otitis. *Laryngoscope*. 1968;78:125794.

2. Mani N, Sudhoff H, Rajapogal S, Moffat D, Axon PR. Cranial nerve involvement in malignant external otitis: implications for clinical outcome. *Laryngoscope*. 2007;117:907–10.
3. Murakami M, Uno T, Nakaguchi H, Yamada SM, Hoya K, Yamazaki K, et al. Isolated recurrence of intracranial and temporal bone myeloid sarcoma – case report. *Neurol Med (Tokyo)*. 2011;51:850–4.
4. Chen CN, Chen YS, Yeh TH, Hsu CJ, Tseng FY. Outcomes of malignant otitis: survival vs mortality. *Acta Otolaryngol*. 2010;130:89–94.
5. Patmore H, Jebreel A, Uppal S, Raine CH, McWhinney P. Skull base infection presenting with multiple lowe cranial nerve palsies. *Am J Otolaryngol*. 2010;31:376–80.
6. Gutfilen B, Lopes de Souza SA, Martins FPP, Cardoso LR, Pinheiro Pessoa MCP, Fonseca LMB. Use of ^{99m}Tc-mono-nuclear leukocyte scintigraphy in nosocomial fever. *Acta Radiol*. 2006;47:699–704.
7. Horger M, Eschmann SM, Pfannenbergr C, Storek D, Dammann F, Vonthein R, et al. The value of SPET/CT in chronic osteomyelitis. *Eur J Nucl Med Mol Imaging*. 2003;30:1667–73.