



ORIGINAL ARTICLE

## Transeptal suturing – a cost-efficient alternative for nasal packing in septal surgery<sup>☆</sup>



Daniel Pérez Plasencia<sup>a</sup>, Juan Carlos Falcón<sup>a</sup>, Silvia Borkoski Barreiro<sup>a,\*</sup>,  
María Sacramento Bocanegra-Pérez<sup>b</sup>, Mario Vicente Barrero<sup>b</sup>, Ángel Ramos Macías<sup>a</sup>

<sup>a</sup> Head Neck Surg Department, Complejo Hospitalario Universitario Insular-Materno Infantil, Gran Canaria, Spain

<sup>b</sup> Stomatology Department, Complejo Hospitalario Universitario Insular-Materno Infantil, Gran Canaria, Spain

Received 7 February 2015; accepted 12 May 2015

Available online 6 November 2015

### KEYWORDS

Septal surgery;  
Nasal packing;  
Transeptal suture;  
Efficiency

### Abstract

*Introduction:* Nasal packing is routinely used in septal surgery to prevent postoperative bleeding.

*Objective:* To demonstrate the possibility of transeptal suture as a safe and effective way to avoid nasal packing and to improve efficiency.

*Methods:* This is a prospective, descriptive, inferential cost study comprising 92 patients. Two randomized groups of patients were analyzed, one with nasal packing and the other with transeptal suture.

*Results:* In the group of transeptal suture no patient experienced postoperative bleeding, and a statistically significant reduction of pain and headache was demonstrated. At the same time, we improved efficiency by saving on material costs.

*Conclusions:* Transeptal suture is an effective and safe alternative to classic nasal packing in septal surgery. Moreover, it improves the efficiency of the intervention by saving costs.

© 2015 Associação Brasileira de Otorrinolaringologia e Cirurgia Cérvico-Facial. Published by Elsevier Editora Ltda. All rights reserved.

### PALAVRAS-CHAVE

Cirurgia septal;  
Tamponamento nasal;  
Sutura transeptal;  
Eficiência

### Sutura transeptal – uma alternativa custo-benefício para tamponamento nasal em cirurgia do septo

### Resumo

*Introdução:* O tamponamento nasal é usado rotineiramente na cirurgia septal para evitar sangramentos no pós-operatório.

<sup>☆</sup> Please cite this article as: Plasencia DP, Falcón JC, Barreiro SB, Bocanegra-Pérez MS, Barrero MV, Macías AR. Transeptal suturing – a cost-efficient alternative for nasal packing in septal surgery. Braz J Otorhinolaryngol. 2016;82:310–3.

\* Corresponding author.

E-mail: [silviaborkoski@hotmail.com](mailto:silviaborkoski@hotmail.com) (S.B. Barreiro).

**Objetivo:** Demonstrar a possibilidade de se realizar uma sutura transeptal como alternativa eficaz e segura ao tamponamento nasal, com melhora na eficiência da intervenção.

**Método:** Este é um estudo prospectivo, descritivo e de custo inferencial, compreendendo 92 pacientes. Dois grupos aleatórios foram estudados: um com tamponamento nasal e o outro com sutura transeptal.

**Resultado:** No grupo de sutura transeptal, nenhum paciente experimentou sangramento no pós-operatório, tendo sido estatisticamente demonstrada uma significativa redução de cefaléia e dor. Ao mesmo tempo, houve melhora na eficiência da intervenção, com economia no custo de material.

**Conclusões:** A sutura transeptal é uma alternativa eficaz e segura ao tamponamento nasal clássico. Além do mais, melhora a eficiência da intervenção, economizando no custo de material. © 2015 Associação Brasileira de Otorrinolaringologia e Cirurgia Cérvico-Facial. Publicado por Elsevier Editora Ltda. Todos os direitos reservados.

## Introduction

Septal surgery is one of the most frequently performed procedures in rhinology. Postoperative nasal packing has been the final step in this procedure since its early descriptions.<sup>1</sup>

The purpose of nasal packing is to avoid bleeding or septal hematoma, reduce edema, optimize the position of the septal flaps, close the dead space, provide internal support and prevent displacement of the cartilage.<sup>2</sup> However, these considerations are not supported in studies with large numbers of cases.<sup>3</sup>

On the other hand, there is no consensus on its duration, ranging from less than 24 h to more than a week. Moreover, performing a nasal packing involves a certain risk, and it has been associated with cardiovascular changes, nasal damage, hypoxemia, apnea, ototubaritis, otitis media and hemotympanum, foreign-body reactions, infections and even toxic shock syndrome (among others). The most common patient complaints are discomfort, pain and nasovagal reflexes at the moment of withdrawal of the packing.

Lemmens wrote that the search for alternatives started with Lee, who describes continuous septal suture as an alternative option to nasal packing.<sup>4</sup>

## Methods

We studied a group of 92 patients who underwent septal surgery between January 2008 and January 2013 (5 years).

The main and compulsory inclusion criterion for the study was patients with respiratory unilateral or bilateral nasal distress that were found with septal dysmorphia. All patients signed an informed consent prior to surgery.

Exclusion criteria were patients with chronic rhinosinusitis with nasal polyposis, patients with HIV infection and immunosuppressed patients, in order to avoid bias in the study.

All procedures were performed under general anesthesia with laryngeal mask. The nose was systematically anesthetized with topical tetracaine (10 mg/mL with adrenaline 1%) instilled with cotton wicks, and local anesthetic (0.5% bupivacaine with epinephrine 1:200,000) was infiltrated in

the septal mucosa subperichondrially on both sides of the septum.

The incision was always hemitransfixional, the mucoperiosteal–mucoperichondrium was elevated bilaterally and the deviated bone and cartilaginous part of the septum were taken off. After correcting the deviated structures, the incision was closed with Vicryl™ 3/0.

The distribution of patients in the two study groups was randomized (by sealed envelope). They were given a nasal packing with polyvinyl alcohol sponge (Merocel™) or 2–3 transfixing suture stitches with Vicryl™ 3/0 using a curved needle with at least one or two vertical stitches and one horizontal stitch, thereby approximating the flap of mucous membrane and avoiding dead spaces (Fig. 1).

All procedures were performed in the afternoon, and patients were hospitalized until the next morning. This period lasted about 16 h on average (range 14–19).

They were subsequently checked three and seven days after surgery. During the first visit, we withdrew the nasal

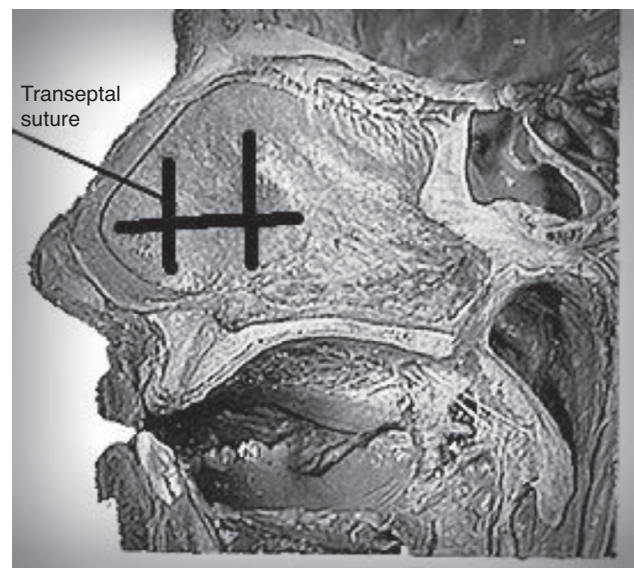


Figure 1 Transeptal nasal suture.

polyvinyl alcohol sponges in the group of patients with nasal packing. All patients were required to rank postoperative pain experienced using a visual scale of pain intensity classified in a range from 1 to 5. This scale is based on the facial affective scale.<sup>5</sup> Then, the patients were checked every month for three months to assess progress in the medium term.

Univariate comparisons of outcome between the two groups were made with  $\chi^2$  analysis, Fisher's exact test, and *t*-tests. We used IBM SPSS Statistics Desktop v. 21.0 Software™.

Surgical procedures were done in two private medical centers without scientific ethic medical committee. Informed consent was signed for every patient.

## Results

Ninety-two septoplasties done from January 2008 to January 2013 were included in this study. The patients were divided in two groups (packing or trans-septal suture) of 46 patients each.

The sex distribution of patients was 53 men and 39 women, and the mean age was 32.12 years with a median of 47 years (range 18–76). There were no significant differences between the two patient groups.

All patients had preoperative nasal symptoms such as respiratory failure (100%). Other associated symptoms were rhinorrhea (52.85%), sneezing (45.71%), hyposmia (35.71%) and self-limited epistaxis (17.14%). In rhinoscopy septal deviation was observed in 100% of cases, and inferior turbinate hypertrophy in 71.42% of cases. There were no significant differences in these preoperative symptoms and signs between the two patient groups studied.

Mean surgery time was 32 min (range 14–50), with no significant statistical differences between groups.

We studied postoperative pain during the first week in both groups. We have obtained significant differences in favor of the group undergoing trans-septal suture. In this group only one patient had severe pain compared to 11 in the nasal packing group ( $p < 0.01$ ) (Fig. 2).

When interrogated regarding the existence of headaches after surgery we observed again significant differences. The group of patients undergoing nasal packing had higher headache incidence ( $p < 0.01$ ) (Fig. 3).

In the group of patients with trans-septal suture, the main complications were septal abscess and septal hematoma. In the group of patients with classic packing none reported such complications. We found no significant differences between the two groups.

In the last visits (3 months), the percentage of patients with nasal respiratory distress was 6.5% in the trans-septal suture group and 23.9% in the group with packing, with no significant differences.

In the trans-septal suture group we observed no significant epistaxis. In the group of nasal packing 4 patients did report epistaxis just after removal (8.69%), but none had to use them again. The difference was significant in this case ( $p < 0.05$ ) (Fig. 4).

One month after surgery 91.31% of patients were satisfied with the outcome of the surgery, with no significant differences between the two surgical procedures.

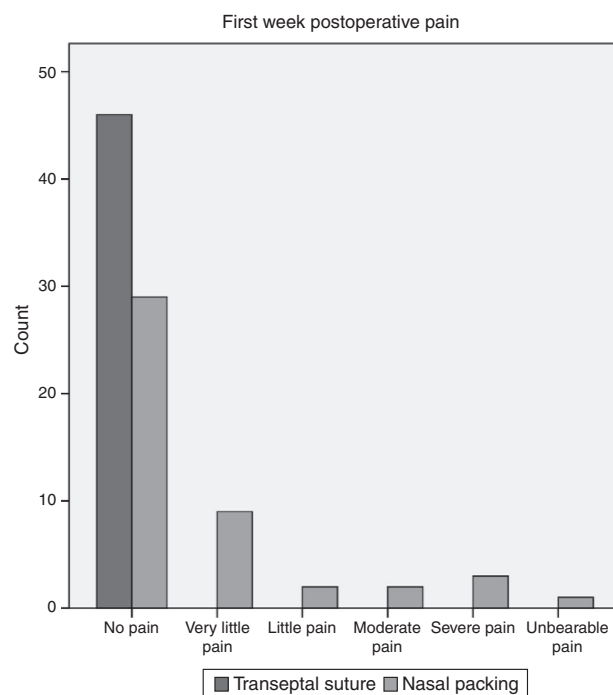


Figure 2 First week postoperative pain.

In the cost study, we emphasize the savings derived from avoiding bilateral nasal packing. The cost of each unit of nasal packing in our center is currently 19.5 euros, excluding taxes. In using this alternative procedure, we have saved 1794 euros excluding taxes, thereby increasing the efficiency of the process, since other costs are similar for both techniques.

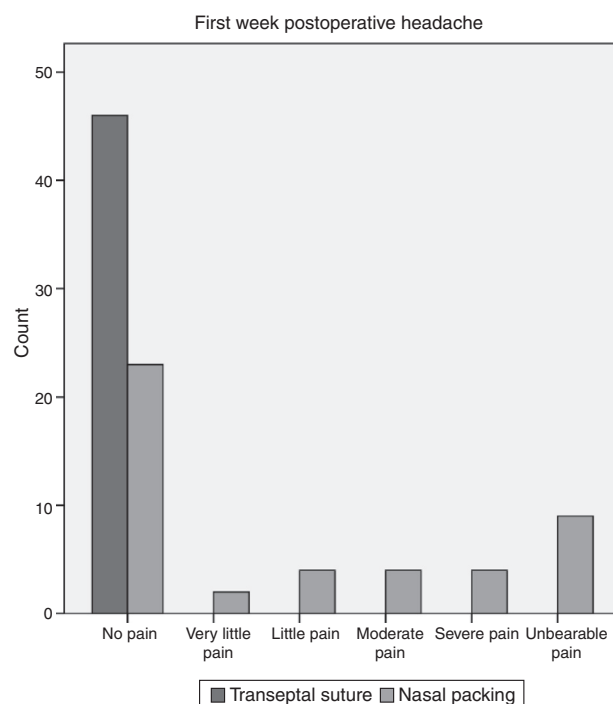


Figure 3 First week postoperative headache.

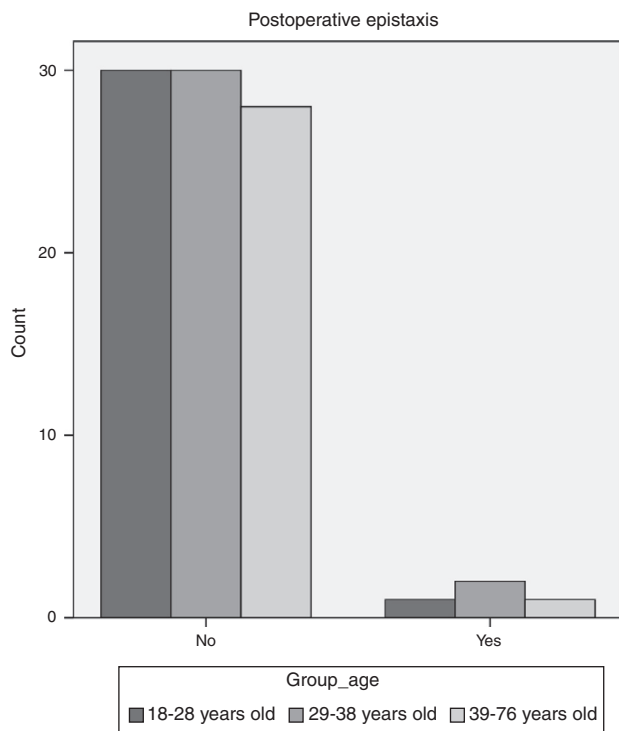


Figure 4 Postoperative epistaxis.

## Discussion

This study aims to verify the usefulness of nasal trans-septal suture to avoid nasal packing and to improve cost efficiency of the surgical procedure.

To this end, we collected data from each patient's medical history. In addition, we collected the results by patients in the first check, where they were asked to choose a value from a visual pain scale rating based on facial affective scale.<sup>5</sup>

The main complaint of patients is the pain and discomfort related to the removal of nasal packing.<sup>6</sup>

The objective of nasal packing is to diminish the likelihood of postoperative bleeding but, as seen in our series, none of the nasal packing patients had 0% postoperative bleeding, and in fact, 4 patients reported significant bleeding after removal of the packing, although none had to use them again. This agrees with the data obtained in the meta-analysis by Certal et al.,<sup>7</sup> which concludes that patients with nasal packing have a reduced risk of postoperative hemorrhage of 1%, which is not significant from a statistical point of view. Nor should one forget that after the withdrawal of classic packing, there exists the possibility of having to do the packing again, as bleeding may occur.<sup>4</sup> Another objective of the packing is to stabilize parts of the septum cartilage and bone. This stabilization can also be achieved with the trans-septal suture structures, which can also remain stable for a much longer time, depending on the material used.<sup>2</sup>

All studies reviewed conclude that patients suffer less pain and discomfort if no nasal packing (1–4, 6–7) is used. The difference is statistically significant and is most evident in the case of headaches, which are reduced by 57% if trans-septal suture is performed.<sup>7</sup> These data are consistent with those obtained in this study.

With regard to septal hematoma, studies that collect this data do not show significant differences between the two techniques.<sup>7</sup> We have seen 2 cases, one of which was a complicated one with septal abscess. Again, no significant differences were found between the two groups. In order to avoid these problems, we recommend making some incisions in septal mucosa as drainage.

To all the advantages listed above, we should add the reduction in costs derived from the use of packing. The trans-septal suture is made with the same material used in the hemitransfixion incision suture and does not involve increasing the cost of consumables, nor does it increase the duration of the procedure.

## Conclusions

Most surgeons still use nasal packing following septal surgery. This work aims only to draw attention to the possibility of avoiding nasal packing, thereby improving postoperative patients and process efficiency.

## Funding

This work has not been funded by any public or private company.

## Conflicts of interest

The authors declare no conflicts of interest.

## References

1. Dubin MR, Pletcher SD. Postoperative packing after septoplasty: is it necessary? *Otolaryngol Clin North Am.* 2009;42:279–85.
2. Reiter D, Alford E, Jabourian Z. Alternatives to packing in septorhinoplasty. *Arch Otolaryngol Head Neck Surg.* 1989;115:1203–5.
3. Joseph T, Marks NJ. Submucous resection as an outpatient procedure. *J Laryngol Otol.* 1991;105:877.
4. Lemmens W, Lemkens P. Septal suturing following nasal septoplasty, a valid alternative for nasal packing? *Acta Otorhinolaryngol Belg.* 2001;55:215–21.
5. Astudillo W, Mendinueta C, Astudillo E, Gabilondo S. Principios básicos para el control del dolor total. *Rev Soc Esp Dolor.* 1999;6:29–40.
6. Yilmazer C, Sener M, Yilmaz I, Erkan AN, Cagici CA, Donmez A, et al. Pre-emptive analgesia for removal of nasal packing: a double-blind placebo controlled study. *Auris Nasus Larynx.* 2007;34:471–5.
7. Certal V, Silva H, Santos T, Correia A, Carvalho C. Trans-septal suturing technique in septoplasty: a systematic review and meta-analysis. *Rhinology.* 2012;50:236–45.