



CASE REPORT

Benign fibrous histiocytoma of the temporal bone: involvement of both mastoids at different times[☆]

Histiocitoma fibroso benigno de osso temporal: comprometimento das mastóides em tempos diferentes

Lídio Granato*, José Donato de Próspero, Wilson Luiz Sanvito,
Lucas Bevilacqua Alves da Costa, Alessandro Murano Ferré Fernandes

Faculdade de Ciências Médicas da Santa Casa de São Paulo (FCMSC-SP), São Paulo, SP, Brazil

Received 8 October 2012; accepted 3 February 2013

Introduction

Benign fibrous histiocytoma is a condition first described by Stout¹ in 1967. It often affects sun-exposed skin, but may be found in other organs, including intraosseous sites.² In these cases, the clinical manifestations are pain and enlargement of the affected bone.

We are reporting the case of a benign mastoid fibrous histiocytoma involving the left mastoid for two years that was pathologically the same as a tumor the patient had experienced 15 years earlier in the right ear.

In the medical literature, this tumor is rarely described involving the mastoid, and we could not find any report with bilateral involvement occurring at different times.

Case presentation

A 56-year-old female patient presented with a one-month history of left retroauricular pain radiating to the ipsilateral head and face. She also had left mastoid tenderness, with normal otoscopic findings and hearing bilaterally. In addition, she reported having an operation to remove a tumor from the opposite ear 15 years earlier that was diagnosed as a benign fibrous histiocytoma.

Computed tomography showed evidence of a right mastoidectomy and a lytic lesion with soft-tissue density material in the left mastoid cavity. Both middle ears were normal.

Magnetic resonance imaging showed high T2 signal seen in the left mastoid cells, with gadolinium-enhanced meningeal thickenings at the cerebellar tentorium and the ipsilateral middle cranial fossa (Fig. 1).

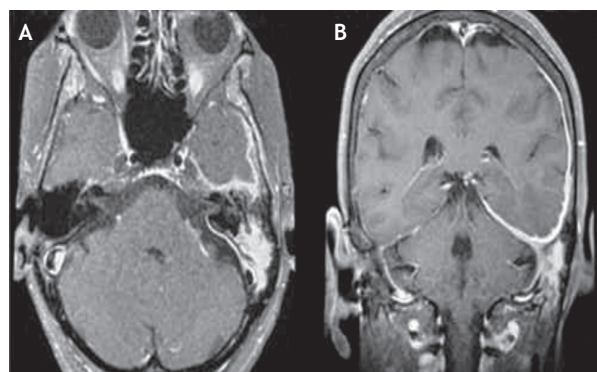


Figure 1 A, Axial view of head magnetic resonance imaging shows the high T2 signal in left mastoid cells. B, Coronal view of head magnetic resonance imaging exhibits ipsilateral cerebellar tentorium and middle fossa leptomeningeal plan enhancement after gadolinium is injected.

[☆]Please cite this article as: Granato L, Próspero JD, Sanvito WL, Costa LBA, Fernandes AMF. Benign fibrous histiocytoma of the temporal bone: involvement of both mastoids at different times. Braz J Otorhinolaryngol. 2014;80:264-5.

* Corresponding author.

E-mail: drlidio@terra.com.br (L. Granato).

The patient underwent left mastoidectomy, with removal of the posterior wall of the ear canal. The lesion was confined to the mastoid cavity and did not involve the tympanic membrane, the middle ear, or the mastoid tegmen. Histological study confirmed the diagnosis of a benign fibrous histiocytoma.

The surgical cavity healed completely within three months, but the patient reported worsening headache and facial pain in the left upper dental arch. She was referred to the pain group for medical treatment, but became symptom-free only two years after the surgery.

Discussion

The fibrous histiocytoma is a rare condition found over a large age range, between 5 and 75 years. It comprises about 1% of all bone tumors,³ often is seen in lower limb bones and is predisposed to relapses.⁴ Few reports describe temporal bone involvement and most of them report malignant tumors. Differential diagnostic conditions include acute inflammation, benign tumors (giant cell tumor and ossifying fibroma) and malignant lesions (fibrosarcoma and osteosarcoma). Magnetic resonance imaging excluded the possibility of inflammation since the tumor was solid. The imaging revealed extensive pachymeningitis, meningeal thickening, which was likely inflammatory in nature, and located in the paratrigeminal area. Although the surgery had removed the lesion, the contiguous bone and meningeal involvement could explain the headache and earache reported by the patient postoperatively, since no communication with the middle cranial fossa has been detected.^{5,6} This involvement can also explain the relapse of these tumors, making it difficult to be certain of a cure and indicating that long-term follow-up is needed. As this is a rare condition, relapse rates are variable and difficult to determine.

No involvement similar to that shown in this report was found in the literature, with bilateral involvement of temporal bones, meningeal extension, similar histological fea-

tures, and development of the second tumor long after the initial lesion.

Final comments

Although the benign temporal bone histiocytoma is rare, this condition can be found and should be remembered in the differential diagnosis of ear tumors.

Clinical and radiological characteristics should draw the physician's attention to a careful work-up, even in bilateral cases, as in this report.

Conflicts of interest

The authors declare no conflicts of interest.

References

1. Stout AP, Lattes R. Tumors of soft tissue: Atlas of tumors pathology. Washington DC: Armed Forces Institute of Pathology. 1967. p. 38-52.
2. Barney PL. Atypical histiocytoma (fibroxanthoma) of the temporal bone. *Trans Am Acad Ophthalmol Otolaryngol.* 1971;76:1392-3.
3. Rico-Martinez G, Linares-Gonzalez LM, Delgado Cedillo EA, Estrada-Villas Senior EG, Méndez-Vasquez TE. Unconventional hip arthroplasty for a 15-year-old benign bone fibrous histiocytoma in a pediatric patient. *Acta Ortop Mex.* 2010;24:371-5.
4. Dahlin DC. Benign and atypical fibrous histiocytoma. *Bone tumors.* Springfield, Charles Thomas. 1978. p.116.
5. Sanvito WL. *Síndromes Neurológicas.* São Paulo: Atheneu; 2008.
6. Ideguchi M, Kajiwara K, Yoshicawa K, Kato S, Fujisawa H, Suzuki M. Benign fibrous histiocytoma of the skull with increased intracranial pressure caused by cerebral venous sinus occlusion. *J Neurosurg.* 2009;111:504-8.