



ORIGINAL ARTICLE

Histologic correlation of expression of Ki-67 in squamous cell carcinoma of the glottis according to the degree of cell differentiation[☆]



Rodrigo Gonzalez Bonhin^{a,*}, Guilherme Machado de Carvalho^a,
Alexandre Caixeta Guimarães^a, Carlos Takahiro Chone^a, Agrício Nubiato Crespo^a,
Albina Messias de Almeida Milani Altemani^b, Eliane M.I. Amstalden^b

^a Discipline of Otorhinolaryngology, Head and Neck, Universidade Estadual de Campinas (UNICAMP), Campinas, SP, Brazil

^b Department of Pathology, Universidade Estadual de Campinas (UNICAMP), Campinas, SP, Brazil

Received 9 February 2013; accepted 11 March 2014

Available online 11 June 2014

KEYWORDS

Carcinoma,
squamous cell;
Glottis;
Biological markers;
Cell proliferation;
Head and neck
neoplasms

Abstract

Introduction: Squamous cell carcinoma is the most common neoplasm of the larynx and glottis, and its prognosis depends on the size of the lesion, level of local invasion, cervical lymphatic spread, and presence of distant metastases. Ki-67 (MKI67) is a protein present in the core, whose function is related to cell proliferation.

Aim: To evaluate the expression of marker Ki-67 in squamous cell carcinoma of the larynx and glottis and its correlation to pathological findings.

Methods: Experimental study with immunohistochemistry analysis of Ki-67, calculating the percentage of the cell proliferation index in glottic squamous cell carcinomas.

Results: Sixteen cases were analyzed, with six well-differentiated and 10 poorly/moderately differentiated tumors. There was a correlation between cell proliferation index and degree of cell differentiation, with higher proliferation in poorly/moderately differentiated tumors.

Conclusion: The cell proliferation index, as measured by Ki-67, may be useful in the characterization of histological degree in glottic squamous cell tumors.

© 2014 Associação Brasileira de Otorrinolaringologia e Cirurgia Cérvico-Facial. Published by Elsevier Editora Ltda. All rights reserved.

[☆] Please cite this article as: Bonhin RG, de Carvalho GM, Guimarães AC, Chone CT, Crespo AN, Altemani AM, et al. Histologic correlation of expression of Ki-67 in squamous cell carcinoma of the glottis according to the degree of cell differentiation. Braz J Otorhinolaryngol. 2014;80:290–5.

* Corresponding author.

E-mail: bonhin@yahoo.com (R.G. Bonhin).

PALAVRAS-CHAVE

Carcinoma de células escamosas;
Glote;
Marcadores biológicos;
Proliferação de células;
Neoplasias de cabeça e pescoço

Correlação histológica da expressão do Ki-67 no Carcinoma Epidermoide Glótico de acordo com grau de diferenciação celular

Resumo

Introdução: O carcinoma de células escamosas é a neoplasia mais frequente da laringe e da região glótica, seu prognóstico depende do tamanho da lesão, do nível de invasão local, disseminação cervical linfática e da existência de metástases à distância. Ki-67 (MKI67) é uma proteína presente no núcleo, cuja função está relacionada com a proliferação celular.

Objetivos: Avaliar a expressão do marcador Ki-67 em carcinoma de células escamosas da laringe glóticas e correlacionar sua expressão com os achados anatomopatológicos.

Método: Trabalho experimental de análise imunohistoquímica do Ki 67 através do cálculo percentual do índice de proliferação celular em produtos de carcinomas epidermóides glóticos.

Resultados: Dezesesseis casos foram analisados, sendo seis bem diferenciados e dez pouco/moderadamente diferenciados. Houve correlação entre o índice de proliferação celular e o grau de diferenciação celular, sendo a proliferação maior nos pouco/moderadamente diferenciados.

Conclusão: O índice de proliferação celular, medido pelo Ki-67 pode ser útil na caracterização do grau histológico em tumores glóticos de células escamosas.

© 2014 Associação Brasileira de Otorrinolaringologia e Cirurgia Cérvico-Facial. Publicado por Elsevier Editora Ltda. Todos os direitos reservados.

Introduction

Squamous cell carcinoma is the most common neoplasm of the larynx and glottic region, and its prognosis depends on the size of the lesion, level of local invasion, lymphatic spread, and presence of distant cervical metastases.¹⁻⁵ The behavior of the squamous cell carcinoma is marked by the degree of cell proliferation and differentiation, and this index can be derived by measuring Ki-67.⁶⁻¹⁰

Histologically, the epidermoid or squamous cell carcinoma in these regions is similar to the others. It is defined by the neoplastic proliferation of squamous cells in different degrees of differentiation and their infiltrative nature. Depending on the power of keratinization and cellular atypia, they are classified as follows: well, moderately, or poorly differentiated.¹

The well-differentiated type is characterized by its similarity with normal squamous epithelium, high power of keratinization, and very mild cell atypia; the moderately differentiated type contains distinct nuclear pleomorphism and mitotic activity is present, including atypical figures. In this type, keratinization is much lower.^{1,2} In the poorly differentiated type, there is a predominance of immature cells, with numerous mitotic figures and virtually absent keratinization.

The level of invasion may be limited to the epithelium, respecting the basal lamina, which is called *in situ*. When it affects only the lamina propria, it is considered microinvasive or superficially invasive.²

As for the frankly invasive carcinoma, it manifests as the destruction of the basal lamina, clearly extending to the underlying tissues, possibly accompanied by stromal reaction. Perineural invasion and angiolymphatic invasion are signs of increased aggressiveness and change in staging, respectively.³

Broders proposed a grading system for squamous cell carcinomas.^{11,12} The classification established in 1920 and subsequently reviewed in 1925 was based on the

Table 1 Broders' classification.

Broders' histological classification	
Parameter	Characteristics
Grade I	0–25% undifferentiated cells
Grade II	25–50% undifferentiated cells
Grade III	50–75% undifferentiated cells
Grade IV	75–100% undifferentiated cells

fundamental principle of cellular differentiation, and was completely dissociated from clinical history. Carcinomas were divided into four grades, ranging from I to IV. Carcinomas of grade I had up to 25% undifferentiated cells. Grade II tumors had 25–50% undifferentiated cells. Grade III tumors consisted of 50–75% undifferentiated cells and Grade IV tumors had 75–100% undifferentiated cells (Table 1).^{11,12}

The histopathological classification of malignancy proposed by the World Health Organization (WHO, 2005) was based on the degree of cell differentiation and allowed the classification of this malignancy into three categories, as well-, moderately and poorly differentiated (Table 2).^{2,11-13}

The well-differentiated tumor is characterized by similarity with normal squamous epithelium, high power of keratinization, and very mild cell atypia; the moderately differentiated contains distinct nuclear pleomorphism, presence of mitotic activity, including atypical figures. In this type, keratinization is much lower.² In the poorly differentiated type, immature cells predominate with numerous mitotic figures and keratinization is virtually absent. Regarding the power of invasion, it can be limited to the epithelium, respecting the basal lamina, when it is called *in situ*. When it only affects the lamina propria, it is considered microinvasive or superficially invasive.²

The frankly invasive carcinoma is manifested by the destruction of the basal lamina with clear extension to

Table 2 Classification recommended by the World Health Organization (WHO).

Histological classification – WHO	
Parameter	Characteristics
Poorly differentiated	Predominance of immature cells Abundant typical and atypical mitoses Minimal keratinization
Moderately differentiated	Some degree of pleomorphism and mitotic activity Little keratinization
Well-differentiated	Tissue architecture similar to the normal pattern of squamous epithelium

underlying tissues, possibly accompanied by stromal reaction. Perineural invasion and angiolymphatic invasion are signs of increased aggressiveness and change in staging, respectively.³

The measurement of mitotic figures, a common practice in the evaluation of tumors regarding their growth rate and degree of aggressiveness, is far from its desired accuracy, since it is not possible to know, through histological sections routinely stained with H&E, which are exactly the cells that entered the cell division cycle. This is due to the fact that the phases G1, S, and G2 of the cell cycle are not identified by optical microscopy (Fig. 1).¹²

Ki-67 (MKI67) is a protein present in the nucleus, whose function is related to cell proliferation. This protein is only expressed in the cell division cycle: interphase (G1, S, G2), prophase, metaphase, anaphase, and telophase, and is absent in the G0 phase, when the cell is quiescent; therefore, it is an excellent marker of cell division.¹¹⁻¹³

The monoclonal antibody Ki-67 is used to demonstrate the expression of this nuclear protein. This antibody binds to its specific-antigen (MKi67) present in the nuclei of proliferating cells, staining them and highlighting all cells that have entered the cell division cycle.^{12,13}

Through optical microscopy it is possible to count the number of cells per field or “hot spot” areas, which are stained, and to calculate the proliferation index (Ki-67

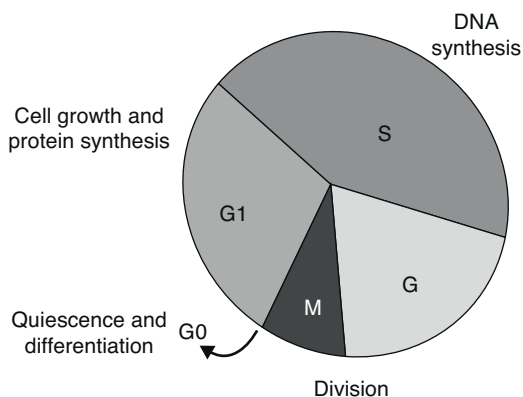


Figure 1 Phases of cell cycle. G1, S, G – presence of MKI67.

index). The analysis of this index is what allows for the characterization of the degree of tumor cell proliferation (growth rate) and consequently, its degree of aggressiveness, increased risk of new tumor clones, and mutations, which hinder tumor restriction by the immune system.^{12,13}

This study aimed to evaluate the expression of the Ki-67 marker in glottic squamous cell carcinoma of the larynx and correlate it regarding pathological findings and cell proliferation characteristics.

Materials and methods

This was an experimental clinical study performed with a cross-section in a historical cohort, using resection specimens from glottic squamous cell carcinoma of patients from a tertiary care university hospital. The patients were submitted to hemi-laryngectomy, total laryngectomy, and removal of the vocal cords with their respective lymphadenectomy.

To facilitate the statistical analysis of glottic tumors, they were divided into well-differentiated and moderately/poorly differentiated.

Cases of glottic squamous cell carcinoma tumors were obtained from the database of the Pathological Anatomy Department of a tertiary university hospital in the period of 1994–2004. This sample included 99 cases in total: 85 cases were moderately/poorly differentiated tumors, of which 41 cases were products of surgical specimens and 44 cases were biopsies that were not treated surgically (chemotherapy/radiotherapy). Fourteen cases were well-differentiated tumors, with eight cases representing products of surgical specimens and six biopsy cases that were not treated surgically (chemo/radiotherapy).

The study only included cases that had surgical specimens, excluding biopsy cases, as they would bring bias to the study by including random tumor fragments. Of eight well-differentiated products of surgical specimens, two cases did not have paraffin blocks available for new sections.

Therefore, the study was conducted with six cases of well-differentiated glottic laryngeal tumors, and 10 cases of moderately/poorly differentiated glottic laryngeal tumors were randomly selected to comprise the control group. The groups did not have the same number of cases, as there were not enough cases of well-differentiated tumors to complete the group.

The inclusion criteria were glottic laryngeal tumors for which paraffin blocks were identified and that contained enough material for new sections. Clinical data and tumor staging were obtained from medical records (Table 3).

The study was approved by the ethics committee of the institution (no. 485/11).

Immunohistochemical analysis was performed with the avidin-biotin-peroxidase method and used the following antibody: Ki-67 (Clone MIB-1, IgG1, 1:150, Dako brand, pre-treated Tris-EDTA).

Positive and negative controls of the marker were used, in order to compare them with the studied cases. Lymphoid tissue was used as positive control.

The specimens were analyzed randomly, by an investigator who had no knowledge of the previous diagnosis given by the pathologist and no knowledge of the patient’s clinical status, comparing them with the positive and negative

Table 3 Clinical data of study patients.

Clinical data	Group 1	Group 2	Obs
TNM	T1N0M0 – four cases T2N0M0 – one case T3N0M0 – one case	T1N0M0 – three cases T2N0M0 – five cases T2N1M0 – one case T3N0M0 – one case	
Alcohol consumption	50% (3 cases)		
Smoking	67% (4 cases)		
Gender	4 M:2 F	10 M:0 F	
Age	53 (37–73)	58 (39–70)	
Preop. clinical neck	Negative	1 positive case (N1)	
Margins	50% positive	100% negative	
Vascular invasion	100% negative	80% negative	2 cases+
Neural involvement	100% negative	90% negative	1 case+
Extracapsular extension	100% negative	100% negative	
Preop. radiotherapy	0 cases	1 case	
Postop. radiotherapy	50% (3 cases)	20% (2 cases)	
Preop. chemotherapy	0 cases	0 cases	
Postop. chemotherapy	0 cases	0 cases	
Total	6 patients	10 patients	

Group 1, well-differentiated glottic SCC; Group 2, CEC moderately/poorly differentiated glottic SCC; Preop., preoperative; Postop., postoperative.

controls. Pictures scanned at high magnification (400×) were taken from highly reactive areas (hot spots), using a Nikon camera (Coolpix 995). Subsequently, the images were uploaded to the computer for histological analysis, using the software Imagelab 2000. All parameters were blindly evaluated.

The evaluation of the cell proliferation rate was performed using common percentage ratio, as it already has been used in literature.^{8,9} Five areas of greater intensity of immunomarker expression (hot spots) were selected. At least 500 cells were counted, and the ratio between the number of cells that had a positively stained nucleus and the total number of cells was calculated. The percentage ratio was stratified as follows: <5% – low cell proliferation rate; between 5% and 10% – mild cell proliferation rate; between 10% and 30% – moderate cell proliferation rate; and >30% – high cell proliferation rate.

To simplify and better analyze the data, they were grouped as follows:

Cell proliferation index:

- Low/mild cell proliferation.
- Moderate/high cell proliferation.

Histological type:

- Glottic, well-differentiated.
- Glottic, moderately/poorly differentiated.

Statistical analysis

After pooling of the data, the statistical analysis was carried out with IBM SPSS Statistics® software, using the Chi-squared test and Fisher's exact test.

Results

A total of 16 cases were evaluated, with six well-differentiated and 10 moderately/poorly differentiated cases.

Among the well-differentiated glottic tumors ($n=6$ cases), four cases had low/mild cell proliferation and two cases had moderate/high cell proliferation. Among the moderately/poorly differentiated glottic tumors ($n=10$ cases), one case had low/mild cell proliferation and nine cases had moderate/high cell proliferation.

In the correlation analysis of cell differentiation degree versus cell proliferation index, statistical significance was demonstrated ($p < 0.05$) when comparing the groups through two-tailed Fisher's exact test, with $p = 0.036$.

Table 4 Distribution of cases according to histological type and cell proliferation.

		Histological type		Total
		Well-differentiated	Moderately/poorly differentiated	
Ki-67	Low/mild	4	1	5
	Moderate/high	2	9	11
Total		6	10	16

Considering the histological type as the gold standard to assess cell differentiation in laryngeal carcinomas, the cell proliferation index had a sensitivity of 0.9, specificity of 0.67, positive predictive value of 0.82, and negative predictive value of 0.8 (Table 4).

Discussion

The cell proliferation index was positively correlated with the degree of cell differentiation, and was higher in moderately/poorly differentiated cases. This finding corroborates the idea that the more undifferentiated the neoplasm, the poorer the control of the cell division process and the greater the proliferation.⁸ This evaluation showed statistical significance between tumor type correlation and cell proliferation index ($p < 0.05$).

The studies by Rodrigues et al. found no correlation between the immunohistochemical expression of Ki-67 and prognostic value;^{7,14,15} however, it appears that Ki-67 overexpression associated with the idea of mitotic disarray, uncontrolled cell growth, and proliferation would be associated with prognostic factors and approach prioritization of these patients.

An interesting fact was pointed out in a Canadian retrospective study on the clinical use of Ki-67, which demonstrated that its overexpression is correlated with high risk of cervical recurrence after radiotherapy and, therefore, such cases should undergo more targeted treatment at earlier stages.¹⁶

Other head and neck tumor sites, such as the oral cavity, also provide evidence that over expression of markers such as p53 and Ki-67 constitute a greater risk and poorer prognosis for this type of squamous cell carcinoma.¹⁷

In a study with animals exposed to tobacco, only the development of benign lesions was observed, with no progression to malignant tumors. Histological evaluation of these animals showed absence of p53 marking, but Ki-67 positivity associated with the tobacco-induced lesion was observed.¹⁸

When assessing the clinical prognosis of patients with epidermoid carcinomas of the larynx, it was observed that the Ki-67 marker associated with Ki-S11 is an important tool to aid in clinical management and prognostic analysis. Patients with low cell proliferation rate assessed by these markers have a lower recurrence rate with statistical significance ($p < 0.05$) and improved five-year survival when compared to the group with high cell proliferation rate.¹⁹

Regarding the clinical application of Ki-67, it was also shown that the group of patients with expression considered to be positive had higher rate of local recurrence, even after radiotherapy. It is suggested that these patients have a personalized and more detailed follow-up protocol.¹⁶ However, in another group, it was identified that patients with glottic tumors involving the anterior commissure and showing over expression of Ki-67 had a better outcome and had tumors considered to be radio-sensitive, with significant relevance of results.²⁰

The literature also indicates the methodology used in the anatomopathological evaluation of advanced epidermoid carcinoma of the larynx. In the aforementioned study, the heterogeneity in Ki-67 expression was demonstrated in

areas of tumor cell activity and, therefore, an assessment methodology should be well-established, and the variability of previous studies that correlated the expression of immunomarkers with prognostic factors can be explained by such characteristic.²¹

The evaluation of carcinoma precursor lesions (hyperplasia, carcinoma *in situ*) was also performed in studies with immunomarkers such as Ki-67 and p-16. Of these lesions, carcinoma *in situ* tends to have a higher positivity than isolated hyperplasias.²²

Although the present study found a significant correlation between cell proliferation degree and histological tumor differentiation, there were two cases (18%) in which the rate of cell proliferation was moderate/high even in well-differentiated tumors. Considering that even some well-differentiated tumors showed high cell proliferation index, these tumors possibly exhibit a more aggressive behavior, as with the increased population of tumor cells, the chance of mitotic disarray is greater.

New clones that may be more aggressive due to mutations and that hinder restriction by the immune system may have better response to chemotherapy and radiotherapy. Future studies that assess the behavior of well-differentiated tumors with high rate of cell proliferation may assist in the management of these patients.

It is noteworthy that although this study had a sample of 16 patients, limited by the difficulty in obtaining surgical material from well-differentiated glottic cases, it emphasized the analysis of this specific region of the larynx, different from other studies with larger samples that included patients with carcinomas in any region of the larynx. Therefore, the present study corroborates the correlation between increased expression of Ki-67 in more undifferentiated tumors,⁸ and demonstrates that this correlation also applies specifically to laryngeal glottic tumors.

The authors believe that the association between the expression of Ki-67 with clinical criteria and prognosis remains unclear. This association is still quite controversial in the medical literature, in both clinical and experimental studies. The relevance of using immunomarkers is clear; however, further studies are necessary to better define the patients in which immunomarkers should be used in clinical practice.

Conclusion

This study demonstrated that the rate of cell proliferation measured by Ki-67 may be useful in characterizing the histological grade in glottic squamous cell tumors of the larynx. Further studies are needed to evaluate the behavior of well-differentiated tumors with high rate of cell proliferation to define the best therapeutic approach in these patients. Other factors must be involved regarding the pathogenesis and tumor progression of this disease in the glottis.

Funding

This study was supported by PIBIC/CNPq.

Conflict of interest

The authors declare no conflicts of interest.

References

1. Altemani AMAM, Amstalden EMI, Bogliolo. *Patologia*. 8th ed. Guanabara Koogan; 2009.
2. *Diagnostic histopathology of tumors*. 3rd ed. Elsevier; 2007. p. 158–65.
3. *Sternberg's diagnostic surgical pathology*. 5th ed. Wolters Kluwer Health/Lippincott William & Wilkins; 2009. p. 777–92.
4. Carde-sa A, Gale N, Nadal A, Zidar N. *Pathology and genetics of head and neck tumors (WHO/OMS)*. IARC Press; 2005. p. 118–21.
5. Carvalho GM, Chone CT, Guimarães AG, Kohler HF, Gripp FM, Crespo AN, et al. Planned neck dissection: evaluation of viable metastases. *Rev Bras Cir Cabeça Pescoço*. 2011;40:133–7.
6. Mohan S, Epstein JB. Carcinogenesis and cyclooxygenase: the potential role of COX-2 inhibition in upper aerodigestive tract cancer. *Oral Oncol*. 2003;39:537–46.
7. Rodrigues RB, Motta RR, Machado SMS, Cambuzzi E, Zettler EW, Zettler CG, et al. Prognostic value of the immunohistochemistry correlation of Ki-67 and p53 in squamous cell carcinomas of the larynx. *Braz J Otorhinolaryngol*. 2008;74:855–9.
8. Ashraf MJ, Maghbul M, Azarpira N, Khademi B. Expression of Ki67 and P53 in primary squamous cell carcinoma of the larynx. *Indian J Pathol Microbiol*. 2010;53:661–5.
9. Haroon S, Hashmi AA, Khurshid A, Kanpurwala MA, Mujuba S, Malik B, et al. Ki67 index breast cancer: correlation with other prognostic markers and potential in Pakistani patients. *Asian Pac J Cancer Prev*. 2014;14:4353–8.
10. Boonkitticharoen V, Kulapaditharom B, Leopairut J, Kraiphibul P, Larbcharoensub N, Cheewaruangroj W, et al. Vascular endothelial growth factor a and proliferation marker in prediction of lymph node metastasis in oral and pharyngeal squamous cell carcinoma. *Arch Otolaryngol Head Neck Surg*. 2008;134:1305–11.
11. Broders AC. The microscopic grading of cancer. *Surg Clin North Am*. 1941;21:947–62.
12. Lourenço SQC, Schueler AF, Camisasca DR, Lindenblatt RC, Bernardo VG. Histological classifications of oral squamous cell carcinoma: a review of the proposed systems. *Rev Bras Cancerol*. 2007;53:325–33.
13. Ward LS. Entendendo o processo molecular da tumorigênese. *Arq Bras Endocrinol Metab*. 2002;46:351–60.
14. Bubán T, Tóth L, Tanyi M, Kappelmayer J, Antal-Szalmás P. Ki-67 – new faces of an old player. *Orv Hetil*. 2009;150:1059–70.
15. Calli C, Calli A, Pinar E, Oncel S, Tatar B. Prognostic significance of p63, p53 and ki67 expression in laryngeal basaloid squamous cell carcinomas. *B-ENT*. 2011;7:37–42.
16. Nichols AC, Whelan F, Basmaji J, Dhaliwal S, Dowthwaite S, Chapeskie C, et al. Ki-67 expression predicts radiotherapy failure in early glottic cancer. *J Otolaryngol Head Neck Surg*. 2012;41:124–30.
17. Motta Rda R, Zettler CG, Cambuzzi E, Jotz GP, Berni RB. Ki-67 and p53 correlation prognostic value in squamous cell carcinomas of the oral cavity and tongue. *Braz J Otorhinolaryngol*. 2009;75:544–9.
18. de Oliveira Semenzati G, de Souza Salgado B, Rocha NS, Michelin Matheus SM, de Carvalho LR, Garcia Martins RH. Histological and immunohistochemical study of the expression of p53 and ki-67 proteins in the mucosa of the tongue, pharynx and larynx of rats exposed to cigarette smoke. *Inhal Toxicol*. 2012;24:723–31.
19. Cordes C, Münzel AK, Rudolph P, Hoffmann M, Leuschner I, Gottschlich S. Immunohistochemical staining of Ki-67 using the monoclonal antibody Ki-s11 is a prognostic indicator for laryngeal squamous cell carcinoma. *Anticancer Res*. 2009;29:1459–65.
20. Ahmed WA, Suzuki K, Imaeda Y, Horibe Y. Ki-67, p53 and epidermal growth factor receptor expression in early glottic cancer involving the anterior commissure treated with radiotherapy. *Auris Nasus Larynx*. 2008;35:213–9.
21. Wittekindt C, Sittel C, Greiss J, Drebber U, Eckel HE, Preuss SF. Mapping of Ki-67 protein distribution on whole organ serial sections of the larynx. *Acta Otolaryngol*. 2008;128:207–12.
22. Pavlovic B, Djukic V, Milovanovic J, Tomanovic N, Milovanovic A, Trivic A. Morphometric analysis of Ki67 and p16 expression in laryngeal precursor lesions. *Eur Arch Otorhinolaryngol*. 2013;270:1405–10.