



ORIGINAL ARTICLE

Association between maxillary sinus pathologies and healthy teeth^{☆,☆☆}



Gina D. Roque-Torres^{a,*}, Laura Ricardina Ramirez-Sotelo^a,
Sergio Lins de Azevedo Vaz^{b,c}, Solange Maria de Almeida de Bóscolo^a,
Frab Norberto Bóscolo^a

^a Department of Oral Diagnosis, Faculdade de Odontologia de Piracicaba, Universidade Estadual de Campinas (UNICAMP), Piracicaba, SP, Brazil

^b Dental Radiology, Universidade Estadual de Campinas (UNICAMP), Piracicaba, SP, Brazil

^c Department of Dental Clinic, School of Dentistry, Universidade Federal do Espírito Santo (UFES), Vitória, ES, Brazil

Received 24 March 2014; accepted 9 December 2014

Available online 10 December 2015

KEYWORDS

Molar tooth;
Premolar tooth;
Maxillary sinus;
Dental root;
Cone beam computed tomography

Abstract

Introduction: The proximity of the roots to the maxillary sinus can create a variety of risks.
Objective: To evaluate the relationship between the roots of healthy teeth and the maxillary sinus, as well as the occurrence of sinus pathologies.
Methods: Three radiologists analyzed 109 cone beam computed tomography (CBCT) images. The Kappa test was used to assess the intra- and inter-rater agreement. The chi-squared test and prevalence ratio were used to test the hypothesis that roots of healthy teeth in the maxillary sinus favored the occurrence of sinus pathologies ($p=0.01$).
Results: Intra- and inter-rater agreement ranged from good to excellent. The chi-squared test demonstrated a statistically significant difference ($p=0.006$) between the tooth roots in diseased maxillary sinuses (6.09%) and those in normal sinuses (3.43%). The prevalence ratio test showed a statistically significant higher prevalence of tooth roots in diseased sinuses than in normal sinuses ($p<0.0001$). Roots in the maxillary sinus were 1.82 times more associated with diseased sinuses.

[☆] Please cite this article as: Roque-Torres GD, Ramirez-Sotelo LR, Vaz SLA, de Almeida de Bóscolo SM, Bóscolo FN. Association between maxillary sinus pathologies and healthy teeth. Braz J Otorhinolaryngol. 2016;82:33–8.

^{☆☆} Institution: Department of Oral Diagnosis, Piracicaba School of Dentistry, State University of Campinas, Piracicaba, SP, Brazil.

* Corresponding author.

E-mail: ginart87@gmail.com (G.D. Roque-Torres).

PALAVRAS-CHAVE

Dente molar;
Dente pré-molar;
Seio maxilar;
Raiz dentária;
Tomografia
computadorizada
de feixe cônico

Conclusion: Dental roots in the maxillary sinus are almost twice as likely to be associated with diseased sinuses than normal sinuses. Healthy teeth whose roots are inside the maxillary sinus may induce an inflammatory response in the sinus membrane. It is suspected that dental procedures may exacerbate the condition.

© 2015 Associação Brasileira de Otorrinolaringologia e Cirurgia Cérvico-Facial. Published by Elsevier Editora Ltda. All rights reserved.

Relação entre doenças no seio maxilar e dentes hígidos**Resumo**

Introdução: A proximidade das raízes com o seio maxilar pode criar uma variedade de riscos.

Objetivo: Avaliar a relação entre as raízes dos dentes hígidos com o seio maxilar, assim como com a ocorrência de doenças sinusais.

Método: Três radiologistas analisaram 109 imagens de tomografia computadorizada de feixe cônico (TCFC). O teste Kappa avaliou a concordância intra e interexaminadores. Os testes de Qui-quadrado e Razão de Prevalência foram utilizados para testar a hipótese de que raízes de dentes hígidos dentro do seio maxilar favorecem a ocorrência de doenças sinusais (nível de significância = 0,01).

Resultados: A concordância intra e interexaminadores variou de boa a excelente. O teste Qui-quadrado mostrou uma diferença estatisticamente significativa ($p = 0,006$) entre as raízes dentárias dentro do seio maxilar patológico (6,09%) e aquelas dentro do seio normal (3,43%). O teste de Razão de Prevalência mostrou uma ocorrência de raízes dentárias dentro de seios patológicos estatisticamente maior do que dentro de seios normais ($p < 0,0001$). As raízes dentro do seio maxilar foram encontradas 1,82 vezes mais associadas a seios patológicos.

Conclusão: Raízes dentárias dentro do seio maxilar são quase duas vezes mais associadas a seios patológicos do que a seios normais. Dentes hígidos que têm raízes dentro do seio maxilar podem induzir uma resposta inflamatória da mucosa sinusal. Suspeita-se que procedimentos odontológicos possam agravar tal situação.

© 2015 Associação Brasileira de Otorrinolaringologia e Cirurgia Cérvico-Facial. Publicado por Elsevier Editora Ltda. Todos os direitos reservados.

Introduction

Maxillary sinuses can vary in size and shape from one individual to another, or even between the right and left sides in the same individual. In approximately half of the population, their length also varies. The floor of the maxillary sinus extends into the alveolar process between the roots of adjacent teeth, creating elevations and depressions called "extensions," with narrow cortical areas.^{1,2} Through histological sections, it has been radiographically demonstrated that most of the roots projecting into the maxillary sinus were in fact surrounded by a thin layer of cortical bone, with perforations present in 14–28% of cases.³ Under normal conditions, the relationship between the tooth and the floor of the maxillary sinus consists of either a thin layer of compact bone that provides support to the apical periodontal ligament fibers, to which it firmly adheres, or there is a direct relationship with the maxillary sinus mucosa. The inner lining of the maxillary sinus cavity is devoid of periosteum; therefore, in the absence of a thin layer of intervening bone, the periodontal tissues are in direct contact with the basal surface of the sinus mucosa.²

The roots of the upper premolars, molars, and occasionally the canine teeth have a close relationship with the

maxillary sinus; in some cases, they may even protrude into it.^{4–6} It has been demonstrated that the closer the tooth apex is to the floor of the maxillary sinus, the greater the impact on antral tissue.⁷ This relationship can result in a variety of risks, especially for certain surgical procedures, such as tooth extraction and implant placement, or during endodontic or orthodontic treatments.^{4,5,8} An accurate description of the relationship between the apices of the upper teeth and the lower wall of the maxillary sinus, as well as the thickness of the cortical bone between these structures, is essential for planning dental procedures.

Dental radiographs, such as panoramic radiography, consist of two-dimensional images and, as such, are inappropriate and/or of little use for accurate morphometric assessment of bone relationships.⁴ In cases where the panoramic radiograph reveals a possible relationship between a tooth that has undergone intervention and its contact with the adjacent maxillary sinus, evaluation by cone beam computed tomography (CBCT) can assist in dental treatment planning. This imaging modality allows for a thorough analysis of the anatomical relationship between the maxillary sinus and the roots of the upper teeth,^{4,6,9,10} thus overcoming the limitations of panoramic radiography, providing multiplanar views without magnification, distortion, or

superimposition.¹¹ This technique is superior to multi-slice computed tomography due to its higher image resolution, reduced radiation exposure, and lower equipment cost.¹²

In apical periodontitis, a periodontal disease,^{13,14} treatment with implants and extraction of upper premolars and molars¹⁵ may increase the risk of pathological processes in the adjacent maxillary sinus. Of the odontogenic sinus diseases, apical periodontitis and periodontal disease account for 83% of all cases having dental origin.^{13,16} The most frequent maxillary sinus pathologies are sinus mucosal thickening and mucous retention cysts, with a prevalence ranging from 8% to 29% and 2% to 36%, respectively.^{16–19} Another study has reported a prevalence rate of odontogenic maxillary sinusitis ranging from 10% to 86%.²⁰

There are few studies describing the relationship between maxillary sinus diseases and healthy upper posterior teeth in contact with the maxillary sinus. Therefore, in order to answer this question, this study aimed to evaluate the relationship between the roots of healthy teeth with healthy and diseased (mucosal thickening and mucous retention cysts) maxillary sinuses through CBCT. This research can help identify correlations between teeth and sinus diseases without causal factors.

Methods

For this study, 109 CBCT images were selected, obtained independently of this research for diagnosis and treatment planning purposes. All images belonged to the digital archive of the Radiology Clinic. After approval of the study protocol by the local Research Ethics Committee (Protocol No. 084/2012), the sample consisted of 78 women and 31 men, mean age 22 years (range: 18–30 years), without distinction by race, gender, social class, or other socioeconomic characteristics. In all images, both maxillary sinuses ($n=218$) and the roots of all premolars and molars on both sides ($n=1875$) were evaluated.

CT scans were obtained using the I-CAT Classic scanner (Imaging Sciences International – Pennsylvania, United States), using the following exposure parameters: 8 mA, 120 kVp, acquisition time of 40 s, 13 cm × 17 cm field of vision, and voxel size of 0.25 mm. Images with good sharpness, density, and contrast were selected. The images had to present the apices of the upper posterior teeth and the maxillary sinus along their entire length.

For inclusion in the study, the images had to present complete permanent dentition, with no evidence of any type of dental pathology, with fully formed root apices, and without the presence of supernumerary teeth. Most reasons for CBCT imaging comprised temporomandibular joint disorder, orthodontic treatment, and evaluation of third molars. Images with evidence of carious lesions, prosthetic crowns, filled root canal, periapical lesions, bifurcation lesions, and moderate or severe bone loss were excluded.

Three experts in dental radiology, who had a minimum experience of two years in CBCT, were selected for the study. In low light conditions, these experts independently assessed the presence or absence of sinus disorders (mucosal thickening or mucous retention cysts), and the topographical relationship between the maxillary sinus and each apex of the upper posterior teeth (first and second premolars,

as well as first and second molars). Only these teeth were assessed, as their root apices are the closest to the maxillary sinus floor. The relationship of the root with the maxillary sinus was determined as follows: roots in the maxillary sinus, and roots outside of the maxillary sinus (apexes in contact or not with the limits of the maxillary sinus cortical). This topographical evaluation (Fig. 1) of the teeth was performed using multiplanar reconstruction (MPR). All views attainable within the software were made available for the detection of pathological findings; thus, the evaluators were allowed to adjust the brightness, contrast, and zoom of the image. The use of filters was not authorized.

The mode was obtained from the three evaluations, both for the topographic relationship between the root and the maxillary sinuses and for the presence or absence of sinus pathology. The frequency of tooth roots inside and outside of the maxillary sinus and the presence or absence of pathology in the maxillary sinus were quantified and subsequently assessed with the chi-squared test and prevalence ratio. A p -value < 0.01 was considered as statistically significant.

Thirty days after the first evaluation, 27% of the sample was re-evaluated for reliability measurements. Inter- and intra-rater correlation was calculated using the Kappa test (poor agreement, 0.40; moderate agreement, 0.40–0.59; good agreement, 0.60–0.74; excellent agreement, 0.75–1.00).

Results

The Kappa values for inter- and intra-rater agreement in the assessments of root-maxillary sinus relationship and of sinus disorders ranged from good to excellent (Table 1).

The frequency of diseased maxillary sinus (34.98%) was lower than that of normal maxillary sinuses (65.02%). Most roots were located outside the maxillary sinus (95.63%). This was observed in normal maxillary sinuses (96.57%), as well as in diseased sinuses (93.91%; Table 2).

The chi-squared test demonstrated that there was a statistically significant difference ($p=0.006$) between the occurrence of tooth roots within diseased maxillary sinuses (6.09%) and within normal sinuses (3.43%). A statistically greater difference was observed in the prevalence of tooth roots within diseased sinuses than in normal sinuses ($p < 0.0001$). Roots located within the maxillary sinuses were

Table 1 Kappa values for inter- and intra-rater agreement.

	Rater 1	Rater 2	Rater 3
<i>Root-maxillary sinus relationship</i>			
Rater 1	0.65	–	–
Rater 2	0.61	0.62	0.61
Rater 3	0.62	–	0.63
<i>Sinus pathology</i>			
Rater 1	1.00	–	–
Rater 2	0.61	1.00	0.78
Rater 3	0.66	–	0.93

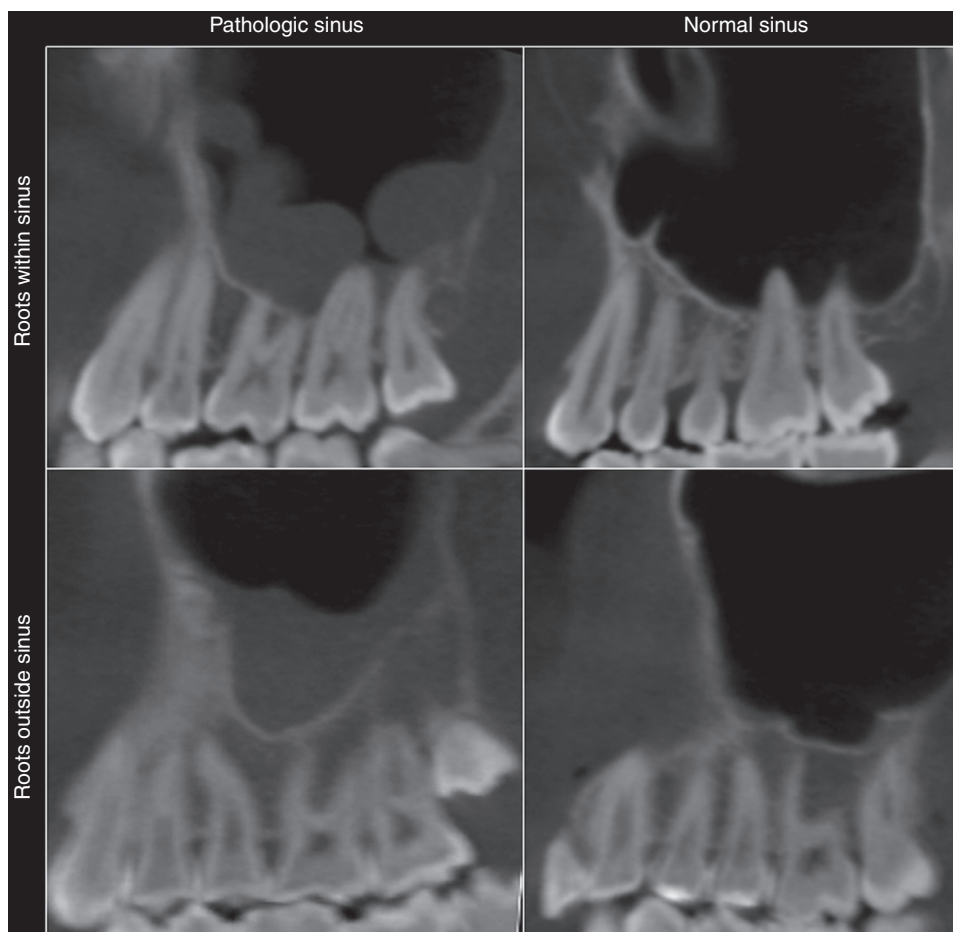


Figure 1 The sinus cavities were classified as diseased or normal. The tooth roots were considered to be inside or outside the sinus.

Table 2 Number of roots inside and outside diseased and normal maxillary sinuses.

	Diseased sinus, <i>n</i> (%)	Normal sinus, <i>n</i> (%)	Total, <i>n</i> (%)
Roots outside the maxillary sinuses	632 (93.91)	1208 (96.57)	1840 (95.63)
Roots inside the maxillary sinuses	41 (6.09)	43 (3.43)	84 (4.37)
Total	673	1251	1924

$\chi^2 = 7387$; $p = 0.006$.

found to be present 1.82 times more frequently in diseased sinuses (95% confidence interval: 1.67–1.98).

The stratification of teeth group with the diseased sinuses, in increasing order, was as follows: first premolar

(0%), lower second premolar (7.31%), first molar (41.46%), and second molar (51.21%). The order for normal sinus was as follows: first premolar (4.65%), second premolar (6.97%), second molar (37.2%), and first molar (51.16%; [Table 3](#)).

Table 3 Number of roots inside diseased and normal maxillary sinuses, by tooth group.

	Diseased sinus, <i>n</i> (%)	Normal sinus, <i>n</i> (%)	Total, <i>n</i> (%)
Second molar	21 (51.21)	16 (37.2)	37 (44.04)
First molar	17 (41.46)	22 (51.16)	39 (46.42)
Second premolar	3 (7.31)	3 (6.97)	6 (7.14)
First premolar	0 (0)	2 (4.65)	2 (2.38)
Total	41 (100)	43 (100)	84 (100)

Discussion

This study aimed to investigate the relationship between tooth roots in the maxillary sinuses and the presence of sinus diseases. The patients in this sample did not present dental diseases such as caries, periapical lesions, filled root canals, or significant alveolar bone loss.

The topographic root-maxillary sinus relationship was assessed using CBCT images obtained from an archive. Studies have shown that when panoramic radiograph was used as a method of assessment, the root-maxillary sinus relationship was improperly determined in 39–57% of cases.^{5,21} The literature has also shown that the reliability in detecting sinus diseases, such as mucosal thickening, is higher using CBCT than 2-D X-rays.²² Consequently, CBCT was considered to be a reliable method for the purposes of the present study.

Three experts in dental radiology, who had at least two years experience with CBCT images, evaluated the images of this study independently; the mode of the three evaluations was then obtained. The inter-rater agreement was measured by the Kappa test. This methodology is rarely applied in similar studies, which often use only one evaluator,^{12,20,23} or two evaluators who then reach a consensus,^{22,24,25} and do not present statistical data regarding the agreement between evaluators. In this study, intra- and inter-rater agreements regarding the tooth-maxillary sinus relationship were good. For sinus conditions, the inter-rater agreement was also good, but for raters 2 and 3, it was excellent. The differences found in this aspect of the study may be related to the fact that the experts were free to evaluate the MPR images as preferred. This may also reflect the difficulty in visualizing thin alveolar cortical plates in the region where the roots were in contact with the maxillary sinus. For future studies, it is recommended that the evaluation of MPR images should be standardized; however, still images should not be used, as CBCT requires a dynamic assessment, comprising all cuts.

Mucosal thickening and mucous retention cysts were grouped as diseased sinuses. The sinus mucosa is considered as thickened when the membrane is 2–6 mm thick. The etiological factors are related to some type of irritation, such as odontogenic cysts or allergy.^{19,26–31} Light mucosal thickening of the maxillary sinus is a normal finding in asymptomatic patients,³² but a thickening greater than 2 mm can be associated with maxillary sinusitis.³³ Using previous studies as reference, mucosae at least 3 mm thick were considered as thickened in the present study.^{26,34} Mucous retention cysts are bodies that develop as a result of a blockage of the sinus ostium and usually resolve spontaneously. They are common findings in CBCT images, but cannot be detected without proper training in dental radiology.³⁵ Although they are usually present in asymptomatic patients, it is important to disclose them in CBCT image reports.

The topographic relationship between tooth roots and the maxillary sinus has been studied in the literature. In one study,⁴ the authors reported that two of the 38 study subjects (5%) had roots that protruded into the sinus cavity. A similar rate (10%) was observed in another study.⁶ Therefore, the incidence of tooth roots in the maxillary sinus in the present study is in agreement with the literature.^{4,6} Oral surgeons should be aware of the amount of bone around the maxillary sinus, so that the necessary precautions can be taken to avoid perforation of the sinus membrane and

introduction of foreign bodies into the maxillary sinus during dental treatments.^{3,36}

The literature has shown that, due to the close relationship between the teeth and the floor of the maxillary sinus, dental infections can extend to the maxillary sinus.²⁴ Direct contact between periodontal tissues and sinus mucosa can occur because of the proximity of the maxillary sinus and the upper posterior teeth implanted in the alveolar process.

Maxillary sinus infections and mucosal thickening have been identified in 2% of patients with dentulous superior maxillas.¹⁸ However, these authors did not find mucous retention cysts in edentulous patients, which may suggest an odontogenic etiology for this condition. In another study,³⁷ 75% of cases with maxillary sinusitis were associated with dental conditions. Other studies have shown that periapical lesions^{19,38} and periodontal disease^{12,19,23,24,39} are associated with sinus pathologies. It has been demonstrated that, in cases of apical periodontitis, when the tip of the tooth root was in contact with the floor of the maxillary sinus, the incidence of mucosal thickening was lower than when the tip of the root exceeded the floor of the maxillary sinus.²⁵

Of all the groups of teeth, the tomographic distance between the upper second molar root apex and the maxillary sinus floor is reported to be the smallest among all maxillary posterior teeth.^{4,40} In line with these reports, in the present study the group of teeth with the most dental roots within diseased sinus was the second molar. Likewise, the first molar had more roots inside normal maxillary sinuses, although this number was quite close to that of the second molar.

Among the limitations of this study, the lack of clinical data on patients evaluated by CBCT is noteworthy. It is also important to highlight that we did not analyze the histological samples that more accurately determine the different pathological changes in the maxillary sinus tissue. The dental radiologists who evaluated the CBCT images were free to adjust the software, so there was little standardization in the assessment of the images.

Conclusions

In the studied sample, tooth roots within the maxillary sinus were almost twice as likely to be associated with pathological maxillary sinuses than normal maxillary sinuses.

Conflicts of interest

The authors declare no conflicts of interest.

References

1. Waite DE. Maxillary sinus. *Dent Clin North Am.* 1971;15:349–68.
2. McGowan DA, Baxter PW, James J. *The maxillary sinus and its dental implications.* 1st ed. London: Wright; 1993. p. 1–25.
3. Wehrbein H, Diedrich P. The initial morphological state in the basally pneumatized maxillary sinus – a radiological-histological study in man. *Fortschr Kieferorthop.* 1992;53:254–62.
4. Eberhardt JA, Torabinejad M, Christiansen EL. A computed tomographic study of the distances between the maxillary sinus

- floor and the apices of the maxillary posterior teeth. *Oral Surg Oral Med Oral Pathol.* 1992;73:345–6.
5. Sharan A, Madjar D, Hashomer T. Correlation between maxillary sinus floor topography and related root position of posterior teeth using panoramic and cross-sectional computed tomography imaging. *Oral Surg Oral Med Oral Pathol Oral Radiol Endod.* 2006;102:375–81.
 6. Kilic C, Kamburoglu K, Pehlivan S, Ozen T. An assessment of the relationship between the maxillary sinus floor and the maxillary posterior teeth root tips using dental cone-beam computerized tomography. *Eur J Dent.* 2010;4:462–7.
 7. Selden H. Endo-Antral syndrome and various endodontic complications. *J Endod.* 1999;25:389–93.
 8. Hauman CH, Chandler NP, Tong DC. Endodontic implications of the maxillary sinus: a review. *Int Endod J.* 2002;35:127–41.
 9. Howe R. First molar radicular bone near the maxillary sinus: a comparison of CBCT analysis and gross anatomic dissection for small bony measurement. *Oral Surg Oral Med Oral Pathol Oral Radiol Endod.* 2009;108:264–9.
 10. Nair UP, Nair MK. Maxillary sinusitis of odontogenic origin: cone-beam volumetric computerized tomography-aided diagnosis. *Oral Surg Oral Med Oral Pathol Oral Radiol Endod.* 2010;110:e53–7.
 11. Lofthag-Hansen S, Huuonen S, Grondahl K, Grondahl HG. Limited cone-beam CT and intraoral radiography for the diagnosis of periapical pathology. *Oral Surg Oral Med Oral Pathol Oral Radiol Endod.* 2007;103:114–9.
 12. Brüllmann DD, Schmidtman I, Hornstein S, Schulze RK. Correlation of cone beam computed tomography (CBCT) findings in the maxillary sinus with dental diagnoses: a retrospective cross-sectional study. *Clin Oral Investig.* 2012;16:1023–9.
 13. Melen I, Lindahl L, Andreasson L, Rundcrantz H. Chronic maxillary sinusitis. Definition, diagnosis and relation to dental infections and nasal polyposis. *Acta Otolaryngol.* 1986;101:320–7.
 14. Abrahams JJ, Glassberg RM. Dental disease: a frequently unrecognized cause of maxillary sinus abnormalities. *AJR Am J Roentgenol.* 1996;166:1219–23.
 15. Doud-Galli SK, Lebowitz RA, Giacchi RJ. Chronic sinusitis complicating sinus lift surgery. *Am J Rhinol.* 2001;15:181–6.
 16. Engström H, Chamberlain D, Kiger R, Egelberg J. Radiographic evaluation of the effect of initial periodontal therapy on thickness of the maxillary sinus mucosa. *J Periodontol.* 1988;59:604–8.
 17. Bhattacharyya N. Do maxillary sinus retention cysts reflect obstructive sinus phenomena. *Arch Otolaryngol Head Neck Surg.* 2000;126:1369–71.
 18. Mathew AL, Pai KM, Sholapurkar A. Maxillary sinus findings in the elderly: a panoramic radiographic study. *J Contemp Dent Pract.* 2009;10:E041–48.
 19. Vallo J, Suominen-Taipale L, Huuonen S, Soikkonen K, Norblad A. Prevalence of mucosal abnormalities of the maxillary sinus and their relationship to dental disease in panoramic radiography: results from the Health 2000 Health Examination Survey. *Oral Surg Oral Med Oral Pathol Oral Radiol Endod.* 2010;109:e80–7.
 20. Ritter L, Lutz J, Neugebauer J. Prevalence of pathologic findings in the maxillary sinus in cone-beam computerized tomography. *Oral Surg Oral Med Oral Pathol Oral Radiol Endod.* 2011;111:634–40.
 21. Freisfeld M, Drescher D, Schellmann B, Schüller H. The maxillary sixth-year molar and its relation to the maxillary sinus. A comparative study between the panoramic tomogram and the computed tomogram. *Fortschr Kieferorthop.* 1993;54:179–86.
 22. Low KM, Dula K, Bürgin W, Von Arx T. Comparison of periapical radiography and limited cone-beam tomography in posterior maxillary teeth referred for apical surgery. *Oral Surg Oral Med Oral Pathol Oral Radiol Endod.* 2007;103:114–9.
 23. Phothikhun S, Suphanantachat S, Chuenchompoonut V, Nisapakultorn K. Cone-beam computed tomographic evidence of the association between periodontal bone loss and mucosal thickening of the maxillary sinus. *J Periodontol.* 2012;83:557–64.
 24. Arijji Y, Obayashi N, Goto M, Izumi M, Naitoh M, Kurita K, et al. Roots of the maxillary first and second molars in horizontal relation to alveolar cortical plates and maxillary sinus: computed tomography assessment for infection spread. *Clin Oral Investig.* 2006;10:35–41.
 25. Lu Y, Liu Z, Zhang L, Zhou X, Zheng Q, Duan X, et al. Associations between maxillary sinus mucosal thickening and apical periodontitis using cone-beam computed tomography scanning: a retrospective study. *J Endod.* 2012;38:1069–74.
 26. Gordts F, Clement PAR, Destryker B, Desprechins B, Kaufman L. Prevalence of sinusitis signs on MRI in a non-ENT paediatric population. *Rhinology.* 1997;35:154–7.
 27. Lim WK, Ram B, Fasulakis S, Kane KJ. Incidental magnetic resonance image sinus abnormalities in asymptomatic Australian children. *J Laryngol Otol.* 2003;117:969–72.
 28. Mehra P, Murad H. Maxillary sinus disease of odontogenic origin. *Otolaryngol Clin North Am.* 2004;37:347–64.
 29. Obayashi N, Arijji Y, Goto M, Izumi M, Naitoh M, Kurita K, et al. Spread of odontogenic infection originating in the maxillary teeth: computerized tomographic assessment. *Oral Surg Oral Med Oral Pathol Oral Radiol Endod.* 2004;98:223–31.
 30. Madani G, Beale TJ. Differential diagnosis in sinonasal disease. *Semin Ultrasound CT MRI.* 2009;30:39–45.
 31. Carmeli G, Artzi Z, Kozlovsky A, Segev Y, Landsberg R. Antral computerized tomography pre-operative evaluation: relationship between mucosal thickening and maxillary sinus function. *Clin Oral Implants Res.* 2011;22:78–82.
 32. Savolainen S, Eskelin M, Jousimies-Somer H, Ylikoski J. Radiological findings in the maxillary sinuses of symptomless young men. *Acta Otolaryngol Suppl.* 1997;529:153–7.
 33. Rak KM, Newell JD 2nd, Yakes WF, Damiano MA, Luethke JM. Paranasal sinuses on MR images of the brain: significance of mucosal thickening. *AJR Am J Roentgenol.* 1991;156:381–4.
 34. Rege IC, Sousa TO, Leles CR, Mendonça EF. Occurrence of maxillary sinus abnormalities detected by cone beam CT in asymptomatic patients. *BMC Oral Health.* 2012;10:12–30.
 35. Ahmed F, Brooks SL, Kapila SD. Efficacy of identifying maxillofacial lesions in cone-beam computed tomographs by orthodontists and orthodontic residents with third-party software. *Am J Orthod Dentofacial Orthop.* 2012;141:451–9.
 36. Khongkhunthian P, Reichart PA. Aspergillosis of the maxillary sinus as a complication of overfilling root canal material into the sinus: report of two cases. *J Endod.* 2001;27:476–8.
 37. Maillet M, Bowles WR, McClanahan SL, John MT, Ahmad M. Cone-beam computed tomography evaluation of maxillary sinusitis. *J Endod.* 2011;37:753–7.
 38. Nenzén B, Welander U. The effect of conservative root canal therapy on local mucosal hyperplasia in the maxillary sinus. *Odontol Revy.* 1967;18:295–302.
 39. Casamassimo PS, Lilly GE. Mucosal cysts of the maxillary sinus: a clinical and radiographic study. *Oral Surg Oral Med Oral Pathol.* 1980;50:282–6.
 40. Nogi T, Kanazawa E. Morphometry of the maxillary sinus and the relationship between the sinus base and the tooth roots. *J Oral Sci.* 2001;27:227–34.