



CASE REPORT

Solitary circumscribed neuroma of the larynx[☆]



Neuroma circunscrito solitário de laringe

Conceição Peixoto^{a,*}, Hugo Guimarães^a, Francisco Oliveira^a,
Eduardo Atraca^a, Margarida Teixeira^b, Ana Paula Ribeiro^a

^a Service of Otorhinolaryngology, Centro Hospitalar do Médio Ave, E.P.E., Santo Tirso, Portugal

^b Pathological Anatomy, Hospital de Braga, Braga, Portugal

Received 12 March 2015; accepted 16 April 2015

Available online 1 October 2015

Introduction

Benign tumors of the larynx are uncommon compared to their malignant counterparts. Even less common are neoplasms of nervous origin, such as schwannomas and neurofibromas. This neurogenous group also contains less frequent varieties, including the palisaded encapsulated neuroma (or solitary circumscribed neuroma).^{1,2}

In general, palisaded encapsulated neuromas account for approximately 25% of all tumors of peripheral nerve sheath origin. Solitary circumscribed neuroma is defined as a neof ormation that originates from a nerve fiber, with varying amounts of all normal components of the peripheral nerve.^{3,4}

It is considered an uncommon tumor that affects middle-aged adults, between the third and fifth decades of life, affecting both genders equally. Ninety percent of cases are located on the face, particularly the nose and cheeks. Less than 10% affect other sites, such as the trunk and the upper limbs. Rarer still are other locations, including mucosal

sites, such as the oral mucosa, eyelids, and genitals.⁵⁻⁷ The authors report a clinical case of this pathology in an anomalous location.

Case report

A 63-year-old female patient was referred for an otorhinolaryngology consultation in May 2014 due to a complaint of pharyngeal foreign body sensation for nearly one year. She denied dysphonia, dysphagia, or dyspnea. The clinical evaluation showed normal otoscopy and oroscopy; the nasoscopy disclosed hypertrophic rhinitis, although with a reasonable nasal patency.

Upon indirect laryngoscopy with a 70° rigid laryngoscope, the patient had a large, pedunculated, 'cystic' round lesion, adjacent to the posterior commissure to the right. Vocal cords exhibited normal mobility and there were no other apparent lesions.

In July 2014, she was submitted to suspension microlaryngoscopy with complete excision of the lesion. The excised lesion was rounded, white, and showed a firm consistency, and was attached adjacent to the pharyngeal surface of the right arytenoid.

The anatomopathological analysis revealed a well-defined neoplasm, consisting of proliferation of spindle cells arranged in short fascicles, whose cells had undulated nuclei without atypia. No mitotic figures were identified.

[☆] Please cite this article as: Peixoto C, Guimarães H, Oliveira F, Atraca E, Teixeira M, Ribeiro AP. Solitary circumscribed neuroma of the larynx. Braz J Otorhinolaryngol. 2016;82:368–70.

* Corresponding author.

E-mail: saopeixoto@gmail.com (C. Peixoto).

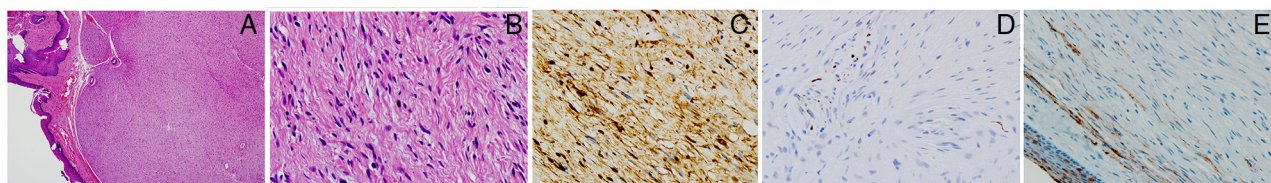


Figure 1 Neoplasia with well-defined limits, consisting of spindle cells arranged in fascicles with undulated nuclei without atypia (A and B). Immunocytochemical analysis: C, S-100 protein (PS-100) – diffusely positive spindle cells; D, neurofilaments (NFs) – positive intratumoral axons for NFs; E, EMA – partially encapsulated neoplasia. Capsule positive for epithelial membrane antigen (EMA).

The immunohistochemical analysis showed diffuse positivity for PS100, a characteristic consistent with solitary circumscribed neuroma (Fig. 1).

The patient had no signs of any associated systemic disease. To date, she has had no evidence of recurrence, after eight months of postoperative follow-up.

Discussion

Among the benign neoplasms of the larynx, there is a relatively rare category that encompasses neoplasms of neural origin. This group includes tumors of peripheral nerve sheath, a relatively rare group of diseases classified according to the specific characteristics of differentiation of their cellular and extracellular matrix components.

The World Health Organization classifies these diseases as: traumatic neuroma, neurofibroma, schwannoma, palisaded encapsulated neuroma (or solitary circumscribed neuroma), granular cell tumor, nerve sheath myxoma (neurothekeoma), and perineurioma, in addition to peripheral nerve sheath malignant tumor.⁸ These are basically constituted by any of the three types of cells that form the peripheral nerve sheath, including Schwann cells, fibroblasts, and perineural cells, with or without axons. Schwann cells are primarily responsible for three different types of tumors: neuromas, schwannomas, and neurofibromas, which differ from each other by the morphological pattern and proportions of their several cell constituents.^{1-3,8}

The palisaded encapsulated neuroma (or solitary circumscribed neuroma) is defined as a new formation that originates from a nerve fiber, with varying amounts of all normal components of the peripheral nerve.

It was identified as an entity in 1972 by Reed, but only in 1994 did Megahed describe its immunohistochemical characteristics.^{9,10}

It is considered an uncommon tumor that affects middle-aged adults, between the 3rd and 5th decades of life, affecting both genders equally. Ninety percent of cases are located in the skin of the face and mucosal sites are rare.⁵⁻⁷

Of the 48 articles found during the search performed in MEDLINE related to "neuroma circunscrito solitário/solitary circumscribed neuroma" and "neuroma capsulado em paliçada/palisaded encapsulated neuroma", the literature described no cases at the level of the larynx. Considering the reviewed studies, the majority referred to skin lesions, although there are some reviews of oral mucosa or ophthalmic eyelid lesions. No apparent etiological factor was described.

As with other neural lesions, their association to syndromes of considerable clinical relevance has been identified, such as neurofibromatosis and multiple endocrine neoplasia, although a clear association has not been identified.⁶

Histologically, the solitary circumscribed neuroma is a well-circumscribed, partially or completely encapsulated neof ormation, consisting of one or more lobes. The capsule consists of a thin layer of elongated and parallel cells, interspersed with collagen fibers and, at times, an association with a peripheral nerve can be observed. The neof ormation consists of interspersed fascicles of spindle cells that correspond to Schwann cells separated by artificial crevices. Cross-sections and special stains show a moderate number of short and irregular axonal fragments. It also demonstrates the presence of fragmented or degenerated myelin sheaths. Masson staining discloses collagen bundles in a tumor stroma. Histopathological differential diagnosis is traumatic neuroma, neurofibroma, neurilemmoma, and leiomyoma. In the immunohistochemical analysis, the tumor cells are strongly positive for S-100 protein.²⁻⁵

S-100 protein is a widely used immunohistochemical marker to identify tumors of neural origin. In normal tissues, it is expressed by glial cells, neurons, Schwann cells, melanocytes, and Langerhans cells. The vast majority of benign tumors of the peripheral nerve sheath show positive immunohistochemical labeling for S-100 protein.^{2-5,10}

The capsule is negative for S-100, but strongly positive for epithelial membrane antigen (EMA).^{4,10}

Treatment consists of surgical excision, and even when exision is incomplete, it evolves without recurrence.^{2,3}

Conclusion

Solitary circumscribed neuroma or palisaded encapsulated neuroma is a typically benign skin lesion, but can also occur, albeit rarely, at the mucosal level. The clinical characteristics are not specific and the definitive diagnosis of solitary circumscribed neuroma is attained through histopathological analysis.

The interest of this report is based on the rarity of the solitary circumscribed neuroma. To the best of authors' knowledge, clinically, this case represents the only one with a laryngeal location to date.

Conflicts of interest

The authors declare no conflicts of interest.

References

1. Weisman RA, Moe KS, Orloff LA. Neoplasms of the larynx and laryngopharynx. In: Snow JB, Ballenger JJ, editors. Ballenger's otorhinolaryngology head and neck surgery. 17th ed. Hamilton, Ontario: BC Decker Inc; 2008. p. 1255–92.
2. Requena L, Sanguenza O. Benign neoplasms with neural differentiation. *Am J Dermatopathol*. 1995;17:75–96.
3. Breathnach S, Burns T, Cox N. Rook's textbook of dermatology. Oxford, UK: Blackwell Publishing, Ltd; 2004.
4. Cribier B, Grosshans E. Tumeurs cutanées nerveuses rares. *Ann Dermatol Venerol*. 1997;124:280–95.
5. Dover J, From L, Lewis A. Palisaded encapsulated neuromas. *Arch Dermatol*. 1989;125:386–9.
6. Lombardi T, Samson J, Kuffer R. Neurome circonscrit solitaire (neuroma palissadique encapsulé) de la muqueuse buccale. *Ann Dermatol Venerol*. 2002;129:229–32.
7. Navarro M, Dilata J, Requena C. Palisaded encapsulated neuroma (solitary circumscribed neuroma) of the penis glans. *Br J Dermatol*. 2000;142:1047–70.
8. Fuller GN, Scheithauer BW. The 2007 Revised World Health Organization (WHO) Classification of tumours of the central nervous system: newly codified entities. *Brain Pathol*. 2007;17:304–7.
9. Reed R, Meltzer H. Palisaded encapsulated neuromas of the skin. *Arch Dermatol*. 1972;106:865–70.
10. Megahed M. Palisaded encapsulated neuroma (solitary circumscribed neuroma). *Am J Dermatopathol*. 1994;16:120–5.