





A hospital-based observational study on clinical and radiographic findings in COVID-19 associated rhinomaxillary mucormycosis: revealing the Pandora box

Sulem Ansari^{1*} , Shivayogi Charantimath² , Vasanti Lagali Jirge² , Vaishali Keluskar² 

¹KAHER's KLE VK Institute of Dental Sciences, JNMC Campus, Belagavi - 590010, India.

²Department of Oral Medicine and Radiology, KLE VK Institute of Dental Sciences, Belagavi - 590010, India.

Corresponding author:

Dr. Sulem Ansari
3rd-year post-graduate department of oral medicine and radiology
KAHER's KLE VK Institute of dental sciences, JNMC Campus
Belagavi-590010, India
Email: ansarisulem@gmail.com
Phone no: 9773723359

Editor: Altair A. Del Bel Cury

Received: Apr 02, 2022

Accepted: Oct 07, 2022



Mucormycosis is a rare, rapidly spreading, fulminant, opportunistic infection that is caused by a group of filamentous molds. During the second wave of COVID-19 India reported most of the cases of mucormycosis which is termed as COVID-19-associated mucormycosis (CAM).

Aim: The purpose of this study is to describe and understand the clinical and radiographic findings related to COVID-19 associated rhinomaxillary mucormycosis. **Methods:** In this observational study 76 individuals with proven rhinomaxillary mucormycosis were included. The demographic profile, predisposing factors, anatomic structures involved, oral manifestations, radiographic findings management, and 90-day mortality were recorded and analyzed. **Results:** Among 76 individuals with COVID-19-associated rhinomaxillary mucormycosis diabetes mellitus was present in 93.42% of cases. Almost all patients received corticosteroids during COVID-19 treatment. The maxilla was most commonly involved in around 98.6% of cases. Interestingly 1 case involving the mandible was noted and the maxillary sinus was the most commonly involved. Mortality occurred in 1.31% (n=1) of cases. **Conclusion:** Diabetes was the most common predisposing factor. Administration of corticosteroids was evident. A considerable number of patients developed diabetes during the treatment of COVID-19. Early signs and oral manifestations of rhinomaxillary mucormycosis play a pivotal role in the early diagnosis and prompt treatment to reduce mortality and morbidity in COVID-19 associated-rhinomaxillary mucormycosis patients.

Keywords: Mucormycosis. COVID-19.

Introduction

Although the primary pathology of COVID-19 is pneumonia and respiratory failure, secondary infections are common and attribute significantly to morbidity and mortality¹. Fungal infections are least common than bacterial infections, nevertheless are usually more invasive and fatal². Mucormycosis is a fungal infection caused by fungi known as Mucorales. It is highly aggressive with a tendency for widespread infection. This infection occurs by inhalation of spores. The fungal spores adhere to the respiratory epithelium and transform into hyphae causing angioinvasion, leading to endothelial injury, thrombosis, and necrosis. The fungus can then spread to various organs rapidly to cause disseminated mucormycosis. If the diagnosis and management are delayed, the prognosis is poor¹.

Several factors increase the risk of invasive fungal infections and mucormycosis in patients with COVID-19. The most important predisposing factor is hyperglycemia which may decrease the ability of the body to fight infections³. Prolonged use of a high dose of corticosteroids and drugs like tocilizumab used in moderate and severe disease may also increase predisposition for fungal infections⁴. Severe COVID-19 disease is associated with the cytokine storm, and it is associated with producing insulin resistance and hyperglycemia and the use of steroids aggravates it, as corticosteroids have hyperglycemic action thus providing the milieu for seeding by mucor. This cytokine storm triggers a hyperinflammatory and hypercoagulatory response, which disrupts endothelial cell integrity thus causing organ damage such as lung injury and pancreatic injury⁵. The SARS-CoV-2 confers pancreatic islet injury and acute diabetes onset by binding to the ACE2 receptor, one more assumed factor for increased risk of mucormycosis in COVID-19 is intracellular iron overload signified by increased ferritin levels, which leads to the formation of reactive oxygen species⁶. Widespread endothelial injury in patients with severe disease can upregulate endothelial receptor glucose-regulated protein (GRP 78), which is responsible for increased adhesion and penetration of Mucorales to the endothelium⁷. The treatment modalities available for the treatment of mucormycosis are aggressive debridement of infected hard and soft tissue and parenteral antifungal therapy such as Liposomal Amphotericin B, lipid Amphotericin B, Posaconazole, and itraconazole. Functional endoscopic sinus surgery (FESS) is an endoscopic surgical debridement of the paranasal sinuses used in the cases of rhinomaxillary mucormycosis⁸.

The commonest reported form of mucormycosis in literature is rhinomaxillary mucormycosis⁹. There are other recently published reports as well as case series that reported similar findings^{10,11}. This study aims to describe and understand the clinical and radiographic findings related to COVID-19-associated rhinomaxillary mucormycosis.

This study aimed to describe the predisposing factors, gender predilection, age, clinical signs and symptoms, oral manifestations, anatomical structures involved, treatment received and mortality related to COVID-19-associated rhinomaxillary mucormycosis in patients who reported to the Dept of Oral Medicine and Radiology with dental complaints.

Materials and methods

This observational hospital-based study was conducted in a dental hospital-based setting. The study sample consisted of confirmed cases of rhinomaxillary mucormycosis with a previous history of COVID-19 who reported during the 2nd wave of COVID-19 from March 2021 to December 2021 in India. Confirmation of diagnosis was based on clinical and radiological features in the paranasal sinus view, computed tomography (PNS CT), and demonstration of *Mucor* on potassium hydroxide (KOH) staining or histopathological examination using periodic acid-Schiff stain (PAS) (Figure 1) and Grocott's Methenamine Silver Stain (GMS) (Figure 2). Patients with fungal culture positive for Mucorales were included in the study.

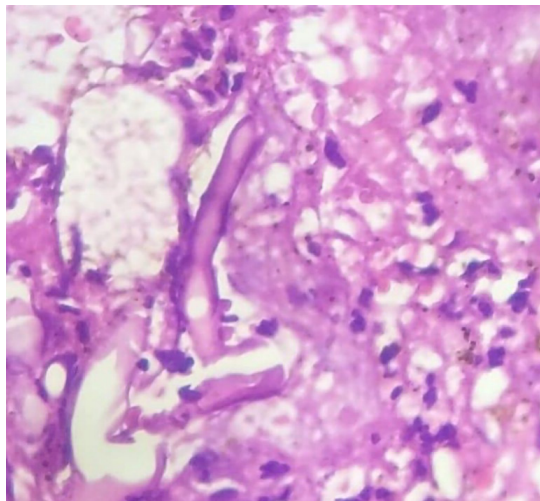


Figure 1. Histopathological section showing non-septate fungal hyphae on periodic acid-Schiff stain

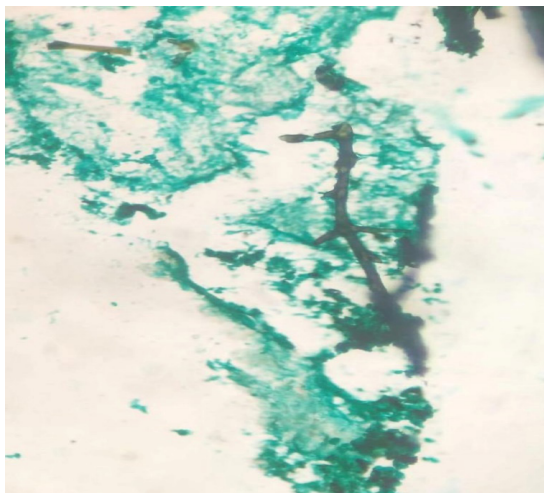


Figure 2. Histopathological section showing septate fungal hyphae on Grocott's Methenamine Silver Stain (GMS)

A total of 76 patients were included in the study. Patients who had rhinomaxillary mucormycosis with negative history of COVID-19 were excluded from this study. Clinical data was retrieved from the clinical records. These included demographic data like age and gender. Details of COVID-19 infection were noted which included duration of hospitalization and intensive care unit (ICU) stay, the need of a ventilator, and use of corticosteroids and other medicines. History of co-morbidities like diabetes, coronary heart disease, kidney disease, cancer, organ transplant, chronic lung diseases, etc. was recorded. Finally, the clinical details of mucormycosis were extracted including the oral manifestations, anatomical structure involved, sinus involvement, treatment provided, and outcome. All data were entered in a central Google spreadsheet and the patient information was de-identified. The data was checked by two investigators.

Results

A total of 76 patients with COVID-19-associated "rhinomaxillary mucormycosis" were included in this study. The mean age of occurrence was 52 years with 72 males (94.73%) and 4 females (5.26 %) given in table-1. Diabetes mellitus (DM) type-II was found in 93.42% (n=71) of the patients. The previous history of DM type-II was noted in 46.47 % (n=33) of patients, and 53.52% (n=38) developed DM type-II during COVID-19 treatment. The list of co-morbidities is given in table 1. History of hospitalization was present in 71 patients (93.42%). Intensive care (ICU) was needed in 22 patients (28.94%). All patients had received systemic corticosteroids. Supplemental oxygen was required in 72.36 % (n=55) of cases. Various antifungal drugs used such as liposomal Amphotericin B were received by 34% (44.73%), although due to acute shortage of the drug 37 (48.68%) patients received lipid Amphotericin B parenterally during hospitalization, non-hospitalized individuals received oral isavuconazole (2.63%) and posaconazole (3.94%) [Table 1]

Table 1. Age and gender correlation, predisposing factors and COVID-19 treatment related parameters in COVID-19 associated rhinomaxillary mucormycosis

Parameters	No. of Patients (n)	Range
Age	76	32-75 years Mean age- 52 years
Sex	76	Males-94.73% (n=72), Females-5.26 % (n=4) M: F ratio – 16:1
Predisposing factors	No. of Patients (n)	Percentage (%)
1) Diabetes mellitus type-II	71	93.42%
a) Previous history of diabetes	33	46.47 %
b) Developed diabetes type-II during COVID 19 treatment	38	53.52%
2) Renal disease	2	2.63 %
3) Myocardial infarction	1	1.31 %
Parameters	No. of Patients (n)	Percentage (%)
Hospitalization	71	93.42%

Continue

Continuation		
Stay in Intensive care unit (ICU)	22	28.94%
Oxygen support	40	56.33%
Systemic corticosteroids	76	100%
Oral	5	6.58 %
IV	71	93.42 %
Antifungal agents		
i) Liposomal Amphotericin B (IV)	34	44.73%
ii) Lipid Amphotericin B (IV)	37	48.68%
iii) Isavuconazole (Oral)	2	2.63%
iv) Posaconazole (Oral)	3	3.94%

The maxilla was the most commonly involved anatomic structure in 98.6% (n=75) of the cases, although 1 case of mucormycosis involving the mandible was noted. The right maxilla 64% (n=48) was more commonly involved than the left maxilla 36% (n=27). The most common oral manifestation was a periodontal abscess (Figure 3) with mobility seen in 50% (n=38) of patients, followed by necrotic bone (Figure 4) with pus discharge in 42.1% (n=32) of patients [Table 2]. In radiographic findings, right maxillary sinus 36% (n=27) was more commonly involved than the left side 26.6% (n=20), although in advanced cases a bilateral sinus involvement was observed in 37.3% (n=28). Other paranasal sinuses were involved in clinically advanced disease. Orbit involvement and other structures of the skull were involved in severe cases. None of the patients showed evidence of brain involvement. [Table 3].

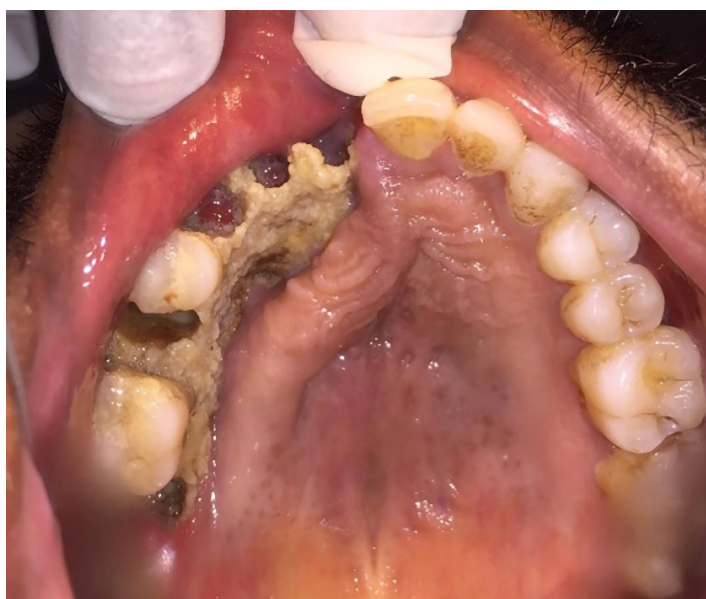

Figure 3. Necrotic bone involving the right maxilla in a patient with rhinomaxillary mucormycosis

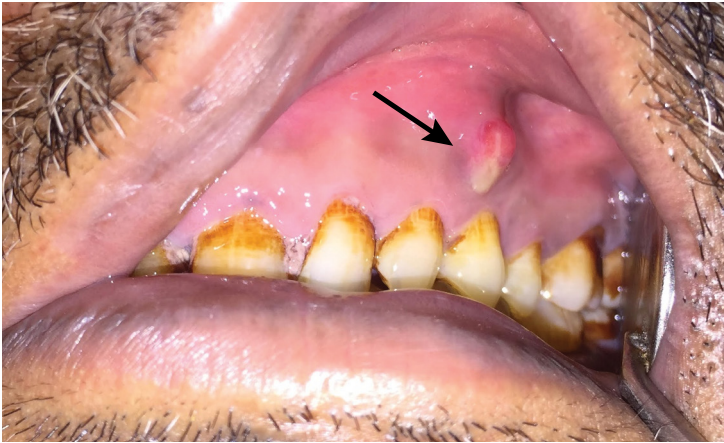


Figure 4. Periodontal abscess i.r.t left maxillary premolar in a patient with rhinomaxillary mucormycosis

Table 2. Oral manifestations and anatomic structures involvement in COVID-19 associated rhinomaxillary mucormycosis

Parameters	No. of individuals (n)	Percentage (%)
Maxilla involvement	75	98.6%
Mandible involvement	1	1.31%
Oral manifestations		
i) Necrotic bone with pus discharge	32	42.1%
ii) Single/ Multiple periodontal abscess with mobility	38	50%
iii) Extra-oral swelling with necrotic bone	6	7.89 %

Table 3. Radiographic findings of Rhinomaxillary mucormycosis in COVID-19 associated rhinomaxillary mucormycosis

Parameters	No. of individuals (n)	Percentage (%)
Paranasal sinus involvement	75	98.6%
i) Maxillary sinus	75	98.6%
a) Right	27	36%
b) Left	20	26.6%
c) Bilateral involvement	28	37.3%
ii) Ethmoid sinus	18	24%
a) Right	8	44.4%
b) Left	7	38.8
c) Bilateral involvement	3	16.6%
iii) Orbital involvement		
a) Medial wall	2	2.6%
b) Lateral wall	2	2.6%
c) Intra-orbital extension	3	3.9%

Continue

Continuation		
Other structures		
Pterygopalatine fossa	3	3.9%
Infra-temporal fossa	2	2.6%
Sphenopalatine foramen	1	1.3%
Ethmoid air cells	2	2.6%
Nasal cavity	20	26.3%
Sphenoid bone	2	2.6%
Zygoma	1	1.3%

Functional endoscopic sinus surgery (FESS) under general anesthesia (GA) was done in 96.68 % (n = 75) of patients. Orbital decompression was done in 3.94 % (n = 3) of patients. Depending upon the bone involvement various surgical procedures were performed as given in table-4. Mortality occurred in 1.31% (n=1) of the patient, it was due to a delay in the treatment due to underlying cardiac disease. [Table 4]

Table 4. Treatment provided and mortality associated with in COVID-19 associated rhinomaxillary mucormycosis

Parameters	No. of individuals (n)	Percentage (%)
Treatment provided	76	100%
i) FESS	75	96.6%
ii) Micro-debridement of orbit	4	5.26 %
iii) Orbital decompression	3	3.94 %
iv) Partial maxillectomy	28	39.47 %
v) Alveolectomy	46	60.52 %
vi) Subtotal maxillectomy	1	1.31%
vii) Debridement	1	1.31%
Mortality associated	1	1.31%

Discussion

Mucormycosis was one of the comorbidities associated with COVID 19. In this observational study majority of patients had diabetes. COVID-19-associated rhinomaxillary mucormycosis was more prevalent in males (94.73%) than females (5.26%) and M: F ratio was 16:1. The age range was between 32-75 years with a mean age of 52 years.

The majority of patients had diabetes mellitus in this observational study; a study conducted by Gupta et al 2021 reported the presence of diabetes in the majority of patients¹². Prominently, the majority of the reported mucormycosis cases during the COVID-19 pandemic were from India. A systematic review of 101 cases of CAM

globally published in July 2021 revealed diabetes in 80% of patients and steroid use in 76% of patients¹³. A retrospective countrywide study revealed that diabetes mellitus is predominant in 79% and steroid use in 87% of patients with rhino-orbito-cerebral mucormycosis associated with COVID-19¹¹. In an updated systematic review comprised of 233 patients from India and 42 from the rest of the world, diabetes was identified as the most common primary risk factor for CAM in India than in other countries. A study from Egypt in 21 patients with CAM also found a high prevalence of diabetes (90%)¹⁴.

In our study, all patients received systemic corticosteroids during the treatment of COVID-19. The interesting fact here is although the prevalence of diabetes was similar in most studies, the use of corticosteroids is less in some studies (85% in a recent systemic review)¹⁵. Another notable finding was that, 53.52% developed diabetes mellitus during the COVID-19 treatment, new onset of diabetes was reported in association with COVID-19¹⁶. The nasal mucociliary clearance is the primary distinctive defense mechanism of the paranasal sinus against various antigens. This mechanism guards the upper respiratory system against numerous inhaled particles and microorganisms. However, it becomes one of the critical factors for the growth of fungus together with the inflammation of the upper airway, in patients requiring prolonged hospital stay with supplemental oxygen therapy¹⁷, Mild thrombocytopenia has been detected in 58–95% of patients with SARS-CoV-2 infection. Platelets possibly hamper the growth of fungi are (i) directly by adhering to Mucorales hyphae to form a thrombus. (ii) Indirectly, platelets secrete pro-inflammatory and anti-inflammatory cytokines such as TGF- β and Thrombocidins which may act against Mucorales¹⁸. Corticosteroids used for suppression of inflammatory mediators and cytokines in severe COVID-19 cause suppression of lymphocytes and also cause hyperglycemia by promoting gluconeogenesis and inhibiting glycolysis thus there is an increased incidence of mucormycosis in patients with a history of corticosteroid use¹⁹.

The maxilla (98.6%) was the most commonly involved jaw bone in our study. Interestingly 1 case involving the mandible was seen, although in bacterial osteomyelitis, the mandible is most common than the maxilla²⁰. The most common oral manifestations were multiple periodontal abscesses with mobility (50%) and necrotic bone with pus discharge (42.1%) followed by extra-oral swelling with necrotic bone (7.89 %). Bacterial osteomyelitis is associated with the symptoms of localized intense pain, fever, tenderness, etc.²¹ although in the cases of COVID-19-associated rhinomaxillary mucormycosis no such symptoms were reported by the patients.

On radiographic examination, the maxillary sinus was the most commonly involved. Bilateral maxillary sinus involvement (37.3%) was most commonly seen followed by right maxillary sinus involvement (36%). Ethmoidal sinus was the second most involved paranasal sinus. Orbital involvement was found in advanced cases of rhinomaxillary mucormycosis. Other vital structures such as infratemporal fossa, pterygopalatine fossa, sphenopalatine foramen, ethmoid air cells, sphenoid bone, and zygoma were seen in clinically advanced cases. This is the first study reporting oral manifestations and radiographic findings of COVID-19-associated rhinomaxillary mucormycosis. Functional endoscopic sinus surgery under

general anesthesia (FESS) was employed in the majority of patients reported with sinus involvement. Depending upon the area of bone involvement resection of jaw bone was done. Due to resection of the bone, there was loss of a masticatory function. The mortality rate observed was 1.31 %, possibly due to early diagnosis and aggressive treatment. Another interesting fact is that the fatality rate of cases reported from India (36.5%) is less than the globally reported cases (61.9%) this might be due to the predominance of rhinomaxillary mucormycosis type of mucormycosis¹⁸. The aggressive nature of *Mucor* species and mucormycosis warrants attention. Dentists should be able to identify the early signs of mucormycosis so that early treatment is instituted thereby reducing morbidity and mortality. Delay in the diagnosis of rhinomaxillary mucormycosis has led to many patients becoming severely disfigured^{19,22}. The increase in mucormycosis cases in the Indian context appears to be due to diabetes (high prevalence genetically). Rampant use of corticosteroids in COVID-19 was reported in many studies. Corticosteroids lead to an increase in blood glucose and consequently increase the chances of developing opportunistic fungal infection. COVID-19 leads to reduced immune functions due to cytokine storm, lymphopenia, and endothelial damage. The combined damaging effects of corticosteroid therapy and SARS-COV 2 virus seem to have led to a high prevalence of rhinomaxillary mucormycosis²³. All efforts should be made to maintain optimal hyperglycaemia and only judicious evidence-based use of corticosteroids in patients with COVID-19 is recommended to reduce the burden of fatal mucormycosis²³.

Oral manifestations of mucormycosis in COVID-19 patients are frequently seen in the palate and may include varying degrees of mucosal discoloration, swelling, ulcerations, and superficial necrotic areas involving the palate (Figure 1), tooth mobility, multiple periodontal abscess, bone necrosis and exposure with dark eschar formation²⁴. Hence, palatal ulcerations could be the primary presenting symptom, leading the patient to the dentist, who can be the first clinician to recognize an infection leading to the diagnosis of rhinomaxillary mucormycosis²⁵. Therefore, a non-specific palatal ulcer can be considered as the presenting sign of mucormycosis, and a dental practitioner must be alert to initial signs and symptoms of this disease, specifically when evaluating the high-risk patients. Early diagnosis of mucormycosis is critical, as treatment should start as soon as possible in an attempt to decrease mortality²⁶.

The role of dentists is critical because mucormycosis primarily occurs around rhinomaxillary or rhinocerebral areas involving facial tissues, palate, alveolar bone, and mandibular bone. Therefore, dental professionals should be alert of symptoms of mucormycosis. In addition to palatal lesions, atypical symptoms such as sinus pain, facial pain, unanticipated odontalgia of otherwise sound teeth, or patient deterioration after dental therapeutic interventions should alert clinicians to seek confirmation of the diagnosis and promptly start optimal treatment²⁷.

Limitations

We could not assess the prevalence of COVID-19 associated rhinomaxillary mucormycosis as this is a single-center study conducted in a dental OPD in India.

In conclusion, this single-center observational study from India found a higher prevalence of diabetes mellitus and steroid administration in COVID-19-associated rhino-maxillary mucormycosis. Maxillary sinus was most commonly involved in the paranasal sinus. Many patients presented with aggressive periodontal disease. In the era of the COVID -19 pandemic, any patient who presents with aggressive periodontal disease and palatal ulcerations should be investigated for Mucormycosis.

Conflict of interest

Authors declare no conflict of interest. This study is self-funded.

Ethics

Obtained Ethical clearance from the institutional ethical committee.

Ethical clearance no: 1382

Source of funding

Self-funded.

Author contribution

1) Dr. Sulem Ansari - Study design, collection of data, interpretation of CT scans, statistical analysis

2) Dr. Shivayogi Charantimath – Interpretation of CT scans

3) Dr. Vasanti Jirge – Study design, Editing of the manuscript

4) Dr. Vaishali Keluskar – Final editing of the manuscript

All authors have revised and approved the final version of the manuscript.

Data availability

Datasets related to this article will be available upon request to the corresponding author.

References

1. Palanisamy N, Vihari N, Meena DS, Kumar D, Midha N, Tak V, et al. Clinical profile of bloodstream infections in COVID-19 patients: a retrospective cohort study. *BMC Infect Dis.* 2021 Sep;21(1):933. doi: 10.1186/s12879-021-06647-x.
2. Zia M, Goli M. Predisposing factors of important invasive fungal coinfections in COVID-19 patients: a review article. *J Int Med Res.* 2021 Sep;49(9):3000605211043413. doi: 10.1177/03000605211043413.
3. Unnikrishnan R, Misra A. Infections and diabetes: risks and mitigation with reference to India. *Diabetes Metab Syndr.* 2020 Nov-Dec;14(6):1889-94. doi: 10.1016/j.dsx.2020.09.022.
4. Garg D, Muthu V, Sehgal IS, Ramachandran R, Kaur H, Bhalla A, et al. Coronavirus disease (Covid-19) associated mucormycosis (CAM): case report and systematic review of literature. *Mycopathologia.* 2021 May;186(2):289-98. doi: 10.1007/s11046-021-00528-2.

5. Oh H, Ghosh S. NF- κ B: roles and regulation in different CD4(+) T-cell subsets. *Immunol Rev*. 2013 Mar;252(1):41-51. doi: 10.1111/imr.12033.
6. Jose A, Singh S, Roychoudhury A, Kholakiya Y, Arya S, Roychoudhury S. Current understanding in the pathophysiology of SARS-CoV-2-associated rhino-orbito-cerebral mucormycosis: a comprehensive review. *J Maxillofac Oral Surg*. 2021 Sep;20(3):373-80. doi: 10.1007/s12663-021-01604-2.
7. Alqarihi A, Gebremariam T, Gu Y, Swidergall M, Alkhazraji S, Soliman SS, et al. GRP78 and integrins play different roles in host cell invasion during mucormycosis. *mBio*. 2020 Jun;11(3):e01087-20. doi: 10.1128/mBio.01087-20.
8. Rai S, Yadav S, Kumar D, Kumar V, Rattan V. Management of rhinomaxillary mucormycosis with Posaconazole in immunocompetent patients. *J Oral Biol Craniofac Res*. 2016 Nov;6(Suppl 1):S5-S8. doi: 10.1016/j.jobcr.2016.10.005.
9. Dilek A, Ozaras R, Ozkaya S, Sunbul M, Sen EI, Leblebicioglu H. COVID-19-associated mucormycosis: Case report and systematic review. *Travel Med Infect Dis*. 2021 Nov-Dec;44:102148. doi: 10.1016/j.tmaid.2021.102148.
10. Patel A, Agarwal R, Rudramurthy SM, Shevkani M, Xess I, Sharma R, et al. Multicenter epidemiologic study of coronavirus disease-associated mucormycosis, India. *Emerg Infect Dis*. 2021 Sep;27(9):2349-59. doi: 10.3201/eid2709.210934.
11. Sen M, Honavar SG, Bansal R, Sengupta S, Rao R, Kim U, et al. Epidemiology, clinical profile, management, and outcome of COVID-19-associated rhino-orbital-cerebral mucormycosis in 2826 patients in India—Collaborative OPAI-IJO Study on Mucormycosis in COVID-19 (COSMIC), Report 1. *Indian J Ophthalmol*. 2021 Jul;69(7):1670-92. doi: 10.4103/ijo.IJO_1565_21.
12. Patel A, Kaur H, Xess I, Michael JS, Savio J, Rudramurthy S, et al. A multicentre observational study on the epidemiology, risk factors, management and outcomes of mucormycosis in India. *Clin Microbiol Infect*. 2020 Jul;26(7):944.e9-944.e15. doi: 10.1016/j.cmi.2019.11.021.
13. Singh AK, Singh R, Joshi SR, Misra A. Mucormycosis in COVID-19: a systematic review of cases reported worldwide and in India. *Diabetes Metab Syndr*. 2021 Jul-Aug;15(4):102146. doi: 10.1016/j.dsx.2021.05.019.
14. Alfshawy M, Elbendary A, Younes A, Negm A, Hassan WS, Osman SH, et al. Diabetes mellitus and Coronavirus disease (Covid-19) associated mucormycosis (CAM): a wake-up call from Egypt. *Diabetes Metab Syndr*. 2021 Sep-Oct;15(5):102195. doi: 10.1016/j.dsx.2021.102195.
15. Pal R, Singh B, Bhadada SK, Banerjee M, Bhogal RS, Hage N, et al. COVID-19-associated mucormycosis: an updated systematic review of literature. *Mycoses*. 2021 Dec;64(12):1452-9. doi: 10.1111/myc.13338.
16. Qadir MM, Bhandeley M, Beatty W, Gaupp DD, Doyle-Meyers LA, Fischer T, et al. SARS-CoV-2 infection of the pancreas promotes thrombofibrosis and is associated with new-onset diabetes. *JCI Insight*. 2021 Aug;6(16):e151551. doi: 10.1172/jci.insight.151551.
17. Jose A, Singh S, Roychoudhury A, Kholakiya Y, Arya S, Roychoudhury S. Current understanding in the pathophysiology of SARS-CoV-2-associated rhino-orbito-cerebral mucormycosis: a comprehensive review. *J Maxillofac Oral Surg*. 2021 Sep;20(3):373-80. doi: 10.1007/s12663-021-01604-2.
18. Muthu V, Rudramurthy SM, Chakrabarti A, Agarwal R. Epidemiology and pathophysiology of COVID-19-associated mucormycosis: India versus the rest of the world. *Mycopathologia*. 2021 Dec;186(6):739-54. doi: 10.1007/s11046-021-00584-8.
19. Weprin BE, Hall WA, Goodman J, Adams GL. Long-term survival in rhinocerebral mucormycosis: case report. *J Neurosurg*. 1998 Mar;88(3):570-5. doi: 10.3171/jns.1998.88.3.0570.
20. Sosale A, Sosale B, Kesavadev J, Chawla M, Reddy S, Saboo B, et al. Steroid use during COVID-19 infection and hyperglycemia—What a physician should know. *Diabetes Metab Syndr*. 2021 Jul-Aug;15(4):102167. doi: 10.1016/j.dsx.2021.06.004.

21. Selvamani M, Donoghue M, Bharani S, Madhushankari GS. Mucormycosis causing maxillary osteomyelitis. *J Nat Sci Biol Med*. 2015 Jul-Dec;6(2):456-9. doi: 10.4103/0976-9668.160039.
22. Gudmundsson T, Torkov P and Thygesen TH. Diagnosis and treatment of osteomyelitis of the jaw – a systematic review of the literature. *J Dent Oral Disord*. 2017 Jun;3(4):1066. doi: 10.26420/jdentoraldisord.2017.1066.
23. Singh AK, Singh R, Joshi SR, Misra A. Mucormycosis in COVID-19: a systematic review of cases reported worldwide and in India. *Diabetes Metab Syndr*. 2021 Jul-Aug;15(4):102146. doi: 10.1016/j.dsx.2021.05.019.
24. Brandão TB, Gueiros LA, Melo TS, Prado-Ribeiro AC, Nesrallah AC, Prado GV, et al. Oral lesions in patients with SARS-CoV-2 infection: could the oral cavity be a target organ? *Oral Surg Oral Med Oral Pathol Oral Radiol*. 2021 Feb;131(2):e45-e51. doi: 10.1016/j.ooolo.2020.07.014.
25. Amorim dos Santos J, Normando AG, Carvalho da Silva RL, Acevedo AC, De Luca Canto G, Sugaya N, et al. Oral manifestations in patients with COVID-19: a living systematic review. *J Dent Res*. 2021 Feb;100(2):141-54. doi: 10.1177/0022034520957289.
26. Sanath AK, Nayak MT, Sunitha JD, Malik SD, Aithal S. Mucormycosis occurring in an immunocompetent patient: a case report and review of literature. *Cesk Patol*. 2020 Winter;56(4):223-6.
27. Bains MK, Hosseini-Ardehali M. Palatal perforations: past and present. Two case reports and a literature review. *Br Dent J*. 2005 Sep;199(5):267-9. doi: 10.1038/sj.bdj.4812650.