




# A systematic review assessing occurrence of medication-related osteonecrosis of the jaw following dental procedures

Shimelly Monteiro de Castro Lara<sup>1</sup>, Francisco Wilker Mustafa Gomes Muniz<sup>2,\*</sup> , Ana Beatriz Caetano Gerônimo<sup>1</sup>, Cinthia Studzinski dos Santos<sup>3</sup> , Thayanne Brasil Barbosa Calcia<sup>1</sup> 

<sup>1</sup> Dentistry Faculty, Arthur Sá Earp Neto University, Petrópolis, Rio de Janeiro, Brazil.

<sup>2</sup> Department of Periodontology, Federal University of Pelotas, Pelotas, Rio Grande do Sul, Brazil.

<sup>3</sup> Graduate Program in Dentistry, Federal University of Pelotas, Pelotas, Rio Grande do Sul, Brazil.

## Corresponding author:

Francisco Wilker Mustafa Gomes Muniz. Rua Gonçalves Chaves, 457 – Pelotas, Rio Grande do Sul, Brazil. ZIP Code: 96015-560. Telephone: +5553991253611. E-mail: wilkermustafa@gmail.com

**Editor:** Altair A. Del Bel Cury

**Received:** August 6, 2021

**Accepted:** January 25, 2022

**Aim:** This study aimed to systematically review existing literature regarding the association between dental procedures—such as tooth extractions and periodontal therapy—and occurrence of medication-related osteonecrosis of the jaw (MRONJ) in individuals using bone-modifying drugs. **Methods:** Search strategies were performed in PubMed, Scopus, Web of Science and Cochrane Library for a timeframe ending in December 2021. Study selection, data extraction and risk of bias were analyzed independently by two researchers. Three meta-analyses were performed, estimating the crude risk ratio (RR), the adjusted odds ratio (OR) and the adjusted hazard ratio (HR) for the association between tooth extraction and MRONJ. **Results:** Of the 1,654 studies initially retrieved, 17 were ultimately included. The majority of patients with MRONJ in these studies were female, with a mean age of 64 years. Zoledronic acid was the most commonly used drug among patients with MRONJ, and cancer was the most frequent underlying health condition. Regarding the performed meta-analyses, crude and adjusted analyses demonstrated that tooth extraction increased the risk for MRONJ by 4.28 (95% confidence interval [95%CI]: 1.73–10.58), the OR for MRONJ by 26.94 (95%CI: 4.17–174.17), and the HR for MRONJ by 9.96 (95%CI: 4.04–24.55). **Conclusion:** It was concluded that performing dental procedures, especially tooth extraction, in patients using bone-modifying drugs increased the risk of MRONJ occurrence and, therefore, should be avoided. Further studies, using adjusted data, are warranted.

**Keywords:** Bisphosphonate-associated osteonecrosis of the jaw. Bone density conservation agents. Diphosphonates. Osteonecrosis. Surgery, oral.



## Introduction

Dental treatment currently presents new challenges among professionals due to the increasing prevalence of patients with cancer and other comorbidities, conditions which are frequently treated with bone-modifying drugs such as bisphosphonates and antiresorptive agents<sup>1</sup>. Bisphosphonates are well-tolerated and extensively used as treatment for bone-related diseases, reducing risk of vertebral fractures and bone loss due to steroid-based treatment<sup>2</sup>. However, in the early 2000's, an important adverse effect related to these drugs was reported. Several patients exhibited necrotic bone in the jaw, often refractory towards surgical debridement, a clinical feature later denominated as bisphosphonate-related osteonecrosis of the jaw (BRONJ)<sup>3-5</sup>.

In ensuing decades, this condition has also been connected to other drugs such as antiresorptive and angiogenesis-inhibiting agents, including (respectively) denosumab and bevacizumab, despite their different mechanisms of action<sup>6,7</sup>. Recently, the newer terminology of medication-related osteonecrosis of the jaw (MRONJ) was adopted in order to include these drugs<sup>8</sup>. The occurrence of MRONJ seems to be highly variable, running from very rare to common (0.01–1%) depending on multiple factors both drug-related and independent<sup>9</sup>. Clinically, this condition presents as an avascular exposed bone or bone that can be probed through an intraoral or extraoral fistula on the maxilla or mandible<sup>8,10</sup>. Furthermore, an MRONJ diagnosis is based on current or previous exposure to antiresorptive or antiangiogenic agents with no history of radiotherapy or metastatic jaw disease<sup>8</sup>.

MRONJ is most often observed in older women, since this group of patients is more likely to be treated with antiresorptives due to conditions such as breast cancer or osteoporosis<sup>11</sup>. This disease can present different degrees of complexity, and a classification according to staging systems has been proposed; at present, every patient under antiresorptive therapy is considered at risk<sup>10</sup>. In this sense, MRONJ presentation can vary from an asymptomatic exposed bone with no further clinical complication to a lesion with extensive bone involvement, extraoral communication and infection<sup>10</sup>. Thus, it is an important oral complication, one for which treatment can be difficult and often ineffective<sup>12</sup>. Its etiology seems to be related to drug dosage, administration route, therapy duration and comorbidities (e.g., diabetes or a smoking habit)<sup>13</sup>. Antiresorptives and/or antiangiogenics usually demand higher doses when prescribed in cancer treatment, which has also been associated with an increased risk<sup>8</sup>. Additionally, use of corticosteroids and/or immunosuppressants may also be related to MRONJ<sup>14</sup>. However, there is no consensus about how these factors can influence MRONJ occurrence<sup>12</sup>.

Crucially, oral surgical procedures are frequently identified as MRONJ precipitating events; therefore, elective procedures are often unadvised<sup>8</sup>. As a result, MRONJ occurrence has become a challenge for dental professionals in recent years due to the absence of predictive factors providing security for dental intervention<sup>10</sup>. However, MRONJ can also occur without a history of oral surgical treatment<sup>15</sup>. Thus, this study aimed to systematically review current literature regarding the association

between dental procedures and MRONJ in patients with current or historical use of bone-modifying agents.

## Material and Methods

### PICO question

A systematic review was performed according to Preferred Reporting Items for Systematic Reviews and Meta-Analyses (PRISMA) guidelines<sup>16</sup>. The present study focused on answering the following clinical question: “Do dental extractions and periodontal surgeries increase the risk of MRONJ in patients in current therapy or with a history of antiresorptive and/or antiangiogenic use?” Therefore, the PICO question was structured as follows: Population: antiresorptive and/or antiangiogenic users or those with a use history; Intervention: extractions and periodontal therapy; Comparison: absence of dental interventions; Outcome: occurrence of MRONJ.

### Search strategy

Electronic search strategies were performed in order to include studies published up to December 2021. The search strategies were applied in the Medline-PubMed, Web of Science, Scopus, and Cochrane Library databases, and are presented in Table 1. Grey literature was also searched using the New York Academy of Medicine (NYAM) gray literature report and Google Scholar databases. An adaptation of the search strategies described in Table 1 was performed on both databases. In Google Scholar, the first 300 studies were searched, as recommended by the literature<sup>17</sup>.

In order to be included in this study, studies from the search results had to involve clinical trials (randomized or not), case-controls, case series (minimum of ten patients) and prospective or retrospective cohorts. Furthermore, studies had to involve current or former users of bone-modifying agents (antiresorptive and/or antiangiogenic drugs). The study group had to be composed of individuals submitted to dental extraction and/or periodontal surgical procedures. The control group had to include those who had not undergone the previously reported dental procedures. Literature reviews, in vitro studies, animal studies and case reports were excluded.

### Study selection

References obtained through the described search strategy were organized, and duplicates were removed using the EndnoteWeb® program (Clarivate Analytics). Study selection was carried out independently by two reviewers (ABGC and SMCL) in consideration of the inclusion criteria. In case of disagreement, a consensus was reached through discussion. Subsequently, full texts were independently evaluated for final selection. Three reviewers (ABGC, SMCL and TBBC) were included in this step and a fourth reviewer (FWMGM) was consulted to resolve possible disagreements. Additionally, a manual search was performed on the references list of selected studies.

**Table 1.** Search strategies performed and number of studies detected in all databases.

Database	Search strategy	Number of studies retrieved
Medline-PubMed	<p>#1 – Surgery, oral[Mesh Terms] OR Oral surgery[Title/abstract] OR Dental care[Mesh Terms] OR Oral Surgical Procedures[Mesh Terms] OR Oral Surgical Procedures[Title/abstract] OR Tooth extraction[Mesh Terms] OR Tooth Extraction[Title/abstract] OR dental extraction[Title/abstract] OR dental extractions[Title/abstract] OR teeth extraction[Title/abstract] OR teeth removal[Title/abstract] OR tooth extraction[Title/abstract] OR Crown Lengthening[Mesh Terms] OR Crown Lengthening[Title/abstract] OR Gingivectomy[Mesh Terms] OR Gingivoplasty[Mesh Terms] OR Dental Scaling[Mesh Terms] OR Root Planing[Title/abstract] OR open flap debridement[Title/abstract] OR periodontal surgery[Title/abstract] OR Guided Tissue Regeneration[Mesh Terms] OR root coverage[Title/abstract] OR gingival graft[Title/abstract] OR periodontal osseous surgery[Title/abstract] OR Periodontal treatment[Title/abstract]</p> <p>#2 – Diphosphonates[MeSH Terms] OR bisphosphonate[Title/abstract] OR bisphosphonates[Title/abstract] OR alendronate[MeSH Terms] OR alendronate sodium[Title/abstract] OR Risedronic Acid[MeSH Terms] OR Risedronate[Title/abstract] OR Pamidronate[MeSH Terms] OR Amidronate[Title/abstract] OR Ibandronate[Title/abstract] OR Ibandronic Acid[MeSH Terms] OR Zoledronate[Title/abstract] OR Zoledronic Acid[Title/abstract] OR Clodronic Acid[MeSH Terms] OR Clodronate[Title/abstract] OR Etidronic Acid[MeSH Terms] OR Denosumab[MeSH Terms] OR Antiresorptive drugs[Title/abstract] OR Bevacizumab[MeSH Terms] OR Sorafenib[MeSH Terms] OR Sunitinib[MeSH Terms] OR Pazopanib[Title/abstract] OR Axitinib[MeSH terms]</p> <p>#3 – Osteonecrosis[Mesh Terms] OR Osteonecrosis[Title/abstract] OR Bone Necrosis[Title/abstract] OR ARONJ[Title/abstract] OR BRONJ[Title/abstract] OR ONJ[Title/abstract] OR MRONJ[Title/abstract] OR “osteonecrosis of the jaw”[Title/abstract] OR “bisphosphonate-related osteonecrosis of the jaw”[Title/abstract] OR “bisphosphonate-related ONJ”[Title/abstract] OR “bisphosphonate-associated osteonecrosis of the jaw”[Title/abstract] OR “medication-related osteonecrosis of the jaw” [Title/abstract]</p> <p>#4 - #1 AND #2 AND #3</p>	918
Web of Science	<p>#1 – TS=(Surgery, oral OR “Oral surgery” OR “Dental care” OR “Oral Surgical Procedures” OR “Tooth extraction” OR “dental extraction” OR “dental extractions” OR “teeth extraction” OR “teeth removal” OR “tooth extraction” OR “Crown Lengthening” OR Gingivectomy OR Gingivoplasty OR “Dental Scaling” OR “Root Planing” OR “open flap debridement” OR “periodontal surgery” OR “Guided Tissue Regeneration” OR “root coverage” OR “gingival graft” OR “periodontal osseous surgery” OR “Periodontal treatment”)</p> <p>#2 – TS=(Diphosphonates OR bisphosphonate OR bisphosphonates OR alendronate OR alendronate sodium OR “Risedronic Acid” OR Risedronate OR Pamidronate OR Amidronate OR Ibandronate OR “Ibandronic Acid” OR Zoledronate OR “Zoledronic Acid” OR “Clodronic Acid” OR Clodronate OR “Etidronic Acid” OR Denosumab OR “Antiresorptive drugs” OR Bevacizumab OR Sorafenib OR Sunitinib OR Pazopanib OR Axitinib)</p> <p>#3 – TS=(Osteonecrosis OR “Bone Necrosis” OR ARONJ OR BRONJ OR ONJ OR MRONJ OR “osteonecrosis of the jaw” OR “bisphosphonate-related osteonecrosis of the jaw” OR “bisphosphonate-related ONJ” OR “bisphosphonate-associated osteonecrosis of the jaw” OR “medication-related osteonecrosis of the jaw”)</p> <p>#4 - #1 AND #2 AND #3</p>	899

Continue

## Continuation

Scopus	<p>(( TITLE-ABS-KEY (Surgery, oral) OR TITLE-ABS-KEY ("Oral surgery") OR TITLE-ABS-KEY ("Dental care") OR TITLE-ABS-KEY ("Oral Surgical Procedures") OR TITLE-ABS-KEY ("Tooth extraction") OR TITLE-ABS-KEY ("dental extraction") OR TITLE-ABS-KEY ("dental extractions") OR TITLE-ABS-KEY ("teeth extraction") OR TITLE-ABS-KEY ("teeth removal") OR TITLE-ABS-KEY ("tooth extraction") OR TITLE-ABS-KEY ("Crown Lengthening") OR TITLE-ABS-KEY (Gingivectomy) OR TITLE-ABS-KEY (Gingivoplasty) OR TITLE-ABS-KEY ("Dental Scaling") OR TITLE-ABS-KEY ("Root Planing") OR TITLE-ABS-KEY ("open flap debridement") OR TITLE-ABS-KEY ("periodontal surgery") OR TITLE-ABS-KEY ("Guided Tissue Regeneration") OR TITLE-ABS-KEY ("root coverage") OR TITLE-ABS-KEY ("gingival graft") OR TITLE-ABS-KEY ("periodontal osseous surgery") OR TITLE-ABS-KEY ("Periodontal treatment"))) AND ((TITLE-ABS-KEY (Diphosphonates) OR TITLE-ABS-KEY (bisphosphonate) OR TITLE-ABS-KEY (bisphosphonates) OR TITLE-ABS-KEY (alendronate) OR TITLE-ABS-KEY (alendronate sodium) OR TITLE-ABS-KEY ("Risedronic Acid") OR TITLE-ABS-KEY (Risedronate) OR TITLE-ABS-KEY (Pamidronate) OR TITLE-ABS-KEY (Amidronate) OR TITLE-ABS-KEY (Ibandronate) OR TITLE-ABS-KEY ("Ibandronic Acid") OR TITLE-ABS-KEY (Zoledronate) OR TITLE-ABS-KEY ("Zoledronic Acid") OR TITLE-ABS-KEY ("Clodronic Acid") OR TITLE-ABS-KEY (Clodronate) OR TITLE-ABS-KEY ("Etidronic Acid") OR TITLE-ABS-KEY (Denosumab) OR TITLE-ABS-KEY ("Antiresorptive drugs") OR TITLE-ABS-KEY (Bevacizumab) OR TITLE-ABS-KEY (Sorafenib) OR TITLE-ABS-KEY (Sunitinib) OR TITLE-ABS-KEY (Pazopanib) OR TITLE-ABS-KEY (Axitinib))) AND ((TITLE-ABS-KEY (Osteonecrosis) OR TITLE-ABS-KEY ("Bone Necrosis") OR TITLE-ABS-KEY (ARONJ) OR TITLE-ABS-KEY (BRONJ) OR TITLE-ABS-KEY (ONJ) OR TITLE-ABS-KEY (MRONJ) OR TITLE-ABS-KEY ("osteonecrosis of the jaw") OR TITLE-ABS-KEY ("bisphosphonate-related osteonecrosis of the jaw") OR TITLE-ABS-KEY ("bisphosphonate-related ONJ") OR TITLE-ABS-KEY ("bisphosphonate-associated osteonecrosis of the jaw") OR TITLE-ABS-KEY ("medication-related osteonecrosis of the jaw"))))</p>	1535
Cochrane Library	<p>#1 - Surgery, oral OR "Oral surgery" OR "Dental care" OR "Oral Surgical Procedures" OR "Tooth extraction" OR "dental extraction" OR "dental extractions" OR "teeth extraction" OR "teeth removal" OR "tooth extraction" OR "Crown Lengthening" OR Gingivectomy OR Gingivoplasty OR "Dental Scaling" OR "Root Planing" OR "open flap debridement" OR "periodontal surgery" OR "Guided Tissue Regeneration" OR "root coverage" OR "gingival graft" OR "periodontal osseous surgery" OR "Periodontal treatment"</p> <p>#2 – Diphosphonates OR bisphosphonate OR bisphosphonates OR alendronate OR alendronate sodium OR "Risedronic Acid" OR Risedronate OR Pamidronate OR Amidronate OR Ibandronate OR "Ibandronic Acid" OR Zoledronate OR "Zoledronic Acid" OR "Clodronic Acid" OR Clodronate OR "Etidronic Acid" OR Denosumab OR "Antiresorptive drugs" OR Bevacizumab OR Sorafenib OR Sunitinib OR Pazopanib OR Axitinib</p> <p>#3 – Osteonecrosis OR "Bone Necrosis" OR ARONJ OR BRONJ OR ONJ OR MRONJ OR "osteonecrosis of the jaw" OR "bisphosphonate-related osteonecrosis of the jaw" OR "bisphosphonate-related ONJ" OR "bisphosphonate-associated osteonecrosis of the jaw" OR "medication-related osteonecrosis of the jaw"</p> <p>#4 - #1 AND #2 AND #3</p>	73
NYAM gray literature report	Oral surgery and osteonecrosis and (bisphosphonate OR Denosumab OR Bevacizumab)	0
Google Scholar	Oral surgery and osteonecrosis and (bisphosphonate OR Denosumab OR Bevacizumab)	300

## Data extraction

Data extraction was performed in a spreadsheet specifically developed for this study. Two researchers (SMCL and TBBC) were involved in this process, with a third

researcher involved in case of discrepancy (FWMGM). The following parameters were collected: author, publication year, country, study design, patient gender, mean (standard deviation [SD]) age, number of patients with and without MRONJ, MRONJ diagnosis criteria, number of patients submitted to dental procedures in both test and control groups, dental prosthesis users, smokers, use of bone-modifying drugs and its clinical indication and other medications reported. In cases of insufficient information, authors were contacted by email to obtain additional information.

### Risk of bias assessment

Both retrospective and prospective cohorts as well as case-control studies were included in this review. Therefore, the Newcastle-Ottawa quality assessment tool was used to analyze the risk of bias in this study. This tool consists of eight criteria and classifies the involved research according to a score ranging from zero to nine stars. On this scale, a study can be awarded a maximum of one star for each item within the selection and outcome categories. In the comparability category, it is possible to award the study with two stars. The first star is received by studies that performed control for the most important factor. The second is received by studies that carried out controls on other additional factors. The risk of bias analysis was performed independently by two reviewers (CSS and TBBC), and discrepancies were solved by a third researcher (FWMGM).

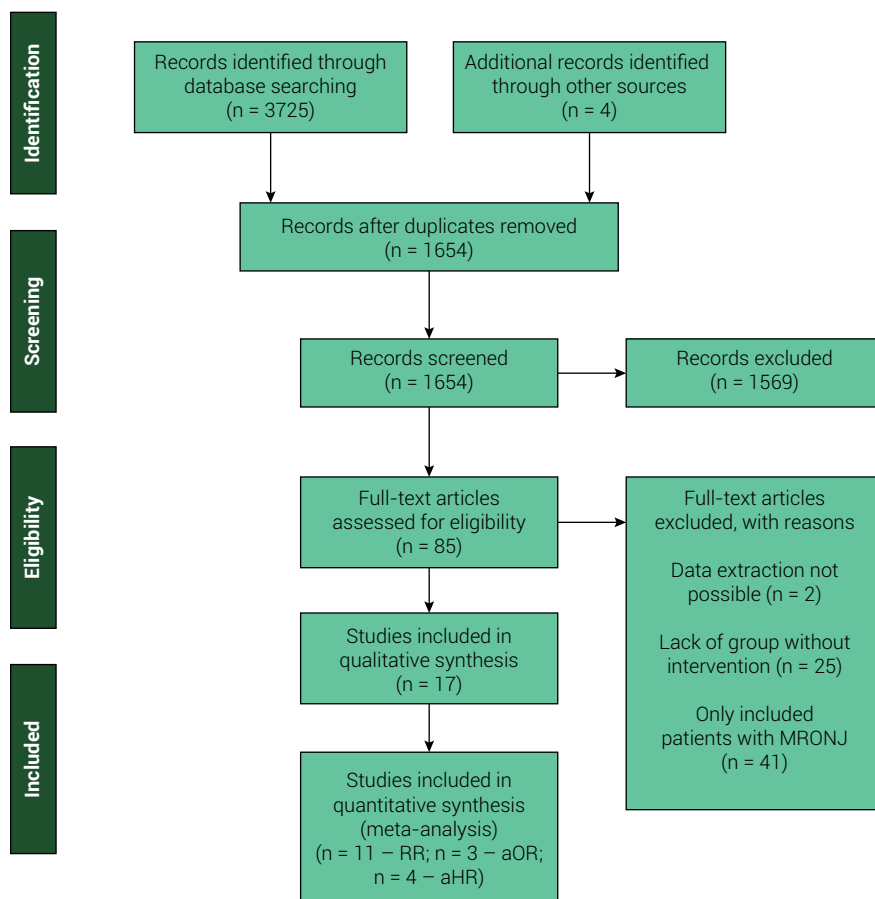
### Data synthesis and statistical analysis

Three different meta-analyses were conducted during this study. Meta-analyses were performed if at least two studies provided enough information regarding the occurrence of MRONJ following dental surgical procedures. No study clearly reported the occurrence of MRONJ after periodontal surgical procedures. Thus, three meta-analyses were performed for tooth extraction procedures regardless of the study follow-up time. Firstly, MRONJ risk involving dental extraction was assessed using risk ratio (RR). Additionally, two other meta-analyses were performed using the pooled log of odds ratio (OR) and the pooled log of hazard ratio (HR); this was done only for studies that provided multivariate estimates for the occurrence of MRONJ following dental extraction, controlling for at least two important confounding variables. Heterogeneity was assessed using the Q test and quantified by  $I^2$ . For both analyses, a random model was used within the Review Manager software (version 5.3).

## Results

### Search results

Firstly, a total of 3,725 studies were obtained through our search strategy. Four additional studies were included as the result of a manual search on the final references list of included articles. After duplicates removal, 1,654 studies were screened; of those, 85 were assessed for eligibility. Seventeen studies fulfilled the outlined inclusion criteria and were included in the qualitative synthesis. Therefore, 13 retrospective cohorts<sup>18-30</sup>, one prospective cohort<sup>31</sup> and three case-control studies<sup>32-34</sup> were included in the present study, as shown in Figure 1.



**Figure 1.** PRISMA flowchart of study selection process. Legend: RR: Risk ratio; aOR: adjusted odds ratio; aHR: adjusted hazard ratio.

## Risk of bias assessment

The risk of bias assessment conducted on the cohort studies is summarized in Figure 2A. Among the different cohort studies, eight<sup>20-23,25,27-29</sup> presented low risk of bias in all analyzed criteria. Four cohort articles presented a high risk of bias regarding comparability between groups, given the presence of possible confounders<sup>18,19,24,31</sup>. Additionally, four studies failed to demonstrate that the outcome was not present at the beginning of the study<sup>19,26,30,31</sup>. Figure 2B presents the risk of bias assessment for the case-control studies. Only one case-control study presented a low risk of bias in all analyzed criteria<sup>34</sup>. Moreover, among case-control studies, risk of bias in relation to non-response rate between groups was detected in two studies, which were thus classified as presenting a high risk of bias<sup>32,33</sup>.

## Main results

The main characteristics of the included studies with patients subject to bone-modifying therapies are summarized in Table 2. The number of patients enrolled had great variability among studies, with a range from 39 to 164,926 individuals. Over-

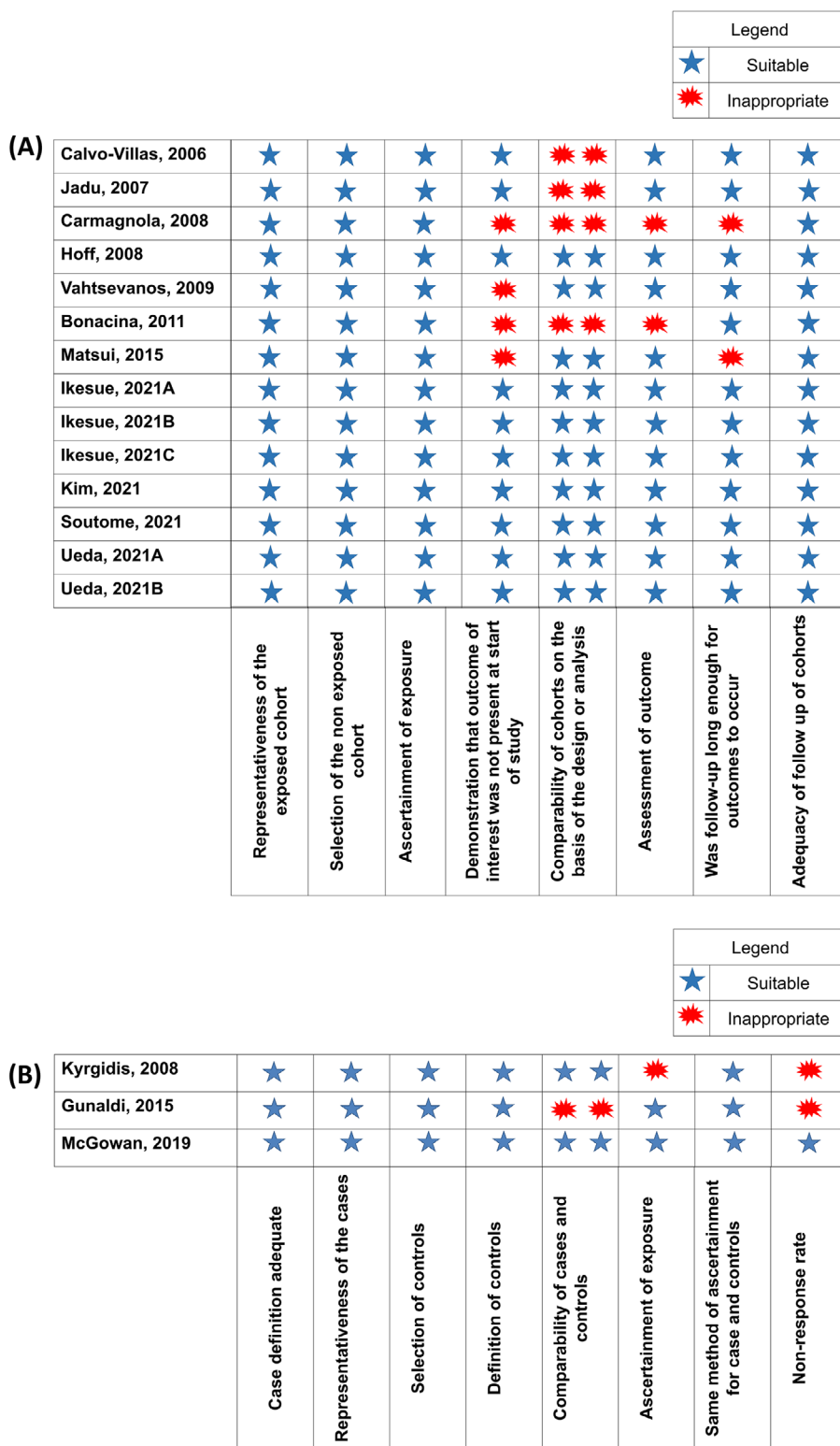


Figure 2. Risk of bias analysis of cohort (A) and case-control (B) studies, according to Newcastle-Ottawa scale.



**Table 2.** Main characteristics of patients using bone-modifying drugs enrolled in the studies.

Author/Year Country Study design	Drug-related factors				Patient-related factors				Main results	
	MRONJ/ All patients		Non-MRONJ		MRONJ		Non-MRONJ			Diabetes; Smokers
	Incidence (%)	Mean age	Bone-modifying drug	Clinical indication; Current medications	Oral surgical procedures; Dental prosthesis; Oral infections	Oral surgical procedures; Dental prosthesis; Oral infections	Diabetes; Smokers			
Bonacina (2011) Canada; Prospective cohort.	7/65 (10.7%) NR		Zoledronate (55) Zoledronate and sunitinib (3)	Cancer (7); Corticoids (0)	MRONJ Zoledronate (7)	Non-MRONJ Cancer (7); Corticoids (7)	MRONJ Extraction (1); NR; NR	Non-MRONJ Extraction (3); NR; NR	NR; 0 NR; 13	Among the evaluated patients, there was a correlation between the number of zoledronate infusions and MRONJ. In addition, all these patients presented previous exposure to bisphosphonates.
Calvo-Villas (2016) Spain; Retrospective cohort.	7/64 (10.9%) 75 yo		Zoledronate (57) Pamidronate and zoledronate (43)	Multiple myeloma (7); Corticoids (7) Thalidomide (3)	MRONJ Zoledronate (3) Pamidronate and zoledronate (4)	Non-MRONJ Multiple myeloma (57); Corticoids (35) Thalidomide (14)	MRONJ Extraction (5); NR; Oral infection (6)	Non-MRONJ Extraction (1); NR; Oral infection (44)	NR; 2 NR; 18	Occurrence of MRONJ was directly related to duration of bisphosphonate therapy and presence of local factors, as oral infections.
Carmagnola (2008) Italy; Retrospective cohort.	20/39 (51.7%) 65 yo		Zoledronate (18) Pamidronate (1)	Cancer (14) Multiple myeloma (6) Lymphoma (1); NR	MRONJ Zoledronate (19) Pamidronate and zoledronate (1)	Non-MRONJ Cancer (12) Multiple myeloma (6) Lymphoma (1); NR	MRONJ Extraction (10); Dentures (7); NR	Non-MRONJ Extraction (5); NR; NR	NR; NR NR; NR	The authors did not find an association between dental extractions and MRONJ. Increased doses of zoledronate were related to MRONJ.
Gunaldi (2015) Turkey; Case-Control	24/44 (54.4%) 60,5 yo		Zoledronate (19) Zoledronate + Bevacizumab (1)	Cancer (14) Multiple myeloma (8) Other (2); Corticoids (7) Thalidomide (5)	MRONJ Zoledronate (23) Zoledronate + Bevacizumab (1)	Non-MRONJ Cancer (9) Multiple myeloma (7) Other (4); Corticoids (7) Thalidomide (4)	MRONJ Extraction (13); NR; NR	Non-MRONJ Extraction (4); NR; NR	1; 4 1; 4	Time of exposure to zoledronate and tooth extraction were factors related to MRONJ.

Continue

Continuation									
Hoff (2008) USA Retrospective cohort.	29/3965 (0.79%) 62yo	Pamidronate (7) Zoledronate (9) Pamidronate + Zoledronate (13)	Pamidronate (2281) Zoledronate (1171) Pamidronate + Zoledronate (513)	Cancer (16) Multiple myeloma (13); Corticoids (23)	Cancer (2392) Multiple myeloma (535) Osteoporosis (271) Paget's disease (11); Corticoids (3272)	Extraction (16); Dentures (3); Oral infection (14)	NR; NR NR; NR NR; NR	NR; NR	Mean time of treatment and dental extractions were related to occurrence of MRONJ. Use of zoledronate increases risk of osteonecrosis.
Ikesue (2021) Japan Retrospective cohort	34/374 (9.09%) 70 yo	Denosumab (27) Zoledronate (7)	Denosumab (198) Zoledronate (152)	Cancer (28) Multiple myeloma (4) Others (2) Oral bisphosphonate (1) Antiangiogenic agents (11) Corticoid (22)	Cancer (246) Multiple myeloma (52) Others (40) Oral bisphosphonate (12) Antiangiogenic agent (62) Corticoid (181)	Extraction (10); NR; NR Extraction (10); NR; NR	3; NR	67; NR	Incidence of MRONJ was greater in the denosumab group than in zoledronate users. MRONJ occurrence was related to age > 65 years and tooth extraction before or after starting therapy.
Ikesue (2021) Japan Retrospective cohort	58/799 (7.3%) NR	Denosumab (39) Zoledronate (19)	Denosumab (367) Zoledronate (374)	NR NR	NR NR	NR; NR; NR NR; NR; NR	NR; NR	NR; NR	Risk of developing MRONJ was higher in denosumab users. Tooth extraction after starting therapy was a significant risk factor to develop MRONJ.
Ikesue (2021) Japan Retrospective cohort	65/795 (8.2%) NR	Denosumab after Zoledronate (7) Zoledronate (19) Denosumab (39)	Denosumab after Zoledronate (36) Zoledronate (331) Denosumab (363)	NR NR	NR NR	NR; NR; NR NR; NR; NR	NR; NR	NR; NR	MRONJ occurrence was associated with tooth extraction, concomitant use of antiangiogenics, denosumab therapy and switching zoledronate to denosumab.

Continue





all, 175,004 patients were included in the seventeen studies, with mean age  $\geq 60$  years. A higher percentage of female patients was reported among the majority of included studies. Male patients were more prevalent in only five studies<sup>21-23,28,29</sup>, while three studies did not provide data regarding sex<sup>24,31,32</sup>. AAOMS classification diagnostic criteria<sup>35</sup> was adopted in ten studies<sup>21-24,26-31</sup>.

Among the included studies, a total of 683 patients with MRONJ were enrolled. This condition had a slightly higher diagnosis rate among female patients ( $n = 129/256$ ), when considering studies that provided this information. Among individuals with MRONJ, 159 patients had a history of tooth extraction, representing 23.2% of the total. Use of dental prosthesis was reported in 60 patients, after an analysis of 196 individuals (30.6%). However, it is important to note that this variable was not reported in most of the studies.

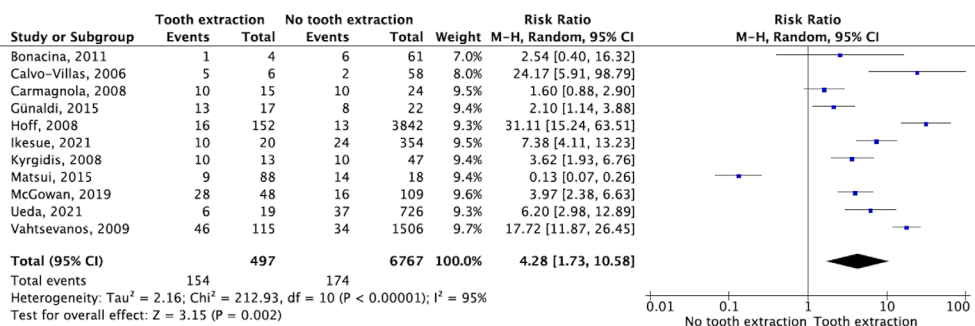
Smoking was also assessed as a possible risk factor for MRONJ; this factor was reported in two studies. Among 966 individuals who reported smoking habits, 89 patients developed MRONJ<sup>18,28,30-34</sup>. The main reason for clinical indication of the use of antiresorptive and antiangiogenic drugs was cancer (209 patients, 30.6%). Among the drugs used, Zoledronate was the most cited (143 patients, 20.9%). When considering corticosteroid use and occurrence of MRONJ, studies reported prevalence varying from 2.3%<sup>28</sup> to 29%<sup>33</sup>, 64.7%<sup>21</sup>, 79%<sup>20</sup> and up to 100%<sup>18</sup> of patients, among five studies that provided this information (Table 2). It is important to highlight that, aside from the provided data, one study was not included in the quantitative synthesis, as only the number of jaws (not patients) was available<sup>27</sup>.

Regarding patients without MRONJ, the total number of patients varied among studies, with a total sample of 174,132. There was once again a higher prevalence of female individuals involved, but the main underlying disease reported was osteoporosis (165,152 patients, 94.8%), mostly due to one expressive cohort study<sup>27</sup>. For patients without MRONJ, pamidronate was the most frequently reported drug used; however, several studies did not specify the bisphosphonate agent. The use of dental prostheses was reported for 259 patients. Additionally, smoking was observed in 0.5% of patients, for a total of 1,010 individuals (Table 2).

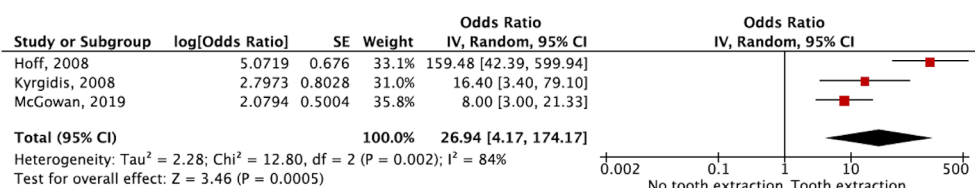
## Meta-analyses

Only dental extraction procedures were reported in all selected studies. For this reason, this was the only dental procedure available to include in meta-analyses. Crude analysis revealed an increase in the relative risk of occurrence of MRONJ following tooth extraction (RR = 4.28; 95%CI: 1.73–10.58), as presented in Figure 3. For this analysis, eleven studies were included<sup>18-21,26,28,30-34</sup>. It is important to highlight the high heterogeneity among these studies ( $I^2 = 95\%$ ,  $p < 0.001$ ).

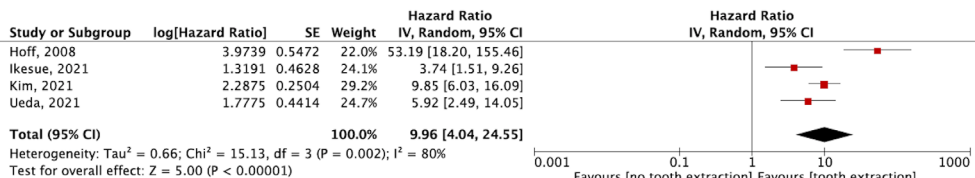
Furthermore, two additional meta-analyses were performed in consideration only of the studies that reported adjusted analysis for the association between dental extraction and MRONJ. Three studies assessed the adjusted OR<sup>20,32,34</sup>, and four estimated the adjusted HR<sup>20,21,25,28</sup>. As shown in Figures 4 and 5, similar results were demonstrated, as dental extraction significantly increased the OR for the occurrence of MRONJ (OR = 26.94; 95%CI: 4.17–174.17%) and the HR for the occurrence of MRONJ (HR = 9.96; 95%CI: 4.04–24.55). Moreover, high heterogeneity was demonstrated in both analyses (respectively:  $I^2 = 84\%$ ,  $p = 0.002$ ; and  $I^2 = 80\%$ ,  $p = 0.002$ ).



**Figure 3.** Forest plot for the crude association between medication-related osteonecrosis of the jaw (MRONJ) and tooth extraction.



**Figure 4.** Forest plot for adjusted odds ratio analysis between medication-related osteonecrosis of the jaw (MRONJ) and tooth extraction.



**Figure 5.** Forest plot for adjusted hazard ratio analysis between medication-related osteonecrosis (MRONJ) of the jaw and tooth extraction.

## Discussion

MRONJ is a recently described complication, first reported in 2003 through a series of cases in patients who used bisphosphonates<sup>3</sup>. Since then, several reports have associated avascular bone necrosis with oral and intravenous bisphosphonates therapy, in addition to antiresorptives and antiangiogenics<sup>8,36</sup>.

Due to its multifactorial nature and complex management, many authors have tried to associate risk factors with MRONJ development in order to avoid its occurrence. The present study identified that the occurrence of MRONJ is generally higher among women, which is in accordance with the literature<sup>37</sup>. Osteoporosis and breast cancer, the therapeutic indications of which are related to the use of antiresorptives, bisphosphonates and antiangiogenics, are more common among female patients, which may explain this result<sup>8</sup>. In addition to these factors, literature reports that women seek more often dental care; this could result in a higher diagnosis rate for several conditions, including MRONJ<sup>38</sup>.

The mean age of patients diagnosed with MRONJ was greater than 60 years in the included studies, which is in accordance with the literature<sup>39,40</sup>. Among these patients, there is a higher incidence of chronic diseases—a common reason for prescribing bone-modifying drugs—and few studies failed to detect this relationship<sup>30</sup>.

Trigger factors for MRONJ remain subject to critical investigation. Marx<sup>3</sup> reported its occurrence more often following dental procedures in the mandible. Among the studies included here, tooth extraction, periodontal disease or trauma induced by poorly adapted prostheses have been involved in the onset and even exacerbation of the condition<sup>20,31</sup>. Bone exostosis, trauma induced by intubation and poor dental implant placement have also been discussed<sup>20</sup>.

Dental extractions can be justified as a risk factor for the development of MRONJ, as they may induce bone exposure in the oral cavity with a consequent reduction in blood support and bone metabolism and greater osteoclast apoptosis<sup>19</sup>. The present study confirms the proposed association between tooth extraction and MRONJ onset, including in the adjusted analysis. In fact, MRONJ occurs frequently at the procedure site, although it can also occur spontaneously (i.e., without an identifiable precipitating clinical event)<sup>41</sup>. According to Carmagnola et al.<sup>19</sup>, patients with MRONJ reported extractions twice as frequently as those without MRONJ. However, analysis also revealed a high heterogeneity, which can be attributed to different experimental designs and varied sampling. Moreover, due to the lack of randomized controlled trials, this research included only cohort and case-control studies; as a result, it is difficult to provide solid evidence regarding this research topic, which explains the fact that several recommendations for the management of MRONJ are based on expert consensus<sup>10</sup>. Hence, this must be taken into consideration when interpreting the results of the present study.

Other local factors may also be involved in the occurrence of MRONJ. Teeth with dental extraction indication are often associated with an infectious process, and the presence of inflammation or infection would be a predisposing factor for the appearance of lesions caused by avascular bone necrosis<sup>41</sup>. In this regard, one study found that MRONJ occurrence may also be related to preexisting inflammatory dental disease; in such a scenario, dental extraction is fundamental in order to prevent MRONJ onset<sup>27</sup>. Furthermore, the use of dental prostheses, which is common among older adults, is considered another potential local risk factor for MRONJ. Unretained dental prosthesis may cause low-grade chronic trauma, usually resulting in oral lesions due to rupture of the protective barrier which allow the entry of highly contaminated oral microbiota into the bone<sup>29,32</sup>.

In addition, systemic factors can also influence the occurrence of MRONJ. One critical example is diabetes, a disease that can predispose a patient to the occurrence of this dental complication<sup>40</sup>. In the present study, two included studies suggested that type II diabetes and smoking represent important risk factors for the occurrence of MRONJ<sup>31,33</sup>. Moreover, exposure to smoke predisposes a patient to cancer, making the need for administration of antiresorptive and antiangiogenic drugs more likely and thus intrinsically increasing the possibility of MRONJ, complicating the identification of a cause-and-effect relationship<sup>33</sup>. Conversely, two previous studies did not state an association between smoking and MRONJ<sup>18,30</sup>.

Current use of other medications, such as corticosteroids, has also been listed as a risk factor in the literature<sup>24</sup>. One included study<sup>18</sup> reported that all MRONJ patients were also using corticosteroids, while another reported this percentage as 2.3%<sup>28</sup>. Therefore, based on compiled data, there is no way to draw a definitive conclusion on this topic.

Bisphosphonate or antiresorptive type, form of administration (oral or IV), number of infusions and the time of exposure are also factors considered in relation to the development of MRONJ<sup>10</sup>. Among the included studies, a higher percentage of patients with MRONJ undergoing cancer treatment was observed. However, due to lack of information regarding time of therapy and dosage, it was not possible to further analyze these characteristics in the present study. That said, the majority of studies found a correlation between cumulative doses and MRONJ.

The included studies ultimately reveal that there is not yet enough evidence to ensure safe invasive dental procedures in such patients, even after the interruption of the therapeutic protocol. Therefore, communication between health care professionals is essential to provide preventive treatment prior to drug administration. Routine and preventive appointments for early identification of infectious areas are fundamental for preventing MRONJ and reducing the significant impact of this complication. It must be noted that the present study was not previously registered in any database of protocols for systematic reviews. Unfortunately, *a posteriori* registrations are not permitted by these databases. This must therefore be understood as a major limitation of the present study.

In summary, this systematic review showed that dental extractions increased the risk of MRONJ occurrence 4.28 times. Risk factors such as smoking, diabetes and the use of corticosteroids are possible variables related to this condition, which is more frequent in women over 60 years of age. Our work adds vital evidence in order to provide better care for these patients. Preventive oral hygiene measures are the best options available for patients using bone-modifying drugs, preferably before the start of medical and dental procedures.

## Acknowledgments

This study was financed in part by the Coordenação de Aperfeiçoamento de Pessoal de Nível Superior - Brasil (CAPES) - Finance Code 001. All other funding was self-supported by the authors. The authors report no conflict of interest.

## Data availability

Datasets related to this article will be available upon request to the corresponding author.

## Conflict of Interests

None.

## Author contribution

Shimelly Monteiro de Castro Lara has contributed with study selection, data extraction and writing; Ana Beatriz Caetano Gerônimo was enrolled in study selection and data



extraction; Francisco Wilker Mustafa Gomes Muniz has contributed with conceptualization, methodological advice, designing search strategies, writing and final revision; Cinthia Studzinski Santos was enrolled in bias assessment and writing; Thayanne Brasil Barbosa Calcia has contributed with conceptualization, bias assessment, writing and final revision.

## List of all captions

AAOMS: American Academy of Oral and Maxillofacial Surgery

BRONJ: bisphosphonate related osteonecrosis of jaw

CI: Confidence Interval

MRONJ: Medication Related Osteonecrosis of the Jaw

OR: odds ratio

PRISMA: Preferred Reporting Items for Systematic Reviews and Meta-Analyses

RR: risk ratio

---

## References

1. Mishra MB, Mishra S, Mishra R. Dental care in the patients with bisphosphonates therapy. *Int J Dent Clin* 2011;3(1):60-4.
2. Allen CS, Yeung JHS, Vandermeer B, Homik J. Bisphosphonates for steroid-induced osteoporosis. *Cochrane Database Syst Rev*. 2016 Oct;10(10):CD001347. doi: 10.1002/14651858.CD001347.pub2.
3. Marx RE. Pamidronate (Aredia) and zoledronate (Zometa) induced avascular necrosis of the jaws: a growing epidemic. *J Oral Maxillofac Surg*. 2003 Sep;61(9):1115-7. doi: 10.1016/s0278-2391(03)00720-1.
4. Ruggiero SL, Mebrota B, Rosenberg TJ, Engroff SL. Osteonecrosis of the jaws associated with the use of bisphosphonates: a review of 63 cases. *J Oral Maxillofac Surg*. 2004 May;62(5):527-34. doi: 10.1016/j.joms.2004.02.004.
5. Ruggiero SL, Gralow J, Marx RE, Hoff AO, Schubert MM, Huryn JM, et al. Practical guidelines for the prevention, diagnosis, and treatment of osteonecrosis of the jaw in patients with cancer. *J Oncol Pract*. 2006 Jan;2(1):7-14. doi: 10.1200/JOP.2006.2.1.7.
6. Yarom N, Lazarovici TS, Whitefield S, Weissman T, Wasserzug O, Yahalom R. Rapid onset of osteonecrosis of the jaw in patients switching from bisphosphonates to denosumab. *Oral Surg Oral Med Oral Pathol Oral Radiol* 2018 Jan;125(1):27-30. doi: 10.1016/j.oooo.2017.09.014..
7. Santos-Silva AR, Belizário Rosa GA, Castro Júnior G, Dias RB, Prado Ribeiro AC, Brandão TB. Osteonecrosis of the mandible associated with bevacizumab therapy. *Oral Surg Oral Med Oral Pathol Oral Radiol*. 2013 Jun;115(6):e32-6. doi: 10.1016/j.oooo.2013.02.001.
8. Ruggiero SL, Dodson TB, Fantasia J, Goodday R, Aghaloo T, Mehrotra B, et al. American association of oral and maxillofacial surgeons position paper on medication-related osteonecrosis of the jaw - 2014 update. *J Oral Maxillofac Surg*. 2014 Oct;72(10):1938-56. doi: 10.1016/j.joms.2014.04.031.
9. Dodson TB. The frequency of medication-related osteonecrosis of the jaw and its associated risk factors. *Oral Maxillofac Surg Clin North Am*. 2015 Nov;27(4):509-16. doi: 10.1016/j.coms.2015.06.003.

10. Yarom N, Shapiro CL, Peterson DE, Poznak CHV, Bohlke K, Ruggiero SL, et al. Medication-Related Osteonecrosis of the Jaw: MASCC/ISOO/ASCO Clinical Practice Guideline. *J Clin Oncol*. 2019 Sep;37(25):2270-90. doi: 10.1200/JCO.19.01186.
11. Wotton CJ, Green J, Brown A, Armstrong MEG, Floud S, Beral V, et al. Use of oral bisphosphonates and risk of hospital admission with osteonecrosis of the jaw: Large prospective cohort study in UK women. *Bone*. 2019 Jul;124:69-74. doi: 10.1016/j.bone.2019.04.003.
12. Nicolatou-Galitis O, Schiødt M, Mendes RA, Ripamonti C, Hope S, Drudge-Coates L, et al. Medication-related osteonecrosis of the jaw: definition and best practice for prevention, diagnosis, and treatment. *Oral Surg Oral Med Oral Pathol Oral Radiol*. 2019 Feb;127(2):117-35. doi: 10.1016/j.oooo.2018.09.008.
13. He L, Sun X, Liu Z, Qiu Y, Niu Y. Pathogenesis and multidisciplinary management of medication-related osteonecrosis of the jaw. *Int J Oral Sci*. 2020 Oct;12(1):30. doi: 10.1038/s41368-020-00093-2.
14. Aljohani S, Fliefel R, Ihbe J, Kühnisch J, Ehrenfeld M, Otto S. What is the effect of anti-resorptive drugs (ARDs) on the development of medication-related osteonecrosis of the jaw (MRONJ) in osteoporosis patients: a systematic review. *J Craniomaxillofac Surg*. 2017 Sep;45(9):1493-502. doi: 10.1016/j.jcms.2017.05.028.
15. Khominsky A, Lim M. "Spontaneous" medication-related osteonecrosis of the jaw; two case reports and a systematic review. *Aust Dent J*. 2018 Dec;63(4):441-54. doi: 10.1111/adj.12648.
16. Page MJ, McKenzie JE, Bossuyt PM, Boutron I, Hoffmann TC, Mulrow CD, et al. The PRISMA 2020 statement: An updated guideline for reporting systematic reviews. *J Clin Epidemiol*. 2021 Jun;134:178-89. doi: 10.1016/j.jclinepi.2021.03.001.
17. Haddaway NR, Collins AM, Coughlin D, Kirk S. The Role of Google Scholar in Evidence Reviews and Its Applicability to Grey Literature Searching. *PLoS One*. 2015 Sep;10(9):e0138237. doi: 10.1371/journal.pone.0138237.
18. Calvo-Villas JM, Torres MT, Rodriguez JG, Granda EC, Guillèn FS. Osteonecrosis of the jaw in patients with multiple myeloma during and after treatment with zoledronic acid. *Med Clin (Barc)*. 2006 Oct;127(15):576-9. doi: 10.1016/s0025-7753(06)72338-7.
19. Carmagnola D, Celestino S, Abati S. Dental and periodontal history of oncologic patients on parenteral bisphosphonates with or without osteonecrosis of the jaws: A pilot study. *Oral Surg Oral Med Oral Pathol Oral Radiol Endod*. 2008 Dec;106(6):e10-5. doi: 10.1016/j.tripleo.2008.07.011.
20. Hoff AO, Toth BB, Altundag K, Johnson MM, Warneke CL, Hu M, et al. Frequency and risk factors associated with osteonecrosis of the jaw in cancer patients treated with intravenous bisphosphonates. *J Bone Miner Res* 2008. 2008 Jun;23(6):826-36. doi: 10.1359/jbmr.080205.
21. Ikesue H, Mouri M, Tomita H, Hirabatake M, Ikemura M, Muroi N, et al. Associated characteristics and treatment outcomes of medication-related osteonecrosis of the jaw in patients receiving denosumab or zoledronic acid for bone metastases. *Support Care Cancer*. 2021 Aug;29(8):4763-72. doi: 10.1007/s00520-021-06018-x.
22. Ikesue H, Doi K, Morimoto M, Hirabatake M, Muroi N, Yamamoto S, et al. Risk evaluation of denosumab and zoledronic acid for medication-related osteonecrosis of the jaw in patients with bone metastases: a propensity score-matched analysis. *Support Care Cancer*. 2022 Mar;30(3):2341-8. doi: 10.1007/s00520-021-06634-7.
23. Ikesue H, Doi K, Morimoto M, Hirabatake M, Muroi N, Yamamoto S, et al. Switching from zoledronic acid to denosumab increases the risk for developing medication-related osteonecrosis of the jaw in patients with bone metastases. *Cancer Chemother Pharmacol*. 2021 Jun;87(6):871-7. doi: 10.1007/s00280-021-04262-w.

24. Jadu F, Lee L, Pharoah M, Reece D, Wang L. A retrospective study assessing the incidence, risk factors and comorbidities of pamidronate-related necrosis of the jaws in multiple myeloma patients. *Ann Oncol*. 2007 Dec;18(12):2015-9. doi: 10.1093/annonc/mdm370.
25. Kim SH, Lee YK, Kim TY, Ha YC, Jang S, Kim HY. Incidence of and risk for osteonecrosis of the jaw in Korean osteoporosis patients treated with bisphosphonates: a nationwide cohort-study. *Bone*. 2021 Feb;143:115650. doi: 10.1016/j.bone.2020.115650.
26. Matsui A, Kurihara J, Morishima H, Suzuki H, Sato S, Yamauchi K, et al. Medication related osteonecrosis of the jaw (MRONJ): a retrospective survey of a series of patients treated according to the AAOMS guidelines. *J Oral Maxillofac Surg Med Pathol*. 2015;27(6):757-63. doi: 10.1016/j.ajoms.2015.03.005.
27. Soutome S, Otsuru M, Hayashida S, Murata M, Yanamoto S, Sawada S, et al. Relationship between tooth extraction and development of medication-related osteonecrosis of the jaw in cancer patients. *Sci Rep*. 2021 Aug 26;11(1):17226. doi: 10.1038/s41598-021-96480-8.
28. Ueda N, Nakashima C, Aoki K, Shimotsuji H, Nakaue K, Yoshioka H, et al. Does inflammatory dental disease affect the development of medication-related osteonecrosis of the jaw in patients using high-dose bone-modifying agents? *Clin Oral Investig*. 2021 May;25(5):3087-93. doi: 10.1007/s00784-020-03632-7.
29. Ueda N, Aoki K, Shimotsuji H, Nakashima C, Kawakami M, Imai Y, et al. Oral risk factors associated with medication-related osteonecrosis of the jaw in patients with cancer. *J Bone Miner Metab*. 2021 Jul;39(4):623-30. doi: 10.1007/s00774-020-01195-x.
30. Vahtsevanos K, Kyrgidis A, Verrou E, Katodritou E, Triaridis S, Andreadis CG, et al. Longitudinal Cohort Study of Risk Factors in Cancer Patients of Bisphosphonate-Related Osteonecrosis of the Jaw. *J Clin Oncol*. 2009 Nov 10;27(32):5356-62. doi: 10.1200/JCO.2009.21.9584.
31. Bonacina R, Mariani U, Villa F, Villa A. Preventive strategies and clinical implications for bisphosphonate-related osteonecrosis of the jaw: a review of 282 patients. *J Can Dent Assoc* 2011;77:b147.
32. Kyrgidis A, Vahtsevanos K, Koloutsos G, Andreadis C, Boukovinas I, Teleioudis Z, et al. et al. Bisphosphonate-related osteonecrosis of the jaws: a case- control study of risk factors in breast cancer patients. *J Clin Oncol*. 2008 Oct;26(28):4634-8. doi: 10.1200/JCO.2008.16.2768.
33. Günaldi M, Afsar CU, Duman BB, Kara IO, Taltli U, Sahin B. Effect of the cumulative dose of zoledronic acid on the pathogenesis of osteonecrosis of the jaws. *Oncol Lett*. 2015 Jul;10(1):439-42. doi: 10.3892/ol.2015.3156.
34. McGowan K, Ware RS, Acton C, Ivanovski S, Johnson NW. Both non-surgical dental treatment and extractions increase the risk of medication-related osteonecrosis of the jaw: case-control study. *Clin Oral Investig*. 2019 Nov;23(11):3967-75. doi: 10.1007/s00784-019-02828-w.
35. Ruggiero SL, Dodson TB, Assael LA, Landesberg R, Marx RE, Mehrotra B, et al. American Association of Oral and Maxillofacial Surgeons position paper on bisphosphonate-related osteonecrosis of the jaws—2009 update. *J Oral Maxillofac Surg*. 2009 May;67(5 Suppl):2-12. doi: 10.1016/j.joms.2009.01.009.
36. Shibahara T. Antiresorptive Agent-Related Osteonecrosis of the Jaw (ARONJ): A Twist of Fate in the Bone. *Tohoku J Exp Med*. 2019 Feb;247(2):75-86. doi: 10.1620/tjem.247.75.
37. Yamazaki T, Yamori M, Ishizaki T, Asai K, Goto K, Takahashi K, et al. Increased incidence of osteonecrosis of the jaw after tooth extraction in patients treated with bisphosphonates: a cohort study. *Int J Oral Maxillofac Surg*. 2012 Nov;41(11):1397-403. doi: 10.1016/j.ijom.2012.06.020.
38. Lo JC, O’Ryan F, Yang J, Hararah MK, Gonzalez JR, Gordon N, et al. Oral health considerations in older women receiving oral. *J Am Geriatr Soc*. 2011 May;59(5):916-22. doi: 10.1111/j.1532-5415.2011.03371.x.

39. Walter C, Al-Nawas B, Grötz K, Thomas C, Thüroff J, Zinser V, et al. Prevalence and risk factors of bisphosphonate-associated osteonecrosis of the jaw in prostate cancer patients with advanced disease treated with zoledronate. *Eur Urol*. 2008 Nov;54(5):1066-72. doi: 10.1016/j.eururo.2008.06.070.
40. Estilo CL, Poznak CH, Williams T, Bohle GC, Lwin PT, Zhou Q, et al. Osteonecrosis of the maxilla and mandible in patients with advanced cancer treated with bisphosphonate therapy. *Oncologist*. 2008 Aug;13(8):911-20. doi: 10.1634/theoncologist.2008-0091.
41. Saad F, Brown JE, Poznak CV, Ibrahim T, Stemmer SM, Stopeck AT, et al. Incidence, risk factors, and outcomes of osteonecrosis of the jaw: integrated analysis from three blinded active-controlled phase III trials in cancer patients with bone metastases. *Ann Oncol*. 2012 May;23(5):1341-7. doi: 10.1093/annonc/mdr435.