







Histomorphometric comparison of two different preclinical models to evaluate the bone repair in grafted areas

Julia Raulino Lima¹ , Priscilla Barbosa Ferreira Soares¹ , Lucas de Sousa Goulart Pereira¹ , Leidys Rodríguez Perdomo¹ , Suzane Cristina Pigossi¹ , Guilherme José Pimentel Lopes de Oliveira^{1,*} 

¹ Department of Periodontology, School of Dentistry, Federal University of Uberlândia (UFU), Uberlândia, MG, Brazil.

Corresponding author:

Guilherme José Pimentel Lopes de Oliveira
Pará, Av., 1760-1844 - Umuarama, Uberlândia - MG,
Zip-code: 38405-320
Email: guilherme.lopesoliveira@ufu.br

Editor: Dr. Altair A. Del Bel Cury

Received: July 10, 2023

Accepted: September 22, 2023



Aim: This study was performed to compare two different rat defect models (critical calvaria defects versus guided bone regeneration in the mandibular ramus) used to evaluate bone repair in grafted areas. **Methods:** A total of 12 rats were allocated in two groups according the experimental model used to evaluate the bone repair in grafted areas: a critical sized-calvaria defect of 5 mm filled with bone graft (n=6) and a mandibular ramus filled with the bone graft associated with a Teflon dome-shaped membrane (n=6). Both groups were grafted with deproteinized bovine bone graft. After 60 days, the animals were euthanized and the samples obtained were submitted to histomorphometry analysis to evaluate the relative amount of bone, remaining bone substitute, and soft tissue within the grafted areas. **Results:** No differences were observed between the preclinical models evaluated in relation to the amount of bone tissue formation ($19.93 \pm 4.55\%$ in calvaria vs. $21.00 \pm 8.20\%$ in mandible). However, there was a smaller amount of soft tissue ($43.20 \pm 10.97\%$ vs. $57.79 \pm 7.61\%$; $p < 0.01$) and a greater amount of bone substitute remaining ($35.80 \pm 5.52\%$ vs. $22.28 \pm 4.36\%$; $p < 0.05$) in the grafted areas in the mandible compared to calvaria defect. **Conclusion:** Preclinical models for the analysis of bone repair in grafted areas in the mandible and critical sized-calvaria defects showed different responses in relation to the amount of soft tissue and bone substitute remnants.

Keywords: Animal experimentation. Bone regeneration. Bone substitutes. Histology.

Introduction

The bone is a tissue characterized by a constant remodeling that ensure the biomechanical maintenance and functional characteristics^{1,2}. Changes in the remodeling process induced by traumatic injuries, infectious diseases, or tumors can lead to the formation of critical defects that exceed the bone regenerative capacity^{2,4}. These defects can lead to the formation of niches that perpetuate inflammatory processes, loss of function, and aesthetic impairment, which can compromise the individual's social coexistence^{2,4}. Thus, the development of biomaterials that ensure the bone defect repair in a predictable way has become the focus of the scientific community^{5,6}.

Bone grafts or substitute biomaterials are commonly used as therapeutic strategies for filling and reconstructing large segments of bone defects^{6,7}. Among the materials proposed for bone reconstruction techniques, autografts are considered the gold standard due to their biological properties. However, the use of autografts is associated with some limitations, such as morbidity in the donor area, hemorrhages, increased surgical time, and loss of tissue volume in the grafted area, especially when used in particulate form⁸. In order to overcome these limitations, bone substitutes from other sources (e.g., xenografts; synthetic grafts) associated with bone guided regeneration techniques have been widely applied in order to allow adequate repair of the defect's areas^{9,10}.

The continuous emergence of new bone substitutes requires that preclinical studies be performed to evaluate the effectiveness of these materials prior to commercialization¹¹. Animal models for bone regeneration enable assessment of the biocompatibility and regenerative potential induced by different types of bone tissue substitutes¹². However, the myriad types of bone defects associated with their location, size, and sources of undifferentiated mesenchymal cells make it important to choose the type of experimental model closest with the clinical application of the tested bone substitute^{12,13}. Among the models applied, critical sized-calvaria defects are the most commonly used preclinical experimental model for the bone substitutes evaluation^{13,14}. This model is characterized by a rounded defect with a diameter sufficient to prevent spontaneous defect healing. In this way, the bone substitute is challenged in a biological healing condition that is difficult to resolve^{14,15}. Another experimental model used for bone substitutes evaluation is that made on the lateral face of the mandibular ramus in which the bone substitute is accommodated on a bone surface and isolated from neighboring tissues by a membrane, which mimics a clinical condition of guided bone regeneration commonly used in Dentistry^{16,17}.

The characterization of the potential of these models offers useful information for predicting the effectiveness of bone defects repair in humans. Therefore, the aim of this study was compare two different rat defect models (critical calvaria defects versus guided bone regeneration in the mandibular ramus) used to evaluate bone repair in grafted areas.

Material and methods

This study was approved by the Animal Use Ethics Committee of the Federal University of Uberlândia - UFU, Faculty of Dentistry of Uberlândia, Brazil (091/18). For this study, 12 rats, (*Rattus norvegicus*, Wistar variation), 3 months of age, weighing between 250–300 g, were used in an environment with controlled temperature ($21\pm 1^\circ\text{C}$), humidity (65–70%), and light cycles (12 hours). The animals were fed appropriate chow and water, offered *ad libitum*. This study was conducted in accordance with the ARRIVE protocol for conducting preclinical studies.

Groups

A total of 12 rats were randomly selected and divided in two types of defects: a critical sized-calvaria defect of 5 mm filled with bone graft (n=6) and a mandibular ramus defect filled with the bone graft associated with a Teflon dome-shaped membrane (n=6). The membrane was placed in contact with the bone tissue graft and fixed by sutures, allowing intimate contact with the mandibular bone. Both groups were grafted with deproteinized bovine bone graft.

Surgical procedure

After a week of acclimatization to the biotery environment, the animals were anesthetized by a combination of Ketamine with Xylazine, in the proportion of 8mg/kg of body mass (Ketamine Hydrochloride – Francotar – Virbac do Brasil Ind. Com. Ltda, São Paulo, Brazil) and 4mg /kg body mass (Xylazine Hydrochloride - Virbaxyl 2% - Virbac do Brasil Ind. E Com. Ltda. São Paulo, Brazil), respectively. Subsequently, the animals were submitted to trichotomy in the masseteric and submandibular region or in the calvaria, and antisepsis of the surgical field was performed with sterile gauze, soaked in a povidine solution.

The calvaria defect procedure was initiated by means of surgical access to the posterior portion of the calvaria through a bicoronal cutaneous and muscular incision, approximately 3 cm long, exposing the bone tissue. The tissues were divided until the periosteum was exposed, which was incised and displaced to expose the bone tissue. A rounded critical bone defect (5 mm in diameter and approximately 1.5 mm in thickness) was made in one of the parietal bones of the calvaria immediately after the apex of the coronal suture of the animal. The defects were made with the aid of a trephine bur (Neodent, Curitiba, Brazil) with an external diameter of 5 mm, mounted in a contra-angle (Anthogyr – Injecta – Diadema, Brazil) with a 16:1 reduction, coupled to a motor for implant installation (BML 600 Plus Driller - CK Driller – Carapicuíba, Brazil), at 1500 rpm, under constant irrigation with saline solution. Two circular perforations were made 2 mm from the margin of the defects and filled with gutta-percha to identify the half of the defect and guide the histological sections. The defect was filled with deproteinized bovine bone (Bio-Oss®, Geistlich AG, Wolhusen, Switzerland) (Figure 1). All defects were covered with the periosteum and sutured in planes; the periosteum with Vicryl 4.0 suture thread (Ethicon, Johnson Prod., São Paulo, SP, Brazil) and the skin tissue with 4.0 silk thread (Ethicon, Johnson Prod., São Paulo, SP, Brazil). The animals were treated in the postoperative period with a single dose of pentabiotic (Pentabiotic Veterinary Small, Zoetis Dodge,

São Paulo, Brazil, Subcutaneous: 0.03/g) and ketoprofen for 3 days (Ketoflex; Mundo Animal, São Paulo, Brazil, IM: 0.03ml/g).

For the guided bone regeneration model in mandibles, horizontal incisions were performed in the lower region of the mandible ramus and the muscle tissue was detached with the periosteum to expose the lateral face of the ascending ramus of the mandible. Four 0.5mm diameter perforations were performed using a spherical drill located parallel to the base of the mandible and 6mm apart, forming the edges of a square. A customized Teflon dome-shaped membrane, with an external diameter of 5mm, height of 2.5mm, and a peripheral collar of 1mm was inserted with its open portion against the lateral face of the mandible. The space of this capsule was filled with deproteinized bovine bone (Bio-Oss®, Geistlich AG, Wolhusen, Switzerland). After filling, the capsule was fixed to the mandible by sutures with 4.0 silk thread that crossed the capsule itself and the perforations made in the mandible ramus (Figure 1). Soft tissues were repositioned over the dome and sutured with 4.0 Vicryl thread. The post-operative medication used was the same as employed for the critical sized-calvaria defect surgical procedure. After 60 days of the surgical procedures, the animals were euthanized with an anesthetic overdose.

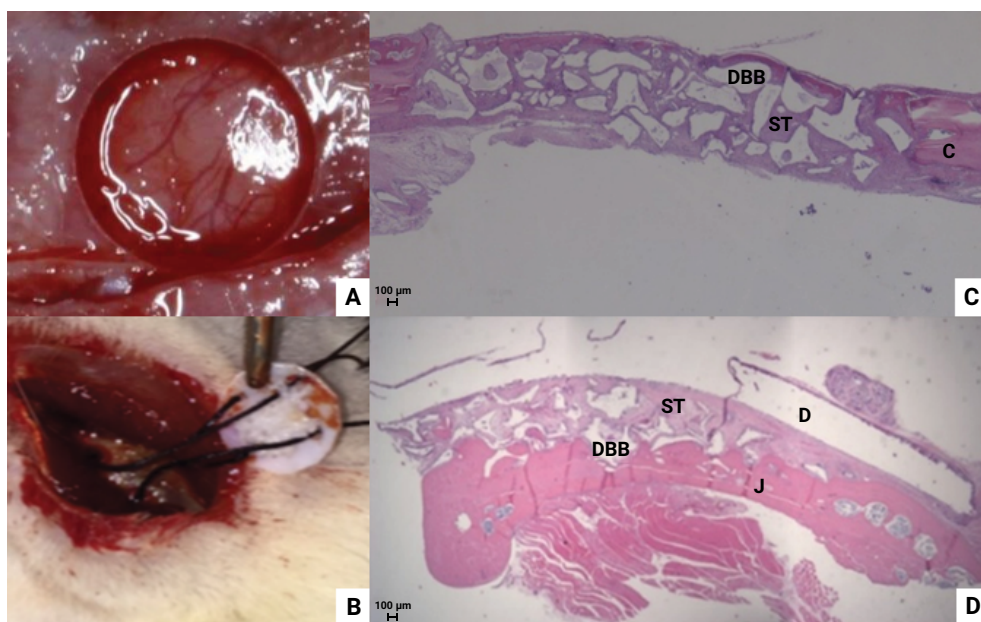


Figure 1. A-B represent the surgical procedures of the critical-sized calvaria defects and fixation of dome in the mandibular region, respectively. C-D histological aspect obtained in critical-sized calvaria defects and in guided bone regeneration model in the mandibular ramus after 60 days of grafting. DBB: Deproteinized Bovine Bone graft; ST: Soft Tissue; C: Calvaria; J: Jaw; D: Dome.

Histomorphometric analysis

Samples obtained from the calvaria and mandible were fixed in 4% paraformaldehyde for 48 hours and decalcified for 8 weeks in a 7% EDTA solution. After histological

processing, the specimens were sectioned in the central portion with a thickness of 5 μm and later stained using the hematoxylin and eosin technique. Three cuts were used for histometric analysis, with the first cut being drawn (from the first or second slide) and the second selected 40 μm away from the subsequent one. The slides were photographed using a DIASTAR optical microscope (Leica Reichert & Jung products, Wetzlar, Germany), with a 25x magnification objective, through which the images were captured and sent to a microcomputer (Leica Microsystems DFC-300-FX; Leica Reichert & Jung Products, Wetzlar, Germany). Measurements were made using image analyzer software (Image J, Jandel Scientific, San Rafael, CA, USA). The composition of the repaired tissue within the defects (bone, remaining bone substitute, and soft tissue) was evaluated and reported in percentage (%) values in relation to the total area involved in the grafting procedure.

Statistical analysis

Data from the histomorphometric analysis of this study were distributed according to normality as determined by the Kolmogorov-Smirnov test. The unpaired t-test was used to compare the histometric data from the areas grafted in the critical defects in the calvaria or in the lateral face of the rat mandibles. Graphpad Prism 6 software (San Diego, CA, USA) was used to perform the statistical tests. All tests were applied with a confidence level of 95%.

Results

The amount of newly formed bone obtained in the mandibular guided bone regeneration model was similar to that obtained in calvaria critical defects. However, the guided bone regeneration model in the mandible showed a higher amount of bone substitute remnants and a lower amount of soft tissue in comparison to calvaria critical defects ($p < 0.05$) (Table 1). In addition, a difference in the direction of bone formation was observed between the experimental models; newly formed bone was observed at the edges of the critical-sized calvaria defects and in the lateral portion of the mandible ramus in the guided bone regeneration model (Figure 2).

Table 1. Mean and standard deviation of data from the histomorphometric analysis in each experimental model

Histomorphometry	Calvaria	Mandible
Bone %	19.93 \pm 4.55	21.00 \pm 8.20
Bone substitute %	22.28 \pm 4.36	35.80 \pm 5.52*
Soft tissue %	57.79 \pm 7.61	43.20 \pm 10.97#

* $p < 0.05$ - Greater amount of bone substitute in guided bone regeneration model in the mandibular ramus than critical sized defect in calvaria model - Unpaired t-test;

$p < 0.05$ - Less soft tissue in guided bone regeneration model in the mandibular ramus than the critical sized defect in calvaria model - Unpaired t-test.

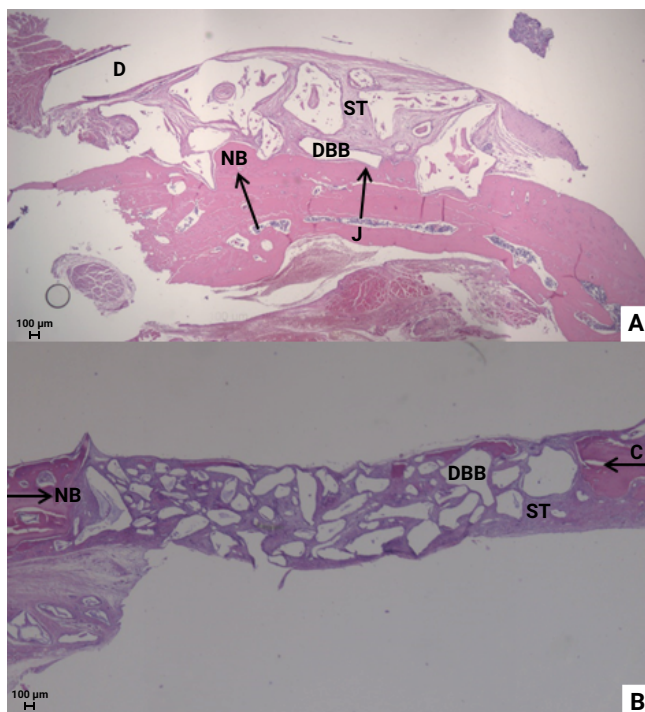


Figure 2. Histological images. A) Guided bone regeneration model in the mandibular ramus and B) critical-sized calvaria defect. Both preclinical models were tested to evaluate the bone repair in grafted areas with deproteinized bovine bone graft. The arrows represent the directions of bone formation. NB: New Bone. 25x.

Discussion

The aim of the present study was to compare two different preclinical rat models used to evaluate bone repair in grafted areas using histomorphometry analysis. The purpose of this analysis is to guide the future studies in the choice for the best evaluation method based on the indication of the material tested. In general, the results obtained showed that the models tested exhibit different repair manner. Although the newly formed bone was not different between the models tested, the location of the newly formed bone occurred in different regions. In addition, the calvaria model had a lower amount of remaining bone substitute and a higher amount of soft tissue when compared to the guided bone regeneration model in the mandible.

Concerning the bone formation direction, it was verified that in the critical sized-calvaria defects the bone neoformation occurred at the edges of the defect, moving towards the center of the defect, while in the guided bone regeneration model in the mandibular ramus, the bone formation occurred from the lateral face of the mandible to the top of the grafted area. This pattern of bone tissue formation has already been identified in previous preclinical studies^{17,18} and is due to the existence of a reservoir of undifferentiated mesenchymal cells in the mandibular bone, originating from the bone marrow.

As previously described, the guided bone regeneration procedures occur with the application of bone substitute in contact with the bone surface, isolated from the defects by a membrane^{19,20}. This differs from the critical-sized calvaria defects model in which the bone substitute is positioned on the brain tissue, separated from this tissue by the meninges. On this way, this model not represent a clinical situation where the objective is, for example, the installation of an implant in a graft area or the regeneration of a periodontal bone defect^{2,16}.

Regarding the amount of soft tissue and bone substitutes, a greater amount of soft tissue and less amount of bone substitute remnants were observed in critical-sized calvaria defects, especially in the center of the defects, due to the fact that bone substitutes are covered by soft tissue^{14,15,18}. As the area of undifferentiated mesenchymal cells sources in critical sized-calvaria defects is smaller in relation to the model of the mandible, and the distance of the biomaterial particles in the center of the critical defect is greater than the particles located on top of the grafted area in the model of the mandible^{17,18}, it is likely that this influences the osteoconduction of the materials and that there is detachment of bone substitutes in critical calvarial defects that end up being occupied by soft tissue.

An important methodological aspect regarding this study is the type of barrier used to isolate the calvaria defects from the scalp soft tissue. In this study, the periosteum was used to cover the calvaria defects since if this tissue is kept intact without cuts at this base, the periosteum presents potential to induce bone tissue formation similar to the use of resorbable membranes²¹. Comparing the use of different types of membranes, it was previous showed that the non-resorbable membranes induces more bone formation in empty calvaria defects compared with the non-resorbable membranes²², however, when the calvaria defects were grafted with a bone substitute the use of the non-resorbable membrane not provide more bone formation in these defects²³. Maybe the use of the non-resorbable membranes will be only useful in pre-clinical experimental model for bone regeneration research associated with non-self-contained defects as the guided bone regeneration model in mandible used in this study. This hypothesis may be more investigate in future.

The calvaria defect model proves to be very useful in the initial evaluation of new osteoinductive therapies with the intention to evaluate a bone substitute that stimulates bone formation by stimulating distant mesenchymal cells to differentiate into osteoblasts^{24,25}. This model is also useful for studies investigating biomaterials indicates for bone regeneration processes in critical defects in humans, where the bone substitute is expected to induce restful healing, accommodated under a soft tissue. Long bone fractures are example of critical defects in which large losses of substances occur, requiring the use of a ring-shaped periosteum-coated biomaterial capable of preserving a good part of the bone substitute in the margins of the material.

On the other hand, guided bone regeneration model in the mandible is indicated to evaluate conditions and characteristics of the bone neoformation process for the critical defects repair in the oral cavity. This model presents greater similarities to the clinical techniques used for the bone defects repair in the oral environment, where the biomaterial is maintained in contact with the edges of remaining bone tissue.

In conclusion, preclinical models for the analysis of bone repair in grafted areas in the mandible and critical sized-calvaria defects present different outcomes regarding to the amount of soft tissue and bone substitute remnants. These models can be indicated to evaluate the bone repair potential of different bone substitutes in different conditions.

Competing Interests

The authors have no relevant financial or non-financial interests to disclose

Author Contribution

Conceptualization: GJPLO and PBFS; Methodology: JRL, LSPG, and LRP; Formal analysis and investigation: GJPLO, PBFS, and SCP; Writing - original draft preparation: JRL, SCP, and GJPLO; Writing - review and editing: all the authors; Funding acquisition: GJPLO; Supervision: GJPLO.

Funding

This study was financed by the Brazilian agencies CNPq (Conselho Nacional de Desenvolvimento Científico e Tecnológico, 426954/2018-1), CAPES (Coordenação de Aperfeiçoamento de Pessoal de Nível Superior – Brasil – Finance Code 001), and FAPEMIG (Fundação de Apoio a Pesquisa do Estado de Minas Gerais - APQ-02211-21)

Data availability

The data of this study is available in the repository of the Universidade Federal de Uberlândia <https://repositorio.ufu.br/handle/123456789/32950>

References

1. Claes L, Recknagel S, Ignatius A. Fracture healing under healthy and inflammatory conditions. *Nat Rev Rheumatol*. 2012 Jan;8(3):133-43. doi: 10.1038/nrrheum.2012.1.
2. Sculean A, Stavropoulos A, Bosshardt DD. Self-regenerative capacity of intra-oral bone defects. *J Clin Periodontol*. 2019 Jun;46 Suppl 21:70-81. doi: 10.1111/jcpe.13075.
3. Grubor P, Milicevic S, Grubor M, Meccariello L. Treatment of bone defects in war wounds: retrospective study. *Med Arch*. 2015 Aug;69(4):260-4. doi: 10.5455/medarh.2015.69.260-264.
4. Chang EI, Hanasono MM. State-of-the-art reconstruction of midface and facial deformities. *J Surg Oncol*. 2016 Jun;113(8):962-70. doi: 10.1002/jso.24150.
5. Bohner M, Santoni BLG, Döbelin N. β -tricalcium phosphate for bone substitution: Synthesis and properties. *Acta Biomater*. 2020 Sep;113:23-41. doi: 10.1016/j.actbio.2020.06.022.
6. Valtanen RS, Yang YP, Gurtner GC, Maloney WJ, Lowenberg DW. Synthetic and bone tissue engineering graft substitutes: What is the future? *Injury*. 2021 Jun;52 Suppl 2:S72-S77. doi: 10.1016/j.injury.2020.07.040.
7. Busch A, Wegner A, Haversath M, Jäger M. Bone substitutes in orthopaedic surgery: current status and future perspectives. *Z Orthop Unfall*. 2021 Jun;159(3):304-13. doi: 10.1055/a-1073-8473.

8. Nkenke E, Neukam FW. Autogenous bone harvesting and grafting in advanced jaw resorption: morbidity, resorption and implant survival. *Eur J Oral Implantol*. 2014 Summer;7 Suppl 2:S203-17.
9. Pang KM, Um IW, Kim YK, Woo JM, Kim SM, Lee JH. Autogenous demineralized dentin matrix from extracted tooth for the augmentation of alveolar bone defect: a prospective randomized clinical trial in comparison with anorganic bovine bone. *Clin Oral Implants Res*. 2017 Jul;28(7):809-15. doi: 10.1111/clr.12885.
10. Oh JS, Seo YS, Lee GJ, You JS, Kim SG. A comparative study with biphasic calcium phosphate to deproteinized bovine bone in maxillary sinus augmentation: a prospective randomized and controlled clinical trial. *Int J Oral Maxillofac Implants*. 2019;34(1):233-42. doi: 10.11607/jomi.7116.
11. Bigham-Sadegh A, Oryan A. Selection of animal models for pre-clinical strategies in evaluating the fracture healing, bone graft substitutes and bone tissue regeneration and engineering. *Connect Tissue Res*. 2015 Jun;56(3):175-94. doi: 10.3109/03008207.2015.1027341.
12. Batool F, Strub M, Petit C, Bugueno IM, Bornert F, Clauss F, et al. Periodontal tissues, maxillary jaw bone, and tooth regeneration approaches: from animal models analyses to clinical applications. *Nanomaterials (Basel)*. 2018 May 16;8(5):337. doi: 10.3390/nano8050337.
13. Donos N, Dereka X, Mardas N. Experimental models for guided bone regeneration in healthy and medically compromised conditions. *Periodontol 2000*. 2015 Jun;68(1):99-121. doi: 10.1111/prd.12077.
14. Spicer PP, Kretlow JD, Young S, Jansen JA, Kasper FK, Mikos AG. Evaluation of bone regeneration using the rat critical size calvarial defect. *Nat Protoc*. 2012 Oct;7(10):1918-29. doi: 10.1038/nprot.2012.113.
15. Vajgel A, Mardas N, Farias BC, Petrie A, Cimões R, Donos N. A systematic review on the critical size defect model. *Clin Oral Implants Res*. 2014 Aug;25(8):879-93. doi: 10.1111/clr.12194.
16. Stavropoulos A, Sculean A, Bosshardt DD, Buser D, Klinge B. Pre-clinical in vivo models for the screening of bone biomaterials for oral/craniofacial indications: focus on small-animal models. *Periodontol 2000*. 2015 Jun;68(1):55-65. doi: 10.1111/prd.12065.
17. de Oliveira GJPL, Aroni MAT, Medeiros MC, Marcantonio E Jr, Marcantonio RAC. Effect of low-level laser therapy on the healing of sites grafted with coagulum, deproteinized bovine bone, and biphasic ceramic made of hydroxyapatite and β -tricalcium phosphate. In vivo study in rats. *Lasers Surg Med*. 2018 Aug;50(6):651-60. doi: 10.1002/lsm.22787.
18. Aroni MAT, de Oliveira GJPL, Spolidório LC, Andersen OZ, Foss M, Marcantonio RAC, et al. Loading deproteinized bovine bone with strontium enhances bone regeneration in rat calvarial critical size defects. *Clin Oral Investig*. 2019 Apr;23(4):1605-14. doi: 10.1007/s00784-018-2588-6.
19. Chappuis V, Rahman L, Buser R, Janner SFM, Belser UC, Buser D. Effectiveness of contour augmentation with guided bone regeneration: 10-year results. *J Dent Res*. 2018 Mar;97(3):266-74. doi: 10.1177/0022034517737755.
20. Benic GI, Eisner BM, Jung RE, Basler T, Schneider D, Hämmerle CHF. Hard tissue changes after guided bone regeneration of peri-implant defects comparing block versus particulate bone substitutes: 6-month results of a randomized controlled clinical trial. *Clin Oral Implants Res*. 2019 Oct;30(10):1016-26. doi: 10.1111/clr.13515.
21. Pinotti FE, Pimentel Lopes de Oliveira GJ, Scardueli CR, Costa de Medeiros M, Stavropoulos A, Chiérici Marcantonio RA. Use of a non-crosslinked collagen membrane during guided bone regeneration does not interfere with the bone regenerative capacity of the periosteum. *J Oral Maxillofac Surg*. 2018 Nov;76(11):2331.e1-2331.e10. doi: 10.1016/j.joms.2018.07.004.
22. Dupoirieux L, Pourquier D, Picot MC, Neves M. Comparative study of three different membranes for guided bone regeneration of rat cranial defects. *Int J Oral Maxillofac Surg*. 2001 Feb;30(1):58-62. doi: 10.1054/ijom.2000.0011.

23. Mardas N, Kostopoulos L, Karring T. Bone and suture regeneration in calvarial defects by e-PTFE-membranes and demineralized bone matrix and the impact on calvarial growth: an experimental study in the rat. *J Craniofac Surg.* 2002 May;13(3):453-62; discussion 462-4. doi: 10.1097/00001665-200205000-00017.
24. Fountain S, Windolf M, Henkel J, Tavakoli A, Schuetz MA, Hutmacher DW, et al. Monitoring healing progression and characterizing the mechanical environment in preclinical models for bone tissue engineering. *Tissue Eng Part B Rev.* 2016 Feb;22(1):47-57. doi: 10.1089/ten.TEB.2015.0123.
25. Zeiter S, Koschitzki K, Alini M, Jakob F, Rudert M, Herrmann M. Evaluation of preclinical models for the testing of bone tissue-engineered constructs. *Tissue Eng Part C Methods.* 2020 Feb;26(2):107-17. doi: 10.1089/ten.TEC.2019.0213.