

## ***Buchholzia coriacea* (wonderful kola) seeds induce male reproductive toxicity by suppressing the pituitary-gonadal axis in Wistar rats**

Olawale O. Obembe<sup>1</sup>\*

<sup>1</sup>Department of Physiology, College of Health Sciences, Osun State University, Osogbo, Nigeria

The methanolic extract of *Buchholzia coriacea* seeds (MEBC) has been reported to induce male reproductive toxicity by decreasing sperm parameters and fertility index. To elucidate the possible mechanism(s), the effects of graded doses of MEBC on sex hormones and sperm profile were investigated in this study. The MEBC (e.g., 50, 200, 400, and 600 mg/kg) was administered daily (p.o.) to male Wistar rats for 6 weeks, while a concurrent control group received distilled water (vehicle). Then, the animals were sacrificed under sodium pentobarbital anaesthesia. Weights of organs were recorded, and the sperm profile was determined microscopically. Testosterone, luteinizing hormone (LH), and follicle stimulating hormone (FSH) were assayed from the obtained serum using the ELISA technique. Sperm motility was significantly reduced by MEBC (i.e., 50 and 200 mg/kg), and sperm count reduced in all treated groups in a dose-dependent manner compared with that of the control. Serum testosterone, LH, and FSH decreased in treated rats. A histopathological examination of testes showed a considerable depletion and necrosis of the epithelium of seminiferous tubules. The result suggests that *Buchholzia coriacea* seeds induce male reproductive toxicity by suppressing the pituitary-gonadal axis.

**Keywords:** *Buchholzia* seeds. Antifertility. Sex hormones. Sperm toxicity.

### INTRODUCTION

*Buchholzia coriacea* Eng. (Capparaceae) is a forest tree, which is also known as musk tree; it was named after R.W. Buchholz, who collected the plant in Cameroon in the late 19<sup>th</sup> century (Keay, 1989). The tree is characterized by large brownish leaves that are leathery and glossy. The flowers are conspicuously large and cream-white in colour. The fruits are yellowish in colour, approximately 5 inches long and 2–3 inches in diameter, with few black seeds that are approximately 1 inch long. The seeds are edible and have a sharp and pungent smell with a hot spicy taste (Adisa, Choudharyb, Olorunsogo, 2011). The plant is widely distributed in West Africa, notably Guinea, Cameroon, Ivory Coast, Gabon, and Nigeria. It is a medicinal plant reputed for several biological activities such as abortifacient

and cytotoxic (Adjanohoun *et al.*, 1996), antihelmintic (Ajaiyeoba, Onocha, Olanrewaju, 2001), antimicrobial (Ezekiel, Onyeoziri, 2009), hypoglycemic (Adisa Choudharyb, Olorunsogo, 2011), and anti-inflammatory (Ezike, *et al.*, 2015) effects. The use of *Buchholzia* seeds in folkloric medicine over the past decades to treat various health issues earned the plant the pseudonym “Wonderful kola”. In Nigeria, its various other names include Oji ogwu, Okekpe, Owu, Omo, and Aponmu (Ezike *et al.*, 2015).

Despite its widely documented beneficial effects, there is a lack of knowledge on its effect on the male reproductive system. *Buchholzia coriacea* seeds are reported to have antibacterial and antimalarial (Mbata, Duru, Onwumelu, 2009; Okoli, Okere, Adeyemo, 2010) properties. Previous studies have suggested the induction of male infertility by medicinal plants with antibiotic and anti-malarial properties. For example, the anti-steroidogenic and anti-fertility action of anti-malarial agents [e.g., quinine (Sairam, 1978; Adeeko, Dada,

\*Correspondence: Olawale O. OBEMBE. Department of Physiology, College of Health Sciences, Osun State University, Osogbo, Nigeria. Phone: +2348033516858. E-mail: olawale.obembe@uniosun.edu.ng

1998), *Quassia amara* (Raji, Bolarinwa, 1997; Faisal *et al.*, 2006; Obembe, Olopade, Raji, 2014), *Alstonia boonei* (Raji, Salman, Akinsomisoye, 2005), *Azadirachta indica* (Rakiswende *et al.*, 2014), and *Gossypium herbaceum* (Arshiya, Khaleequr, Shafeequr, 2012)] is well-documented. Preliminary reports from our laboratory suggest the possible toxicity to male reproductive functions because a single daily dose of crude methanol extract (200 mg/kg bw) resulted in a considerable decline in sperm motility, semen volume, and caudal epididymal weight with a notable autolysis of epididymal sperm (Obembe, Onasanwo, Raji, 2012).

The phytochemical screening of *Buchholzia coriacea* seeds has shown that the seeds are rich in alkaloids, tannins, flavonoids, and saponins (Mbata, Duru, Onwumelu, 2009; Obiudu *et al.*, 2015). Many medicinal plants with antibacterial and anti-malarial properties, which have been reported to be rich in these phytochemicals, are also reputed to have antifertility actions (Gupta, Sharma, 2006). Therefore, it is imperative to examine the effects of graded doses of *B. coriacea* seeds on sex hormones as a probable mechanism of action of toxicity of these seeds on male reproductive physiology.

## MATERIAL AND METHODS

### *Buchholzia coriacea* seed extraction

The methanolic extract of *B. coriacea* seed (MEBC) was prepared according to the procedure described in (Obembe, Onasanwo, Raji, 2012). Fresh seeds of *B. coriacea* were obtained from a neighbourhood market and were authenticated at the herbarium of Forestry Research Institute of Nigeria (FRIN), Ibadan, Nigeria, where we had a specimen voucher number FHI 109920 previously assigned. The seeds were thoroughly washed with distilled water to remove adhering particles. Then, the seeds were sliced, shade dried, and pulverized. The powdered seeds (3.7 kg) were defatted by soaking in hexane (15 L) for 72 h. The hexane extract was obtained using a muslin bag after soaking the shaft in pure hexane for another 72 h. The extract was filtered using a Whatman paper (1 mm) and concentrated by a rotary evaporator (30 °C). This extract was further concentrated in a vacuum oven (30 °C, 700 mmHg). The obtained extract was air-dried for 3 h, and the extraction process was repeated using methanol. The weight of the obtained methanolic extract was determined, and the percent yield was calculated.

The extract was highly soluble in water. The extract was preserved in a refrigerator until use.

### Experimental animals

Twenty five adult male Wistar rats (180–200 g) were housed in well-ventilated wire mesh cages in the Animal House of the College of Health Sciences, Osun State University with constant 12 hour light - 12 hour dark cycle. The rats were fed standard rat chow and clean water *ad libitum* and were allowed ten days of acclimatization. All procedures in this study conformed to the guiding principles for research involving animals, as recommended by the Declaration of Helsinki and the Guiding principles in the care and use of animals (World Medical Association, American Physiological Society, 2002). All experiments were carried out in accordance with the National Institutes of Health Guide for Care and Use of Laboratory animals (National Research Council, National Academy of Sciences, 2011) and were approved by the Research Ethics Committee of the College of Health Sciences, Osun State University, Osogbo, Nigeria.

### Experimental design

The MEBC was administered (e.g., 50, 200, 400, and 600 mg/kg *b.w.*) daily using oral gavage (p.o.) to experimental rats (n=5) for 6 weeks, while the control group concurrently received the vehicle (distilled water, 0.3 mL) for the same duration. The doses of MEBC used were the same as those previously reported (Adisa, Choudharyb, Olorunsogo, 2011; Obembe, Onasanwo, Raji, 2012). At the end of the 6<sup>th</sup> week of treatment, all rats were sacrificed by cervical dislocation under sodium pentobarbital (30 mg/kg *i.p.*) anaesthesia. Reproductive organs (e.g., testis, epididymis, prostate, and seminal vesicle) and visceral organs (e.g., lungs, liver, heart, and kidney) were excised, cleared of fat and adhering tissues, then weighed using a digital weighing scale (EasyWay Medical, England). All excised organs for histological studies were preserved in Bouin's fluid for 6 h and then replaced with 10% formaldehyde.

### Sperm analysis

Sperm characteristics analysis was performed on sperm samples collected from the left caudal epididymis of rats. The prepared sperm solution was examined using an Olympus research microscope (Olympus, Japan). A

total of 5  $\mu$ L of diluted sperm solution was placed on a pre-warmed slide, and 2 drops of warm 2.9% sodium citrate was added. Progressive forward motility was examined immediately and scored to the nearest 10 (Morrissey *et al.*, 1988). Sperm viability was assessed using the eosin/nigrosin staining technique. Motile sperm remained unstained, while dead sperm were stained. On the basis of these observations, percentile viability was recorded. Sperm count was determined with the aid of improved Neubauer haemocytometer. The counting was performed in five Thoma chambers (Shi, Haug, 1990). Sperm volume was estimated by immersing the epididymis in 5 mL of normal saline in a measuring cylinder. The volume of fluid displaced was recorded as the sperm volume (Freund, Carol, 1964). Sperm morphology was assessed using a Walls and Ewa stain. The dried slides were examined under oil immersion. The morphologically defective sperm cells were counted in percentile (Wyrobek, Bruce, 1980).

### Hormone assay

Blood was collected from all rats after overnight fast and allowed to clot for 5 h on the bench prior to centrifugation at 3,000 rpm for 5 min. The obtained clear supernatant was decanted and stored at  $-20^{\circ}\text{C}$ . An enzyme-based immunoassay (EIA) technique was used to measure testosterone, luteinizing hormone (LH), and follicle stimulating hormone (FSH) in the serum samples. The EIA kits were obtained from Calbiotech Inc. (California, USA) and contained a respective EIA enzyme label, EIA substrate reagents, and an EIA quality control sample. Quality control was carried out at the beginning and at the end of the assay to ascertain acceptability with respect to bias and within batch variation. The testosterone kit used had a sensitivity of 0.075 ng/mL with intra and inter assay variations of 3.9% and 4.3%, respectively. The LH and FSH kits had a sensitivity of 0.12 and 0.353 mIU/mL and intra assay variations of 7.6% and 5.6%, respectively, while inter assay variations were 10.83% and 6.4%, respectively.

### Statistical analysis

The data were expressed as the mean  $\pm$  standard error of mean (SEM). Comparisons were made by Student's t-test and analysis of variance (ANOVA) using SPSS version 16 (SPSS Inc., Chicago, IL).  $P < 0.05$  was considered significant.

## RESULTS

### *Buchholzia coriacea* seed extract

The obtained MEBC was a honey-like jelly and weighed 202.22 g. The percentage yield was 5.47%.

### Organ weights

The data obtained in study showed that the MEBC at all doses administered did not affect the relative organ weights of the lungs, heart, kidney, epididymis, and prostate gland (Table I). However, the weight of the spleen and liver considerably decreased in groups that were administered 400 mg/kg and 600 mg/kg MEBC, respectively. The weight of testes and seminal vesicle decreased in all treatment groups compared to those of the control.

### Sperm profile and sex hormones

There was a considerable reduction in sperm motility and sperm count and a significant increase in the number of sperm cells with defective morphology when the treated rats were compared with the control. However, sperm viability and sperm volume were not affected (Table II). The MEBC caused a significant decline in the serum levels of testosterone, LH, and FSH compared to those of the control. The decline in serum LH and FSH levels was observed to be dose-dependent (Figure 1).

### Histology

Histopathological examination of the testes revealed a considerable decline in the rate of spermatogenesis because there were fewer spermatozoa and late stage spermatids. The ducts of seminiferous tubules were depleted or empty, and there was loss of spermatogenic epithelium (Figure 2). However, the examination of the prostate (Figure 3) and seminal vesicle (Figure 4) revealed no visible lesion, and the lumens of these organs were filled with secretions. In addition, histopathological examination of the visceral organs (e.g., lungs, kidney, and liver) revealed no visible lesion (Figure 5).

**TABLE I** – Relative organ weight (%) of MEBC-treated rats

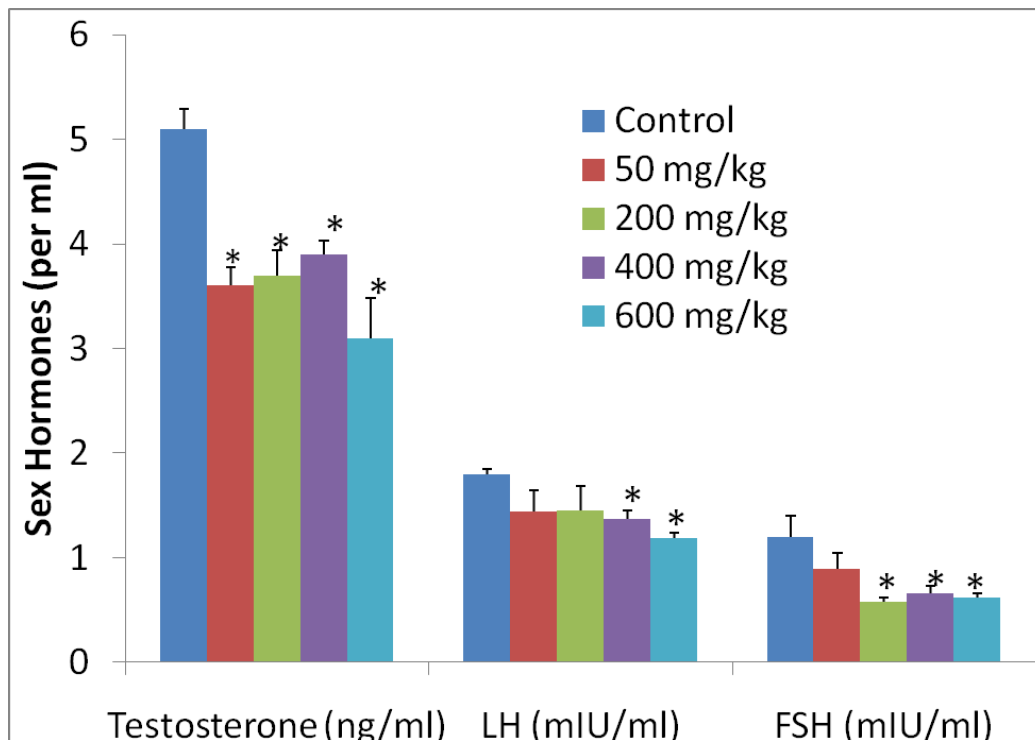
	Control	50 mg/kg MEBC	200 mg/kg MEBC	400 mg/kg MEBC	600 mg/kg MEBC
<b>Lungs</b>	0.95 ± 0.18	0.72 ± 0.04	0.70 ± 0.02	0.63 ± 0.03	0.55 ± 0.04
<b>Liver</b>	2.78 ± 0.09	2.63 ± 0.03	2.81 ± 0.11	2.73 ± 0.12	2.31 ± 0.08*
<b>Heart</b>	0.35 ± 0.01	0.31 ± 0.02	0.33 ± 0.03	0.32 ± 0.01	0.32 ± 0.02
<b>Kidney</b>	0.26 ± 0.01	0.25 ± 0.01	0.25 ± 0.01	0.28 ± 0.01	0.30 ± 0.01
<b>Spleen</b>	0.37 ± 0.02	0.34 ± 0.02	0.41 ± 0.03	0.30 ± 0.02*	0.32 ± 0.02
<b>Testes</b>	0.50 ± 0.01	0.45 ± 0.03	0.38 ± 0.03*	0.56 ± 0.03	0.54 ± 0.04
<b>Epididymis</b>	0.29 ± 0.05	0.29 ± 0.08	0.34 ± 0.14	0.27 ± 0.02	0.27 ± 0.02
<b>Seminal vesicle</b>	0.65 ± 0.07	0.70 ± 0.04	0.58 ± 0.02	0.34 ± 0.07*	0.30 ± 0.09*
<b>Prostate</b>	0.13 ± 0.01	0.16 ± 0.02	0.15 ± 0.03	0.16 ± 0.02	0.13 ± 0.01

The values are expressed as the mean ± SEM, n=5, \*p<0.05 indicates a significant difference from the control

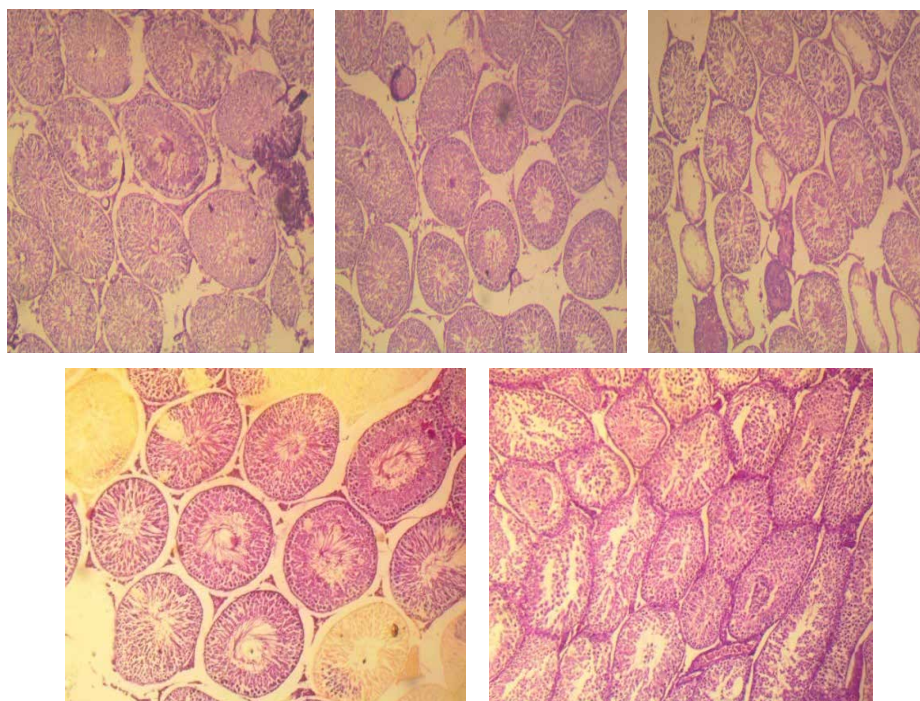
**TABLE II** – Sperm profile of MEBC-treated rats

	Control	50 mg/kg MEBC	200 mg/kg MEBC	400 mg/kg MEBC	600 mg/kg MEBC
<b>Sperm motility (%)</b>	93.0 ± 1.2	74.0 ± 2.5*	64.0 ± 2.5*	68.0 ± 2.0	72.0 ± 2.0
<b>Sperm viability (%)</b>	98.0 ± 0	96.8 ± 0.7	93.6 ± 2.2	96.2 ± 0.7	96.2 ± 0.7
<b>Sperm volume (mL)</b>	5.18 ± 0.02	5.18 ± 0.02	5.20 ± 0.00	5.16 ± 0.02	5.18 ± 0.02
<b>Sperm count (million/mL)</b>	129.6 ± 5.3	109.8 ± 6.0	98.4 ± 5.6*	97.4 ± 3.0*	92.2 ± 4.2*
<b>Abnormal morphology (%)</b>	11.9 ± 0.5	13.6 ± 0.2*	13.18 ± 0.6	13.06 ± 0.45	13.03 ± 0.28

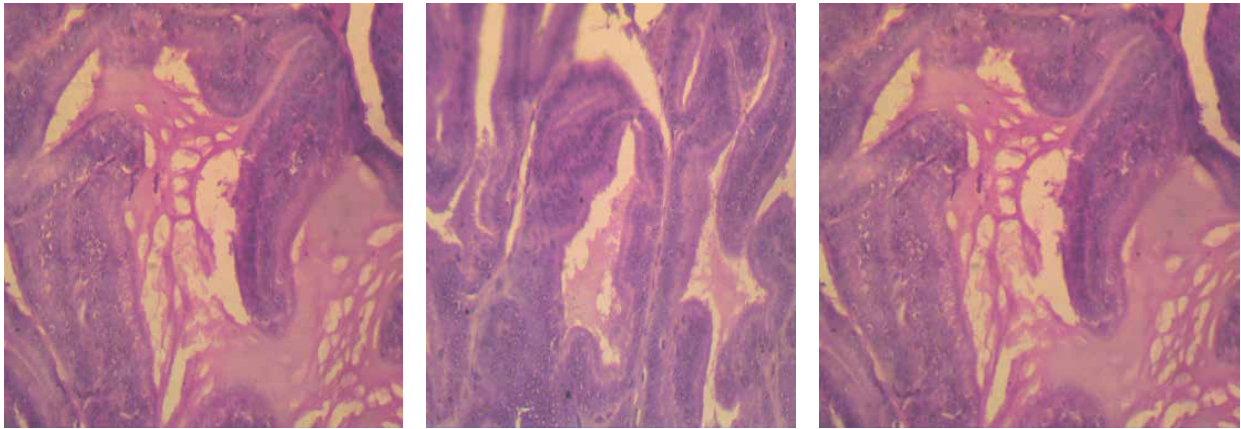
The values are expressed as the mean ± SEM, n=5, \*P<0.05 indicates a significant difference from the control



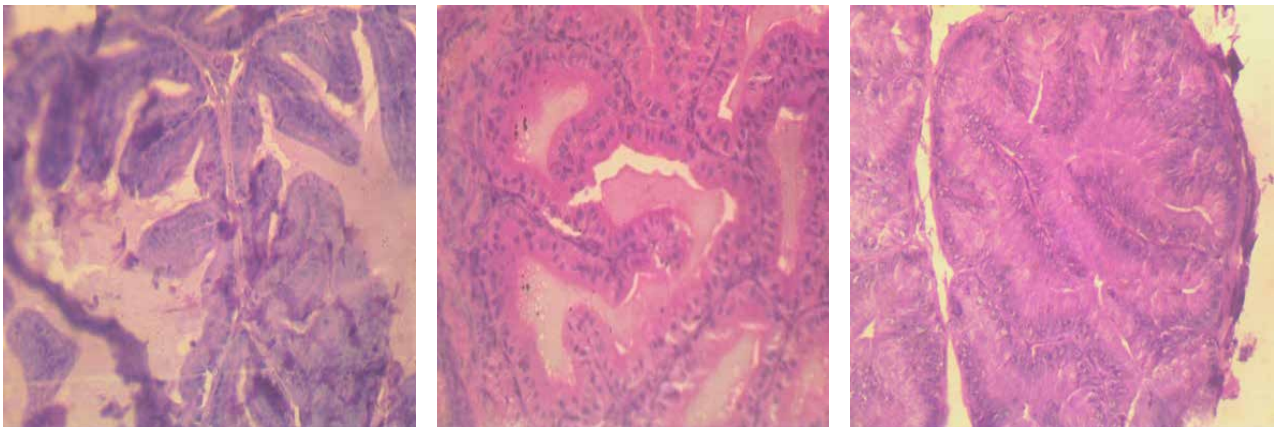
**FIGURE 1** – Sex hormones of MEBC-treated rats. \*P<0.05 indicates a significant difference from the control.



**FIGURE 2** – Transverse sections through the testis of rats treated with: vehicle (A), 50, 200, 400, and 600 mg/kg MEBC (B–E, respectively). Arrows indicate seminiferous tubules with considerable depletion, necrosis, and loss of spermatogenic epithelium in treated rats (100× magnification).

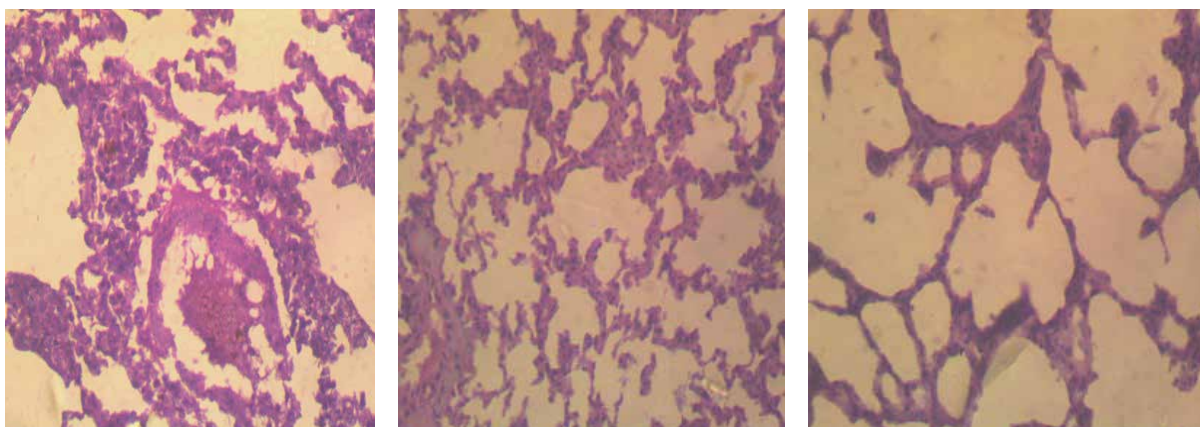


**FIGURE 3** – Transverse sections through the prostate of the control (A), rats treated with 50 mg/kg MEBC (B), and 200 mg/kg MEBC (C). Prostatic epithelium shows no visible lesion compared to that of the control. The lumens are filled with secretion (100× magnification).



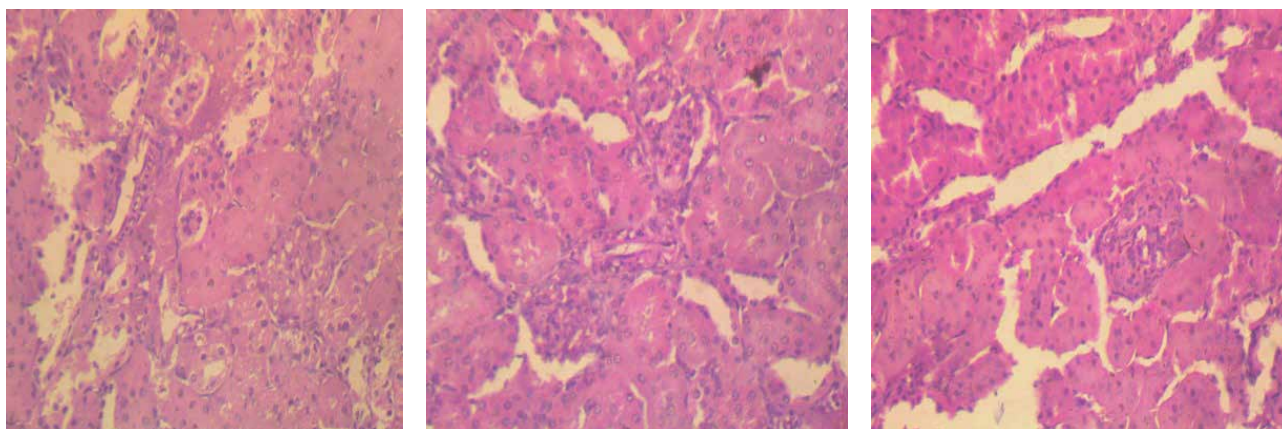
**FIGURE 4** – Transverse sections through the seminal vesicle of the control (A), rats treated with 50 mg/kg MEBC (B), and 200 mg/kg MEBC (C). All epithelial infoldings appear normal and show no visible lesion. In addition, secretions are present in the lumens (100× magnification).

**A**



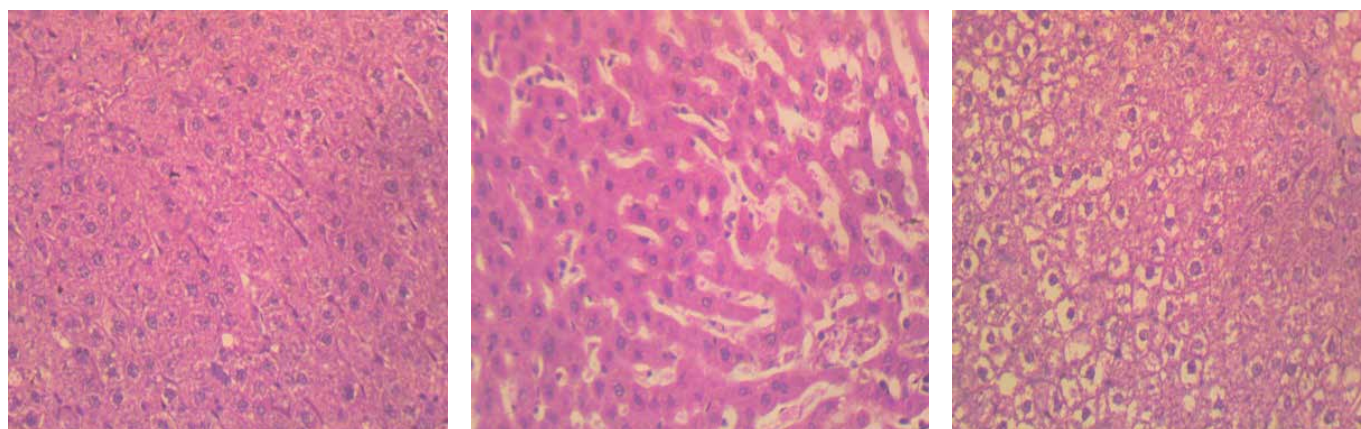
Transverse sections through the lungs of the control (1), rats treated with 50 mg/kg MEBC (2), and 200 mg/kg MEBC (3). No visible lesion was observed (100× magnification).

**B**



Transverse sections through the kidneys of the control (1), rats treated with 50 mg/kg MEBC (2), and 200 mg/kg MEBC (3). No visible lesion was observed (100× magnification).

**C**



Transverse section through the liver of the control (1), rats treated with 50 mg/kg MEBC (2), and 200 mg/kg MEBC (3). No visible lesion was observed (100× magnification).

**FIGURE 5** – Histology of Visceral Organs. A- Lungs, B- Kidney, C- Liver.

## DISCUSSION

The regulation of spermatogenesis involves both endocrine and paracrine mechanisms (De Kretser *et al.*, 1998). The endocrine regulation involves testosterone, luteinizing hormone (LH), and follicle stimulating hormone (FSH). Factors that interfere with the production, release, transport, metabolism, binding, action, or elimination of these hormones in the body may impact the process of spermatogenesis, which may manifest as abnormal sperm physiology and male infertility (Meeker, Godfrey-Bailey, Hauser, 2007).

The induction of male infertility in many experimental animals owing to the treatment with medicinal plants and their products has attracted the attention of researchers. In our preliminary findings, we reported a possible toxicity of the MEBC to male reproductive physiology in rats (Obembe, Onasanwo, Raji, 2012). However, in this study, a possible mechanism of the MEBC was investigated using graded doses of the seed extract. Testosterone was observed to decline in all MEBC-treated rats compared with that in the control (Figure 1). The observed decline in testosterone probably accounts for the observed decrease in sperm count (Table II). In a study on the relationship between serum hormone levels and semen quality, a positive correlation between serum testosterone level and sperm count has been reported (Meeker, Godfrey-Bailey, Hauser, 2007).

Male sex steroid testosterone is synthesized in the Leydig cells of the testes under the influence of LH from the anterior pituitary (Leung, Wong, 2013). The MEBC caused a reduction in the serum levels of gonadotropic hormones LH and FSH, and this reduction was dose-dependent. Thus, the MEBC had an inhibitory effect on the secretory capability of the gonadotropes located in the anterior pituitary gland. Therefore, it is possible that the observed decline in testosterone recorded in this study occurs owing to the decline in LH. FSH has been documented to be required for the determination of sertoli cell number and for the induction and maintenance of normal sperm production (Simoni, *et al.*, 1999). In addition, it is the prime inducer of spermatogonial proliferation. The reduction or elimination of the FSH action completely suppresses spermatogenesis. A decrease in FSH observed in this study is most likely responsible for the decrease in sperm count recorded when the MEBC-treated rats were compared with the control. In a study on the role of FSH in male gonadal function, Simoni *et al.* (1999)

concluded that the combination of FSH and testosterone at physiological levels is a prerequisite for qualitative and quantitative normal spermatogenesis. Therefore, the debilitating effects of the MEBC on sex hormones and sperm count show that *B. coriacea* seeds interfered with testicular spermatogenesis. This is corroborated by the depletion of seminiferous tubules and loss of spermatogenic epithelium (Figure 2).

Sperm acquire capability for motility in the epididymis, and typically, all caudal epididymal sperm are motile (Zhou *et al.*, 2008). A decline in the observed sperm motility in MEBC-treated rats suggests that the MEBC exhibited a toxic effect on the epididymis. Even though in this study no effect was observed on the total epididymal weight, we previously reported a reduction in the caudal epididymal weight and derangement of epididymal epithelium in MEBC-treated rats (Obembe, Onasanwo, Raji, 2012). A decrease in the serum testosterone level may not account for the observed decline in sperm motility because the correlation between serum testosterone level and sperm motility of infertile men have been reported (Meeker, Godfrey-Bailey, Hauser, 2007). Serum testosterone level has been reported to have no correlation with sperm motility, concentration, pH, and morphology in buffalo bulls (Sajjad *et al.*, 2007). Similarly, Novero *et al.* (1997) reported the lack of any relationship between human serum FSH concentration and sperm motility and morphology.

Adisa, Choudharyb, and Olorunsogo (2011) reported the hypoglycemic activity of *Buchholzia* seeds, and the authors proposed a possible hepatoprotective property and capability to attenuate streptozotocin-induced hepatic and renal damage. The lack of effect of the MEBC on weights of visceral organs, especially at low doses, and the lack of any visible detrimental effect on the histopathology of these organs (Figures 3–5) may suggest the lack of adverse effects on these organs. The MEBC at doses administered clearly had a toxic effect that was limited to the male reproductive physiology and, therefore, had an antifertility effect that is mediated through the pituitary-gonadal axis.

In conclusion, this study showed that *Buchholzia coriacea* seeds induced male reproductive toxicity via the suppression of the hormones of the pituitary-gonadal axis. Because male infertility and male contraception can be regarded to be the same, the negative effects of *B. coriacea* seeds may be further studied to determine whether these seeds can be used as a possible male contraceptive agent.



## ACKNOWLEDGEMENTS

The assistance of Mr. Ejiro with the assessment of sperm profile and Mr. Salisu for the assay of hormones is highly appreciated.

## CONFLICT OF INTEREST

Authors declare no conflict of interest

## REFERENCES

- Adeeko AO, Dada OA. Chloroquine reduces fertility capacity of epididymal sperm in rats. *Afri J Med Sci*. 1998;27(1-2): 63-68.
- Adisa RA, Choudharyb MI, Olorunsogo OO. Hypoglycemic activity of *Buchholzia coriacea* (Capparaceae) seeds in streptozotocin-induced diabetic rats and mice. *Elsevier Gmbh, Exp Toxicol Pathol*. 2011;63(7-8):619-625.
- Adjahoun JE, Aboubakar N, Dramane K, Ebot ME, Ekpere JA, Enoworock EG et al. Organization of African Unity; Scientific, Technical and Research Commission, editor. Contribution to ethno botanical and floristic studies in Cameroon. *Trad Med Pharmacopoeia* 1996.
- Ajaiyeoba EO, Onocha PA, Olanrewaju OT. In vitro anti-helminthic properties of *Buchholzia coriacea* and *Gynandropsis gynandra*. *Pharm Biol*. 2001;39(3):217-20.
- Arshiya S, Khaleequr R, Shafeequr R. *Gossypium herbaceum* Linn: An ethnopharmacological review. *J Pharm Sci Inn*. 2012;1(5):1-5.
- De Kretser DM, Loveland KL, Meinhardt A, Simorangkir D, Wreford N. *Spermatogenesis* 1998;13(1):1-8.
- Ezekiel OO, Onyeoziri NF. Preliminary studies on the antimicrobial properties of *Buchholziacoriacea*. *Afr J Biotechnol*. 2009;8(3):472-474.
- Ezike AC, Onyeto CA, Nwabunike IA, Mbaoji FN, Attah BE, Amanambu SO et al. Anti-inflammatory activity of *Bulchhozia coriacea* Engl. Leaf extract: evaluation of components of inflammatory response involved. *J Complement Ingr Med*. 2015;12(2):153-158.
- Faisal K, Parveen S, Rajendran R, Girija R, Periasamy VS, Kadalmani B et al. Male reproductive toxic effect of *Quassia amara*: Observation on mouse sperm. *J Endocr Reprod*. 2006;10(1):66-69.
- Freund M, Carol B. Factors affecting haemocytometer count of sperm concentration in human semen. *J Reprod Fertil*. 1964;8:149-155.
- Gupta RS, Sharma R. A review on medicinal plants exhibiting antifertility activity in males. *Nat Prod Rad*. 2006;5(5):389-410.
- Keay RWJ. *Trees of Nigeria*, Clarendon press, Oxford, 1989.
- Leung KW, Wong AST. Ginseng and male reproductive function. *Spermatogenesis* 2013; 3(3): e26391 doi: 10.4161/spmg.26391
- Mbata TI, Duru CM, Onwumelu HA. Antibacterial activity of crude seed extract of *Buchholzia Coriacea* E. on some pathogenic bacteria. *J Dev Biol Tissue Eng*. 2009;1(1):1-5.
- Meeker JD, Godfrey-Bailey L, Hauser R. Relationship between serum hormone levels and semen quality among men from an infertility clinic. *J Androl*. 2007;28(3):397-406.
- Morrissey RE, Schwetz BA, Lamb JC, Ross MD, Teague JL, Morris RW. Evaluation of rodent sperm, vaginal cytology, and reproductive organ weight data from National Toxicology Program 13-week studies. *Fundam Appl Toxicol*. 1988;11(2):343-58.
- National Research Council, National Academy of Sciences. Guide for care and use of laboratory animals, eighth ed., The National Academics Press, Washington DC, USA; 2011.
- Novero V, Camus M, Tournaye H, Smits J, Verheyen G, Joris H et al. Relationship between serum follicle stimulating hormone in the male and standard sperm parameters, and the results of intracytoplasmic sperm injection. *Hum Reprod*. 1997;12(1):59-63.
- Obembe OO, Olopade JO, Raji Y. Implication of HongrES1 protein in quassin-induced male reproductive abnormality in rats. *Endocr Metab Syndrome* 2014;3(2):128 doi:10.4172/2161-1017.1000128
- Obembe OO, Onasanwo SA, Raji Y. Preliminary study on the effects of *Buchholzia coriacea* seed extract on male reproductive parameters in rats. *Niger J Physiol Sci*. 2012;27:165-169.
- Obiudu IK, Okolie AC, Agbafor KN, Unaegbu ME, Engwa GA, Obiudu CV. Anti-diabetic property and phytochemical composition of aqueous and methanol extracts of *buchholzia coriacea* seeds in alloxan-induced diabetic rats. *J Med Sci*. 2015;15(5):241-245.
- Okoli BJ, Okere OS, Adeyemo SO. The antiplasmodic activity of *Buchholzia Coriacea*. *J Med Appl Biosci*. 2010;2:21-29.

- Raji Y, Bolarinwa AF. Antifertility activity of *Quassia amara* in male rats: in vivo study. *Life Sci.* 1997;61(11):1067-1074.
- Raji Y, Salman TM, Akinsomisoye OS. Reproductive functions of male rats treated with methanolic extract of *Alstonia boonei* stem bark. *Afri J Biom Res.* 2005;8:105-111.
- Rakiswende SY, Leonardo L, Robert KO, Dari FD, Franck AY, Koudraogo BY. Transmission blocking activity of *Azadirachta indica* and *Guiera senegalensis* extracts on the sporogonic development of *Plasmodium falciparum* field isolates of *Anopheles coluzzii* mosquitoes. *Par Vect.* 2014;7:185.
- Sairam MR. Drug effects on luteinizing hormone-releasing hormone action. In: K.W. McKerns (ed). *Structure and function of gonadotrophins*. New York: Plenum Press; 1978. p. 275-294.
- Sajjad M, Ali S, Ullah N, Anwar M, Akhter S, Andrabi SMH. Blood serum testosterone level and its relationship with scrotal circumference and semen characteristics in Nili-Ravi Buffalo bulls. *Pakistan Vet J.* 2007;27(2):63-66.
- Shi B, Haug A. Aluminum uptake by neuroblastoma cells. *J Neurochem.* 1990;55(2):551-558.
- Simoni M, Weinbauer GF, Gromoll J, Nieschlag E. Role of FSH in male gonadal function. *Ann Endocr.* 1999;60(2): 102-106.
- World Medical Association, American Physiological Society. Guiding principles for research involving animals and human beings. *Am J Physiol Regul Integr Comp physiol.* 2002;283:R281-R283.
- Wyrobek AJ, Bruce WR. The induction of sperm shape abnormalities in mice and humans. In: Hollaender A; De Serres FJ. *Chem Mutagens Vol. 5*. New York: Plenum Press; 1980 p. 257-285.
- Zhou Y, Zheng M, Shi Q, Zhang L, Zhen W, Chen W et al. An Epididymis-Specific Secretory Protein *HongrES1* Critically Regulates Sperm Capacitation and Male Fertility. *PLoS ONE* 2008; 3(12): e4106.

Received for publication on 12<sup>nd</sup> January 2018

Accepted for publication on 27<sup>th</sup> August 2019