




# Simultaneous Kidney Transplantation and Abdominoplasty in a Prune-Belly Syndrome Patient

André Barcelos da Silva<sup>1</sup> , Guilherme Alonso Daud Patavino<sup>2</sup> , Miguel Bonfitto<sup>2,\*</sup> , Wilson Ferreira Aguiar<sup>2</sup> , Renato Demarchi Foresto<sup>2</sup> , Helio Tedesco-Silva<sup>2</sup> , José Medina Pestana<sup>2</sup> 

1.Universidade Federal de São Paulo  – Departamento de Urologia – São Paulo/SP – Brazil. 2.Hospital do Rim e Hipertensão  – Fundação Oswaldo Ramos  – São Paulo/SP – Brazil.

\*Corresponding author: [rdforesto@gmail.com](mailto:rdforesto@gmail.com)

Section editor: Ilka de Fátima Santana F Boin 

Received: June 10, 2023 | Accepted: July 28, 2023

How to cite: Silva AB, Patavino GAD, Bonfitto M, Aguiar WF, Foresto RD, Tedesco-Silva H, Pestana JM. Simultaneous Kidney Transplantation and Abdominoplasty in a Prune-Belly Syndrome Patient. BJT. 2023.26 (01):e2823. [https://doi.org/10.53855/bjt.v26i1.519\\_ENG](https://doi.org/10.53855/bjt.v26i1.519_ENG)

## ABSTRACT

Simultaneous correction of the abdominal wall defect during kidney transplantation in a patient with Prune-Belly Syndrome (PBS) was not described yet. The abdominoplasty is postponed because the concomitant approach would result in greater complexity to the procedure and increase the surgical risk. We report a 14-year-old male patient with PBS submitted to simultaneous kidney transplantation and abdominoplasty, describing the steps of the surgery. This approach is feasible and promotes functional improvement of the abdomen, minimizing potential damage and costs of future approaches, and provides a better quality of life.

Descriptors: Prune Belly Syndrome; Kidney Transplantation; Abdominal Wall.

## *Transplante Renal e Abdominoplastia Simultâneos em um Paciente com Síndrome de Prune-Belly*

## RESUMO

A correção simultânea do defeito da parede abdominal durante o transplante renal em um paciente com síndrome de Prune-Belly (SPB) ainda não foi descrita. A abdominoplastia é adiada, pois a abordagem concomitante resultaria em maior complexidade do procedimento e aumentaria o risco de complicações cirúrgicas. Relatamos, caso de paciente do sexo masculino, 14 anos, apresentando SPB, e submetido ao transplante renal e abdominoplastia simultaneamente, sendo descrito os passos da cirurgia. Essa abordagem é viável e promove melhora funcional do abdome, minimizando possíveis danos e custos de futuras abordagens cirúrgicas, além de proporcionar melhor qualidade de vida.

Descritores: Síndrome de Prune Belly; Transplante de Rim; Parede Abdominal.

## INTRODUCTION

Prune-Belly Syndrome (PBS), or Eagle-Barrett Syndrome, is a congenital disorder composed of the triad: abdominal hypoplasia, bilateral cryptorchidism, and urinary tract malformations such as renal dysplasia, megaureter, megabladder, urethral malformations, and hydronephrosis. It may also present changes in the gastrointestinal, cardiopulmonary, and musculoskeletal tracts.<sup>1,2</sup> It affects mostly male patients, with an incidence of 3.8:100,000.<sup>3</sup>

Urinary tract alterations predispose to recurrent infectious and obstructive conditions. The evolution of the disease to chronic kidney disease is the leading cause of morbidity and mortality, where 40% of patients need renal replacement therapy. Kidney transplantation

is a treatment that promotes gains in survival and quality of life in these cases, with outcomes similar to the general transplant population, despite the adverse clinical conditions in this syndrome.<sup>3,4</sup>

Abdominal weakness is also a component of potential systemic repercussions in these patients. The reduction in abdominal contraction contributes to bladder, respiratory and intestinal dysfunctions. Correction at the right time, using abdominoplasty, promotes functional and esthetic improvement, directly impacting the patient's quality of life.<sup>5,6</sup>

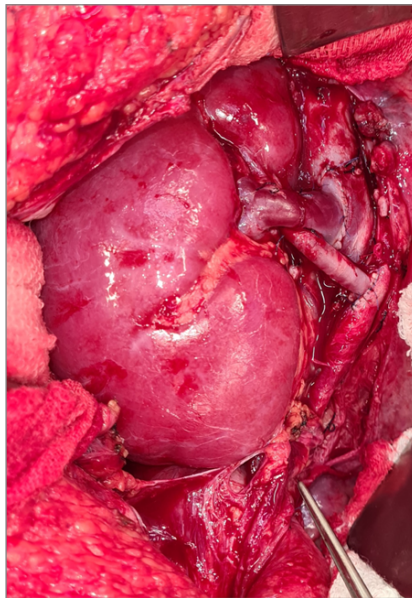
Here, we will present the clinical and surgical outcomes of a patient with PBS undergoing kidney transplantation and abdominoplasty during a single surgical procedure.

## CASE REPORT

A 14-year-old male patient was evaluated for a deceased donor kidney transplantation. He was diagnosed with SPB and an atrophic right kidney at birth. At eight months of age, he was admitted for urinary tract infection and renal dysfunction, diagnosed with a posterior urethral valve, and a bypass with bilateral ureterostomy was performed. At the age of 6, he reconstructed the urinary tract with ureteral reimplantation, valve fulguration, and bilateral orchidopexy. Serum creatinine remained stable until age 11, when he presented two more infectious conditions with impaired renal function and the need for renal replacement therapy.

In the pre-transplant clinical evaluation, flaccidity and fragility of the abdominal wall were observed, with a median scar above and below the umbilical region. The care team, the patient, and his parents discussed and accepted the decision to simultaneously perform the kidney transplantation and abdominoplasty. After two years on the waiting list, the patient was called for the kidney transplant with a deceased donor.

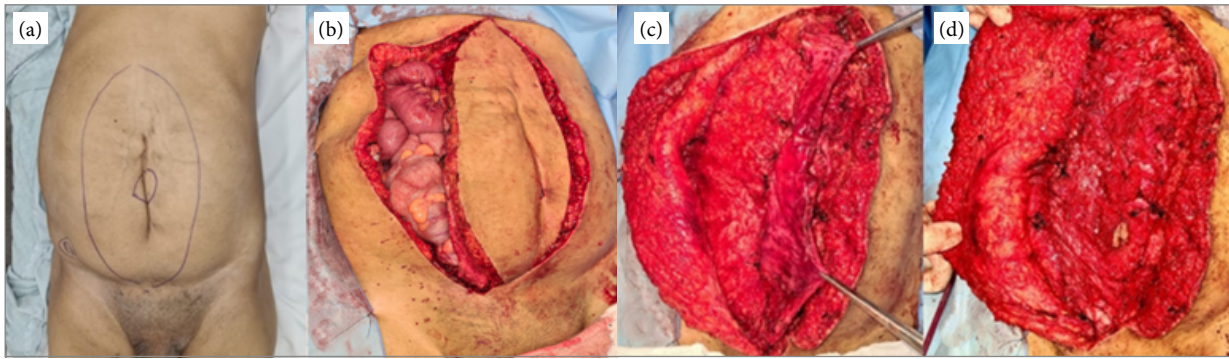
A right renal graft with single vessels and a ureter was used for transplantation. The skin of the abdomen was demarcated in an ellipse shape to limit the area of skin resection for closure. The initial abdominal incision was made on the right margin. Due to the intense abdominal adhesion caused by previous surgeries, transperitoneal access was necessary to expose the vessels and bladder. Vascular anastomoses were performed in the inferior vena cava and common iliac artery, with an end-to-side format (Fig. 1). The Lich-Gregoir technique was used for the ureteral implant without a ureteral catheter. In the end, a drain was maintained in a graft shop.



Source: Elaborated by the authors.

**Figure 1.** Renal graft with anastomosis in the vena cava and common iliac artery.

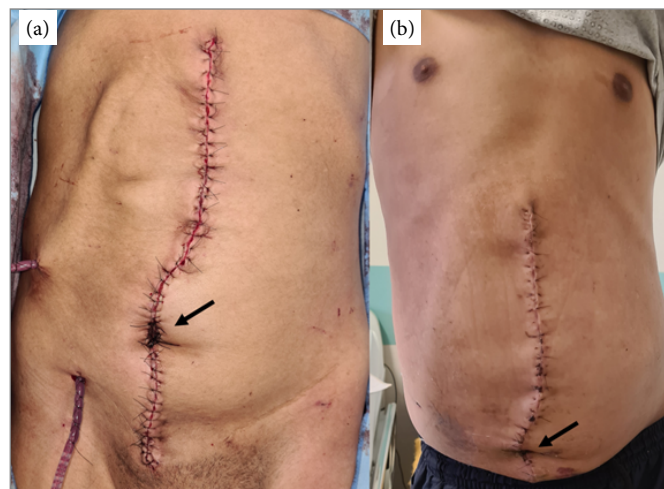
For the synthesis of the abdominal wall, the modified Montfort technique was used (Fig. 2). First, excess skin was resected, preserving the umbilical scar. Next, the opening of the muscle fascia of the incision was widened to the level of the xiphoid appendix, followed by the imbrication of the edges, fixing the smaller musculoaponeurotic portion below the contralateral portion. To avoid seroma in the detachment area, the subcutaneous tissue was fixed to the aponeurosis with PDS 3-0 threads, and a drain was maintained in the subcutaneous tissue for 7 days. Another drain was left close to the graft and removed in 5 days (Fig. 3). The approximate total surgery time (abdominoplasty + transplant) was 4 hours. The patient had no complications from the surgical wound.



Source: Elaborated by the authors.

**Figure 2.** Ellipse-shaped demarcation (A). Extension of the aponeurosis to the lateral portion of the abdomen (B). External fascia folded over the internal muscular fascia (C). Preparation of a double muscle layer (D).

After surgery, the patient was referred to the Intensive Care Unit due to monitoring blood pressure with vasoactive drugs. He was transferred to the ward on the second postoperative day and remained hospitalized until the 17<sup>th</sup> day. He evolved with adynamic ileus during hospitalization, which was resolved through clinical measures. At follow-up, he has satisfactory graft function and esthetic results (Fig. 3).



Source: Elaborated by the authors.

**Figure 3.** Results on 1<sup>st</sup> (A) and 17<sup>th</sup> (B) postoperative day after kidney transplantation and abdominoplasty. The arrows show the umbilical preservation.

## DISCUSSION

Since the first kidney transplantation in a patient with PBS in 1976, there has been no record of simultaneous correction of the abdominal wall defect during the same procedure. When not performed previously, this step is postponed because the concomitant approach would result in greater complexity to the procedure and increase the surgical risk.<sup>7</sup> However, there are reports of graft loss related to changes in the abdominal wall in these patients.

Following the principles of Laplace's Law, where there is a correlation between pressure, tension, and radius measurement of structures, an abdomen with preserved musculature has a better intracavitary pressure distribution. Such pressure contributes to satisfactory bladder emptying in patients with associated bladder dysfunction.

The heterogeneous manifestation of the syndrome makes each case unique<sup>4</sup> and challenging, limiting the standardization of procedures for patients with PBS. In addition, the involvement of the abdominal wall has a spectral presentation, which can vary from a simple weakness to loss of muscle mass or total absence of abdominal muscles. Thus, preoperative evaluation is essential for surgical planning and post-transplant follow-up.

Individuals with PBS undergo numerous surgical procedures to correct congenital anomalies. Multiple approaches determine intra-abdominal adhesions, with difficult access to the retroperitoneum during transplantation. In these cases, the transperitoneal route is more feasible, but there is a greater risk of torsion of the renal hilum due to graft mobility when the kidney is positioned

inside the peritoneum. In the case described, the patient had a history of orchidopexy and bilateral ureteral reimplantation during childhood, but without correcting the aponeurotic defect.<sup>3</sup> Therefore, the transperitoneal access route to the iliac vessels for anastomosis was necessary, with care in positioning the graft at the end of the procedure.

Among the possibilities of abdominal closure, the Montfort technique, which initially uses the vertical folding of the fascia to reinforce the abdominal wall, was modified by Denés through a single incision in the fascia, allowing abdominoplasty to be performed with reinforcement of the anterior abdominal wall.<sup>8-10</sup> Another alternative would be the Randolph technique, which proposes vertical correction of the redundancy of the skin and infra-umbilical fascia without removing the lateral portion.

This patient had an excellent postoperative evolution, with a high functional and esthetic satisfaction level. We believe that when adequately indicated, being in a highly complex service and with a trained surgical team, the proposed surgical approach becomes feasible, with the patient and their guardians aware of the inherent risks.

## CONCLUSION

Simultaneous abdominoplasty with kidney transplantation is feasible and promotes functional and aesthetic improvement of the abdomen, minimizing potential damage and costs of future approaches and providing a high patient satisfaction rate.

## CONFLICT OF INTEREST

Nothing to declare.

## AUTHORS' CONTRIBUTION

**Substantive scientific and intellectual contributions to the study:** Silva AB, Patavino GAD, Bonfitto M, Aguiar WF, Foresto RD, Tedesco-Silva H, Pestana JM; **Conception and design:** Silva AB, Patavino GAD, Bonfitto M, Aguiar WF, Foresto RD, Tedesco-Silva H, Pestana JM; **Data analysis and interpretation:** Silva AB, Patavino GAD, Bonfitto M; **Article writing:** Silva AB, Patavino GAD, Bonfitto M; **Critical revision:** Foresto RD, Tedesco-Silva H, Pestana JM; **Final approval:** Aguiar WF, Foresto RD, Tedesco-Silva H, Pestana JM.

## AVAILABILITY OF RESEARCH DATA

Data will be provided upon request.

## FUNDING

Not applicable.

## ACKNOWLEDGEMENTS

Thank all those who provided intellectual assistance, technical help (including writing and editing), or who provided special equipment or materials.

## REFERENCES

1. Arlen AM, Nawaf C, Kirsch AJ. Prune belly syndrome: current perspectives. *Pediatric Health Med Ther.* 2019;10:75-81. <https://doi.org/10.2147/PHMT.S188014>
2. Yalcinkaya F, Bonthuis M, Erdogan BD, van Stralen KJ, Baiko S, Chehade H, et al. Outcomes of renal replacement therapy in boys with prune belly syndrome: findings from the ESPN/ERA-EDTA Registry. *Pediatr Nephrol.* 2018;33(1):117-24. <https://doi.org/10.1007/s00467-017-3770-9>
3. Fusaro F, Zanon GF, Ferreli AM, Giuliani S, Zacchello G, Passerini-Glazel G, et al. Renal transplantation in prune-belly syndrome. *Transpl Int.* 2004;17(9):549-52. <https://doi.org/10.1007/s00147-004-0759-7>

4. Fearon JA, Varkarakis G. Dynamic abdominoplasty for the treatment of prune belly syndrome. *Plast Reconstr Surg.* 2012;130(3):648-57. <https://doi.org/10.1097/PRS.0b013e31825dc170>
5. Seidel NE, Arlen AM, Smith EA, Kirsch AJ. Clinical manifestations and management of prune-belly syndrome in a large contemporary pediatric population. *Urology.* 2015;85(1):211-5. <https://doi.org/10.1016/j.urology.2014.09.029>
6. Diao B, Diallo Y, Fall PA, Ngom G, Fall B, Ndoye AK, et al. Prune Belly syndrome: Epidemiologic, clinic and therapeutic aspects. *Prog Urol.* 2008;18(7):470-4. <https://doi.org/10.1016/j.purol.2008.04.003>
7. Zugar V, Schott GE, Labanaris AP. The Prune Belly syndrome: urological aspects and long-term outcomes of a rare disease. *Pediatr Rep.* 2012;4(2):e20. <https://doi.org/10.4081/pr.2012.e20>
8. Dénes FT, Lopes RI, Oliveira LM, Tavares A, Srougi M. Modified abdominoplasty for patients with the Prune Belly syndrome. *Urology.* 2014;83(2):451-4. <https://doi.org/10.1016/j.urology.2013.09.031>
9. Dénes FT, Park R, Lopes RI, Moscardi PR, Srougi M. Abdominoplasty in Prune Belly Syndrome. *J Pediatr Urol.* 2015;11(5):291-2. <https://doi.org/10.1016/j.jpuro.2015.06.006>
10. Hassett S, Smith GHH, Holland AJA. Prune belly syndrome. *Pediatr Surg Int.* 2012;28(3):219-28. <https://doi.org/10.1007/s00383-011-3046-6>