







Recommendations for Dengue Screening Protocol for Donors and Recipients in Solid Organ Transplantation

Daniel Wagner de Castro Lima Santos^{1,2,*} , Raquel Silveira Bello Stucchi³ , Wanessa Trindade Clemente⁴ ,
Edson Abdala⁵ , Guilherme Santoro-Lopes⁶ , Ligia Camera Pierrotti⁵ 

1. Universidade Federal do Maranhão  – São Luís (MA) – Brazil.
2. Instituto D'Or de Pesquisa e Ensino  – Rio de Janeiro (RJ) – Brazil.
3. Universidade Estadual de Campinas  – Campinas (SP) – Brazil.
4. Universidade Federal de Minas Gerais  – Belo Horizonte (MG) – Brazil.
5. Universidade de São Paulo  – São Paulo (SP) – Brazil.
6. Universidade Federal do Rio de Janeiro  – Rio de Janeiro (RJ) – Brazil.

*Corresponding author: danielinfectologista@gmail.com

Section editor: Ilka de Fátima S. F. Boin 

Received: Mar 19, 2024 | Accepted: Mar 21 2024

ABSTRACT

Dengue, an infection characterized by recurrent epidemic spanning 3 to 5 years, stands out as a one of the most prominent problem due to its escalating case number and geographic extension. Despite its vast distribution, the disease occurs most intensely in the Americas and Southeast Asia. Within this scenario, it is imperative to carefully assess the potential repercussions of this epidemic on transplant activity. Although literature on this matter remains sparse, a review of probable and confirmed cases of dengue transmission through infected donors was carried out, addressing clinical characteristics and outcomes in recipients of such organs. Considering the strategies adopted in other countries that have already experienced dengue epidemics with the transmission of the virus through organ transplantation, the Comissão de Infecção em Transplante (COINT) da Associação Brasileira de Transplante (ABTO) delineates a protocol for screening potential donors and transplant candidates. This protocol involves the combined use of NS1/IgM on blood, alongside stringent criteria for evaluating donor and recipient suitability.

Descriptors: Dengue; Communicable Diseases; Organ Transplantation.

Recomendações de Triagem de Dengue de Doador e Receptor no Transplante de Órgãos Sólidos

RESUMO

A dengue, infecção caracterizada por ciclos epidêmicos que se repetem a cada 3 a 5 anos, figura como um dos problemas de maior destaque, tendo em vista sua progressiva expansão em número de casos e extensão geográfica. Em que pese sua vasta distribuição geográfica, é nas Américas e Sudeste Asiático que a doença incide de forma mais intensa. No contexto de surtos e epidemias, as infecções transmitidas pelos doadores podem representar um grande desafio devido à falta de dados, na literatura, de uma política clara para triagem dos doadores e dos possíveis desfechos indesejáveis. Casos de transmissão provável e confirmada têm sido relatados em receptores de diferentes órgãos. Embora o total de casos descritos seja pequeno, é importante considerar a possibilidade de subnotificação e o aumento substancial do risco desse evento, especialmente nos períodos em que a transmissão da dengue atinge níveis epidêmicos na população. Com base na escassa literatura, porém baseada em estratégias adotadas em outros países que já experimentaram epidemias de dengue com transmissão do vírus por meio de transplante de órgãos, a Comissão de Infecção em Transplante (COINT) da Associação Brasileira de Transplante (ABTO) sugere triagem de doadores e candidatos a transplante com o uso combinado de NS1/IgM no sangue e critérios para o aceite do doador e do candidato.

Descritores: Dengue; Doenças Transmissíveis; Transplante de Órgãos.

DENGUE EPIDEMIOLOGICAL SITUATION AND IMPACT ON TRANSPLANT ACTIVITY

The emergence and re-emergence of different arboviruses are a growing concern in the global public health panorama. In this context, dengue, an infection characterized by epidemic cycles that repeat every 3 to 5 years, appears as one of the most prominent problems, given its progressive expansion in the number of cases and geographic extension. World Health Organization (WHO) data report a 10-fold increase in cases from 2000 to 2019, with occurrences currently recorded in 129 countries¹. Despite its vast geographic distribution, it is in the Americas that the disease occurs most intensely. In 2023, were detected in this region 80% of suspected cases, with a notable concentration in Brazil and the year 2024 brought a further worsening of the epidemiological situation in our country. The number of probable cases reported in the first nine weeks of the year is markedly higher than that recorded in the same period in 2023, approaching the total number of cases recorded in the previous year².

Given this scenario, the potential impact of this epidemic on the population of organ transplant recipients deserves particular consideration. Although the scarcity of data on this topic in the literature is recognized, it is essential to note that a systematic review carried out with data on dengue fever in kidney transplant recipients published up to 2017 highlighted particularities worthy of attention in both the clinical presentation and prognosis of the infection in these patients³. Regarding the first aspect, the study showed that clinical manifestations such as fever, myalgia, arthralgia and headache, which make up the definition of a suspected case⁴, occur with a significantly lower frequency than that observed in the general population. This finding suggests that the suspected case definition recommended for the general population is less sensitive for detecting cases among transplant recipients, thus highlighting the need to maintain a high degree of clinical suspicion when caring for these patients and not limit the diagnostic investigation only to cases that meet those criteria. On the other hand, the same study demonstrated a significantly higher prevalence among transplant recipients signaling severe manifestations, such as ascites and pleural effusion, a higher proportion of patients who met the criteria for severe dengue and a significant increase in lethality. As there is no specific treatment for dengue, the observation of its worse prognosis among transplant recipients emphasizes the need to intensify preventive guidelines for this segment of the population.

Another aspect that deserves particular attention is the possible non-vector transmission of dengue caused by organ donation. Cases of probable transmission have been reported⁵⁻⁷ in receptors from different organs (kidney, liver, heart). Although the total number of cases described is small, it is crucial to consider the possibility of underreporting and the substantial increase in the risk of this event, especially when dengue transmission reaches epidemic levels in the population. The small number of cases described to date does not allow us to define the prognosis of donor-derived dengue cases accurately. However, it is plausible that such cases are at greater risk of complications and death, given the vulnerable conditions observed in the first weeks after organ transplantation, which tend, in general, to worsen the repercussions of infection in these patients. Therefore, it justified the proposal of a dengue screening routine among donors and candidates for organ transplants to mitigate its risk of occurrence early after organ transplantation, either through transmission through organ donation or through failure to recognize active infection in the candidate at the time of transplant.

LABORATORY DIAGNOSIS OF DENGUE

Laboratory diagnosis of dengue is crucial due to its nonspecific presentation, which requires differentiation from other conditions, including coronavirus disease 2019 (COVID-19), in some situations. Rapid dengue diagnostic tests are essential for the most effective and agile approach to diagnosing and managing the disease in vulnerable patients, including transplant recipients, a group at the highest risk of developing complications (group B of the Ministry of Health's Clinical Protocol)⁸.

Additionally, rapid tests can be used for laboratory screening of dengue fever in asymptomatic candidates and donors (living and deceased), as the disease can be completely asymptomatic in around 75%. Therefore, there is a risk of viral transmission by the donor at the time of transplantation or a risk of an unfavorable outcome for the candidate if the transplant is performed at a time of asymptomatic viremia.

Although viral isolation is the "gold standard" diagnosis, it is not viable in clinical practice. Therefore, in clinical practice, diagnosis is based on detecting the NS1 virus glycoprotein, detecting antibodies of the IgM and IgG classes and detecting viral genetic material using the polymerase chain reaction (PCR) technique. NS1 and IgM/IgG are detected using the enzyme-linked immunosorbent assay (ELISA) technique in a laboratory environment and immunochromatographic method, with

results available within 2 hours. The diagnostic performance of PCR and NS1 detection is similar but with some differences, as discussed below.

Currently, numerous laboratory methods to detect NS1, IgM/IgG, and PCR-dengue are approved by the National Health Surveillance Agency (Anvisa) and are available on the market. However, no rapid molecular diagnostic test for dengue is available. Therefore, dengue rapid response laboratory tests are only NS1 and/or IgM/IgG detection tests by immunochromatography.

NS1 is detectable in the blood from the 1st day of symptoms and remains detectable for 8 to 9 days after the onset of symptoms. IgM is positive from the 3rd to 4th day of the onset of symptoms in primary dengue and from the 6th to 7th day of the onset of symptoms in secondary dengue and remains detectable for approximately 90 days or more extended periods in secondary dengue.

The sensitivity and specificity of NS1 and IgM tests vary depending on the manufacturer and the characteristics of the virus and disease. Thus, NS1 was shown to have lower sensitivity in cases of DENV-4 infection compared to infection with other viral types⁹ and greater sensitivity in cases of uncomplicated infection, cases of primary infection, patients with greater viremia, and symptomatic patients^{10,11}.

Using a rapid immunochromatography test with simultaneous detection of the NS1 protein and IgM and IgG antibodies considerably increases the sensitivity and specificity of the test, making its application safer and more reliable. In a study with 320 confirmed cases of dengue, the NS1/IgM combination identified 90.3% of cases compared to 50.6% of cases identified by the isolated PCR-DENV test, 71.6% by IgM MAC-ELISA, 62.5 % by NS1, and 68.7% by immunochromatographic IgM¹².

Combined NS1/IgM identification may decrease the risk of false-negative results from viremic samples based on NS1 testing alone. In a study on blood bank donors in Puerto Rico from 2010 to 2012, the NS1 test identified only 20% of viremic samples confirmed retrospectively by PCR-DENV¹³.

Dengue virus (DENV) can also be detected in urine and saliva samples. However, as described by Humaidi et al. 14, the viral detection capacity in these clinical samples is lower than the capacity in plasma throughout the entire period of disease evolution. In the study of Andries et al.¹⁵, 401 confirmed PCR-DENV investigated dengue cases in Singapore; positivity was 85.4% in plasma, 41.6% in urine and 39% in saliva.

TRANSMISSION OF DENGUE BY THE DONOR AND MITIGATION MEASURES

Non-vector transmission of dengue can occur through transfusion of blood components from infected donors (platelets, whole blood, packed red blood cells, fresh frozen plasma, cryoprecipitate), solid organ transplantation, stem and hematopoietic cell transplantation and, rarely, nosocomial transmission through contaminated needle sticks^{13,16,17}.

The potential for transmission through organ transplantation exists as dengue fever evolves with viremia, with the virus persisting in the tissue after blood bleaching. Additionally, up to 75% of individuals are asymptomatic, allowing asymptomatic viremic organ donors not to be identified by clinical screening¹⁸.

There are limited descriptions of possible non-vector transmission of dengue through organ transplantation. Table 1 represents a review of cases in the literature of potential or confirmed dengue transmission through organ transplantation.¹⁹⁻²⁶

Table 1. Published cases of probable and confirmed DENV infection in organ transplant recipients.

Reference	Country	Organ/receiver characteristics	Donor type	Symptoms (D1)	Donor/receiver symptoms	Classification	Outcome	Antigen, serology or molecular testing
Saigal et al. ¹⁹	India	Liver/male, 38 years old, cirrhosis due to hepatitis B virus	Alive, son, 19 years old	6	Receiver: D6: fever, thrombocytopenia, severe graft dysfunction (AST > 3,500 and ALT > 2,500)	Classic dengue with warning signs	Alive	Receiver: NS1+ and PCR DENV+ Donor: NS1+ and PCR DENV+
Gupta et al. ²⁰	India	Liver/male, 40 years old, cryptogenic cirrhosis	Alive, brother-in-law, 29 years old	5	Donor: D2-3 post Tx: fever, thrombocytopenia, elevated transaminases. Receiver: D3-6: elevation of transaminases; D5: fever; D7: thrombocytopenia.	Classic dengue without complications	Alive	Donor: NS1+ post-Tx Receiver: NS1+

Continue...

Table 1. Continuation...

Reference	Country	Organ/receiver characteristics	Donor type	Symptoms (D1)	Donor/receiver symptoms	Classification	Outcome	Antigen, serology or molecular testing
Rosso et al. ²¹	Colombia	Liver/male, 53 years old	Deceased, intracranial hemorrhage, SAH	2	<p>Donor: Visited the service with fever and thrombocytopenia one week before death (chart review).</p> <p>Receiver: D2: fever, thrombocytopenia, lymphopenia, anemia, elevated transaminases, transient encephalopathy, liver biopsy with lymphoplasmacytic, neutrophilic infiltrate suggestive of viral disease.</p>	Severe dengue with organ dysfunction	Alive	<p>Donor: IgG+ and IgM+ (retroactive testing on stored blood).</p> <p>Receiver: IgG-; IgM+ and PCR DENV3+.</p>
Rosso et al. ²¹	Colombia	Heart/male, 41 years old, dilated cardiomyopathy	Deceased, intracranial hemorrhage, SAH	3	<p>Donor: Visiting the service with fever and thrombocytopenia one week before death (chart review).</p> <p>Receiver: D3: myalgia, arthralgia, fever, lymphopenia, thrombocytopenia, elevation of transaminases, bilirubin and alkaline phosphatase; D16: severe thrombocytopenia, shock and cardiac tamponade (hemorrhagic pericardial effusion).</p>	Severe dengue fever with organ dysfunction and hemorrhage	Alive	<p>Donor: IgG+ and IgM+ (retroactive testing on stored blood).</p> <p>Receiver: IgG -; IgM+ and PCR DENV3+.</p>
Rosso et al. ²¹	Colombia	Kidney/female, 31 years old	Deceased, head trauma	8	<p>Donor: No reported symptoms.</p> <p>Receiver: D8: fever, vomiting, diarrhea, jaundice, pain in the right iliac fossa, thrombocytopenia; D15: drained perigraft hematoma.</p>	Severe dengue fever with organ dysfunction and hemorrhage	Alive	<p>Donor: NS1+ (retroactive test on stored blood performed for the diagnosis of dengue in this recipient).</p> <p>Receiver: NS1+ and PCR DENV4+</p>
Rosso et al. ²¹	Colombia	Kidney/female, 48 years old	Deceased, head trauma	4	<p>Donor: No reported symptoms.</p> <p>Receiver: D4: fever, anemia; D23: asymptomatic elevation of transaminases.</p>	Classic dengue without complications	Alive	<p>Donor: NS1+ (retroactive test on stored blood carried out following the diagnosis of dengue in the other recipient).</p> <p>Receiver: IgM+; NS1, IgG and PCR DENV negative.</p>
Kumar et al. ²²	India	Liver/male, 64 years old, cirrhosis due to non-alcoholic steatohepatitis and hepatitis C virus	Alive, son, 28 years old	4	<p>Donor: D2: fever, anemia, thrombocytopenia; D9: bleeding from the surgical wound.</p> <p>Receiver: D4: thrombocytopenia, elevated transaminases; after D12, he developed upper gastrointestinal bleeding, endotracheal intubation, and acute respiratory distress syndrome.</p>	Severe dengue with multiple organ dysfunction and hemorrhage	Death	<p>Donor: NS1+</p> <p>Receiver: NS1+; PCR DENV1+, IgG-, IgM-.</p>

Continue...

Table 1. Continuation...

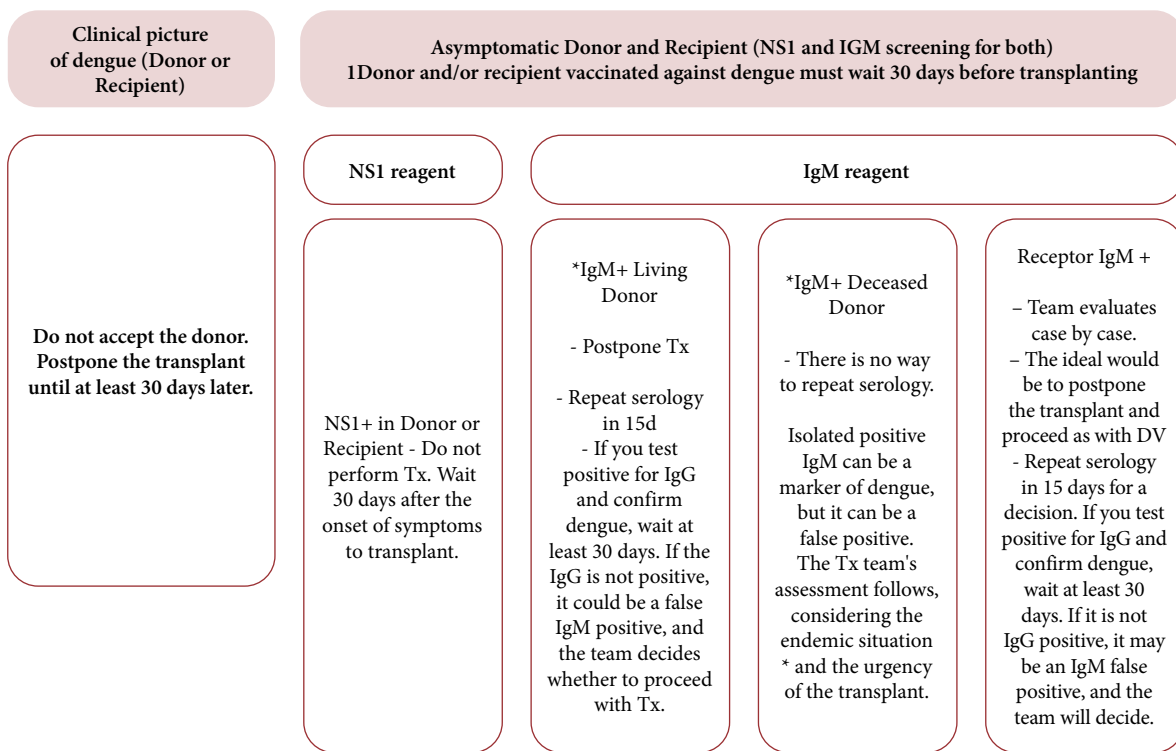
Reference	Country	Organ/receiver characteristics	Donor type	Symptoms (D1)	Donor/receiver symptoms	Classification	Outcome	Antigen, serology or molecular testing
Mathew ²³	India	Liver/male, 58 years old, alcoholic cirrhosis	Alive, brother, 48 years old	9	Donor: D6: fever, thrombocytopenia, abdominal pain. It evolves with ascites, elevated transaminases and encephalopathy. Receiver: D9: abdominal pain, thrombocytopenia, and altered sensorium. He developed encephalitis and kidney and liver dysfunction.	Severe dengue with multiple organ dysfunction	Death	Donor: NS1-; PCR DENV1+, IgG+, IgM+. Receiver: NS1+; PCR DENV1+, IgG-, IgM-.
Lecadiou et al. ²⁴	France (La Réunion)	Kidney/male, 58 years old, chronic kidney disease due to nephrolithiasis	Deceased, male, 62 years old, head trauma	11	Donor: No reported symptoms. Receiver: D11: anemia, thrombocytopenia, elevated transaminases, hypotension and abdominal pain. Subjected to abdominal wall collection drainage, evolving into hemorrhagic shock.	Severe dengue with multiple organ dysfunction	Alive	Donor: D0: PCR DENV-; IgM+/IgG+ Receiver: D11: PCR DENV1+; D30: IgM+/IgG+.
Lecadiou et al. ²⁴	France (La Réunion)	Kidney/male, 61 years old	Deceased, male, 62 years old, with head trauma	12	Donor: No reported symptoms. Receiver: D12: thrombocytopenia, elevation of transaminases.	Classic dengue without complications	Alive	Donor: D0: PCR DENV-; IgM+/IgG+ Receiver: D12: PCR DENV1+ (sanguine)/IgM-/IgG-; D30: PCR DENV- (blood)/PCR DENV+ (urine)/IgM+/Ig+.
Sim et al. ²⁵	Singapore	Kidney/male, 63 years old, IgA nephropathy	Deceased, female, 26 years old, intracranial hemorrhage	5	Donor: Isolated fever 10 days before brain death (eve of elective cesarean section). She was hospitalized 10 days later with intracranial hemorrhage and brain death. Receiver: D5: fever, thrombocytopenia.	Classic dengue without complications	Alive	Donor: D-10: PCR DENV-; D-10: NS1-; D0: PCR DENV- (blood); D0: PCR DENV+ (urine). Receiver: D0: PCR DENV-/IgG+; D8-14: PCR DENV2+ (blood).
Sim et al. ²⁵	Singapore	Kidney/male, 39 years old, glomerulonephritis	Deceased, female, 26 years old, intracranial hemorrhage	-	Donor: Isolated fever 10 days before brain death (eve of elective cesarean section). She was hospitalized 10 days later with intracranial hemorrhage and brain death. Receiver: Asymptomatic. Mild elevation of AST, with normal ALT.	Classic dengue without complications	Alive	Donor: D-10: PCR DENV-; D-10: NS1-; D0: PCR DENV- (blood); D0: PCR DENV+ (urine). Receiver: D0: IgG-/IgM-; D9-16: PCR DENV2+ (blood); D13: IgM+.
Jayant et al. ²⁶	India	Liver/female, 19 years old, cirrhosis due to Wilson's disease	Deceased, no other data	8	Donor: No data and no samples for testing. Receiver: D8: fever, chills, tachycardia and tachypnea. Mild elevation of transaminases; D16: hypotension, acute respiratory distress, shock, ascites.	Severe dengue with organ dysfunction	Alive	Donor: No samples. Receiver: D8: NS1+/IgM+/IgG-; the other two organ recipients (kidney) from the same donor: NS1+ e IgM+.

Source: Elaborated by the authors. ALT = alanine aminotransferase; AST = aspartate aminotransferase; D1 = day one; SAH = systemic arterial hypertension; Tx = transplant.

Most cases are documented based on the early onset of symptoms in the recipient after transplantation and, in several instances, the occurrence of dengue fever in more than one recipient from the same donor. However, in most reports, it is impossible to unequivocally confirm the transmission of dengue by the donor due to the lack of confirmation of viral PCR in the donor and recipients. Genetic sequencing was carried out in just one case, with 99.9% homology found when comparing the donor and recipient viruses²³. Furthermore, there are cases of possible transmission from donors with negative PCR-DENV in the blood performed during laboratory screening.^{24,25} These cases could represent false-negative cases or cases of low viremia with the presence of the virus in organs and tissues. In this way, the combined identification of IgM class antibodies could identify potentially at-risk donors, mitigating transmission through organ transplantation¹⁸.

Currently, there is no universal recommendation for dengue screening in donors and candidates. The American Association of Blood Banks (AABB) and the Centers for Disease Control and Prevention (CDC) recommend screening blood components for dengue in endemic countries. However, this recommendation is not included in the American Society of Transplantation (AST) organ transplant guidelines. During a dengue outbreak in Colombia, Rosso et al. 21 recommended universal screening of organ donors using the NS1 antigen. Since November 2016, all blood and organ donors in Singapore have been routinely screened for DENV by RT-PCR²⁵.

Based on the scarce literature and strategies adopted in other countries that have already experienced dengue epidemics with transmission of the virus through organ transplantation, the Commission on Infection in Transplantation (*Comissão de Infecção em Transplante-COINT*) of the Brazilian Transplant Association (*Associação Brasileira de Transplante-ABTO*) suggests screening of donors and transplant candidates with the combined use of NS1/IgM in blood and criteria for acceptance of the donor and candidate, according to the flowchart shown in Fig. 1.



Source: Elaborated by the authors.

Figure 1. Dengue laboratory screening and donor and candidate acceptance criteria. Tx = transplant. ¹Dengue vaccines use attenuated viruses. Transplantation should be delayed for 30 days after the last dose. * It is recommended not to accept deceased donors with negative NS1/positive IgM in cases of donors coming from dengue endemic areas (with > 300 cases/100,000 inhabitants). In other cases, it is recommended not to accept a deceased donor with negative NS1/positive IgM without a history of symptoms suggestive of dengue in the last 30 days, in which the diagnosis of dengue has not previously been ruled out.

It is not recommended to use IgG to interpret the diagnosis of dengue, as individuals exposed to dengue in the past will have positive IgG, regardless of the phase of the current acute illness. The isolated presence of IgG in the candidate does not contraindicate transplantation, and the isolated presence in the donor does not contraindicate acceptance of the organ. However, the presence of positive IgG together with the other infection markers (IgM and/or NS1) does not change the interpretation suggested in the flowchart represented in Fig. 1.

DENGUE FEVER IMMUNIZATION

The Takeda Laboratory dengue vaccine (QDenga®) was recently approved in Brazil. The vaccine protects against the four serotypes of dengue and is indicated for immunocompetent people with or without previous exposure to dengue in the age group of 4 to 60. It must be administered subcutaneously, at a dosage of 0.5 mL, in a two-dose regimen (0 and 3 months). As it is an attenuated vaccine, it is contraindicated in immunosuppressed people and pregnant and breastfeeding women. There is no data on use in people over 60 or safety in patients with chronic medical conditions.^{27,28} Vaccinated donor and/or recipient must wait 30 days for a transplant. This recommendation is based on international recommendations on administering attenuated vaccines in the pre- and post-transplant period.^{29,30} In 2023, Gould et al.³¹ documented the transmission of the vaccine yellow fever virus to four organ recipients who received blood products from a donor vaccinated against yellow fever five days before blood donation. All four presented severe neurological complications secondary to the vaccine virus—two died³¹.

There are still no publications on the efficacy and safety of administering the dengue vaccine in the transplant setting.

CONFLICT OF INTEREST

Nothing to declare.

AUTHOR'S CONTRIBUTION

Substantive scientific and intellectual contributions to the study: Santos DWCL, Stucchi RSB, Clemente WT, Abdala E, Santoro-Lopes G, Pierrotti LC; **Conception and design:** Santos DWCL, Stucchi RSB, Clemente WT, Abdala E, Santoro-Lopes G, Pierrotti LC; **Data analysis and interpretation:** Santos DWCL, Stucchi RSB, Clemente WT, Abdala E, Santoro-Lopes G, Pierrotti LC; **Article writing:** Santos DWCL, Stucchi RSB, Clemente WT, Abdala E, Santoro-Lopes G, Pierrotti LC; **Critical revision:** Santos DWCL, Stucchi RSB, Clemente WT, Abdala E, Santoro-Lopes G, Pierrotti LC; **Final approval:** Santos DWCL.

DATA AVAILABILITY STATEMENT

Not applicable.

FUNDING

Not applicable.

ACKNOWLEDGEMENT

Not applicable.

REFERENCES

1. World Health Organization [homepage Internet]. Dengue – Global situation [updated on 21 Dez 2023; accessed on 28 Feb 2024]. Available at: <https://www.who.int/emergencies/disease-outbreak-news/item/2023-DON498>
2. Brasil. Ministério da Saúde do Brasil [homepage Internet]. Paineis de monitoramento de arboviroses [accessed on 14 Mar 2024]. Available at: <https://www.gov.br/saude/pt-br/assuntos/saude-de-a-a-z/a/aedes-aegypti/monitoramento-das-arboviroses>
3. Weerakkody RM, Patrick JA, Sheriff MH. Dengue fever in renal transplant patients: a systematic review of literature. *BMC Nephrol* 2017;18(1):15. <https://doi.org/10.1186/s12882-016-0428-y>
4. Brasil. Ministério da Saúde do Brasil. Dengue. Diagnóstico e manejo clínico. Adulto e criança. 6ª ed. Brasília (DF): Ministério da Saúde; 2024. [accessed on 18 Mar 2024]. Available at: http://bvsmms.saude.gov.br/bvs/publicacoes/dengue_diagnostico_manejo_clinico_6ed.pdf
5. Di Ascia L, Jaffar-Bandjee MC, Cresta MP, Vasseur AS, Lugagne N, Vacher-Coponat H, et al. Dengue virus in kidney allograft: implications for donor screening and viral reservoir. *Kidney Int Rep* 2023;9(1):186-90. <https://doi.org/10.1016/j.ekir.2023.10.012>

6. Peghin M, Grossi PA. Donor-derived infections in solid organ transplant recipients. *Curr Opin Organ Transplant* 2023;28(5):384-90. <https://doi.org/10.1111/j.1600-6143.2009.02889.x>
7. Cedano JA, Mora BL, Parra-Lara LG, Manzano-Núñez R, Rosso F. A scoping review of transmission of dengue virus from donors to recipients after solid organ transplantation. *Trans R Soc Trop Med Hyg* 2019;113(8):431-6. <https://doi.org/10.1093/trstmh/trz024>
8. Brasil. Ministério da Saúde do Brasil. Dengue. Diagnóstico e manejo clínico. 6ª ed. Brasília (DF): Ministério da Saúde; 2024. [accessed on 18 Mar 2024]. Available at: <https://www.gov.br/saude/pt-br/centrais-de-conteudo/publicacoes/svsa/dengue/dengue-diagnostico-e-manejo-clinico-adulto-e-crianca>
9. Gonçalves BS, Horta MAP, Acero PHC, Bochner R, Queiroz Lima MDR, de Araújo ES, et al. Dynamics of nonstructural glycoprotein-1 in dengue patients presenting with different clinical manifestations from 1986 to 2012 in Rio de Janeiro, Brazil. *J Med Virol* 2019;91(4):555-63. <https://doi.org/10.1002/jmv.25356>
10. Duong V, Ly S, Try PL, Tuiskunen A, Ong S, Chroeueng N, et al. Clinical and virological factors influencing the performance of a NS1 antigen-capture assay and potential use as a marker of dengue disease severity. *PLoS Negl Trop Dis* 2011;5(7):e1244. <https://doi.org/10.1371/journal.pntd.0001244>
11. Teoh BT, Sam SS, Tan KK, Johari J, Abd-Jamil J, Hooi PS, et al. The use of NS1 rapid diagnostic test and qRT-PCR to complement IgM ELISA for improved dengue diagnosis from single specimen. *Sci Rep* 2016;6:27663. <https://doi.org/10.1038/srep27663>
12. Wang SM, Sekaran SD. Early diagnosis of dengue infection using a commercial Dengue Duo rapid test kit for the detection of NS1, IGM, and IGG. *Am J Trop Med Hyg* 2010;83(3):690-5. <https://doi.org/10.4269/ajtmh.2010.10-0117>
13. Matos D, Tomashek KM, Perez-Padilla J, Muñoz-Jordán J, Hunsperger E, Horiuchi K, et al. Probable and possible transfusion-transmitted dengue associated with NS1 antigen-negative but RNA confirmed-positive red blood cells. *Transfusion* 2016;56(1):215-22. <https://doi.org/10.1111/trf.13288>
14. Humaidi M, Tien WP, Yap G, Chua CR, Ng LC. Non-invasive dengue diagnostics – The use of saliva and urine for different stages of the illness. *Diagnostics (Basel)* 2021;11(8):1345. <https://doi.org/10.3390/diagnostics11081345>
15. Andries AC, Duong V, Ly S, Cappelle J, Kim KS, Try PL, et al. Value of routine dengue diagnostic tests in urine and saliva specimens. *PLoS Negl Trop Dis*. 2015;9(9):e0004100. <https://doi.org/10.1371/journal.pntd.0004100>
16. Perera L, De Zoysa N, Jayarajah U, Senanayake N, De Zoysa I, Seneviratne SL. Transfusion-transmissible dengue infections. *Trans R Soc Trop Med Hyg* 2020;114(11):866-82. <https://doi.org/10.1093/trstmh/traa075>
17. Sabino EC, Loureiro P, Lopes ME, Capuani L, McClure C, Chowdhury D, et al. Transfusion-transmitted dengue and associated clinical symptoms during the 2012 epidemic in Brazil. *J Infect Dis* 2016;213(5):694-702. <https://doi.org/10.1093/infdis/jiv326>
18. Pozzetto B, Grard G, Durand G, Paty MC, Gallian P, Lucas-Samuel S, et al. Arboviral risk associated with solid organ and hematopoietic stem cell grafts: the prophylactic answers proposed by the French High Council of Public Health in a national context. *Viruses* 2023;15(9):1783. <https://doi.org/10.3390/v15091783>
19. Saigal S, Choudhary NS, Saraf N, Kataria S, Mohanka R, Sooin AS. Transmission of dengue virus from a donor to a recipient after living donor liver transplantation. *Liver Transpl* 2013;19(12):1413-4. <https://doi.org/10.1002/lt.23755>
20. Gupta RK, Gupta G, Chorasaya VK, Bag P, Shandil R, Bhatia V, et al. Dengue virus transmission from living donor to recipient in liver transplantation: a case report. *J Clin Exp Hepatol* 2016;6(1):59-61. <https://doi.org/10.1016/j.jceh.2016.01.005>
21. Rosso F, Pineda JC, Sanz AM, Cedano JA, Caicedo LA. Transmission of dengue virus from deceased donors to solid organ transplant recipients: case report and literature review. *Braz J Infect Dis* 2018;22(1):63-9. <https://doi.org/10.1016/j.bjid.2018.01.001>
22. Kumar S, Sable S, Yadav K, Sharma S, Chouhan A, Kapoor S, et al. Dengue transmission from donor to recipient after living donor liver transplant. *Trop Gastroenterol* 2019. <https://dx.doi.org/10.7869/tg.497>
23. Mathew JS, Menon VP, Menon VP, Mallick S, Amma BSPT, Balakrishnan D, et al. Dengue virus transmission from live donor liver graft. *Am J Transplant* 2019;19(6):1838-46. <https://doi.org/10.1111/ajt.15270>
24. Lecadiou A, Teyssyre L, Larsen K, Vidal C, Caron M, Traversier N, et al. Case report: transmission of dengue virus from a deceased donor to a kidney transplant recipient previously infected by dengue virus. *Am J Trop Med Hyg* 2021;104(6):2199-2201. <https://doi.org/10.4269/ajtmh.21-0137>
25. Sim JXY, Gan ES, Tan HC, Choy MM, Wong HM, Tan BH, et al. Aviremic organ transplant dengue virus transmission – A case report. *Am J Transplant* 2021;21(5):1944-7. <https://doi.org/10.1111/ajt.16540>
26. Jayant D, Behera A, Kaman L, Savlania A, Tandup C, Naik K. Dengue transmission from donor to recipient after deceased donor liver transplant; report of a case and review of literature: is liver a privileged organ? *Exp Clin Transplant* 2022;20(10):959-64. <https://doi.org/10.6002/ect.2022.0136>
27. Sociedade Brasileira de Imunizações. Nota Técnica Conjunta SBIm/SBI/SBMT - 03/07/2023 (atualizada em 06/03/2024). Vacina DENGUE 1,2,3 e 4 (atenuada) QDENGAR[®]. [accessed on 15 Mar 2024]. Available at: <https://sbim.org.br/images/files/notas-tecnicas/nota-tecnica-sbim-sbi-sbmt-qdenga-v5.pdf>

28. Takeda. Dossiê de avaliação de tecnologias em saúde preparado para a CONITEC. QDENGGA® (vacina dengue 1, 2, 3 e 4 – atenuada) indicada para a prevenção de dengue em indivíduos de 4 aos 60 anos de idade [accessed on 15 Mar 2024]. Available at: <https://www.gov.br/conitec/pt-br/midias/consultas/dossie/2023/DossietakedaVacinadengue.pdf>
29. Bahakel H, Feldman AG, Danziger-Isakov L. Immunization of solid organ transplant candidates and recipients: a 2022 update. *Infect Dis Clin North Am* 2023;37(3):427-41. <https://doi.org/10.1016/j.idc.2023.03.004>
30. Danziger-Isakov L, Kumar D; AST ID Community of Practice. Vaccination of solid organ transplant candidates and recipients: guidelines from the American Society of Transplantation infectious diseases community of practice. *Clin Transplant* 2019;33(9):e13563. Erratum in: *Clin Transplant* 2020;34(3):e13806. <https://doi.org/10.1111/ctr.13563>
31. Gould CV, Free RJ, Bhatnagar J, Soto RA, Royer TL, Maley WR, et al. Yellow fever vaccine virus transplant and transfusion investigation team. Transmission of yellow fever vaccine virus through blood transfusion and organ transplantation in the USA in 2021: report of an investigation. *Lancet Microbe* 2023;4(9):e711-21. Erratum in: *Lancet Microbe* . [https://doi.org/10.1016/S2666-5247\(23\)00170-2](https://doi.org/10.1016/S2666-5247(23)00170-2)