







# Recurrent Parvovirus B19-Associated Pure Red Cell Aplasia: A Challenging Disease in Kidney Transplantation

Núria Paulo<sup>1\*</sup> , Carolina Ferreira<sup>2</sup> , Ana Cerqueira<sup>1</sup> , Susana Sampaio<sup>1</sup> , Manuel Pestana<sup>1</sup> 

1.Unidade Local de Saúde de São João  – Porto – Portugal.

2.Unidade Local de Saúde de Viseu Dão Lafões – Viseu – Portugal.

\*Correspondence author: [nuriapaulo@hotmail.com](mailto:nuriapaulo@hotmail.com)

Section editor: Ilka de Fátima Santana F. Boin 

Received: May 01, 2024 | Approved: June 20, 2024

## ABSTRACT

Parvovirus B19 (PVB19)-associated pure red cell aplasia (PRCA) is an important diagnosis to consider in kidney transplant (KT) recipients experiencing persistent anemia, in whom other etiologies have been excluded. Its management poses a challenge since reducing immunosuppression (IS) to address the viral infection needs to be carefully balanced with the increased risk of allograft rejection. The authors describe a case of a 43-year-old male with a history of chronic kidney disease of unknown etiology who underwent a KT from a deceased donor after circulatory death in January 2021. In the 1st year post-KT, the patient was repeatedly admitted due to the recurrence of PVB19-associated PRCA, requiring blood transfusions and intravenous immunoglobulin (IVIG). IS was initially adjusted with mycophenolate mofetil (MMF) suspension and later transitioned to a TRANSFORM scheme with prednisolone, tacrolimus, and everolimus. Due to deteriorating kidney function, a kidney biopsy was performed and revealed borderline acute T-cell mediated rejection with significant signs of chronicity (50% of interstitial fibrosis and tubular atrophy). To guarantee infection control, IS was not increased. Considering the recurrence of PVB19-associated PRCA, despite the use of a TRANSFORM IS scheme in a patient with chronic allograft dysfunction and high immunologic risk, maintenance therapy with IVIG (0.4 mg/kg) every 4 weeks was started. After 9 months of maintenance therapy, no relapse was identified. To promote an individualized IS prescription, an ImmunoBiogram<sup>®</sup> was recently performed and an IS reduction is planned, followed by an ImmunoBiogram<sup>®</sup> control, which will potentially allow the suspension of IVIG maintenance therapy. The diagnosis and management of PVB19-associated PRCA is challenging. Regarding recurrent disease, prolonged IVIG treatment appears to be a useful treatment strategy, but more studies are necessary to ascertain its role. It is also fundamental to tailor the IS as much as possible to the individualized immunologic profile of the patients to prevent overimmunosuppression.

**Descriptors:** Parvovirus B19; Anemia; Kidney Transplantation; Immunoglobulin; Immunosuppression.

## *Recorrência de Aplasia Eritrocitária Pura Associada ao Parvovírus B19: Uma Doença Desafiante no Transplante Renal*

## RESUMO

A aplasia eritrocitária pura (PRCA) associada à infecção por parvovírus B19 (PVB19) é um importante diagnóstico a considerar em receptores de transplante renal (TR) que se apresentam com anemia persistente, nos quais outras etiologias foram excluídas. A gestão desses doentes representa um desafio, uma vez que a redução da imunossupressão (IS) para tratar a infecção vírica deve ser cautelosa pelo potencial aumento do risco de rejeição do aloenxerto. Os autores descrevem um caso de um homem de 43 anos com antecedentes de doença renal crónica de etiologia indeterminada que foi submetido a TR de um dador falecido após morte circulatória em janeiro de 2021. No primeiro ano pós-TR, o paciente foi internado repetidamente devido a PRCA associada ao PVB19 e necessitou de transfusões de glóbulos vermelhos e tratamento com imunoglobulina humana intravenosa (IVIG). A IS foi inicialmente ajustada com suspensão do micofenolato de mofetil (MMF) e posteriormente alterada para um esquema TRANSFORM com prednisolona, tacrolimus e everolimus. Devido ao agravamento da função renal, foi realizada uma biópsia renal que revelou rejeição aguda mediada por células T *borderline* com sinais significativos de cronicidade (50% de fibrose intersticial e atrofia tubular). Para garantir o controlo da infecção, a IS não foi aumentada. Considerando a recorrência da PRCA associada ao PVB19 apesar do uso de um esquema IS TRANSFORM num paciente com disfunção crónica do aloenxerto e alto risco imunológico, foi iniciada terapêutica de manutenção com IVIG (0,4 mg/kg) a cada 4 semanas. Após 9 meses de tratamento não

foi identificada nenhuma recidiva. De forma a promover uma prescrição individualizada de IS, um ImmunoBiogram® foi recentemente realizado, estando a ser considerada uma redução da IS que potencialmente permitirá a suspensão da terapia de manutenção com IVIG. O diagnóstico e tratamento da PRCA associada ao PVB19 são desafiadores. Relativamente à doença recidivante, o tratamento prolongado com IVIG parece ser útil, mas mais estudos são necessários para estabelecer o seu papel. Também é fundamental adaptar, tanto quanto possível, a IS ao perfil imunológico individual dos doentes para prevenir o uso excessivo de imunossupressão.

**Descritores:** Parvovírus B19; Anemia; Transplante Renal; Imunoglobulina; Imunossupressão.

## INTRODUCTION

Anemia is reported in 20-50% of kidney transplant (KT) recipients.<sup>1</sup> Potential causes include iron and folate deficiency, diminished erythropoietin production, infections, and hematological toxicity from immunosuppressants.<sup>2,3</sup> Parvovirus B19 (PVB19)-associated pure red cell aplasia (PRCA) becomes an important diagnosis in KT recipients experiencing persistent anemia, in whom other etiologies have been excluded. PVB19-associated PRCA is described in up to 27% of KT recipients with anemia and recurrent disease in up to one-third of cases. Its management poses a challenge since reducing immunosuppression (IS) to address the viral infection needs to be carefully balanced with the increased risk of allograft rejection.<sup>4</sup> The authors describe a case of a recurrent PVB19-associated PRCA in a KT recipient.

### Case report

A 43-year-old male with a history of chronic kidney disease of unknown etiology underwent KT in January 2021 from a deceased donor after circulatory death. He received induction IS with anti-human thymocyte immunoglobulin (Thymoglobulin®) and a maintenance IS scheme with prednisolone, tacrolimus, and mycophenolate mofetil (MMF). Considering the patient experienced delayed graft function, a kidney biopsy was performed, which demonstrated severe acute tubular necrosis. Renal function was recovered, and the patient was discharged with a serum creatinine of 4.3 mg/dL.

Three months after KT, the patient complained of progressive asthenia, and normocytic normochromic anemia was detected although renal function improved (serum creatinine of 3.2 mg/dL). A thorough investigation revealed normal leucocyte and platelet counts, a low reticulocyte count (0.5%), and no signs of active bleeding, bacterial infection, iron deficiency, or hemolysis (rare schizocytes, normal lactate dehydrogenase, bilirubin, and haptoglobin); thyroid function, folate, and vitamin B12 levels were normal, the direct Coombs test was negative, and no monoclonal spike was detected on protein electrophoresis (Table 1). Endoscopic studies excluded gastrointestinal bleeding and cervico-thoraco-abdomino-pelvic computed tomography did not identify any suspicious lesions. Serum polymerase chain reaction (PCR) of cytomegalovirus and Epstein-Barr virus were negative, while PVB19 PCR was positive ( $10.6 \times 10^{10}$  UI/mL [11 log]) and confirmed the diagnosis of PVB19-associated PRCA. Even though IS was adjusted and MMF was discontinued, the patient's hemoglobin level declined (nadir hemoglobin level of 6.6 g/dL) with a sustained high PVB19 plasma load. He was then admitted to the hospital where he received two blood transfusions and was started on intravenous immunoglobulin (IVIG), a total dose of 2 g/kg. Since the patient was initially not responding as expected, hematology was consulted and a bone marrow aspirate was performed, revealing findings compatible with recovery after erythroid aplasia. Bone marrow biopsy revealed hypoplasia with relative erythroid hyperplasia. The patient was discharged after 20 days with hemoglobin of 8 g/dL and reduced PVB19 load. He re-initiated MMF at a lower dose.

In the 1st year post-KT, the patient was admitted twice due to the recurrence of PVB19-associated PRCA occurring every 4 months. On both occasions, he received IVIG infusions (2 g/kg), and after the second recurrence, the maintenance IS was changed to a TRANSFORM scheme with prednisolone, tacrolimus, and everolimus. Additionally, due to deteriorating kidney function, a kidney biopsy was performed and revealed borderline acute T-cell mediated rejection with significant signs of chronicity (50% of interstitial fibrosis and tubular atrophy). To guarantee infection control, IS was not increased. Considering the recurrence of PVB19-associated PRCA, despite the use of a TRANSFORM IS scheme in a patient with chronic allograft dysfunction, high immunologic risk, and the probable nephrotoxicity of foscarnet, preventive therapy with IVIG (0.4 mg/kg) every 4 weeks was started.

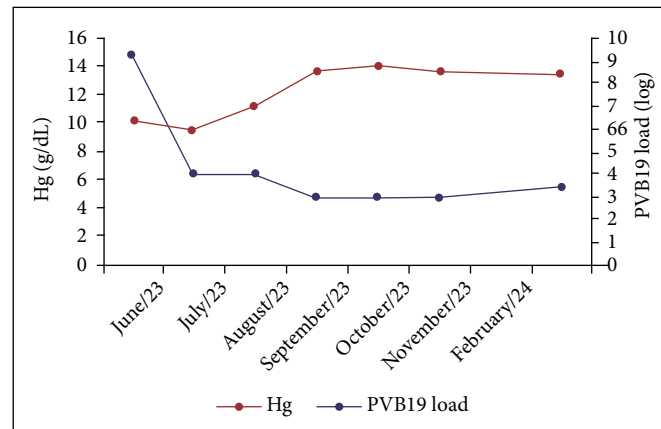
After 9 months of maintenance therapy, the patient continues to be followed up at nephrology consultation, and no relapse was identified. The evolution of hemoglobin levels and PVB19 load after the last episode of PVB19-associated PRCA relapse is described in Fig. 1.

To promote an individualized IS prescription, an ImmunoBiogram® was recently performed. The patient presented a z score of 1.5 for tacrolimus, 1.2 for everolimus, and -1.5 for MMF, and an activation ratio of 2.11 (reference level > 5.2). Consequently, we are planning an IS reduction, followed by an ImmunoBiogram® control, which will potentially allow the suspension of IVIG maintenance therapy.

**Table 1.** Laboratory results at initial hospitalization admission.

Parameter	Value (reference range)
Hemoglobin (g/dL)	6.6 (12-16)
Leucocytes ( $\times 10^9/L$ )	4.1 (4-11)
Platelets ( $\times 10^9/L$ )	275 (150-400)
C-reactive protein (mg/L)	0.9 (< 3)
Serum creatinine (mg/dL)	3.60 (0.51-0.95)
Serum urea (mg/dL)	151 (10-50)
Serum sodium (mEq/L)	139 (135-147)
Serum potassium (mEq/L)	5.0 (3.5-5.1)
Serum chlorine (mEq/L)	102 (101-109)
Reticulocyte ( $\times 10^{12}/L$ )	0.004 (0.025-0.090)
Lactate dehydrogenase (U/L)	250 (135-225)
Total bilirubin (mg/dL)	0.9 (< 1.2)
Haptoglobin (mg/dL)	87 (50-320)
Iron (ug/dL)	51 (53-167)
Transferrin saturation (%)	26 (20-50)
Ferritin (ng/mL)	1646 (22-336)
Folate (ng/mL)	3.7 (2.2-17.5)
Vitamin B12 (pg/mL)	462 (187-883)
Thyroid-stimulating hormone (UI/mL)	0.30 (0.35-4.94)
Free thyroxine (ng/mL)	0.84 (0.7-1.48)

Source: Elaborated by the authors.



Source: Elaborated by the authors.

**Figure 1.** Evolution of hemoglobin and PVB19 load after IVIG maintenance therapy.

## DISCUSSION

PVB19 is a linear DNA virus of the Parvoviridae family. It has a tropism for the erythrocyte P antigen, a cellular receptor expressed on red blood cells, erythroid precursors, placenta, and endothelial cells. PVB19 replicates in erythroid precursors and, due to its direct cytotoxic effect, blocks erythropoiesis and promotes red blood cell destruction.<sup>2,3</sup>

Most commonly, symptomatic PVB19 infection occurs in children, but it can also occur in solid-organ transplant recipients. It can be transmitted through respiratory droplets, transplacental infections, and blood transfusions. Regarding KT recipients, PVB19 infection can occur either through reactivation of the latent virus, persistent viremia, or transmission from the allograft.<sup>1,3,5</sup> Routine screening of both KT donor and recipient serostatus is, however, not recommended.<sup>6</sup>

PVB19 infection may manifest clinically through symptoms such as skin rash, arthropathy, and organ-invasive disease.<sup>5</sup> Allograft dysfunction can manifest as collapsing glomerulopathy and thrombotic microangiopathy, and can induce graft loss.<sup>7</sup> Additionally, the increased risk of allograft rejection following the reduction of IS has to be considered.<sup>3,5</sup> PVB19 infection can cause pancytopenia and, most commonly, PVB19-associated PRCA, with important implications for patient and allograft survival.<sup>8</sup> As previously mentioned, anemia is a common finding in the early post-KT period and many contributing factors have

been identified.<sup>3</sup> Our patient developed aggravated anemia without an apparent cause after a thorough investigation, raising the hypothesis of PVB19-associated PRCA. This typically occurs in the first 3 months after KT and is characterized by persistent normocytic normochromic anemia with low reticulocyte counts, which is unresponsive to erythropoietin.<sup>2,8,9</sup> Bone marrow studies, typically performed if the diagnosis is not obvious, show giant pronormoblasts or absent erythroid precursors.<sup>8</sup> One significant risk factor is induction IS, particularly thymoglobulin,<sup>5</sup> as was the case with our patient.

Due to its non-specific clinical manifestations and the wide differential diagnosis regarding anemia in KT recipients, the diagnosis of PVB19-associated PRCA is frequently delayed.<sup>10</sup> It can be made either through the detection of antibodies or direct viral DNA detection in blood, bone marrow, or affected tissues. In the setting of solid organ transplants, where a proper humoral response might be lacking and a high viral load may be associated with falsely negative serology, the absence of PVB19 antibodies does not exclude this diagnosis and viral detection should be performed.<sup>2,11</sup> Higher viral loads are more commonly associated with an increased risk of symptomatic disease. Nevertheless, considering that in certain patients the virus is still detectable years after the acute phase of infection, a positive PCR for PVB19 does not necessarily reflect an acute infection.<sup>6</sup> The concomitant detection of acute anemia and positive PCR for PVB19 confirmed the diagnosis in our patient.

The initial therapeutic approach involves supportive measures, including blood transfusions and IS reduction. However, balancing the benefits of controlling viral infection with the heightened risk of allograft rejection is crucial when considering a reduction in IS. If this approach proves insufficient, treatment with IVIG (400 mg/kg/day for 5 days) is usually successful due to the considerable concentration of anti-PVB19 IgG antibodies present in IVIG, which can neutralize the virus.<sup>4,12</sup> A higher daily dose can also be administered (with a total dose of 2 g/kg), but the increased risk of nephrotoxicity associated with doses  $\geq 1$  g/kg/day should be considered.<sup>6</sup> Our patient developed the first episode of PVB19-associated PRCA 3 months after KT and was initially successfully treated with MMF suspension, IVIG therapy, and IS adjustment to a TRANSFORM scheme in an attempt to reduce tacrolimus dosage while taking advantage of the potential antiviral properties of the mTOR inhibitor, similar to cytomegalovirus and BK polyomavirus infections.

Monitoring therapy response with serial PCR for PVB19 may not be appropriate, since some asymptomatic patients maintain low-grade viremia months after effective therapy. Consequently, monitoring hemoglobin levels and ordering PCR for PVB19 in case of aggravated anemia is possibly the best approach to follow these patients.<sup>6</sup> Recurrence of PVB19-associated PRCA occurs in up to 33% of patients, particularly those who had primary infection post-KT and those who received heavy IS, which limits patients' capability of clearing the virus.<sup>11</sup> At the first episode of relapse, a second dose of IVIG is usually administered.<sup>10</sup> However, in the case of multiple recurrences, alternative therapies should be considered. *In vitro* data suggests that cidofovir may be effective in clearing viral load, but more studies are necessary.<sup>6</sup> Foscarnet is more commonly used for the treatment of cytomegalovirus, herpes simplex virus, and varicella-zoster virus infections in KT recipients. There have been small reports demonstrating foscarnet's efficacy in the treatment of recurrent PVB19-associated PRCA in KT recipients.<sup>8</sup> One major concern is its nephrotoxicity, prompting consideration of prolonged IVIG infusions in patients with allograft dysfunction. Prolonged IVIG infusions have been reported in immunocompromised patients, such as those with human immunodeficiency virus infection, who present with severe refractory anemia. Normalization of red blood cell counts and reduction of serum PVB19 load seem to be achieved after therapy.<sup>12</sup> During the first year post-KT and despite IS reduction, our patient was readmitted to the hospital due to frequent relapses. The results of the ImmunoBiogram<sup>®</sup>, a functional test that predicts the *in vitro* pharmacodynamic response to immunosuppressive treatment by measuring the metabolic activity of the patient's immunologically activated peripheral blood mononuclear cells,<sup>13,14</sup> were only available after several months of follow-up. These results may justify the lack of response of our patient to the TRANSFORM scheme since it was demonstrated that he is more sensitive to tacrolimus and everolimus when compared to MMF. The activation ratio of 2.11 is also compatible with a "highly immunosuppressed" patient.<sup>13,14</sup> The frequent recurrences in this case highlighted the need for alternative therapies. The fact that the patient had chronic allograft dysfunction made the management of recurrent PVB19-associated PRCA more challenging since drugs such as foscarnet were not recommended. To further exacerbate this complexity, following the reduction of IS, our patient developed borderline acute T-cell mediated rejection, necessitating an intensification of IS, which was not performed as it could potentially jeopardize infection control. Therefore, considering the facts that allograft rejection limits the reduction of IS, the need for blood transfusions and the inherent immunization in a young patient who will possibly require a second KT, the undesirable nephrotoxicity of foscarnet, the successful response to IVIG, and considering the patient's quality of life, chronic IVIG therapy every 4 weeks was thought to be the best choice. Despite the absence of precise guidelines for chronic PVB19 infection management, including the duration of therapy, maintenance therapy with prolonged IVIG infusions may be a therapeutic option for recurrent PRCA, but more studies are necessary to define the appropriate duration of treatment. With this strategy, in a 9-month follow-up, our patient remains free of relapses with stable serum hemoglobin and reduced PVB19 load.

In this particular patient, individualized IS selection could be enough to prevent rejection while avoiding recurrent infections. According to the ImmunoBiogram<sup>®</sup> results suggestive of overimmunosuppression, we will reduce the IS. It is imperative to

frequently monitor the changes in the ImmunoBiogram® as the patient's immune status can vary over time and depending on the clinical condition. We will, therefore, repeat the ImmunoBiogram® during follow-up to obtain a pattern of the patient's immune response that allows a tailored IS therapy to his needs.

## CONCLUSION

The diagnosis and management of PVB19-associated PRCA is challenging. Regarding recurrent disease, prolonged IVIG treatment appears to be a useful treatment strategy, but more studies are necessary to prove its efficacy and determine the appropriate duration of therapy. It is also fundamental to tailor the IS as much as possible to the individualized immunologic profile of the patients to prevent overimmunosuppression.

## CONFLICT OF INTEREST

Nothing to declare.

## AUTHOR'S CONTRIBUTION

**Substantive scientific and intellectual contributions to the study:** Paulo N, Ferreira C, Cerqueira A; **Conception and design:** Paulo N, Ferreira C, Cerqueira A; **Data analysis and interpretation:** Paulo N, Ferreira C; **Article writing:** Paulo N, Ferreira C; **Critical revision:** Cerqueira A, Sampaio S, Pestana M; **Final approval:** Cerqueira A, Sampaio S, Pestana M. **Note:** Where indicated, Paulo N and Ferreira C contributed equally.

## DATA AVAILABILITY STATEMENT

All datasets were generated or analyzed in the current study.

## FUNDING

Not applicable.

## ACKNOWLEDGEMENT

Not applicable.

## REFERENCES

1. Sharma N, Bajwa R. Parvovirus infection-related anemia after kidney transplantation. *Case Rep Transplant* 2020;6437392. <https://doi.org/10.1155/2020/6437392>
2. Gang S, Park S, Min SI, Hong J, Chang YH, Ha J, et al. Recurrent parvovirus B19 infection-associated pure red cell aplasia in a kidney transplant patient. *Korean J Transplant* 2020;34(3):199-203. <https://doi.org/10.4285/kjt.2020.34.3.199>
3. Thongprayoon C, Khoury NJ, Bathini T, Aeddula NR, Boonpheng B, Lertjitbanjong P, et al. Epidemiology of parvovirus B19 and anemia among kidney transplant recipients: a meta-analysis. *Urol Ann* 2020;12(3):241-7. [https://doi.org/10.4103/UA.UA\\_89\\_19](https://doi.org/10.4103/UA.UA_89_19)
4. An HPH, Diem HT, Cuong NT. Parvovirus B19-associated anemia in kidney transplant recipients: a single-center experience. *Transplant Proc* 2019;51(8):2693-6. <https://doi.org/10.1016/j.transproceed.2019.03.076>
5. Krishnan P, Ramadas P, Rajendran PP, Madhavan P, Alex A, Jayaschandran V, et al. Effects of parvovirus B19 Infection in renal transplant recipients: a retrospective review of three cases. *Int J Angiol* 2015;24(2):87-92. <https://doi.org/10.1055/s-0034-1371759>
6. Plentz A, Wurdinger M, Kudlich M, Modrow S. Low-level DNAemia of parvovirus B19 (genotypes 1-3) in adult transplant recipients is not associated with anaemia. *J Clin Virol* 2013;58(2):443-8. <https://doi.org/10.1016/j.jcv.2013.07.007>
7. Inamdar N, Nada R, Minz R, Kenwar DB, Singh S, Sharma A, et al. Successful re-transplantation in patient with recurrent parvovirus B19 pure red cell aplasia. *Transpl Infect Dis* 2019;21(6):e13164. <https://doi.org/10.1111/tid.13164>

8. Yu Y, Bao R, Lyu J, Wu J, Chen J, Peng W. Foscarnet therapy for pure red cell aplasia related to human parvovirus B19 infection in kidney transplant recipients: a preliminary exploration. *Infect Drug Resist* 2021;14:2911-23. <https://doi.org/10.2147/IDR.S321936>
9. Egbuna O, Zand MS, Arbini A, Menegus M, Taylor J. A cluster of parvovirus B19 infections in renal transplant recipients: a prospective case series and review of the literature. *Am J Transplant* 2006;6(1):225-31. <https://doi.org/10.1111/j.1600-6143.2005.01139.x>
10. Bentata Y. Parvovirus B19 in kidney transplantation: key points and essential pitfalls to know. *Infect Dis* 2021;53(6):404-8. <https://doi.org/10.1080/23744235.2021.1893379>
11. Eid AJ, Ardura MI. Practice ASTIDCo. Human parvovirus B19 in solid organ transplantation: guidelines from the American Society of Transplantation infectious diseases community of practice. *Clin Transplant* 2019;33(9):e13535. <https://doi.org/10.1111/ctr.13535>
12. Gor D, Singh V, Gupta V, Levitt M. A persistent parvovirus infection causing anemia in an HIV patient requiring intravenous immunoglobulin maintenance therapy. *Cureus* 2022;14(4):e24627. <https://doi.org/10.7759/cureus.24627>
13. Portoles JM, Jimenez C, Janeiro D, Lopez-Oliva MO, Ortega-Carrion A, Blaquez D, et al. The immunobiogram, a novel in vitro assay to evaluate treatment resistance in patients receiving immunosuppressive therapy. *Front Immunol* 2020;11:618202. <https://doi.org/10.3389/fimmu.2020.618202>
14. Pascual J, Jimenez C, Krajewska M, Seron D, Kotton CN, Portoles J, et al. The Immunobiogram, a novel in vitro diagnostic test to measure the pharmacodynamic response to immunosuppressive therapy in kidney transplant patients. *Transpl Immunol* 2022;75:101711. <https://doi.org/10.1016/j.trim.2022.101711>