


# Guillain-Barré Syndrome Secondary to Cytomegalovirus Infection in a Pediatric Kidney Transplant Patient

Daniela Saraiva Guerra Lopes<sup>1,\*</sup> , Iracy de Oliveira Araujo<sup>1</sup> , Rodrigo Melo Gallindo<sup>1</sup> ,  
Cassio Tâmara Ribeiro<sup>1</sup> , Paula Andréa dos Santos Genesio<sup>1</sup> 

1. Instituto de Medicina Integral Prof. Fernando Figueira  – Recife (PE) – Brazil.

\*Corresponding author: [danielasaraiva@gmail.com](mailto:danielasaraiva@gmail.com)

Section editor: Ilka de Fátima Santana F Boin 

Received: May 18, 2024 | Approved: Ago 14, 2024

## ABSTRACT

The association between Guillain-Barré syndrome (GBS) and cytomegalovirus (CMV) is already well established in the literature, first reported in 1967. However, this association is rare in solid organ transplant patients, although the incidence of symptomatic CMV infection is higher in this population. Due to its potential severity, high morbidity and mortality, the possibility of GBS cannot be ruled out in the case of neurological complications in transplant patients. In this report, a case of GBS secondary to CMV is described in an eight-year-old kidney transplant patient in the pediatric age group, an interval with an even greater scarcity of reports on this association. The patient had negative antibodies (IgG and IgM) for CMV in pre-transplant tests, while the donor had positive IgG antibodies, meaning a higher risk of developing the disease. The clinical condition began approximately two months after the transplant, with classic symptoms and the evolution of GBS. The clinical aspects, diagnosis, treatment and evolution of the disease are discussed, in addition to the evidence in the world literature.

**Descriptors:** Kidney Transplant; Child; Guillain-Barré Syndrome; Cytomegalovirus.

## *Síndrome de Guillain-Barré Secundária à Infecção por Citomegalovírus em Paciente Pediátrico Transplantado Renal*

## RESUMO

A associação entre síndrome de Guillain-Barré (SGB) e citomegalovírus (CMV) já é bem estabelecida na literatura, tendo sido primeiramente relatada em 1967. Porém, essa associação é rara em pacientes transplantados de órgãos sólidos, apesar da incidência de infecção sintomática por CMV ser maior nesta população. Devido ao seu potencial de gravidade, alta morbidade e mortalidade, a possibilidade de SGB não pode ser afastada em caso de complicação neurológica em pacientes transplantados. Neste relato, é descrito um caso de SGB secundária a CMV em um paciente transplantado renal de 8 anos de idade, na faixa etária pediátrica, intervalo com ainda maior escassez de relatos sobre essa associação. O paciente apresentava sorologia (IgG e IgM) negativa para CMV em exames pré-transplante, enquanto o doador possuía IgG positiva, havendo dessa forma alto risco de desenvolvimento da doença. A abertura do quadro clínico ocorreu cerca de dois meses após a realização do transplante, com sintomas e evolução clássicos de SGB. São discutidos os aspectos clínicos, diagnósticos, de tratamento e de evolução da doença, além da relação com as evidências presentes na literatura mundial.

**Descritores:** Transplante Renal; Criança; Síndrome de Guillain-Barré; Citomegalovírus.

## INTRODUCTION

Cytomegalovirus (CMV) infection is one of the most common infectious complications after solid organ transplantation.<sup>1</sup> It can occur early or late but is more common in the first three months post-transplant due to the more intense immunosuppressive state. Its prevalence in this population is essential, as it has a significant impact on the morbidity and mortality of these patients, significantly affecting their survival and graft survival.<sup>2</sup>

In kidney transplant patients, the development of CMV occurs either through primary infection (through contact with bodily fluids or through transplantation of an organ from a CMV-seropositive patient into a seronegative recipient) or through reactivation of a latent CMV infection due to immunosuppression state.<sup>1-3</sup>

Guillain-Barré syndrome (GBS) is the most common cause of flaccid paralysis in the world, with an incidence rate of 0.5 to 4 cases per 100,000 in the general population, with its peak incidence in young adults between 20 and 40 years old.<sup>4</sup>

It is characterized by symmetrical and progressive motor weakness (initially in the lower limbs), associated with the loss of deep tendon reflexes. It may also be associated with pain, paresthesia and loss of limb sensitivity. Other more severe complications are acute respiratory failure and autonomic dysfunction. Around 30% of patients require ventilatory support during the disease process.<sup>5</sup>

The association of CMV with GBS is already well established in the literature, having been first reported in 1967.<sup>6</sup> CMV is the second most common cause of GBS and the leading viral cause. Still, it is more common in patients with HIV or bone marrow transplants.<sup>7-8</sup>

Despite the high incidence of CMV infection in this population, this association is infrequent in solid organ recipients, with few cases described in the literature.<sup>9-14</sup> Among kidney transplant recipients, Ostman and Chacko 2018 conducted an extensive literature review, finding only 12 cases, none in the pediatric age group.<sup>15</sup>

## CASE DESCRIPTION

An 8-year-old male patient with grade V chronic kidney disease secondary to congenital malformation of the urinary tract (neurogenic bladder and Prunne-Belly syndrome) has been on a renal replacement therapy program (hemodialysis) for two years.

He underwent a deceased donor kidney transplant at the Instituto de Medicina Integral Prof. Fernando Figueira, with a cold ischemia time of 13 hours, using basiliximab as induction of immunosuppression and subsequent maintenance with a triple regimen: Tacrolimus, sodium mycophenolate and prednisone. The patient had negative pre-transplant serology (IgG and IgM) for CMV, toxoplasmosis, Chagas disease and Epstein Barr. In addition to negative VDRL and serology for HIV and HTLV, he also had non-reactive Hbs-Ag and AntiHCV with reactive Anti-HbS.

Deceased female donor, 14 years old, with cause of death of traumatic brain injury and positive IgG serologies for CMV and toxoplasmosis, the others being negative. Basal creatinine of 0.5 mg/dL (input and final).

The patient had no complications in the immediate post-transplant period, evolving with rapid recovery of renal function. He was discharged from the hospital seven days after transplantation with a creatinine of 1.11 mg/dL and was using immunosuppression and usual prophylaxis. During outpatient follow-up, he had no clinical complications, maintaining good diuresis and reaching a creatinine of 0.58 mg/dL.

61 days after the transplant, the patient was readmitted to the service with complaints of paresthesia in the lower limbs and changes in gait. These symptoms began approximately three days before admission. He denied fever or any other symptoms. Computed tomography of the skull without contrast was requested urgently, and no changes were observed. Serum tests collected on admission also showed no significant changes (Table 1), maintaining renal function within normal limits. Urine tests showed urinary infection, with a positive culture for *Klebsiella pneumoniae* above 100,000 CFU, and treatment with ceftriaxone 100 mg/kg/day was started, carried out for seven days, with a negative control urine culture.

48 hours after admission, the patient presented a progression of neurological symptoms, with paresthesia in the hands and strength deficits in the lower limbs. He was evaluated by pediatric neurology, whose clinical neurological examination showed reduced profound sensitivity, tetraparesis with distal predominance, abolished reflexes and ataxic gait. The hypothesis of deep and peripheral sensory syndrome and motor syndrome, possibly associated with B vitamin deficiency, neurosyphilis or secondary to drugs. Serum tests were requested, as shown in Table 2, collection of cerebrospinal fluid (CSF) and magnetic resonance imaging (MRI) of the skull and cervical, thoracic and lumbosacral spines with contrast.

Despite the serum level of Tacrolimus being within normal limits, the team decided to change the medication to Sirolimus due to the potential neurotoxicity of the calcineurin inhibitor. Vitamin D supplementation was also started.

Between the fourth and fifth days of the hospital stay, the patient presented a significant worsening of neurological symptoms, with strength deficits in the lower and upper limbs and an inability to walk or even stand. He also had paresthesia in his lips, difficulty swallowing and frequent choking. It was decided to apply a nasoenteral tube diet to avoid bronchoaspiration until the results of exams and a new opinion from pediatric neurology. A place in the pediatric Intensive Care Unit (ICU) was also requested, and CSF collection was performed, with results as shown in Table 3 below:

**Table 1.** Admission exams.

Exam	Results	Reference value
Creatinine	0.70 mg/dL	0.57 – 0.88 mg/dL
Urea	38 mg/dL	15 – 40 mg/dL
Oxaloacetic transaminase	24 U/L	5 – 34 U/L
Pyruvic transaminase	22 U/L	0 – 55 U/L
Total bilirubin	0.37 mg/dL	0.2 – 1.20 mg/dL
Potassium	3.9 mmol/L	3.5 – 5.1 mmol/L
Sodium	135 mmol/L	136 – 145 mmol/L
Chloride	102 mmol/L	98 – 107 mmol/L
Alkaline reserve	20 mmol/L	20 – 28 mmol/L
Uric acid	3.4 mg/dL	2.6 – 6.0 mg/dL
Calcium	9.5 mg/dL	8.8 – 10.8 mg/dL
Phosphorus	4.8 mg/dL	2.3 – 4.7 mg/dL
Alkaline phosphatase	220 U/L	Less than 500 U/L
Magnesium	1.6 mg/dL	1.6 – 2.6 mg/dL
Blood glucose	87 mg/dL	70 – 99 mg/dL
Total cholesterol	155 mg/dL	Desirable: less than 170mg/dL
Hemoglobin	11.6 g/dL	12 – 16 g/dL
Hematocrit	38.2%	35 – 47%
Leukocytes	5.100 / $\mu$ L	3,500 - 11,000 / $\mu$ L
Neutrophils	61%	50 – 70%
Monocytes	8%	2 – 12%
Lymphocytes	30%	20 – 30%
Platelets	233,000 / $\mu$ L	150,000 - 450,000 / $\mu$ L

Source: Elaborated by the authors

**Table 2.** Exams requested after Neurology evaluation.

Exam	Results	Reference value
Vitamin B12	313 pg/mL	210-980 pg/mL
25-OH-vitamin D	16 ng/mL	Deficiency: less than 20ng/mL
TSH	2.53 $\mu$ UI/mL	0.4-5.0 $\mu$ UI/mL
Free T4	1.61 ng/dL	0.8-1.75 ng/dL
Thyroxine – T4	13.1 $\mu$ g/dL	6.4 – 13.3 $\mu$ g/dL
VDRL	Non-reactive	Non-reactive
Tacrolimus serum level	8.6 ng/mL	5.0-20 ng/mL

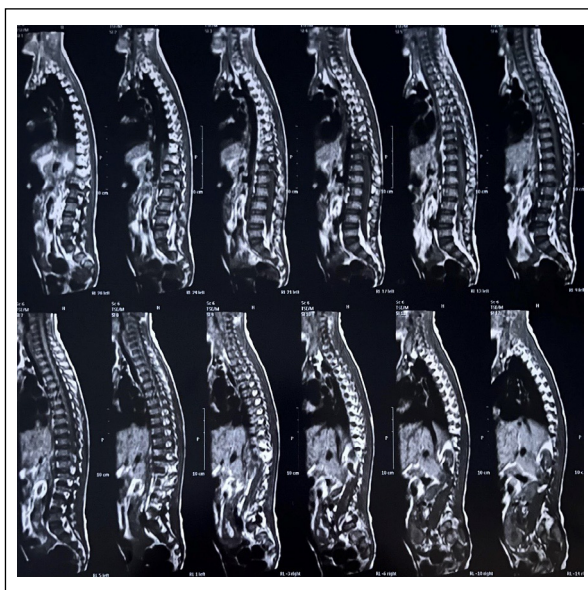
Source: Elaborated by the authors

**Table 3.** Cerebrospinal fluid assessment result.

Parameter	Result	Reference value
Aspect	Clear and colorless	Clear and colorless
Glucose	86 mg/dL	60-80 mg/dL
Proteins	335 mg/dL	15-45 mg/dL
Cell count	0 / mm <sup>3</sup>	Up to 3 mm <sup>3</sup>
RBC count	absent	absent
Culture	Negative	Negative

Source: Elaborated by the authors

An MRI of the skull and spine with contrast was also performed. It showed a slight thickening of the roots of the cauda equina, with slight enhancement by venous contrast, an aspect suggestive of inflammatory changes/polyradiculopathies. Other changes were absent (Figure 1). An electroneuromyography of the four limbs was also requested, but it was not performed.



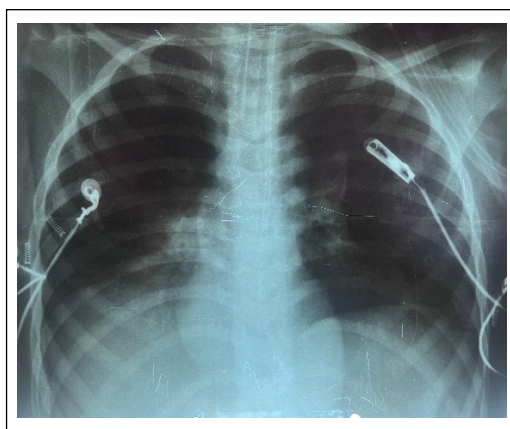
Source: Authors' archive.

**Figure 1.** MRI of the spine.

On the 7th day of hospitalization, the patient began to present dysphoric speech, associated with the other symptoms already reported and was reevaluated by pediatric neurology, which, based on the clinic and examinations (signs of polyradiculopathy on MRI associated with CSF with increased proteins without infectious signs), diagnosed flaccid areflexic tetraparesis – Guillain-Barré syndrome.

The patient was transferred to the pediatric ICU, and intravenous immunoglobulin 400 mg/kg/day was started. In investigating the cause of the neurological condition, serum and CSF serology and PCR for serum CMV were collected.

On the 8th day of hospitalization, already in the pediatric ICU, the patient developed severe respiratory failure, requiring orotracheal intubation and assisted mechanical ventilation support. Chest X-ray suggestive of left diaphragmatic paralysis (Figure 2).



Source: Authors' archive.

**Figura 2.** Radiografia de tórax

Serum serology results showed active CMV infection (IgG 97 AU/mL and IgM 9.9 index), and treatment with intravenous ganciclovir 10 mg/kg/day was initiated. Subsequently, the PCR result for serum CMV confirmed the diagnosis with 20 copies/mL. Serology for CMV in CSF also corroborated the diagnosis with reactive IgG and strong reactive IgM.

The patient remained clinically stable in the pediatric ICU, completing five days of intravenous immunoglobulin. The patient was extubated on the 15th day of his hospital stay. He tolerated room air well, with good lung expansion and spontaneous breathing, but he maintained flaccid quadriplegia and a swallowing disorder.

From that moment on, while still in the pediatric ICU, he began a rehabilitation program with respiratory physiotherapy, motor physiotherapy and speech therapy. On the 19th day of hospitalization, he was discharged from the ICU to the ward after accepting an oral soft diet and progressive recovery of movement, especially in the upper limbs.

During the period in the ward, he continued treatment with ganciclovir, completing 21 days. He also underwent an intensive rehabilitation program with motor physiotherapy and speech therapy, with progressive improvement. He also presented a new episode of urinary tract infection (*Escherichia coli*), being treated for seven days with piperacillin-tazobactam.

The patient was discharged after 36 days of hospitalization, with satisfactory recovery from the neurological condition and only changes in gait, to undergo outpatient physiotherapeutic monitoring. During the hospitalization, renal function did not change, and good diuresis and serum urea and creatinine levels were maintained within the patient's baseline.

After discharge from the hospital, he maintained outpatient follow-up, with a complete improvement in neurological symptoms and an adequate return to social and school activities two months after the onset of the condition.

## DISCUSSION

CMV is a herpes virus common in the general population. It has a long life cycle and persists latently, mainly in endothelial cells, fibroblasts, and monocytes. Its transmission occurs through body fluids and, in most immunocompetent people, it is asymptomatic or oligosymptomatic, self-limited, with mild and non-specific symptoms, such as fever, asthenia and mild to moderate arthralgia.<sup>3</sup>

In immunosuppressed patients, the disease can progress more seriously, leading to hepatosplenomegaly, pancytopenia, changes in liver enzymes, gastrointestinal symptoms, retinitis, pneumonia, pericarditis and encephalitis.<sup>2,3</sup> The patient reported that the disease evolved asymptotically, with no clinical or laboratory test changes until hospitalization.

In kidney transplant patients, a high incidence of CMV infection is reported, up to 32%.<sup>16,17</sup> And although the incidence of GBS in the general population who contract CMV is reported to be 1:1,000, there is no proportional increase in the transplant patient population.<sup>7,8,16-18</sup> Some authors suggest that the immunosuppressive therapy used by these patients could act as a protective factor due to the autoimmune nature of GBS.<sup>18</sup>

Therefore, it is important to highlight that GBS is a disease of autoimmune etiology, which consists of the production of antibodies against gangliosides present in the myelin sheath or axons of peripheral nerves, leading to acute or subacute inflammatory demyelinating polyradiculopathy. It generally occurs after an infectious condition (bacterial or viral). Still, it has been related to drug use and surgical trauma, and some cases remain without a defined cause, even after investigation.<sup>4,5</sup> Although GBS, in most cases, is a self-limited disease, with symptoms peaking between two and four weeks into the illness, it still has a relatively high mortality rate, ranging from 4% to 10%, depending on the speed of diagnosis, installation of multidisciplinary clinical support and initiation of treatment.<sup>4,7</sup> In addition to the high mortality rate, around 20% to 30% of patients require assisted mechanical ventilation, and between 15% and 30% of patients have some residual neurological deficit to a lesser or greater extent in the long term.<sup>5,6,9,19</sup>

Therefore, when there is a clinical suspicion of GBS, for greater effectiveness and to reduce the possibility of sequelae, treatment must be promptly instituted, which consists of the use of intravenous immunoglobulin and/or plasmapheresis, in addition to the necessary support depending on the severity of the condition and treatment of the underlying cause of the disease.<sup>4,5,9,19</sup> In the case of GBS secondary to CMV infection, treatment with specific intravenous (ganciclovir) or oral (valganciclovir) antiviral medication was performed and recommended in all reported cases.<sup>10-13,15,17,18</sup>

The patient in our report presented classic symptoms and evolution of GBS, with ascending symmetric flaccid quadriplegia, paresthesias and progression to acute respiratory failure in the second week of the disease. The response to treatment was quick and satisfactory, with the child overcoming the need for ventilatory support eight days after the institution of specific therapy and showing full recovery from the neurological condition two months after the onset of symptoms.

In a recent review, Khan et al.<sup>5</sup> defined the challenges for diagnosis and treatment in underdeveloped and developing countries due to limited access to diagnostic and therapeutic resources, leading to inadequate or late diagnosis.

Despite the favorable outcome, the reported case showed deficiencies and weaknesses in the country's public health system, such as the difficulty of carrying out adequate medical prophylaxis for CMV in serodivergent recipients (IgG positive donor/IgG negative recipient) due to the high cost of the indicated medication, and the delay in carrying out and releasing the results of more complex tests, such as magnetic resonance imaging, serology and PCR for CMV. Furthermore, the difficulty in rapid assessment by a specialist (pediatric neurologist) and the failure to carry out a vital test to confirm the diagnosis (electroneuromyography of the limbs) also contributed to some delay in the diagnosis and institution of treatment.

## CONCLUSION

CMV infection is a relatively common infectious complication after kidney transplantation, occurring in a significant percentage of this population. In turn, GBS is an uncommon but severe and potentially fatal complication of CMV infection. Although the association of these diseases is infrequent in solid organ recipients, especially in the pediatric age group, professionals at transplant centers must understand them, as early diagnosis and the institution of therapeutic measures quickly and effectively increase the chances of favorable outcomes for the patient.

## CONFLICT OF INTEREST

Nothing to declare.

## AUTHOR'S CONTRIBUTION

**Substantive scientific and intellectual contributions to the study:** Lopes DSG, Araújo IO, Gallindo RM, Ribeiro CT, Genésio PAS; **Conception and design:** Lopes DSG, Gallindo RM; **Data analysis and interpretation:** Lopes DSG; **Article writing:** Lopes DSG, Araújo IO; **Critical review:** Lopes DSG, Araújo IO; **Final approval:** Lopes DSG, Araújo IO.

## DATA AVAILABILITY STATEMENT

All dataset were generated/analyzed in the current study.

## FUNDING

Not applicable.

## ACKNOWLEDGEMENT

We would like to thank the entire multidisciplinary team involved in assisting pediatric kidney transplant patients at our institution

## REFERENCES

1. Lopau K, Greser A, Wanner C. Efficacy and safety of preemptive anti-CMV therapy with valganciclovir after kidney transplantation. *Clinical Transplantation*. 2007 Jan; 21(1):80–5. <https://doi.org/10.1111/j.1399-0012.2006.00586.x>
2. Raval AD, Kistler KD, Tang Y, Murata Y, Snyderman DR. Epidemiology, Risk factors and Outcomes Associated with Cytomegalovirus in Adult Kidney Transplant Recipients: A Systematic Literature Review of Real-World Evidence. *Transplant Infectious Disease*. 2020 Oct 4. <https://doi.org/10.1111/tid.13483>
3. Abou-Jaoudé M, El Hage S, Akiki D, Fadlallah M, Ghaith AK, Dib A. Cytomegalovirus infection in kidney transplant patients: Prevalence, risk factors, and impact on outcome – A local multicentre experience. *Transplant Immunology*. 2021 Dec; 69:101473. <https://doi.org/10.1016/j.trim.2021.101473>
4. Shahrizaila N, Lehmann HC, Kuwabara S. Guillain-Barré syndrome. *The Lancet*. 2021 Mar 27; 397(10280):1214–28 [https://doi.org/10.1016/s0140-6736\(21\)00517-1](https://doi.org/10.1016/s0140-6736(21)00517-1)
5. Khan SA, Das PR, Nahar Z, Dewan SMR. An updated review on Guillain-Barré syndrome: Challenges in infection prevention and control in low- and middle-income countries. *SAGE open medicine*. 2024 Jan 1; 12. <https://doi.org/10.1177/20503121241239538>
6. Klemola E, Weckman N, Haltia K, Kääriäinen L. The Guillain-Barré Syndrome Associated with Acquired Cytomegalovirus Infection. *Acta Medica Scandinavica*. 2009 Apr 24; 181(5):603–7. <https://doi.org/10.1111/j.0954-6820.1967.tb07283.x>
7. Awwad A, Ghada Ashmawi, Hassan Y, Asser S. Association between Guillain-Barré syndrome and Herpes virus family members, A Multiplex PCR study. *Egyptian Journal of Medical Microbiology*. 2020 Jan 1; 29(1):173–9. <https://doi.org/10.21608/ejmm.2020.249876>
8. Dourado Junior MET, Sousa BF de, Costa NMC da, Jeronimo SMB. Cytomegalovirus infection in Guillain-Barré syndrome: a retrospective study in Brazil. *Arquivos de Neuro-Psiquiatria*. 2021 Aug 25 [cited 2022 Oct 18]; 79:607–11. <https://doi.org/10.1590/0004-282X-ANP-2020-0464>

9. El-Sabroun RA, Radovancevic B, Ankoma-Sey V, Van Buren and CT. Guillain-Barre syndrome after solid organ transplantation. *Transplantation*. 2001 May; 71(9):1311–6. <https://doi.org/10.1097/00007890-200105150-00023>
10. Wadhai KG, Kute VB, Ghodela VA, Shah MK, Patel HV, Gera DN, et al. Guillain-Barré syndrome post renal transplantation – A rare entity. *Clinical Queries: Nephrology*. 2015 Jan; 4(1-2):21–2. <https://doi.org/10.1016/j.cqn.2015.11.004>
11. Steger CM, Antretter H, Höfer D. Guillain-Barré Syndrome due to CMV Reactivation after Cardiac Transplantation. *Case Reports in Cardiology*. 2012; 2012:1–3. <https://doi.org/10.1155/2012/506290>
12. Ting P, Camaj A, Bienstock S, Choy A, Mitter SS, Barghash M, et al. Guillain-Barré Syndrome After Primary Cytomegalovirus Infection in a Patient With a Heart Transplant. *JACC: Case Reports*. 2021 Mar 1; 3(3):455–8. <https://doi.org/10.1016/j.jaccas.2020.12.037>
13. Keithi-Reddy SRR., Chakravarthi RM, Hussaini SM, Venkatapuram RR, Murthy K. Cytomegalovirus disease with Guillain-Barré syndrome in a cadaver renal allograft recipient: cause or coincidence. *International urology and nephrology*. 2007 Apr 21; 39(3):967–70. <https://doi.org/10.1007/s11255-007-9197-7>
14. Ruiz domínguez JA, Delgado domínguez MA, Pascual pascual I, Frauca remacha E, Ruza tarrio F. Síndrome de Guillain-Barré después de trasplante hepático pediátrico. *Medicina Intensiva*. 2003 Jan; 27(6):430–3. [https://doi.org/10.1016/s0210-5691\(03\)79924-0](https://doi.org/10.1016/s0210-5691(03)79924-0)
15. Ostman C, Chacko B. Guillain-Barré syndrome post renal transplant: A systematic review. *Transplant Infectious Disease*. 2018 Nov 28; 21(1):e13021. <https://doi.org/10.1111/tid.13021>
16. Spagnoli C, Iodice A, Grazia Gabriella Salerno, Frattini D, Bertani G, Pisani F, et al. CMV-associated axonal sensory-motor Guillain-Barré syndrome in a child: Case report and review of the literature. 2016 Jan 1; 20(1):168–75. <https://doi.org/10.1016/j.ejpn.2015.11.004>
17. Merzkani M, Israel E, Sachdeva M. Primary Cytomegalovirus Infection Causing Guillain-Barré Syndrome in a Living Renal Allograft Recipient. *Case Reports in Transplantation*. 2017; 2017:1–5. <https://doi.org/10.1155/2017/7264793>
18. Jakes AD, Jani P, Bhandari S. Case Report: Guillain-Barré Syndrome following Renal Transplantation - A Diagnostic Dilemma. *Nephron Clinical practice*. 2014 Feb 4; 124(3-4):239–42. <https://doi.org/10.1159/000358087>
19. Deliceo Göbüt E, Us Ö, Işık U. Anti-GM2 antibody positive Guillain-Barré syndrome presenting with ataxia in a pediatric patient: An atypical manifestation. *Brain and Development*. 2021 Jun; 43(6):729–3. <https://doi.org/10.1016/j.braindev.2021.02.003>