

## Ocular alkali lesions in dogs. Acetylcysteine and blood serum effects

### Lesões oculares por álcali em cães. Efeitos da acetilcisteína e do soro sanguíneo

Carla Freitas CAMPOS<sup>1</sup>;  
Adriana Torrecilhas JORGE<sup>1</sup>;  
Ivía Carmen TALIERI<sup>1</sup>;  
Felipe Antônio Mendes VICENTI<sup>1</sup>;  
Evandro de TOLEDO-PIZA<sup>2</sup>;  
José Luiz LAUS<sup>1</sup>

1 Departamento de Clínica e Cirurgia Veterinária da Faculdade de Ciências Agrárias e Veterinárias da UNESP, Jaboticabal - SP  
2 Instituto de Patologia Veterinária - IPEV, Rio de Janeiro - RJ

#### Correspondence to:

JOSÉ LUIZ LAUS  
Departamento de Clínica e Cirurgia Veterinária  
Faculdade de Ciências Agrárias e Veterinárias da UNESP  
Via de acesso Prof. Paulo Donato Castellane, s/n  
14994-800 - Jaboticabal, SP  
e-mail: jllaus@fcav.unesp.br

Received: 02/05/2002  
Accepted: 27/09/2002

#### Summary

Ophthalmic lesions induced by contact with Sodium hydroxide (NaOH) at 3 M concentration in 42 dogs, divided into three groups (G1, G2 and G3), respectively treated with autogenous blood serum, acetylcysteine and a balanced saline solution were investigated. Comparison of the three groups in terms of clinical and microscopical findings showed no significant differences between groups.

#### Key-words

Eye.  
Dogs.  
Eye (lesions).

#### Introduction

Corneal ulcerations are among the most commonly occurring ophthalmic lesions<sup>1</sup>. However, when melting and progressive stromal liquefaction are present, healing becomes complicated. During the healing phases, proteases and collagenases are released and act in the removal of dead cells and debris. Epithelial cells, fibroblasts, leukocytes, some bacteria (especially *Pseudomonas* spp.) and some fungi are active producers of such enzymes.<sup>2</sup>

Chemical injuries may cause extensive lesions on the ocular surface and inside the eye.<sup>3</sup> In dogs, clinical signs of superficial lesions are pain, tear film inadequacy, corneal ulcerations, edema, and marked neovascularization.<sup>4</sup> Alkali injuries are more common than acid ones because alkalis are components of the most commonly used cleaning products and civil construction materials.<sup>5</sup> Alkalis

may cause lesions on the corneal and conjunctival epithelium, basal membrane, keratocytes and stromal nerve endings, corneal and conjunctival vascular endothelium and episclera.<sup>3</sup> Intraocular findings are hypopyon, hyphema, phthisis bulbi,<sup>5</sup> anterior synechiae, iritis, ciliary body inflammatory infiltrations and edema and opacification of lens epithelium.<sup>3</sup> Alkali-induced corneal lesions frequently result in deep ulcers and perforations.<sup>1</sup> It has been proved that collagenase activity is the responsible for the rapid and progressive evolution of stromal melting.<sup>6</sup> Therefore, effective management of melting corneal ulcers requires infection control and blockage of lytic enzyme activity.<sup>2</sup> The effectiveness of many anticollagenase substances has been proved in different illness states. Acetylcysteine, cysteine, progesterone, medroxyprogesterone, sodium citrate, sodium ascorbate, tetracycline components, thiol peptides, sodium

EDTA, calcium EDTA, penicillamine, heparin and blood serum are among the most used ones.<sup>7</sup> Acetylcysteine has been used for its stability and commercial availability.<sup>6</sup> However, the need for refrigeration, the frequent instillations required, the poor ability to penetrate the corneal stroma and relative toxicity are undesirable characteristics of this agent.<sup>3</sup>

Blood serum inhibits collagenase activity and contains proteins such as  $\alpha$ 1-antitrypsin ( $\alpha$ 1-at) and  $\alpha$ 2-macroglobulin ( $\alpha$ 2-m) that exhibit anticollagenase activity.<sup>6</sup> The  $\alpha$ 1-at is present in most body fluids, including aqueous humor and tears. Its synthesis occurs mainly in liver, but also in circulating monocytes, alveolar macrophages, enterocytes<sup>3</sup> and the human cornea.<sup>8</sup> The  $\alpha$ 2-m is a multifactorial inhibitor, able to inhibit the activity of the majority of enzymes pertaining to the four main classes, i.e., blood proteinases, metalloproteinases, aspartic proteinases and thiol proteinases.<sup>9</sup> Considering the destructive activity of alkali substances on the ocular surface and the consequent direct or indirect intraocular lesions, the purpose of the present study was to investigate the activity of anticollagenase substances in the management of corneal ulcerations and the control of intraocular lesions. To collect conclusive data, critical conditions were induced using a high molarity (3M) alkali solution.

## Material and Method

The use of animals in this investigation was according to the *ARVO Resolution on the Use of Animals in Research*. Forty-two dogs, male or female, free of systemic or ophthalmic alterations were used and divided into 3 groups: Group 1 (G1) – 15 animals,

Group 2 (G2) – 14 animals and Group 3 (G3) – 13 animals.

Autogenous blood serum was obtained by puncture of the jugular vein at three day intervals, placed in sterile bottles and refrigerated at 4°C for a maximum period of 72 hours, during which it was used for the study. Acetylcysteine (Acetilcisteína a 10%: Ophthalmos Farmácia Oftálmica S/A, São Paulo, Brazil) and 0.90% saline (Salina Fisiológica: Laboratório Farmacêutico Arboreto Ltda, Juiz de Fora, Brasil) solutions were commercially obtained and also refrigerated at 4°C.

For induction of ophthalmic lesions, the animals were previously anesthetized, receiving 1.00% acepromazine (Acepran 1%: Laboratório Univet S/A - Indústria Veterinária, São Paulo, Brazil - 0.1 mg/kg IM) as pre-treatment, followed by dissociative anesthesia with tiletamine and zolazepam (Zoletil 50: Laboratório Virbac do Brasil Indústria e comércio Ltda, S/A, São Paulo, Brazil - 7.5 mg/kg IM) 15 minutes later. Lesions were induced only in the left eye with a filter paper disk no 42 Whatman (Quanty 9cm JP 42: J. Prolab, Curitiba, Brazil) measuring 8 mm in diameter soaked in 3M NaOH and placed on the corneal superotemporal quadrant in contact with the adjacent limbus and bulbar conjunctiva for 1 minute. After disk removal, remnants of the corneal epithelium on the lesion area were removed with a sterile swab and the ocular surface was irrigated with 0.90% saline for 2 minutes. Fluoresceine-dye was used to confirm and delimit the ulcerative lesion induced. A single dose of Flunixin Meglumine (Banamine: Indústria Química e Farmacêutica Schering Plough S/A, Rio de Janeiro, Brazil - 1.1 mg/kg IV) was applied after these

procedures. To avoid accidents, the dogs were maintained with Elizabethan collars. Drops were applied to each group at 6 hour intervals throughout the observation period, beginning 4 hours after ulceration induction. G1 animals received autogenous blood serum, G2 animals received 10% acetylcysteine and G3 animals received balanced saline solution. Additionally, the dogs were topically treated with 1.00% atropine eye drops- (Atropina 1%: Allergan Produtos farmacêuticos Ltda., São Paulo, Brazil) twice a day for 7 consecutive days.

Low magnification ophthalmic examination, slit lamp biomicroscopy and the fluorescein dye test were performed at 24 hour intervals. The ocular signs evaluated were photophobia/blepharospasm, ocular discharge, conjunctival congestion and hyperemia, chemosis, and corneal transparency/opacification, edema, neovascularization and pigmentation. The characteristics of the aqueous humor (transparency, hemorrhage and debris) and the presence of uveitis, secondary cataracts and posterior segment lesions were also studied. The signs and symptoms were scored as absent - *Nihil* (no abnormalities), light (+), moderate (++), and intense (+++). The severity of ulceration was scored as follows: grade 0, no ulceration; grade 1, lesions of the epithelium and superficial third of the stroma; grade 2, lesions of the middle third of the stroma; grade 3, lesions of the deepest third of the stroma; grade 4, lesions with exposure of Descemet's membrane; grade 5, perforations.

#### Statistical analysis

The grades of the clinical signs were analyzed statistically by analysis of variance for nonparametric data

(Kruskal-Wallis test), with the level of significance set at  $p < 0.05$ . The significance of the differences in perforation between groups was analyzed by the group and period independence test (Fisher exact test).

Light microscopy studies were performed 1, 3, 10, 30 and 60 days after ulceration. For this purpose, animals were pre-treated intravenously with levomepromazine (Neozine: Rhodia S/A. Divisão Farmacêutica, São Paulo, Brazil), 1.0 mg/kg body weight. After 15 minutes, the animals received a mean dose of 12.5 mg/kg sodium thiopental (Thiopental: Cristalia produtos químicos farmacêuticos Ltda., São Paulo, Brazil) by the same route to permit positioning of the orotracheal tube and were maintained under general anesthesia with 1.5V% halothane (Halotano®: Hoechst do Brasil, São Paulo, Brazil) diluted in O<sub>2</sub> in a semi-closed system. The left eye of each dog was enucleated by subconjunctival access and fixed in Bouin solution for 24 hours. The globe was then washed in increasing ethyl alcohol concentrations from 70.00% to 100.00%. In a second stage, the globes were embedded in paraffin, cut into 4 mm thick sections, stained with hematoxylin-eosin (HE), and studied by light microscopy.

## Results

### Clinical evaluation

The clinical signs did not differ between groups and are illustrated in Figure 1. Due to the poor transparency conditions of the cornea, intraocular lesions were only observed by light microscopy. The statistical analysis by the Kruskal-Wallis test revealed no significant differences between the groups (Table 1).

### Ocular perforations (grade 5 lesions)

Perforations occurred in all groups. Five animals presented perforations between 4 and 18 days in G1, 4 animals presented perforations between 9 and 21 days in G2, and 3 animals presented perforations between 8 and 9 days in G3. The Fisher exact test revealed that the perforations were independent of group and treatment (probability=0.205).

### Light Microscopy

Signs of epithelial healing were observed since the first day after lesion induction, but were still absent in some animals (Figure 2a). After 3 days, epithelial hyperplasia, swelling of the basal layer, fibroblastic activation and polymorphonuclear migration were observed. After 10 days, the animals presented regeneration of the epithelium on Descemet's membrane in an area devoid of stroma (Figure 2b), and corneal narrowing (Figure 2b). In some dogs, hydropic degeneration of the basement membrane or swelling of the basal layer of the corneal epithelium occurred. After 30 days, the epithelium was reconstituted in all animals. In some cases it presented projections towards the stroma and was hyperplastic. Rare and small vesicles were found in one animal. Mixed epithelium with goblet cells on the Descemet membrane was present in one animal. After 60 days, the epithelium was thinner in about half

of the animals. In the other half, it presented a normal appearance, except for one animal that presented an area of hyperplasia.

Intense dissociation of the stroma into bundles (edema) occurred in one animal after 3 days, in one after 30 days (Figure 2c) and in another after 60 days. In about 30.00% of the dogs, this event was intense after 10 and 60 days, and was not observed in the remaining animals.

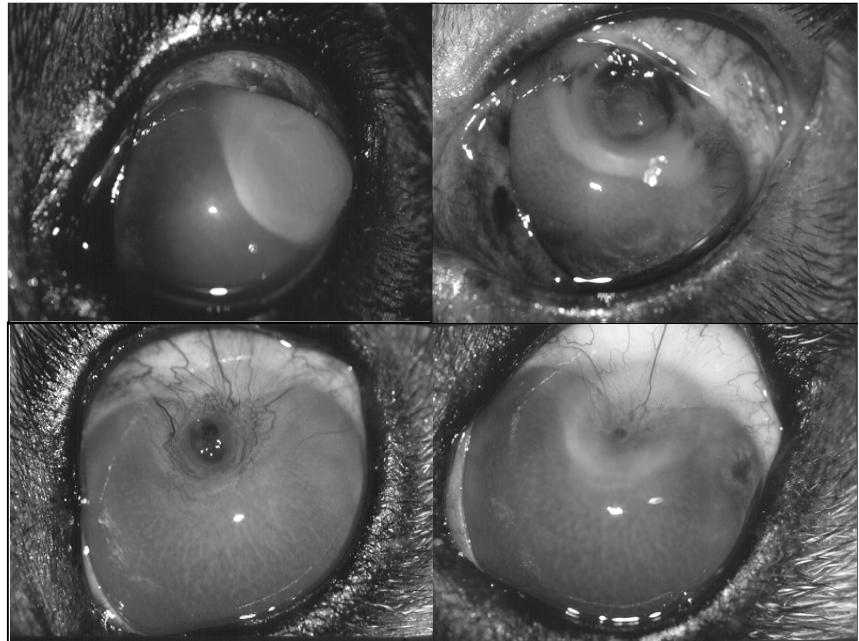
Stromal compaction occurred in all animals after 1 (Figure 2a) and 3 days, in 50,00% of the dogs after 30 days and in all of them after 60 days. Inflammatory cell infiltration (polymorphonuclear and mononuclear cells) occurred in all animals after one day, mainly consisting of neutrophils. After 10 days, about half of the dogs presented polymorphonuclear infiltration. After 30 days, most of the animals presented mononuclear cell infiltration. After 60 days, about one third of the animals presented lymphocyte infiltration. Polymorphonuclear leukocyte infiltration and partial absence of corneal endothelium occurred in most animals after one day. After 3 days, the endothelium was absent in one third of the animals, present in a small area in another third and reconstituted in the remaining dogs and in the other periods.

Corneal neovascularization occurred after 10 days (Figure 2b), being moderate in most of the animals and mild in the others. After 30 days, it was mainly moderate (Figure 2c) and after

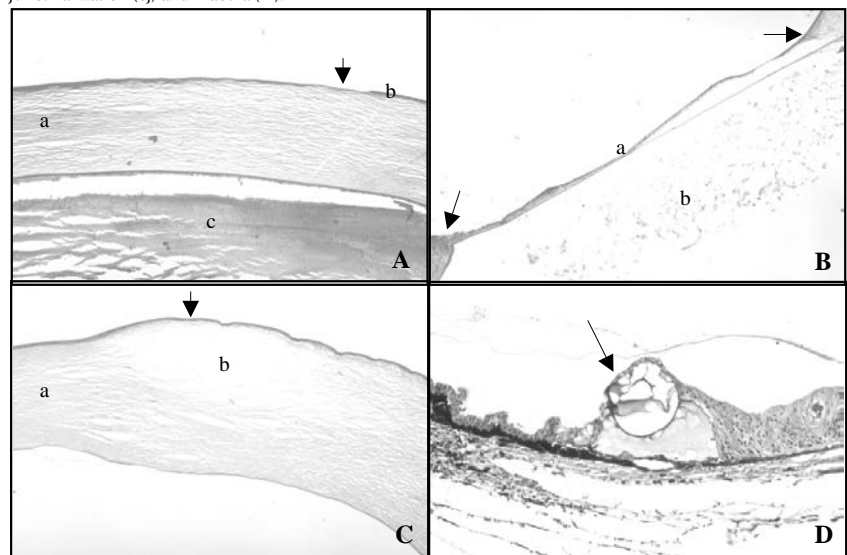
**Tabela 1**

Número e porcentagem de bovinos com anticorpos contra o vírus da Estomatite Vesicular tipo Indiana 1, segundo os municípios da região de Araçatuba. São Paulo, 2001.

Day/ Signal	Blepharospasm	Ocular discharge	Conjunctival congestion and hyperemia	Chemosis	Corneal transparency/ opacification	Neovascularization	Pigmentation	Corneal ulceration
1	0,7100	0,7149	0,2668	0,9509	0,1982	1,0000	1,0000	0,1971
3	0,4329	0,8926	0,3920	0,4323	0,7146	1,0000	1,0000	0,3217
10	0,2928	0,0193	0,3134	0,4828	0,0588	0,1846	1,0000	0,4144
30	1,0000	0,3679	0,8518	0,2946	0,6775	1,0000	0,0256	0,3558
60	1,0000	1,0000	0,3679	0,3679	0,3247	1,0000	0,3679	1,0000



**Figure 1**  
 Photographic image of a dog eye treated with autogenous blood serum. A. After 3 days of treatment, note intense chemosis and moderate conjunctival congestion (c), moderate corneal opacification (o), that becomes intense in the area of superficial corneal ulceration (u). B. After 10 days of treatment, note mild chemosis and moderate conjunctival congestion (c), moderate neovascularization (n), mild corneal opacification (o) and exposition of the Descemet membrane (d). C. After 30 days of treatment, note moderate conjunctival congestion (c), neovascularization (n), corneal conjunctivalization (cj) with congested vessels invading the cornea around the lesion and moderate opacification (o). D. After 60 days of treatment, note mild conjunctival congestion (arrow), moderate corneal opacification (o), corneal conjunctivalization (cj) and macula (m).



**Figure 2**  
 A. Photomicrograph of a dog cornea after 1 day of treatment with balanced saline solution, note uncovered (denuded) stroma in the area of lesion (arrow), area of stromal compaction (a) and non reactive epithelium (b). In the anterior chamber, note intense deposition of protein-like material (c) on the Descemet membrane due to absence of epithelium. (HE, 40X) B. Photomicrograph of a dog cornea after 10 days of treatment with autogenous blood serum, note stromal narrowing (arrows), epithelium deposited on the Descemet membrane (a) and protein-like material on its other face, discretely filling the anterior chamber (b). (HE, 40X) C. Photomicrograph of a dog cornea after 60 days of treatment with balanced saline solution. Note area of stromal compaction (a), thinned epithelium (arrow) and dissociation of stroma into bundles (b). (HE, 40X) D. Photomicrograph of a dog eye after 30 days of treatment with balanced saline solution. Note cystic space (arrow) in ora ciliaris retinae filled by a basophilic material. (HE, 100X)

60 days mainly discrete.

Protein (Figure 2a, 2b) and polymorphonuclear leukocyte exudates were observed in the anterior chamber and drainage angle of most dogs after 1 day. After 3 days, an anterior synechia was present in one animal. Edema and inflammatory cell infiltration occurred in the ciliary body of all animals after 1 and 3 days and was still present in one third of the dogs after 10 days, in most of them after 30 days, and in one dog after 60 days. Edema of the iris stroma was also observed after 1 day in one animal. Ciliary processes were congested and edematous in one dog after 3 days. Hemorrhage in the iris occurred in one animal after 3 days. After 30 days, mild uveal inflammation was present. After 60 days, retinal and ciliary congestion were present in about 30.00% of the dogs, while signs of intraocular inflammation were no longer present in the remaining animals. Cystic spaces filled with vitreous humor in *ora ciliaris retinae* occurred in one animal after 1 day and in one third of the dogs after 3, 10 and 30 days (Figure 2d).

## Discussion

The effects of acetylcysteine and autogenous blood serum on healing of alkali-induced corneal ulcers in dogs were investigated to determine the beneficial effects of the substances in terms of minimizing the action of lytic enzymes on the wounded cornea.<sup>9</sup> Collagenase inhibitors must be used when lytic enzymes are suspected to act at the site of lesions.<sup>7,10</sup>

The observation periods used in the present study for clinical and microscopic evaluation were planned in order to monitor the evolution of exudation, proliferation and maturation during the healing process.<sup>3</sup>

Animals that presented corneal perforation were replaced with others to permit uniform microscopy studies

for all animals at the same time points. However, perforation cases were considered and included in the statistical analysis, which showed no differences between groups or treatments in terms of the occurrence of perforations.

Dogs were employed in the study because they are frequently affected by corneal lesions and because they are routinely exposed to increasing risks of contact with alkali substances found in cleaning products and in building materials.<sup>4</sup> Alkali lesions were used because they are a critical model for the study of the anti-collagenase substances actions.<sup>8</sup> Lesions included limbic areas to permit the study of alterations occurring in the presence of partial depletion of stem cells, which act as a source of cells for corneal regeneration and differentiation.<sup>11</sup>

Ophthalmic events after alkali burns were systematically studied previously and corneal opacification and poor adhesion of epithelium to the adjacent stroma were described.<sup>12</sup> Similar signs were found in the present study, in which the epithelium could be easily removed when with a sterile swab after alkali contact. Ocular discharge was mucous or mucopurulent, mild to moderate and tended to disappear gradually. This sign was reported occurring in a moderate manner 24 hours after the injury, tending to disappear during the next periods, and was related to lesion of conjunctival goblet cells.<sup>12</sup>

The effects of autogenous blood serum and of an EDTA and cysteine solution on alkali-induced corneal ulcers have already been studied. The authors reported that neovascularization did not occur in the anticollagenolytic group, indicating that vasostimulant substances were inhibited by the anticollagenolytic agents.<sup>10</sup> In our study, however, the acetylcysteine-treated group presented

more intense neovascularization after 10 days compared to the others, with no difference between groups after 30 and 60 days. Neovascularization was clinically observed after 3 days of lesion induction, originating from the limbus, reaching the cornea and then the ulceration area. Others reported a correlation between neovascularization, fibroplasty and polymorphonuclear migration.<sup>13</sup> Corneal vascularization occurred at a similar rate as reepithelialization. Animals who presented corneal perforation exhibited few corneal vessels. It has been stated that cell migration is dependent upon the intensity of vascularization and that the prognosis of such lesions is directly dependent on vascular formation.<sup>14</sup> Vessels have been reported after one week and localized mainly in the anterior third of the stroma.<sup>12</sup> In our study, vascularization occurred at the same site after 3 days. Ulcer evolution was similar to that reported in the literature also in terms of perforations, which were more common around the tenth day. The critical period for alkali-induced corneal ulcers has been reported as 7 to 13 days.<sup>12</sup>

Many studies have been conducted on alkali-induced perforations.<sup>14</sup> Corneal and scleral cell death were observed immediately after alkali contact and corneal perforation in 90% of the cases, two to three weeks after the accident.<sup>7</sup> In our study, corneal perforations were independent of group or treatment. Anticollagenase substances were pointed as able to avoid the occurrence of perforations.<sup>10</sup>

Inflammatory cells infiltration was discrete at all observation times. It was present in all animals one day after ulceration, in one third after 10 days and in half after 30 days, and was no longer observed after 60 days. These findings are different from those obtained by other authors, who reported inflammatory cell kinetics 12 to 24

hours after the injury, followed by a second neutrophil infiltration of great intensity after 10 days, with maximal manifestation on the 21<sup>st</sup> day and regression on the 28<sup>th</sup> day.<sup>3</sup> Mononuclear and polymorphonuclear cells infiltrated mainly the epithelium and anterior stromal third, presenting a homogeneous distribution. Others reported inflammatory cell infiltration as a consequence of direct vascular lesion and neuronal conjunctival vascular dilatation, leading to protein and polymorphonuclear cell passage to the tear film and deposition on denuded surfaces, mainly in the junction between wounded and healthy epithelium.<sup>3</sup>

Limbus and cornea were reepithelialized by the adjacent conjunctival epithelium. Similar findings were previously reported, and was stated that, due to limbic stem cell deficiency, conjunctivalization and neovascularization may initiate, with retarded healing and occasional recurrent corneal erosions.<sup>11</sup> It has been emphasized that, due to anatomical and biochemical differences between corneal and conjunctival epithelium, six weeks may be needed for a complete incorporation of the conjunctiva into the corneal surface.<sup>7</sup> Chronic ocular irritation after alkali injuries has been reported.<sup>14</sup> In our study, conjunctival congestion/hyperemia occurred during the 60 day period of observation. Other authors reported that congestion was frequently present in cases of corneal conjunctivalization.<sup>3</sup> After 30 days of ulceration, one G1 dog presented small corneal epithelial vesicles, as previously reported by others in cases of stromal degeneration.<sup>15</sup> Some animals presented flat cells, as described before,<sup>12</sup> and others exhibited an epithelium of many layers and swelling of the basal layer.<sup>10</sup>

Pigmentation occurred in a small number of animals 30 days after

alkali contact. Corneal opacification occurred in all animals after the first 24 hours of ulceration, intensifying after 3 days, becoming less intense on the 10th day and being still present in some animals on the 60th day. These findings are different from those previously described by Christmas.<sup>4</sup> In our study, the opacification was considered intense when it prevented visualization of the iris. Similarly, corneal opacification was reported as enough to reduce vision.<sup>14</sup> Alkali-induced lesions cause glycosaminoglycan and keratocyte lesions with derangement of collagen lamellae and a tendency to reorganize from the periphery, as the lesion dry components organize.<sup>1</sup> In the present study, a classical pattern of alkali lesion was evident, in which corneal opacification was mainly due to stromal compaction observed by light microscopy. Light microscopy also revealed exudates inside the anterior chamber, which were not detected during clinical examination due to corneal opacification. Anterior chamber exudation two hours after alkali injury was reported, which was initially serous and became purulent after 16 hours.<sup>12</sup>

Hughes<sup>12</sup> reported endothelial destruction two hours after contact with alkali and corneal healing beginning from the periphery of the lesion after 7 days and being complete at the end of the second week. The present findings agree with those ones, since the

endothelium, when present, was visible only in a small area between one and three days and was completely reconstituted after 10 days. Light microscopy revealed lesions in the iris, ciliary body and processes, *ora ciliaris retinae* and retinal epithelium and vessels in many cases, as previously reported by others.<sup>3,4,12,16</sup> Intraocular pressure alterations, reported to occur after alkali injuries,<sup>16</sup> were not investigated due to the deleterious effects of local anesthetics impairing the healing process.<sup>15</sup>

The inefficiency of acetylcysteine in the treatment of corneal ulcers was reported.<sup>12</sup> In our study there were no differences between the corneas that received acetylcysteine and those that received other treatments. The inefficiency of blood serum in the treatment of alkali-induced corneal ulcers had been reported in rabbits. Treated animals presented perforation at the same rate as the controls.<sup>14</sup> In our study, as discussed before, perforations occurred in all groups, without expressive differences.

## Conclusions

Based on the results of this study, autogenous blood serum and 10% acetylcysteine did not alter the healing process kinetics of dog corneas that suffered the caustic effects of 3 M sodium hydroxide compared to corneas that received 0.90% balanced saline solution.

## Resumo

Estudaram-se lesões oftálmicas promovidas pelo contato com Hidróxido de sódio (NaOH) a 3M em 42 cães, divididos em três grupos, tratados com soro sanguíneo autógeno, da acetilcisteína e solução salina balanceada (G1, G2 e G3, respectivamente). Não foram encontradas diferenças mediante a comparação entre os grupos, considerando-se parâmetros clínicos e microscópicos.

**Palavras-chave**  
Olho.  
Cães.  
Olho (lesões).



## References

1. DONZIS, P. B.; MONDINO, P. J. Management of noninfectious corneal ulcers. **Survey of Ophthalmology**, v. 32, n. 2, p. 94-110, 1987.
2. BROWN, S. I.; BLOOMFIELD, S. E.; TAM, W. I. The cornea destroying enzyme of *Pseudomonas aeruginosa*. **Investigative Ophthalmology**, v. 13, n. 3, p. 174-180, 1974.
3. WAGONER, M. D. Chemical injuries of the eye: current concepts in pathophysiology and therapy. **Survey of Ophthalmology**, v. 4, n. 4, p. 275-313, 1997.
4. CHRISTMAS, R. Management of chemical burns of the canine cornea. **Canadian Veterinary Journal**, v. 32, n. 10, p. 608-612, 1991.
5. MORGAN, S. J. Chemical burns of the eye: causes and management. **British Journal Of Ophthalmology**, v. 71, n. 6, p. 854-857, 1987.
6. BERMAN, M. B.; DOHLMAN, C. H. Collagenase inhibitors. **Archives of Ophthalmology**, v. 35, n. 1, p. 95-108, 1975.
7. BROWN, S. I.; WELLER, C. A. Collagenase inhibitors in prevention of ulcers of alkali-burned cornea. **Archives of Ophthalmology**, v. 83, n. 3, p. 352-353, 1970.
8. TWINING, S. S. et al. Corneal synthesis of a1-proteinase inhibitor (a1-antitrypsin). **Investigative Ophthalmology and Visual Science**, v. 35, n. 1, p. 458-462, 1994.
9. BORTH, W. ????2-macroglobulin, a multifunctional binding protein with target characteristics. **FASEB Journal**, v. 6, n. 7, p. 3345-3353, 1992.
10. BROWN, S. I.; AKIYA, S.; WELLER, C. A. Prevention of the ulcers of the alkali-burned cornea. Preliminary studies with collagenase inhibitors. **Archives of Ophthalmology**, v. 82, n. 7, p. 95-97, 1969a.
11. CHEN, J. J. Y.; TSENG, S. C. G. Corneal epithelial wound healing in partial limbal deficiency. **Investigative Ophthalmology and Visual Science**, v. 31, n. 7, p. 1301-1314, 1990.
12. HUGHES, W. F. Alkali burns of the eye. **Archives of Ophthalmology**, v. 35, n. 4, p. 423-449, 1986.
13. BROWN, S. I.; WELLER, C. A.; AKIYA, S. Pathogenesis of ulcers of the alkali burned cornea. **Archives of Ophthalmology**, v. 83, n. 4, p. 205-208, 1970.
14. BROWN, S. I.; WASSERMAN, H. E.; DUNN, M. W. Alkali burns of the eye. **Archives of Ophthalmology**, v. 82, n. 7, p. 91-94, 1969b.
15. BISLA, K.; TANELIAN, D. L. Concentration-dependent effects of lidocaine on corneal epithelial wound healing. **Investigative Ophthalmology and Visual Science**, v. 33, n. 11, p. 3029-3033, 1992.
16. STEIN, M. R.; NAIDOFF, M. A.; DAWSON, M. D. Intraocular pressure response to experimental alkali burns. **American Journal of Ophthalmology**, v. 75, n. 1, p. 99-109, 1973.