

# Histopathologic and mycologic aspects of experimental infection of guinea pigs with *Microsporum canis*

## Aspectos histopatológicos e micológicos da infecção experimental de cobaias com *Microsporum canis*

Josemara Neves CAVALCANTI<sup>1</sup>; José Luiz GUERRA<sup>2</sup>; Walderez GAMBALÉ<sup>3</sup>; Benedito CORRÊA<sup>3</sup>; Claudete Rodrigues PAULA<sup>3</sup>

CORRESPONDENCE TO:  
JOSEMARA NEVES CAVALCANTI  
Faculdade de Medicina Veterinária  
Centro Regional da Universidade de Espírito Santo do Pinhal  
Av. Helió Vergueiro Leite, 01 - Caixa Postal 5  
13990-000 - Espírito Santo do Pinhal - SP  
e-mail: jocavalcanti@uol.com.br

1- Faculdade de Medicina Veterinária do Centro Regional da Universidade de Espírito Santo do Pinhal, Espírito Santo do Pinhal - SP

2- Departamento de Patologia da Faculdade de Medicina Veterinária e Zootecnia da USP, São Paulo - SP

3- Departamento de Microbiologia do Instituto de Ciências Biológicas da USP, São Paulo - SP

### SUMMARY

Dermatophytosis is a zoonosis in whose etiology the dermatophyte *Microsporum canis* is frequently involved. The fungus can be transmitted to man by dogs and cats. In the present study, guinea pigs were experimentally inoculated with *M. canis* and the course of the lesions was evaluated. Inoculation resulted in lesions in 100% of the animals, with a clinical course consisting of an incubation period, an inflammatory and a phase of lesion resolution. The histopathologic evaluation of the skin biopsies revealed the presence of acanthosis, hyperkeratosis, spongiosis and marked dermal edema. *M. canis* spores and hyphae were detected in histologic sections stained with periodic acid-Schiff. The combination of the fluorescent dyes FD and EB permitted the adequate visualization of viable and dead fungal cells in skin fragments of guinea pigs inoculated with *M. canis* and the identification of the morphologic characteristics of the cells. This experimental model represents a valuable instrument for the study of the pathogenesis of dermatophytic infection with respect to the evaluation of the efficacy of antifungal drugs, and may also be used for the study of the immunology of dermatophytoses and of dermatophyte morphogenesis.

**KEY-WORDS:** Dermatophytosis. *Microsporum canis*. Ringworm. Guinea pigs.

### INTRODUCTION

Dermatophytosis, also called tinea, ringworm, or superficial fungal infection, is one of the most common diseases of the skin and is caused by dermatophytes of the genera *Microsporum*, *Trichophyton* and *Epidermophyton*, which show great affinity for the skin and its annexes<sup>5,16</sup>. In Brazil, the most frequently diagnosed agents in the clinical dermatology of dogs and cats are in decreasing order of occurrence *Microsporum canis*, *M. gypseum*, *Trichophyton mentagrophytes* and *T. verrucosum*<sup>12, 14, 27, 39</sup>.

Dermatophytosis, especially feline dermatophytosis, is an important public health problem, since *M. canis* is a dermatophyte that frequently infects humans, with transmission of the infestation to humans being observed in 30% of feline dermatophytosis cases<sup>13,31</sup>.

According to Quaife and Womar<sup>37</sup> and Gambale *et al.*<sup>15</sup>, dogs and cats without clinical manifestations of the disease can carry dermatophytes in their coat. Mantovani<sup>29</sup> showed that, in addition to dogs and cats, numerous other animals, including wild animals, can harbor dermatophytes

and transmit the disease to man and other animals. Dermatophytes can be transmitted by direct contact with the infected host through fomites containing infected material, or by exposure to environments contaminated with spores from coats or from cells shed from the skin<sup>30</sup>.

Young animals and older animals with immunological deficiency or debilitating disease are among those most susceptible to dermatophytosis. Corticoid treatment, stress and nutritional deficiencies are also factors that may predispose to the disease<sup>16,38</sup>. No sex or race preference has been observed, although some individuals of a family or race have been found to be more susceptible to the disease<sup>22</sup>.

The classical dermatophytic lesions are characterized by polycyclic, nummular rings. Alopecia and crusts can be observed. The hairs remaining in the central area or borders of the lesion are fine and brittle. Secondary papular folliculitis and dry seborrhea may also be present. Normally, pruritus does not occur, but moderate or intense pruritic lesions have been observed in some cases<sup>6,16</sup>.

The diagnosis of dermatophytosis is based on clinical history, detection of lesions, and various diagnostic tests including Wood's light interposition, direct microscopic

examination of the hairs and/or crusts, mycologic cultivation of perilesional material, and biopsy<sup>16,30</sup>. Despite the large number of diagnostic methods available, none of them is completely efficient<sup>38</sup>.

Microscopically, the dermatophytic lesions show variable patterns, ranging from a noninflammatory to discrete reaction in association with spores or hyphae in the stratum corneum or in the hair follicles, to an intense inflammatory reaction without evidence of fungal elements. Fungal particles can be visualized in histologic sections by special staining methods such as silver methenamine or periodic acid-Schiff (PAS)<sup>22</sup>.

Gross *et al.*<sup>16</sup> observed dermatophytosis with variable degrees of acanthosis of the epidermis and follicular infundibulum, hyperkeratosis and, in some cases, superficial crusts. Folliculitis may be observed in dogs but does not occur in cats. The hair follicles and blood vessels of the superficial dermis are found to be infiltrated by lymphocytes and macrophages and, sometimes, by few neutrophils. The hairs can be infiltrated by dermatophytic spores and hyphae.

The combined use of fluorescein diacetate and ethidium bromide (FD-EB) has been widely employed in studies on microorganism viability<sup>8, 10, 20, 28, 35, 36</sup> using clinical material obtained from natural human and animal lesions and from experimental inoculations, that was preceded by the standardization of the fluorescent FD-EB technique for the study of fungal cell viability.

## MATERIAL AND METHOD

### *Microsporum canis* strain

An *M. canis* strain (ICB-35) obtained from the Mycology Section of the Department of Microbiology, Institute of Biological Sciences, University of São Paulo, which was isolated from the hairs and epidermal flakes of a dog, was used in the present study.

### Skin biopsies

Fifty-two skin biopsies were collected from guinea pigs experimentally inoculated with *M. canis* with a punch measuring 4 mm in diameter.

### Animals

Twenty-four guinea pigs of both sexes, weighing approximately 600 g were obtained from the animal house of the Faculty of Medicine, University of São Paulo. Two depilated animals, whose skin was submitted to gentle scarification with a sterile scalpel blade but which were not inoculated, were used as control.

### Inoculation

Animals were inoculated according to the modified method of Tagami *et al.*<sup>37</sup>. The hair in the posterior dorsal

region of the animals was removed and a skin area in this region of approximately 4 cm was submitted to gentle scarification with a sterile scalpel blade. A suspension (0.4 ml) containing 10<sup>6</sup> *M. canis* spores/ml was inoculated at the site, which was covered with a 4 x 4 cm polyethylene film and kept in place with a 4-cm high elastic bandage for 24 h.

### Preparation and quantification the inoculum

The suspensions used for the inoculation were prepared from *M. canis* colonies initially cultivated on Mycosel (DIFCO) and then on potato agar for approximately 2 to 3 weeks at 25°C. The colonies were gently scraped from the surface of the culture medium, placed in test tubes containing 20 ml sterile saline, and triturated and homogenized in a mollusks triturator for about 1 min. Fungal cells were counted using each of the four "A" compartments of a Neubauer chamber. The inoculum was adjusted to 10<sup>6</sup> *M. canis* spores/ml as recommended by Bonk *et al.*<sup>2</sup> and Reinhardt *et al.*<sup>33</sup>.

### Fungal cell viability

Aliquots of 0.1 ml were removed from the *M. canis* suspensions and equal aliquots (v/v) of FD (5 µg/ml) and EB (50 µg/ml) in phosphate buffered saline (PBS) prepared shortly before use were added<sup>10,35</sup>. One drop of this mixture was examined with a fluorescence microscope, and a fungal cell count revealed 85% of viable cells.

### Clinical evaluation of the lesions

The lesions were clinically followed-up daily until resolution was observed, considering the following aspects: a) incubation period, b) erythema, c) shedding, d) crusts, e) hair rarefaction, f) alopecia, g) dissemination of the lesions to other sites of the animal's body, and h) cure of the lesions.

### Mycologic and histopathologic evaluation

*Mycologic evaluation.* Epidermal flakes were scraped from the animal and hairs were collected by manual avulsion at intervals of 24 and 72 h, and 5, 6, 7, 8, 9, 11, 13, 15, 17, 20, 25 and 32 days after inoculation. After complete resolution of the lesions, material was collected from the animals using the "carpet technique" as described by Lacaz<sup>26</sup>. The epidermal flakes and hairs were seeded in tubes containing Mycosel (DIFCO) agar and maintained in an incubator at 25°C, and fungal development was periodically analyzed, with the fungi identified as described by Rebell and Taplin<sup>34</sup>.

*Histopathologic evaluation.* Two skin biopsies were obtained from the inoculation site with a punch measuring 4 mm in diameter at the above time intervals. One biopsy was duly processed and examined for the identification of fungal cells using the FD-EB method. The other biopsy was fixed in 10% formalin, embedded in paraffin, cut into 5-µm thick sections, and stained with hematoxylin-eosin and PAS.

### Processing of the skin biopsies and determination of viability using FD-EB

*M. canis*-containing suspensions were obtained after biopsy processing and 0.1 ml aliquots were added to equal aliquots (v/v) of FD (5 µg/ml) and EB (50 µg/ml) in phosphate buffered saline (PBS) prepared shortly before use (Restrepo et al.<sup>35</sup>; Corrêa,<sup>10</sup>). One drop of the mixture containing skin fragments and the reagents was placed between a slide and coverslip and the material was examined with a fluorescence microscope.

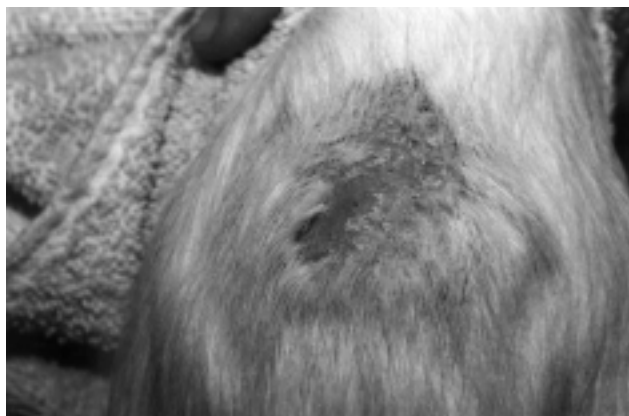### RESULTS

Experimental infection of guinea pigs with *M. canis* resulted in lesions in 100% of the animals. The first signs of

infection were observed on the 5th day after inoculation in 21 (87.5%) animals, and manifested in the form of edema, erythema and mild shedding. These alterations became more evident around the 10th day. The lesions progressively increased in diameter and were found to be covered with white-yellow crusts strongly adhered to the epidermis between the 8th and 15th day.

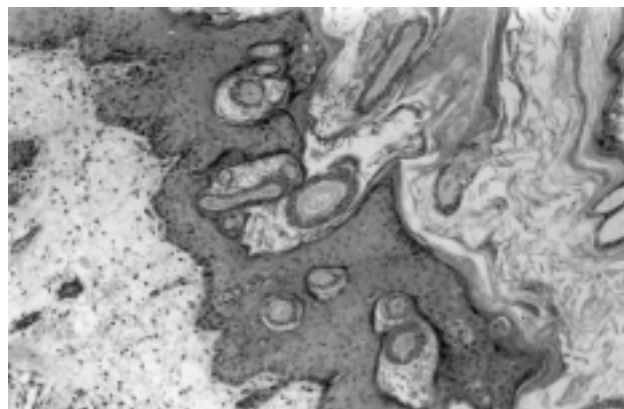
Between the 20th and 25th day, the inoculation site showed areas of alopecia, shedding and crusts. The skin was found to be intensely swollen and erythematous (Fig. 1). Hair growth was observed in 22 (92%) animals from the 30th day on, and the lesions were completely resolved on the 40th day in 20 (83%) animals.

*M. canis* could be reisolated from hairs and epidermal flakes of 15 (62%) inoculated animals from the 5th



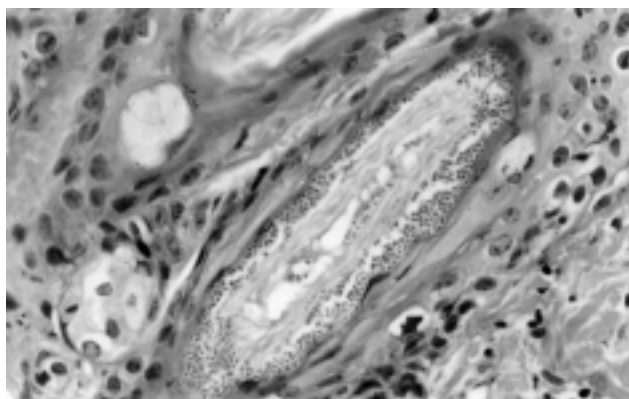
**Figure 1**

Photograph of an experimental lesion proceed by *M. canis* in a guinea pig, after 25 days of evolution. Alopecia and desquamation can be seen.



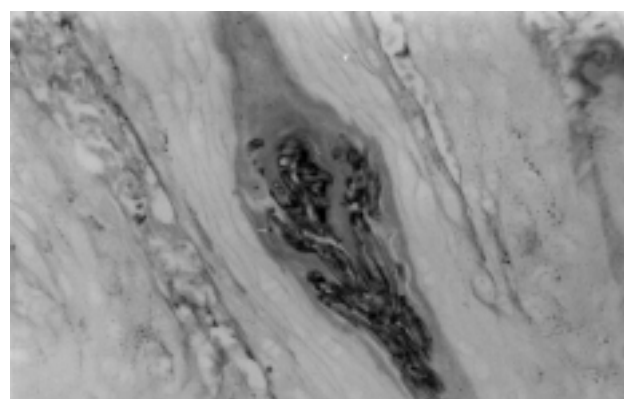
**Figure 2**

Photomicrograph of a histological section of the skin of a guinea pig inoculated with *M. canis*, after 15 days of evolution. Marked hyperkeratosis and acanthosis are observed; the dermis shows an inflammatory infiltrate predominantly composed of mononuclear cells, and the hair follicles are filled with spores and hyphae. Staining: hematoxylin-eosin. Magnification: 200x



**Figure 3**

Photomicrograph of a histological section of the skin of a guinea pig inoculated with *M. canis*, after 8 days of evolution. Spored hyphae are observed inside the hair follicle. Staining: hematoxylin-eosin. Magnification: 400x



**Figure 4**

Histological section of the skin of a guinea pig inoculated with *M. canis*, after 8 days of evolution. A hair follicle containing spore and hyphae can be seen. Staining: Period Acid Schiff. Magnification: 400x

day on. Mycologic cultures were positive in 10 (38%) animals on the 30th day after inoculation. After 50 days of inoculation, *M. canis* could not be isolated from the material collected at the inoculation site of 18 (75%) animals.

Using the carpet technique, *M. canis* was isolated from 6 (25%) animals that did not show clinical lesions 40 days after inoculation. However, *M. canis* could be isolated from the previously monitored animals and from two additional animals on the 100th day, with an increase in the percentage of positive animals without clinical lesions to 33.3%.

Histologic sections stained with hematoxylin-eosin showed a discrete neutrophilic infiltrate and dermal edema 24 h after *M. canis* inoculation into the skin of guinea pigs; at 72 h of inoculation these alterations were found to be more pronounced. Five days after inoculation, skin fragments showed acanthosis, hyperkeratosis, spongiosis and marked dermal edema. These findings became progressively more pronounced, with highly marked alterations being observed 15 days after inoculation (Fig. 2), and being less prominent on the 17th day. The histopathologic alterations were found to be discrete 32 days after *M. canis* inoculation. Even in sections stained with hematoxylin-eosin fungal spores and hyphae were observed in the stratum corneum and inside the hair follicles (Fig. 2 e 3).

*M. canis* spores and hyphae were detected in the stratum corneum 24 h after inoculation in histologic sections stained with PAS. Fungal particles were also observed inside the hair follicles from the 5th to the 20th day after inoculation (Fig. 4), but were no longer detected in the histologic sections after this time interval.

The viability test using the fluorescent dyes FD-EB demonstrated the presence of viable cells with uniformly distributed, greenish fluorescence in skin fragments from guinea pigs previously inoculated with *M. canis*. Dead fungal cells showed reddish and brilliant fluorescence. The FD-EB technique especially permitted the observation of microconidia which were mostly round in shape and of variable diameter. Ovoid microconidia were eventually observed. Hyphae could be rarely visualized and, if present, only some were viable. Both viable and dead hyphal fragments were observed up to the 15th day. After this time interval, hyphae could be rarely observed, most of them being dead.

A predominance of viable cells was observed on the 15th day after inoculation. On the other hand, dead cells were predominant 24 h after inoculation and tended to increase from the 20th day on.

## DISCUSSION

In the present study, infection was induced with a

suspension containing *M. canis* mycelia isolated from the lesions of a dog with dermatophytosis and cultivated in the laboratory, with special attention being paid to abrasion and occlusion of the inoculation site, in an attempt to reproduce important natural conditions of dermatophytic infections. However, Bonk<sup>2</sup> did not consider these measures to influence the infectivity of these agents.

The clinical course of *M. canis* infection in guinea pigs was found to consist of an incubation period (0-5 days after inoculation), a phase of establishment of the lesions or inflammatory phase (5-20 days after inoculation) and a resolution phase (20-30 days of evolution), similar to the clinical course of experimental infections in guinea pigs induced by other dermatophytes<sup>2, 5, 7, 17, 21, 24</sup>.

Spontaneous cure of the lesions occurred about 40 days after inoculation. This short duration of infection is an aspect that limits the use of experimental *M. canis* dermatophytosis in guinea pigs, especially in studies evaluating the efficacy of therapeutic agents.

Positive fungal cultures were obtained from the material collected at the inoculation site of 6 animals 100 days after the lesions had been cured. Other authors<sup>11, 23</sup> described a similar finding and suggested that the fact that animals continue to be culture positive even after cure of the lesions may be related to recontamination with fomites present in the environment. In the present study, recontamination with fomites present in the environment may have occurred since *M. canis* was isolated from only 5 animals on the 50th day, while on the 100th day the fungus was isolated from 2 additional animals upon collection of material for mycologic examination, leading to a total of 7 culture-positive animals.

The literature does not report any studies describing the histopathologic alterations of the skin of guinea pigs experimentally inoculated with *M. canis*; however, the microscopic alterations found here were similar to those observed for natural lesions caused by *M. canis* in dogs, cats and guinea pigs<sup>3,4,12,22,24</sup>.

In the present study, invasion of the hair follicles by hyphae and spores was established 5 days after inoculation, while Hay *et al.*<sup>18,19</sup> observed parasitized hair follicles in experimental lesions of rats produced by *T. quinckeanum* 24 and 72 h after inoculation.

The viable fungal cells stained with FD showed uniformly distributed, greenish fluorescence, while dead fungal cells presented reddish and brilliant, uniformly distributed fluorescence, as also observed by Rojas Pedra<sup>36</sup>; Corrêa *et al.*<sup>8</sup>; Corrêa *et al.*<sup>9</sup> and Corrêa *et al.*<sup>10</sup>.

Hyphae could be rarely visualized in the preparations stained with FD-EB, a fact possibly related to deficient trypsinization of the skin biopsies, preventing the release of the hyphae from the tissues.

## CONCLUSIONS

The present results obtained by experimental inoculation of *M. canis* led us to conclude that:

The model of experimental induction of *M. canis* dermatophytosis in guinea pigs was relatively simple to perform and resulted in lesions in all animals studied.

The experimental *M. canis* infection in guinea pigs proposed here does not reproduce with absolute accuracy natural dermatophytic lesions; however, in terms of the clinical aspects, the lesions observed here were similar to natural lesions.

The present model represents a valuable instrument for the study of the pathogenesis of dermatophytic infection with respect to the evaluation of the efficacy of prophylactic or antifungal therapeutic drugs and for the study of the immunology of dermatophytoses.

The use of the fluorescent dyes FD-EB for the evaluation of *M. canis* viability in skin fragments permitted a

safe differentiation between dead and live cells, in addition to preserving the characteristic morphology of the fungi.

The fluorescent FD-EB technique represents an alternative mycologic diagnostic method, with the advantage of sensitivity and rapid execution compared to classical methods.

The use of the fluorescent method permitted the perfect visualization of the morphologic characteristics of *M. canis* in skin fragments, thus representing a method which may be used to study the morphogenesis of this or other fungi in biological material.

Due to the identification of dead and live microorganisms in tissues, the fluorescent method permits the study of the effects of drugs on fungal cells.

The viability test employing the fluorescent dyes FD-EB can be applied to the evaluation of the viability of microorganisms to be used in the induction of experimental lesions.

## RESUMO

Com frequência o dermatófito *Microsporium canis* está envolvido na etiologia da dermatofitose, podendo ser transmitido para o homem por cães e gatos. Neste estudo foi procedida inoculação experimental de *M. canis* em cobaias resultando em lesões em 100 % dos animais e o curso clínico consistiu de período de incubação, fase inflamatória e fase de resolução das lesões. O exame histopatológico de biópsias cutâneas revelou presença de infiltrado neutrofílico e edema; acantose, hiperqueratose e espongiose. Estas lesões tornaram-se menos acentuadas no 30.<sup>o</sup> dia pós-inoculação. Esporos e hifas de *M. canis* foram detectadas em cortes histológicos corados com PAS (Ácido Periódico de Schiff). A combinação dos corantes fluorescentes diacetato de fluoresceína (DF) e brometo de etídio (BE), possibilitou uma adequada visualização das células fúngicas viáveis e não viáveis com evidenciação de seus caracteres morfológicos. Este modelo experimental representa um valioso instrumento para o estudo da patogênese da infecção por dermatófitos, para a avaliação da eficácia de drogas antifúngicas, podendo também ser utilizado em estudos sobre a imunologia das dermatofitoses e na determinação da morfogênese de dermatófitos.

**PALAVRAS-CHAVE:** Dermatofitose. *Microsporium canis*. Inoculação. Cobaias.

## REFERÊNCIAS

1. BAXTER, M. Ringworm due to *Microsporium canis* in cats and dogs in New Zealand. **Veterinary Journal**, v. 21., n.3, p.33-37, 1973.
2. BONK, A. F.; FRIEDMAN, L.; DERBEN, V.J. Experimental dermatophytosis. **Journal Investigative Dermatology**, v. 39, n.4, p.281-286, 1962.
3. BUERGELT, C.D. Guinea pig dermatophytosis. **Veterinary Medicine**, v. 95, n.10, p. 755, 2000.
4. CABAÑES, F. J.; ABARCA, L.; BRAGULAT, M.R.; CALVO, M.A. Experimental dermatophytosis produced by *Epidermophyton Floccosum* in guinea pigs. **Mycopathologia**, v.98, n.1, p.45-47, 1987.
5. CABANES, F.J.; ABARCA, M.L.; BRAGULAT, M.R. Dermatophytes isolated from domestic animals in Barcelona, Spain. **Mycopathologia**, v. 137, n. 2, p. 107-113, 1997.
6. CARLOTTI, D.N.; BESINGNOR, E. Dermatophytosis due to *Mycrosporium persicolor* (13 cases) or *Microsporium gypseum* (20 cases) in dogs. **Veterinary Dermatology**, v. 10, n. 1, p. 17-27, 1999.
7. CHITTASOBHON, N.; SMITH, M. B. The production of experimental dermatophyte lesions in guinea pigs. **Journal of Investigative Dermatology**, V.73, n.2, p.198-201, 1979.
8. CORRÊA, B.; PURCHIO, A.; PAULA, C.R.; GAMBALE, W. Evaluation of a fluorescent method (fluorescein diacetate and ethidium bromide solution) in the study of the viability *Cryptococcus neoformans* strains. **Mycopathologia**, v. 96, n. 3, p. 91-96, 1986.
9. CORRÊA, B.; PURCHIO, A.; PAULA, C.R.; GAMBALE, W. Evaluation of a fluorescent method in the study of the viability of *Candida albicans* strains. **Revista de Microbiologia**, v. 18, n.3, p. 258-263, 1987.
10. CORRÊA, B. **Aplicação do método de fluorescência (solução de diacetato de fluoresceína e brometo de etídio) para a análise de viabilidade de células fúngicas em materiais clínicos**. São Paulo, 1988. 81p. Tese (Doutorado) - Instituto de Ciências Biomédicas, Universidade de São Paulo, São Paulo, 1988.
11. DEBOER, D.J.; MORIELLO, K.A. Inability of two topical treatments to influence the course of experimentally induced dermatophytosis in cats. **Journal of the American Veterinary Medical Association**, v.207, n.1, p.52-57, 1995.

12. DUBUGRAS, M.T.B.; LARSSON, C.E.; LEDON, A.L.B.P.; GAMBALE, W. Dermatofitoses e leveduras de cães e gatos. Aspectos diagnósticos. **Brazilian Journal Veterinary Research Animal Science**, v.29, n.2, p.273-287, 1992.
13. FERNANDES, N.C.; MONTEIRO, P.C.F.; PEREZ, M.A. Dermatophytosis in children: risk factors study. **Journal de Mycologie Medicale**, v. 5, n. 3, p.188-189, 1995.
14. GAMBALE, W.; CORRÊA, B.; PAULA, C.R.; PURCHIO, A.; LARSSON, C. E. **Ocorrência de fungos em lesões superficiais de cães na cidade de São Paulo, Brasil**. Revista da Faculdade de Medicina Veterinária e Zootecnia da Universidade de São Paulo, v.24, n.2, p.187-192, 1987.
15. GAMBALE, W.; LARSSON, C.E.; MORITAMI, M.M.; CORRÊA, B.; PAULA, C.R.; FRAMIL, V.M.S. Dermatophytes and other fungi of the haircoat of cats whitout dermatophytosis in the city of São Paulo, Brasil. **Feline Practice**, v.21, n.3, p.29-33, 1993.
16. GROSS, T.L.; IHRKE, P.J.; WALDER, E.J. **Veterinary Dermatopathology**: a macroscopic and microscopic evaluation of canine and feline skin disease. St. Louis: Mosby - Year Book, 1992, p. 241-246.
17. GREENBERG, J.H.; KING, R.D.; KERBS, S.; FIELD, R. A quantitative dermatophyte infection model in the guinea pig - a parallel to the quantitated human infection model. **Journal of Investigative Dermatology**, v.67, n.6, p.704-708, 1976.
18. HAY, R.J.; CALDERON, R.A.; COLLINS, M.J. Experimental dermatophytosis: the clinical and histopathologic features of a mouse model using *Trichophyton quinckeanum* ( mouse favus). **Journal of Investigative Dermatology**, v.81, n.3, p. 270-274, 1983.
19. HAY, R.J.; CALDERON, R.A.; MACKENZIE, R. Experimental dermatophytosis in mice: correlation between light and electron microscopic changes in primary, secondary and chronic infections. **British Journal of Experimental Pathology**, v. 69, n.5, p.703-716, 1988.
20. JARNAGIN, J.L.; LUCHSINGER, D.W. The use of fluorescein diacetate and ethidium bromide as a stain for evaluating viability of mycobacteria. **Stain Technology**, v.55, n.4, p.253-258, 1980.
21. JONES, H.E.; REINHARDT, J.H.; RINALD, M.G. Acquired immunity to dermatophytes. **Archives Dermatology**, v.109, n.6, p. 840-8, 1974.
22. JUNGERMAN, P.F.; SCHWARTZMAN, R.M. In: Microsporosis and trichophytosis. **Veterinary medical micology**. Philadelphia: Lea & Febiger, 1972. p.3-28.
23. KERBS, S.; ALLEN, A.M. Effect of occlusion on *Trichophyton mentagrophytes* infections in guinea pigs. **Journal of Investigative Dermatology**, v.71, n.5, p.301-304, 1978.
24. KOSTRO, K. Hypersensitivity to trichophytin in small animals experimentally infected with *Trichophyton equinum*. **Journal of Medical and Veterinary Micology**, v.27, n.6, p.353-3 61, 1989.
25. KVACH, J.T.; MUNGUIA, G.; STRAND, S.H. Staining tissue-derived *Mycobacterium leprae* with fluorescein diacetate and ethidium bromide. **Institute Journal Leprae**, v.52, n.2, p.176-182, 1982.
26. LACAZ, C.S.; PORTO, E.; MARTINS, J.E.C. **Micologia médica**: fungos, actinomicetos e algas de interesse médico. São Paulo: Sarvier, 1991. 695p.
27. LARSSON, C.E.; LUCAS, R.; GERMANO, P.M.L. Dermatofitoses de cães e gatos em São Paulo: estudo da possível influência sazonal. **Anais Brasileiros de Dermatologia**, v. 72, n. 2, p. 139-142, 1997.
28. MAFFEI, C.M.L. **Aplicação do método de fluorescência (por solução de diacetato de fluoresceína e brometo de etídio) para o estudo da viabilidade de *Paracoccidioides brasiliensis* "in vivo" e determinação dos padrões fluorescentes**. São Paulo, 1990. 129p. Dissertação (Mestrado) - Instituto de Ciências Biológicas, Universidade de São Paulo, São Paulo, 1990.
29. MANTOVANI, A. The hole of animals in the epidemiology of the mycoses. **Mycopathologia**, v.65, n. 1, p.61-66, 1978.
30. MORIELLO, K.A. Management of dermatophyte infection in catteries and multiple-cat households. **Advances in Clinical Dermatology**, v.20, n.6, p.1456-1474, 1990.
31. PINHEIRO, A.Q.; MOREIRA, J.L.B.; SIDRIM, J.J.C. Dermatophytosis in the urban environment and the coexistence of man with dogs and cats. **Revista da Sociedade Brasileira de Medicina Tropical**, v. 30, n. 4, p. 287-294, 1997.
32. QUAIFFE, R.A.; WOMAR, S.M. *Microporum canis* isolations from show cats. **Veterinary Record**, v.110, n. 14, p.333-4, 1992.
33. REINHARDT, J.H.; ALLEN, A.F.; GUNNISON, D.; AKERS, W.A. Experimental human *Trichophyton mentagrophytes* infections. **Journal Investigative Dermatology**, v.63, n.5, p.419-422, 1974.
34. REBELL, G.; TAPLIN, D. **Dermatophytes, their recognition and identification**. Miami: Coral Gables, 1970. 340p.
35. RESTREPO, A.; CANO, L. E.; BEDOUT, C.; BRUMMER, E.; STEVENS, A.D. Comparison of various techniques for determining of *Paracoccidioides brasiliensis* yeast-form cells. **Journal Clinical Microbiology**, v.16, n.1, p.209-211, 1982.
36. ROJAS PEDRAL, M.M.E. **Avaliação da eficiência do método de fluorescência (solução de diacetato de fluoresceína e brometo de etídio) no estudo da viabilidade de células leveduriformes de *Sporothrix schenckii***. São Paulo, 1983. 98p. Dissertação (Mestrado) - Instituto de Ciências Biomédicas, Universidade de São Paulo, São Paulo, 1983.
37. TAGAMI, H.; WATANABE, S.; OFUGI, S. Trichophytin contact sensitivity in guinea pigs with experimental dermatophytosis induced by a new inoculation method. **Journal of Investigative Dermatology**, v. 61, n. 4, p.237-241, 1973.
38. THOMAS, M.L.; SHEIDT, V.J.; WALKER, R.L. Inapparent carriage of *Microsporium canis* in cats. Compendium Continuing Education. **Small Animal Practice**, v.11, n.5, p.563-570, 1989.
39. TORRES, S.M.F.; MOREIRA, Y.K. Dermatomicose em cães de Belo Horizonte, Minas Gerais, Brasil. **Arquivo Brasileiro de Medicina Veterinária e Zootecnia**, v.36, n.6, p.695-701, 1984.

Recebido para publicação: 22/02/2002  
Aprovado para publicação: 21/05/2002