

TECHNICAL NOTE

A simple technique for knot tying in single incision laparoscopic surgery (SILS)

Baki Ekçi

Yeditepe University, Faculty of Medicine, Department of General Surgery, İcerenkoy, Istanbul, Turkey.

Email: drbaki@yahoo.com

Tel.: 0905333186578

INTRODUCTION

Minimal access surgery has been generally accepted as a method of operating through a very small incision or no incision at all. Today, all abdominal and thoracic surgeries can be performed with laparoscopy. Intracorporeal knot tying is an advanced skill that involves a difficult process with a long learning curve.^{1,2} In particular, when the angle between the working instruments is narrow and the working area is limited, ligation and suturing are substantially difficult to perform.

A new concept known as single incision laparoscopic surgery (SILS) was recently introduced. With this technique, the approach to the abdominal cavity is made through a single incision. However, with this method, intracorporeal suturing is more difficult than it is with traditional laparoscopy. There are several reasons for the technical complexity of this surgical approach. The surgeon's vision is restricted. It is difficult to handle the instruments. One lacks tactile perception, and there is a limited working area. Furthermore, the procedure necessitates excellent hand-eye coordination and manual dexterity.^{3,4} In routine practice involving laparoscopic equipment, port and optic entrances should be appropriately selected according to the type of the surgical procedure and feasible suturing. On the other hand, in SILS, such is not possible since the optic equipment and hand instruments are on the same plane. This configuration complicates the surgical procedure and frequently renders suturing impossible.

Taking this fact into account, a technique called the "side winding" method was developed in an attempt to simplify the intracorporeal suturing procedure during SILS. By means of this safe, simple, and fast technique, intracorporeal suturing is performed remotely with a limited field of vision and it does not require a significant amount of experience.

Technique

This method, which allows knots to be tied safely, is easily carried out under direct vision after the maintenance of the pneumoperitoneum. To conduct this technique, a surgeon requires a flexible grasping forceps (Roticulator™ Endo Grasp™ 5 mm, Covidien, USA) to hold up the tissue and the stitch, and a needle holder or other endoscopic

instrument. Flexible instruments are either curved or articulated to accommodate the restricted space and the limited range of motion.

In the first step, the Roticulator Endo Grasp is opened in the knotting area, and the suture is wound around twice (Fig. 1a-f). The suture is grasped with the Roticulator instrument at a point a few centimeters distal to the exit of the suture from the tissue (Fig. 2). The reef knot is converted into a slip knot by applying distracting forces on the suture material at the two opposite points (Fig. 3). After the first knot has been tightened, the instrument is removed, and the procedure is repeated until the desired number of knots has been made. Finally, after the knot has been tightened, the suture is cut.

DISCUSSION

Suturing and knot tying have an important place in laparoscopic surgery.^{5,6} According to Rosser et al.,⁷ intracorporeal suturing is perhaps the most difficult of the advanced laparoscopic skills. Despite the advances that have occurred in the fields of optics and imaging, laparoscopic suturing and knot tying entail patience and experience, and they are difficult, time consuming, and frustrating to perform.⁸ In certain instances, this hurdle is so great that laparoscopic procedures have to be abandoned. During laparoscopic knotting, the manual instruments are pulled away from each other, and this process may eventually cause tissue damage. In addition, the inadequate control of the instrument compromises a surgeon's ability to tighten the knot in SILS. Many new instruments and methods have been developed to overcome these difficulties in laparoscopic surgery.⁹

For effective endosuturing, triadic relationships of port sites are very important, with the optical port in the center and suturing ports on either side. However, the ideal port position is difficult to achieve in the operating room in all cases in SILS. If the angle between the hand instruments is narrow, laparoscopic suturing is difficult to perform. SILS is a new and promising technique, but suturing is more difficult in this procedure due to the port position and the angle of the hand instruments. It is particularly challenging to form a loop around the hand instrument when there is limited working space. Many methods have been described for intracorporeal suturing and tying in laparoscopic surgery before such a technique was developed in the early 1970s.^{1,2,10,11} Since then, there has been ongoing research and development in this field. The majority of these methods required special, often disposable, devices that were expensive (i.e., Endo Stitch).¹² The "side winding"




Figure 1a-f - The Reticulator Endo Grasp is opened on the knotting area and the suture is wrapped around twice.

technique makes laparoscopic suturing feasible, especially when the angle between the hand instruments is not ideal and the working space is limited. With this simple technique, the disadvantages of the single incision are overcome with the aid of flexible instruments. It is also helpful when the length of the suture is short. With this technique, laparoscopic suturing may be performed by

using routine instruments, thus providing cost-effectiveness, feasibility, and minimal instrument transfer. Moreover, with this technique, the instruments are pulled away from the tissue during knotting, so it is safer than the conventional approach. It reduces the possibility of inadvertently catching the organs in the suture.

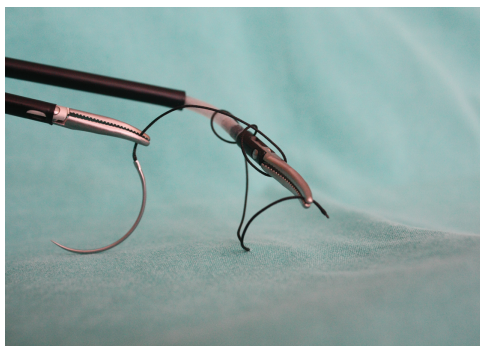

Figure 2 - The suture is grasped with the Reticulator instrument at a point that is a few centimeters distal to the exit of the suture from the tissue.



Figure 3 - The reef knot is converted into a slip knot by applying distracting forces on the suture material at the two opposite points.

In conclusion, the “side winding” intracorporeal knot tying technique may be used, even when the surgeon has only a limited view of the scope and instruments. Even an inexperienced laparoscopic surgeon will be able to execute this suture safely, much more simply, quickly, and cost effectively. Furthermore, it is assumed that this technique will allow a wide spectrum of innovative and high-quality operations to be performed and will improve patient safety.

REFERENCES

1. Kawano T, Nishikage T. Open-jaw technique in laparoscopic knot tying. *Surg Endosc.* 2008;22:269–70, doi: 10.1007/s00464-007-9637-6.
2. Croce E, Olmi S. Intracorporeal knot-tying and suturing techniques in laparoscopic surgery: technical details. *J Soc Laparoendosc Surg.* 2000;4:17-22.
3. Chow A, Purkayastha S, Aziz O, Paraskeva P. Single-incision laparoscopic surgery for cholecystectomy: an evolving technique. *Surg Endosc.* 2010;24:709-14, doi: 10.1007/s00464-009-0655-4.
4. Solomon D, Bell RL, Duffy AJ, Roberts KE. Single-port cholecystectomy: small scar, short learning curve. *Surg Endosc.* 2010 Apr 17. [Epub ahead of print].
5. Nathanson LK, Nathanson PDK, Cuschieri A. Safety of vessel ligation in laparoscopic surgery. *Endoscopy.* 1991;23:206-10, doi: 10.1055/s-2007-1010657.
6. Nathanson LK, Easter DW, Cuschieri A. Ligation of the structures of the cystic pedicle during laparoscopic cholecystectomy. *Am J Surg.* 1991;161:350-4, doi: 10.1016/0002-9610(91)90596-6.
7. Rosser JC Jr, Colsant BJ, Lynch PJ, Herman B, Klonsky J, Young SM. The use of a “hybrid” trainer in an established laparoscopic skills program. *JLS.* 2006;10:4-10.
8. Meilahn JE. The need for improving laparoscopic suturing and knot-tying. *J Laparoendosc Surg.* 1992;2:267.
9. Euan MS, Frew. A simple technique for tying intracorporeal knots in laparoscopic surgery. *J Can Chirur.* 2001;44:460–1.
10. Semm K. The endoscopic intra-abdominal suture. *Geburtshilfe Frauenheilkd.* 1982;42:56-7, doi: 10.1055/s-2008-1036623.
11. Clarke HC. Laparoscopy-new instruments for suturing and ligation. *Fertil Steril.* 1972;23:274-7.
12. Ealshry OM, Nakada SY, Wolf S Jr, Figenshaw RS, McDougall EM, Claymen RV. A comparative study of port-closure techniques following laparoscopic surgery. *J Am Coll Surg.* 1996;183:335-44.