

---

**CLINICAL SCIENCE**

---

**INTRAMYOCARDIAL INJECTION OF AUTOLOGOUS BONE MARROW CELLS AS AN ADJUNCTIVE THERAPY TO INCOMPLETE MYOCARDIAL REVASCULARIZATION - SAFETY ISSUES**

Luís Henrique W. Gowdak, Isolmar T. Schetttert, Eduardo Baptista, Nailú L. G. Lopes, Carlos Eduardo Rochitte, Marcelo Luiz C. Vieira, César José Grupi, Luiz Antonio M. César, José Eduardo Krieger, Sérgio A. de Oliveira

---

Gowdak LHW, Schetttert IT, Baptista E, Lopes NLG, Rochitte CE, Vieira MLC, et al. Intramyocardial injection of autologous bone marrow cells as an adjunctive therapy to incomplete myocardial revascularization - safety issues. Clinics. 2008;63:207-14.

**OBJECTIVES:** To determine the safety of intramyocardial injection of autologous bone marrow cells in patients undergoing surgical myocardial revascularization (CABG) for severe coronary artery disease.

**INTRODUCTION:** There is little data available regarding the safety profile of autologous bone marrow cells injected during surgical myocardial revascularization. Potential risks include arrhythmias, fibrosis in the injected sites and growth of non-cardiac tissues.

**METHODS:** Ten patients (eight men) were enrolled; they were 59±5 years old with limiting angina and were non-optimal candidates for complete CABG. Bone marrow cells ( $1.3\pm 0.3 \times 10^8$ ) were obtained prior to surgery, and the lymphomonocytic fraction (CD34+=1.8±0.3%) was separated by density gradient centrifugation. During surgery, bone marrow cells were injected in non-grafted areas of ischemic myocardium. During the first year after surgery, the patients underwent laboratory tests, cardiac imaging, and 24-hour ECG monitoring.

**RESULTS:** Injected segments: inferior (n=7), anterior (n=2), septal (n=1), apical (n=1), and lateral (n=1) walls. Except for a transient elevation of C-reactive protein at one month post-surgery (P=0.01), laboratory tests results were within normal ranges; neither complex arrhythmias nor structural abnormalities were detected during follow-up. There was a reduction in functional class of angina from 3.6±0.8 (baseline) to 1.2±0.4 (one year) (P<0.0001). Also, patients had a significant decrease in the ischemic score assessed by magnetic resonance, not only globally from 0.65±0.14 (baseline) to 0.17±0.05 (one year) (P=0.002), but also in the injected areas from 1.11±0.20 (baseline) to 0.34±0.13 (one year) (P=0.0009).

**CONCLUSIONS:** Intramyocardial injection of bone marrow cells combined with CABG appears to be safe. Theoretical concerns with arrhythmias and/or structural abnormalities after cell therapy were not confirmed in this safety trial.

**KEY WORDS:** Cells. Cardiac surgery. Angiogenesis. Angina. Ischemia.

---

**INTRODUCTION**

Cell therapy represents a novel therapeutic strategy for treating cardiovascular diseases including ischemic heart disease (IHD) and heart failure.<sup>1,2</sup> It is widely accepted that bone

marrow-derived cells (BMC) can play a role in the induction of angiogenesis under different conditions such as wound healing and limb ischemia,<sup>3,4</sup> post-myocardial infarction,<sup>5,6</sup> and endothelialization of vascular grafts.<sup>7</sup> Results from animal models of IHD have shown that pluripotent stem cells have the potential to differentiate in both contractile and blood vessels in ischemic tissues.<sup>8,9</sup> Early reports of improvement in myocardial perfusion and segmental contractility either for acute<sup>10</sup> or chronic<sup>11</sup> IHD in small series of patients have established the feasibility and short-term safety of transplantation of BMC in IHD.

---

Heart Institute (InCor), Faculdade de Medicina da Universidade de São Paulo - São Paulo/SP, Brazil.

luis.gowdak@incor.usp.br

Received for publication on 19/12/07

Accepted for publication on 26/12/07

---

Still, the long-term safety profile of BMC in the clinical setting is subject to several major concerns.<sup>12</sup> Since BMC consist of a heterogeneous population of undifferentiated cells able to differentiate into various cell types by means of a complex and poorly understood process, it is possible that unintended cell differentiation towards non-cardiac tissues may occur<sup>13</sup> as well as oncogenic transformation.<sup>14</sup> Uncontrolled vascular growth has been demonstrated in transgenic animals expressing increased levels of angiogenic cytokines,<sup>15</sup> a finding inspiring caution since BMC can express different angiogenic factors.<sup>16</sup> Based on previous data on the use of myoblasts in cell therapy trials, malignant ventricular arrhythmias have been documented with potentially serious consequences.<sup>17,18</sup> These safety issues must be carefully addressed before progressing to efficacy studies with a larger number of patients.

Accordingly, the present study was designed to test the hypothesis that, in the long-term, intramyocardial injection of autologous BMC is feasible, safe and well-tolerated. Furthermore, this injection may serve as an adjunctive therapy to patients undergoing surgical myocardial revascularization for severe IHD and diffuse coronary artery disease (CAD), helping to increase myocardial perfusion and contractility.

## METHODS

This prospective, non-randomized, open-label, phase I clinical study was approved by the Institutional Ethics Committee and was conducted in accordance with federal guidelines of the Brazilian National Research Ethics Council (CONEP).

### Patient Selection

From August 2002 to July 2003, ten patients were referred to the Cell Therapy Group for Chronic Ischemic Heart Disease at the Heart Institute (InCor) for clinical evaluation. They were included in this safety trial based on the following criteria: the age was between 18 and 80 years; limiting angina was present (Class III-IV as defined by the Canadian Cardiovascular Society<sup>19</sup> despite maximally tolerated medical therapy); multi-vessel CAD was present; patients were non-optimal candidates for a “complete” bypass surgery due to the extension and severity of the obstructive lesions according to an expert panel; and patients had at least one non-bypassable coronary artery associated with an area of viable, ischemic myocardium. Patients were excluded if any of the following criteria was met: life expectancy less than one year; past or current history of neoplasia; no objective evidence of myocardial ischemia; primary hematological disease; or associated cardiomyopathy of other etiologies. All

patients provided a signed, written informed consent. Table 1 shows the clinical characteristics of enrolled patients.

**Table 1** - Clinical characteristics of enrolled patients.

Variable	Patients (n=10)
Age (years)	59±5
Male / female (n)	8 / 2
Diabetes (n)	7
Hypertension (n)	10
Hypercholesterolemia (n)	8
Current or previous smoker (n)	6
Previous myocardial infarction (n)	5
Previous myocardial revascularization (PCI/CABG) (n)	7

## Study Protocol

At baseline (B), and at 1, 3, 6, and 12 months after the procedure, all patients were subjected to a clinical evaluation, laboratory tests, 24-h Holter monitoring, and echocardiogram. Also, myocardial perfusion was blindly assessed by magnetic resonance imaging (MRI). After the first year, patients were followed on a clinical basis only. A five-year follow-up re-evaluation is currently being performed.

### • 24-h Holter Monitoring

ECG Holter monitoring was performed with Marquette 800 portable amplitude-modulated two-channel devices (Marquette 9428; Marquette Medical Systems, Milwaukee, WI). After the monitor was withdrawn, the tapes were analyzed with the MARS system (Marquette). Maximum, minimum, and mean heart rate values were determined, and the occurrence of arrhythmias was recorded.

### • Echocardiogram

Echocardiogram examinations were performed by two-dimensional (2-D) imaging and by spectral and color flow mapping with a 2.75-MHz transducer or a 2–4-MHz/3–5-MHz phased array transducer as previously described<sup>20</sup> with an Apogee CX 200 ultrasound system (Interspec, Inc, Ambler, PA), or with an HDI 3000/5000 device (Advanced Technology Laboratories, Bothell, WA). The left ventricle (LV) ejection fraction was determined by the 2-D mode from the apical view (4- and 2-chamber), according to Simpson’s rule.

### • Magnetic Resonance Imaging (MRI)

All patients underwent MRI examination in a 1.5T MR scanner (GE CV/i System, GE Medical Systems, Wakesha, WI). First-pass myocardial perfusion LV short-axis images were obtained 3 min after dipyridamole injection (0.56mg.

kg<sup>-1</sup> injected over 4 min). After dynamic MR images acquisition was started, 0.05mM.kg<sup>-1</sup> of gadolinium-based contrast material (gadodiamide, Ominiscan™, Amersham Health, Princeton, NJ) was injected into the antecubital vein by a power injector at a rate of 5mL.s<sup>-1</sup> and followed by a 20-mL saline flush. Immediately after this stress perfusion sequence, aminophylline was intravenously injected. Myocardial perfusion was blindly determined in 17 myocardial segments; each segment was graded as normal perfusion (score 0), or having mild (score 1) or severe (score 2) perfusion defects. An overall ischemic score based on all 17 segments (total ischemic score) or only segments injected with BMC (regional ischemic score) was calculated.

#### Preparation of the BMC

After induction of anesthesia and immediately prior to surgery, 100 mL of bone marrow from the right posterior iliac crest were aspirated and heparinized. Bone marrow-derived progenitor and mononuclear cells were isolated by density gradient centrifugation on Ficoll-Paque Plus™ (Amersham Biosciences Corp., Piscataway, NJ), washed with heparinized saline, resuspended in 5mL normal saline, and placed in five 1-mL syringes ready for injection. A 1-mL sample of the cell suspension was used for cell counting and sorting by flow cytometry using leukocyte differentiation markers. A trypan blue exclusion test showed viability greater than 90%.

#### • Flow Cytometry Analysis

The cell sample consisted of a heterogeneous cell population with bone marrow-derived progenitor and mononuclear

cells. The samples were treated with human IgG polyclonal antibody and incubated with the different monoclonal antibodies conjugated with fluorescein isothiocyanate (Pharmingen, San Diego, CA), phycoerythrin (PE), PerCP or CyChrome as shown in Table 2.<sup>21</sup>

Erythrocytes were lysed after staining with BD lysis buffer solution according to the manufacturer's instructions. Data acquisition and analyses were performed on a three-color immunofluorescent FACS with CellQuest 3.1 software (BD).

#### Injection of BMC During Surgical Myocardial Revascularization

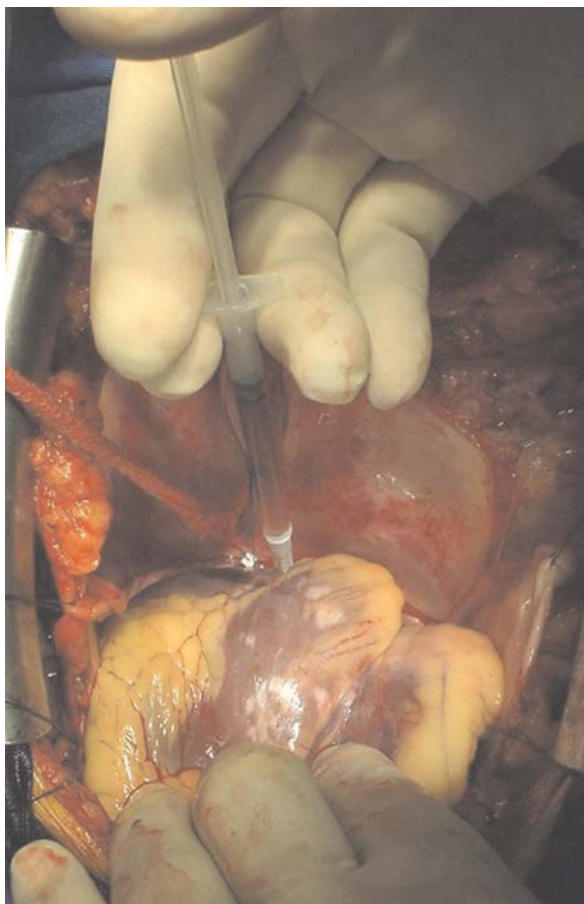CABG was done during cardiopulmonary bypass and warm blood cardioplegic arrest as previously described.<sup>22</sup> Once all bypasses had been completed, 25 samples of cell suspension (0.2 mL) were injected into the ischemic non-bypassable area of myocardium, using a 22-gauge hypodermic needle (Figure 1). Afterwards, the heart was reperfused, and the operation completed as usual.

#### Statistical Analysis

Data analyses were performed with a commercially available statistical package (JMP® for Windows – version 6.0.0, SAS Institute Inc., Cary, NC). Results for continuous variables are presented as mean±SD, and for categorical variables as percentages. One-way ANOVA with repeated measurements was used for comparison between time points. Statistical significance was set at P<0.05.

**Table 2** - Flow cytometry markers.<sup>21</sup>

Antibody	Main cellular expression	Manufacturer
Anti-CD3 (clone HI3a)	Thymocytes, T cells	Pharmingen
Anti-CD4 (clone MT310)	Thymocyte subsets, helper and inflammatory T cells (about two thirds of peripheral T cells), monocytes, macrophages	Pharmingen
Anti-CD8 (clone DK250)	Thymocyte subsets, cytotoxic T cells (about one third of peripheral T cells)	Pharmingen
Anti-CD10 (clone HI10a)	B and T cell precursors, bone marrow stromal cells	Becton, Dickinson & Co
Anti-CD13 (clone WM-47)	Myelomonocytic cells	Dako North America
Anti-CD14 (clone TUK-4)	Myelomonocytic cells	Pharmingen
Anti-CD15 (clone BI59)	Neutrophils, eosinophils, monocytes	Pharmingen
Anti-CD19 (clone HD-37)	B cells	Pharmingen
Anti-CD31 (clone L133.1)	Monocytes, platelets, granulocytes, B cells, endothelial cells	Becton, Dickinson & Co
Anti-CD34 (clone HPCA-2)	Hematopoietic precursors, capillary endothelium	Becton, Dickinson & Co
Anti-CD38 (clone HB27)	Early B and T cells, activated T cells, germinal center B cells, plasma cells	Becton, Dickinson & Co
Anti-CD45 (clone 2D1)	All hematopoietic cells	Becton, Dickinson & Co
Anti-CD56 (clone BI59)	Natural killer cells	Pharmingen
Anti-CD133 (clone AC141)	Stem/progenitor cells	Miltenyi Biotech Inc



**Figure 1** - Intramyocardial injection of autologous bone marrow cells during CABG in non-bypassable areas of ischemic, viable myocardium.

## RESULTS

### Procedural Data

The total operation time for CABG (including the intramyocardial injections of BMC) was  $6\text{h}27\text{min}\pm 1\text{h}25\text{min}$ ; the “on-pump” time was  $1\text{h}04\text{min}\pm 15\text{min}$ . Patients had  $4.1\pm 1.7$  coronary arteries with stenosis greater than 70% and they received  $2.6\pm 0.2$  grafts.

Injected myocardial segments (n=12) included the inferior (n=7), anterior (n=2), septal (n=1), apical (n=1) and lateral (n=1) walls. Note that in two patients, more than one myocardial segment was injected with BMC.

The number of cells injected per patient was  $1.3\pm 0.3\times 10^8$ . The fractions of CD34+ and CD133+ cells were  $1.50\pm 0.15\%$  and  $0.67\pm 0.65\%$ , respectively. A more detailed analysis of the cell population subtypes can be seen in Table 3.

### Clinical Morbidity and Mortality

The mean in-hospital stay after surgery was  $11\pm 2$  days. In-hospital non-fatal complications included pulmonary

**Table 3** - Selected cell populations (%) after flow cytometry.

Cell Population Phenotype	% of Injected Cells
CD34+	$1.50\pm 0.15$
CD45+ CD133+	$0.7\pm 0.1$
CD45- CD133+	$0.04\pm 0.01$
CD14+	$6.6\pm 0.8$
CD19+	$4.0\pm 0.5$
CD4+	$9.1\pm 1.1$
CD8+	$5.7\pm 0.7$
CD31+	$2.2\pm 0.3$

infection (n=2) and acute decompensation of heart failure (n=1), all of which were managed clinically and completely resolved after a few days. There were no deaths related to the procedure and all patients were discharged for follow-up at the out-patient clinic.

All patients completed the pre-specified first year of follow-up; no complications were recorded. During this period, the angina functional class levels significantly decreased from  $3.6\pm 0.8$  (baseline) to  $1.2\pm 0.4$  (12 months) ( $P < 0.0001$ ).

### Laboratory Tests

Results of main biochemical/hematological tests are shown in Table 4. We observed a significant elevation of C-reactive protein at one month after surgery compared to baseline, but this value returned to the normal range in the following evaluations. No other hematological abnormalities, including liver or renal dysfunction, were observed.

### Cardiac Arrhythmias

The mean heart rate (HR) and the number of supraventricular or ventricular premature beats are shown in Table 5. During follow-up, no patient presented life-threatening arrhythmias such as sustained ventricular tachycardia (VT).

### Echocardiogram

No structural abnormalities were seen on Doppler echocardiograms for any time point after the procedure: no pericardial effusion, no fibrosis at injection sites, and no growth of non-cardiac tissues. At 12 months after surgery, LV function analysis showed that, compared to baseline, there was no significant change in either the mean LV end-systolic volume ( $73\pm 7$  vs.  $68\pm 10\text{mL}$ ;  $P=0.41$ ) or the mean end-diastolic volume ( $149\pm 10$  vs.  $136\pm 13\text{mL}$ ;  $P=0.47$ )

**Table 4** - Selected laboratory tests at baseline and during the first year of follow-up.

Variable	Baseline	1 m	3 m	6 m	12 m	P
Hemoglobin (g/dL)	13.9±1.5	12.0±1.3	13.6±1.3	13.4±2.1	13.2±1.9	0.12
White cells (x10 <sup>3</sup> /mm <sup>3</sup> )	7.6±1.9	7.0±1.7	7.1±2.3	6.7±1.5	6.5±1.6	0.67
Platelets (x10 <sup>3</sup> /mm <sup>3</sup> )	230±57	271±144	231±46	236±79	191±78	0.39
Urea (mg/dL)	42±14	44±12	37±13	39±15	44±13	0.80
Creatinine (mg/dL)	1.2±0.3	1.2±0.6	1.1±0.2	1.2±0.5	1.2±0.5	0.92
AST	12±6	10±4	10±2	10±3	10±3	0.55
ALT	16±11	19±5	11±2	11±5	11±4	0.44
Glucose level (mg/dL)	113±34	124±39	113±19	111±29	137±48	0.43
Total cholesterol (mg/dL)	184±36	154±29	165±27	177±32	167±29	0.25
HDL-cholesterol (mg/dL)	43±7	37±5	40±5	40±5	45±6	0.02
LDL-cholesterol (mg/dL)	106±24	84±24	93±29	92±38	93±21	0.57
Triglycerides (mg/dL)	178±89	167±58	157±51	179±65	133±46	0.47
C-reactive protein (mg/dL)	0.1±0.1	4.0±3.5	0.2±0.1	0.2±0.1	0.4±0.5	0.01
INR	1.0±0.1	1.1±0.1	1.1±0.1	1.0±0.1	1.0±0.1	0.80

**Table 5** - Data from 24-h ECG monitoring (Holter) at baseline and during the first year of follow-up.

Variable	Baseline	1 m	3 m	6m	12m	P
Mean heart rate (bpm/min)	73±10	75±12	79±17	74±11	74±12	0.88
Ventricular premature beats/h	6±13	5±9	8±17	34±6	6±9	0.58
Supraventricular premature beats/h	3±4	7±11	2±2	4±9	15±35	0.55

(Table 6). Overall, there was no significant change in the mean LV ejection fraction ( $0.54\pm0.03$  vs.  $0.52\pm0.03$ ;  $P=0.68$ ) compared to baseline.

### Magnetic Resonance Imaging (MRI)

As seen in Figure 2, the LV ischemic score decreased significantly during the first year (panel A) as expected after a myocardial revascularization procedure. More interestingly, however, there was also an early and sustained improvement in myocardial perfusion in injected non-revascularized areas compared to baseline (panel B). No structural abnormalities were seen on the MRI after the procedure.

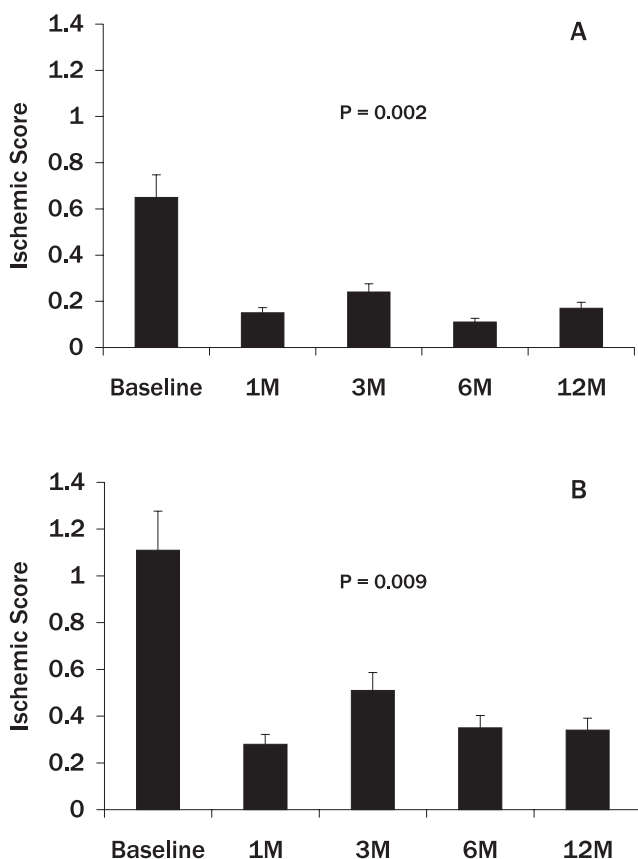
### DISCUSSION

The results presented here show the feasibility and long-term safety of intramyocardial injection of autologous BMC combined with surgical myocardial revascularization in patients suffering from diffuse CAD, who were not optimal candidates for a complete surgical bypass procedure. Moreover, injected BMC might have contributed to increased tissue perfusion in areas of ischemic myocardium not suitable for direct revascularization.

The majority of patients with mild to moderate angina can be adequately treated with anti-anginal medications.<sup>23</sup> However, as life expectancy increases and the mortality

**Table 6** - Echocardiography data at baseline and during the first year of follow-up.

Variable	Baseline	1 m	3 m	6m	12m	P
Septum (mm)	10±1	10±1	10±1	10±1	9±2	0.28
Posterior wall (mm)	10±1	9±1	10±1	10±1	9±1	0.39
LV end-diastolic diameter (mm)	51±7	55±6	53±5	53±5	53±9	0.94
LV ejection fraction (%)	63±14	66±8	58±13	61±8	67±13	0.80
Left atrium (mm)	41±8	40±3	40±2	42±1	38±5	0.62
Aorta (mm)	32±3	32±3	32±4	32±3	28±9	0.58



**Figure 2** - Total (A) and regional (B) LV ischemic scores as assessed by MRI at baseline and during the first year after injection of BMC.

rate due to acute coronary syndromes decreases, there is a growing population of patients with CAD for whom medical therapy is only partially effective. New therapeutic strategies are necessary, since many of them have already undergone multiple PCIs or surgical revascularization and hence, are not “ideal” candidates for additional procedures.

Deprivation of oxygen and nutrients to myocytes in chronic IHD may lead to death of viable myocardium and cell replacement by fibrous tissue deposition, which further impairs LV function. Neoangiogenesis, a multifactorial process involving complex interactions between inflammatory cells, cytokines, and many extracellular matrix proteins, is a crucial step in preserving cardiomyocytes from death.<sup>24</sup> Usually, when extensive myocardial ischemic injury occurs, the contribution of neoangiogenesis to the ischemic capillary network is insufficient to keep pace with tissue demands; therefore, normal contractility of ischemic, but viable, myocardium cannot be sustained.<sup>25</sup>

Experimental evidence suggests that BMC have the potential to induce therapeutic angiogenesis in ischemic tissues.<sup>26</sup> After vascular injury, endothelial progenitor cells are naturally mobilized from the bone marrow to the circula-

tion, along with hematopoietic stem cells and hematopoietic progenitor cells. The physiological role of co-recruitment of hematopoietic stem and progenitor cells in formation of long-lasting functional neovessels remains to be determined.<sup>27</sup>

Based on the initial reports of successful transplantation of progenitor cells in patients with acute or chronic coronary artery disease,<sup>9-11</sup> we conducted this phase I, open-label, non-randomized trial and were able to show that intramyocardial injection of autologous BMC combined with surgical myocardial revascularization is feasible, safe and well-tolerated. However, our data suggest a role for injected BMC in increasing myocardial perfusion.

Regarding safety issues within the first year after this procedure, early complications included pulmonary infection and decompensation of heart failure, conditions most likely related to the surgical procedure itself rather than the cell injections *per se*. One of the most disturbing complications related to cell therapy, based on previous experience with myoblasts, is the occurrence of malignant arrhythmias. Fortunately, there was no detectable increase in the number of supraventricular or ventricular premature beats and no life-threatening arrhythmias were detected.

Except for a transient elevation of C-reactive protein early in the follow-up after surgery, all other biochemical and hematological values were within the normal range. Again, since CRP is a marker of inflammation, its elevation is no surprise after a major surgery like CABG. Cardiac imaging studies showed no evidence of scar tissue formation in the injection sites, no evidence of structural abnormalities related to the procedure such as pericardial effusion, and no evidence of *in situ* growth of non-cardiac tissues.

Overall, there was no overall appreciable change in LV ejection fraction or end-diastolic/systolic volumes. One can assume that since the mean LV function was within the normal range, no significant improvement would be seen in an already normal LV function. Nevertheless, specifically in patients with low LV ejection fraction, LV function increased significantly after surgery (data not shown), reflecting the functional recovery of ischemic viable (hibernating) myocardium.

Although this was basically a safety trial, we performed a myocardial perfusion assessment in an attempt to collect preliminary data on the efficacy of stem cell therapy for severe CAD. MRI results showed a significant decrease in the LV ischemic score after the procedure; this decrease was not only in the total ischemic score (as expected), but also in the injected, non-revascularized areas. These data suggest an improvement in myocardial perfusion in the injected but non-grafted areas. Even though an indirect effect for this improvement from the grafts placed in the adjacent areas cannot be ruled out, it is tempting to speculate that the transplanted

cells may have contributed to this response. In a study similar to ours, Stamm et al.<sup>28</sup> injected BMC into the infarct border zone in six patients who had had a myocardial infarction and undergone CABG. Their work showed that, as of three to nine months after surgery, LV function was enhanced in four patients, and infarct tissue perfusion had improved strikingly in five patients. More recently,<sup>29</sup> the same group extended their initial series of patients and concluded that, at least for the first three years of follow-up, intramyocardial delivery of purified bone marrow stem cells together with CABG surgery is safe and provides beneficial effects.

In summary, we were able to show that, during the first year of a four year follow-up, intramyocardial injection of BMC appears to be safe and may have contributed to increased myocardial perfusion in the ischemic, non-revascularized myocardium. The effectiveness of cell transplantation in improving myocardial perfusion and contractility in patients with advanced CAD is a question to be addressed

in controlled, randomized studies with a larger series of patients and longer follow-up. Cell transplantation has been addressed in recent studies, albeit with conflicting results.<sup>30,31</sup> A much larger, multicenter, randomized, double-blind, placebo-controlled study is underway.<sup>32</sup>

## ACKNOWLEDGMENTS

The authors would like to express their gratefulness to Teresa Cristina B. F. da Silva, RN, for her dedication to the care of patients; to Maria de Lourdes Junqueira, BS, for technical assistance; and to Meyrielli Alves Vieira, for secretarial assistance. This study was supported by grants from Fundação de Amparo à Pesquisa do Estado de São Paulo (FAPESP Grant 01/00009-0 to JEK), Conselho Nacional de Desenvolvimento Científico e Tecnológico (CNPq Grant 552320/2005/6 to LHWG, and 552324/2005-1 to JEK) and Fundação Zerbini.

## REFERENCES

1. Menasche P. Stem cells for clinical use in cardiovascular medicine: current limitations and future perspectives. *Thromb Haemost.* 2005;94:697-701.
2. Balsam LB, Robbins RC. Haematopoietic stem cells and repair of the ischaemic heart. *Clin Sci (Lond).* 2005;109:483-92.
3. Luttun A, Carmeliet G, Carmeliet P. Vascular progenitors: from biology to treatment. *Trends Cardiovasc Med.* 2002;12:88-96.
4. Takahashi T, Kalka C, Masuda H, Chen D, Silver M, Kearney M, et al. Ischemia- and cytokine-induced mobilization of bone marrow-derived endothelial progenitor cells for neovascularization. *Nat Med.* 1999;5:434-8.
5. Orlic D, Kajstura J, Chimenti S, Limana F, Jakoniuk I, Quaini F, et al. Mobilized bone marrow cells repair the infarcted heart, improving function and survival. *Proc Natl Acad Sci USA.* 2001;98:10344-9.
6. Kocher AA, Schuster MD, Szabolcs MJ, Takuma S, Burkhoff D, Wang J, et al. Neovascularization of ischemic myocardium by human bone-marrow-derived angioblasts prevents cardiomyocyte apoptosis, reduces remodeling and improves cardiac function. *Nat Med.* 2001;7:430-6.
7. Noishiki Y, Tomizawa Y, Yamane Y, Matsumoto A. Autocrine angiogenic vascular prosthesis with bone marrow transplantation. *Nat Med.* 1996;2:90-3.
8. Orlic D, Kajstura J, Chimenti S, Jakoniuk I, Anderson SM, Li B, et al. Bone marrow cells regenerate infarcted myocardium. *Nature.* 2001;410:701-5.
9. Hamano K, Li TS, Kobayashi T, Hirata K, Yano M, Kohno M, et al. Therapeutic angiogenesis induced by local autologous bone marrow cell implantation. *Ann Thorac Surg.* 2002;73:1210-5.
10. Assmus B, Schächinger V, Teupe C, Britten M, Lehmann R, Döbert N, et al. Transplantation of progenitor cells and regeneration enhancement in acute myocardial infarction (TOPCARE-AMI). *Circulation.* 2002;106:3009-17.
11. Perin EC, Dohmann HF, Borojevic R, Silva SA, Sousa AL, Mesquita CT, et al. Transendocardial, autologous bone marrow cell transplantation for severe, chronic ischemic heart failure. *Circulation.* 2003;107:2294-302.
12. Gersh BJ, Simari RD. Cardiac cell-repair therapy: clinical issues. *Nat Clin Pract Cardiovasc Med.* 2006;3(Suppl 1):S105-9.
13. Yoon YS, Park JS, Tkebuchava T, Luedeman C, Losordo DW. Unexpected severe calcification after transplantation of bone marrow cells in acute myocardial infarction. *Circulation.* 2004;109:3154-7.
14. Singh SK, Clarke ID, Terasaki M, Bonn VE, Hawkins C, Squire J, et al. Identification of a cancer stem cell in human brain tumors. *Cancer Res.* 2003;63:5821-8.
15. Kitajima S, Liu E, Morimoto M, Koike T, Yu Y, Watanabe T, et al. Transgenic rabbits with increased VEGF expression develop hemangiomas in the liver: a new model for Kasabach-Merritt syndrome. *Lab Invest.* 2005;85:1517-27.
16. Liu Y, Guo J, Zhang P, Zhang S, Chen P, Ma K, Zhou C. Bone marrow mononuclear cell transplantation into heart elevates the expression of angiogenic factors. *Microvasc Res.* 2004;68:156-60.
17. Menasché P, Hagege AA, Vilquin JT, Desnos M, Abergel E, Pouzet B, et al. Autologous skeletal myoblast transplantation for severe postinfarction left ventricular dysfunction. *J Am Coll Cardiol.* 2003;41:1078-83.

18. Siminiak T, Kalawski R, Fiszer D, Jerzykowska O, Rze niczak J, Rozwadowska N, et al. Autologous skeletal myoblast transplantation for the treatment of postinfarction myocardial injury: phase I clinical study with 12 months of follow-up. *Am Heart J*. 2004;148:531-7.
19. Campeau L. Grading of angina pectoris. *Circulation*. 1976;54:522-3.
20. Schiller NB, Shah PM, Crawford M, DeMaria A, Devereux R, Feigenbaum H, et al. Recommendations for quantitation of the left ventricle by two-dimensional echocardiography. American Society of Echocardiography Committee on Standards, Subcommittee on Quantitation of Two-Dimensional Echocardiograms. *J Am Soc Echocardiogr*. 1989;2:358-67.
21. Appendix II. CD Antigens. In: Janeway C, Travers P, Walport M, Shlomchik M, editors. *Immunobiology: the immune system in health and disease – 5<sup>th</sup> Edition*. Oxford, UK: Garland Publishing; 2001. Disponível em: <http://www.ncbi.nlm.nih.gov/books/bv.fcgi?rid=imm.table.2497>. Acesso em: 24/Jan/2008.
22. Eagle KA, Guyton RA, Davidoff R, Edwards FH, Ewy GA, Gardner TJ, et al. ACC/AHA 2004 guideline update for coronary artery bypass graft surgery: a report of the American College of Cardiology/American Heart Association Task Force on Practice Guidelines (Committee to Update the 1999 Guidelines for Coronary Artery Bypass Graft Surgery). American College of Cardiology Web Site. Available at: <http://www.acc.org/clinical/guidelines/cabg/cabg.pdf>.
23. Gibbons RJ, Abrams J, Chatterjee K, Daley J, Deedwania PC, Douglas JS, et al. American College of Cardiology; American Heart Association Task Force on practice guidelines (Committee on the Management of Patients With Chronic Stable Angina). ACC/AHA 2002 guideline update for the management of patients with chronic stable angina: a report of the American College of Cardiology/American Heart Association Task Force on Practice Guidelines (Committee to Update the 1999 Guidelines for the Management of Patients with Chronic Stable Angina). *J Am Coll Cardiol*. 2003;41:159-68.
24. Kalkman EA, Bilgin YM, van Haren P, van Suylen RJ, Saxena PR, Schoemaker RG. Determinants of coronary reserve in rats subjected to coronary artery ligation or aortic banding. *Cardiovasc Res*. 1996;32:1088-95.
25. Braunwald E, Rutherford JD. Reversible ischemic left ventricular dysfunction: evidence for the “hibernating myocardium”. *J Am Coll Cardiol*. 1986;8:1467-70.
26. Kalka C, Masuda H, Takahashi T, Kalka-Moll WM, Silver M, Kearney M, et al. Transplantation of ex vivo expanded endothelial progenitor cells for therapeutic neovascularization. *Proc Natl Acad Sci USA*. 2000;97:3422-7.
27. Rafii S, Lyden D. Therapeutic stem and progenitor cell transplantation for organ vascularization and regeneration. *Nat Med*. 2003;9:702-12.
28. Stamm C, Westphal B, Kleine HD, Petzsch M, Kittner C, Klinge H, et al. Autologous bone-marrow stem-cell transplantation for myocardial regeneration. *Lancet*. 2003;361:45-6.
29. Stamm C, Kleine HD, Choi YH, Dunkelmann S, Lauffs JA, Lorenzen B, et al. Intramyocardial delivery of CD133+ bone marrow cells and coronary artery bypass grafting for chronic ischemic heart disease: safety and efficacy studies. *J Thorac Cardiovasc Surg*. 2007;133:717-25.
30. Lunde K, Solheim S, Aakhus S, Arnesen H, Abdelnoor M, Egeland T, et al. Intracoronary injection of mononuclear bone marrow cells in acute myocardial infarction. *N Eng J Med*. 2006;355:1199-209.
31. Schächinger V, Erbs S, Elsässer A, Haberbosch W, Hambrecht R, Hölschermann H, et al. Intracoronary Bone Marrow-Derived Progenitor Cells in Acute Myocardial Infarction. *N Eng J Med*. 2006;355:1199-209.
32. Tura BR, Martino HF, Gowdak LH, dos Santos RR, Dohmann HF, Krieger JE, et al. Multicenter randomized trial of cell therapy in cardiopathies - MiHeart Study. *Trials*. 2007;8:2.