

CLINICAL SCIENCE

Thoracic Injuries in earthquake-related versus non-earthquake-related trauma patients: differentiation via Multi-detector Computed Tomography

Zhi-hui Dong,¹ Zhi-gang Yang,^{1,II} Tian-wu Chen,^{1,III} Zhi-gang Chu,¹ Wen Deng,¹ Heng Shao¹

¹Department of Radiology, West China Hospital of Sichuan University, Chengdu, China. ^{II}State Key Laboratory of Biotherapy, West China Hospital of Sichuan University, Chengdu, China. ^{III}Sichuan Province Key Laboratory of Medical Imaging and Department of Radiology, Affiliated Hospital of North Sichuan Medical College, 63# Wen Hua Lu, Nanchong, Sichuan, China.

PURPOSE: Massive earthquakes are harmful to humankind. This study of a historical cohort aimed to investigate the difference between earthquake-related crush thoracic traumas and thoracic traumas unrelated to earthquakes using a multi-detector Computed Tomography (CT).

METHODS: We retrospectively compared an earthquake-exposed cohort of 215 thoracic trauma crush victims of the Sichuan earthquake to a cohort of 215 non-earthquake-related thoracic trauma patients, focusing on the lesions and coexisting injuries to the thoracic cage and the pulmonary parenchyma and pleura using a multi-detector CT.

RESULTS: The incidence of rib fracture was elevated in the earthquake-exposed cohort (143 vs. 66 patients in the non-earthquake-exposed cohort, Risk Ratio (RR) = 2.2; $p < 0.001$). Among these patients, those with more than 3 fractured ribs (106/143 vs. 41/66 patients, RR = 1.2; $p < 0.05$) or flail chest (45/143 vs. 11/66 patients, RR = 1.9; $p < 0.05$) were more frequently seen in the earthquake cohort. Earthquake-related crush injuries more frequently resulted in bilateral rib fractures (66/143 vs. 18/66 patients, RR = 1.7; $p < 0.01$). Additionally, the incidence of non-rib fracture was higher in the earthquake cohort (85 vs. 60 patients, RR = 1.4; $p < 0.01$). Pulmonary parenchymal and pleural injuries were more frequently seen in earthquake-related crush injuries (117 vs. 80 patients, RR = 1.5 for parenchymal and 146 vs. 74 patients, RR = 2.0 for pleural injuries; $p < 0.001$). Non-rib fractures, pulmonary parenchymal and pleural injuries had significant positive correlation with rib fractures in these two cohorts.

CONCLUSIONS: Thoracic crush traumas resulting from the earthquake were life threatening with a high incidence of bony thoracic fractures. The ribs were frequently involved in bilateral and severe types of fractures, which were accompanied by non-rib fractures, pulmonary parenchymal and pleural injuries.

KEYWORDS: Thorax; Rib; Injury; Earthquake; Tomography, X-ray computed.

Dong ZH, Yang ZG, Chen TW, Chu ZG, Deng W, Shao H. Thoracic Injuries in earthquake-related versus non-earthquake-related trauma patients: differentiation via Multi-detector Computed Tomography. Clinics. 2011;66(5):817-822.

Received for publication on January 19, 2011; First review completed on February 21, 2011; Accepted for publication on February 21, 2011

E-mail: dongzhih@163.com

Tel.: 86-28-85423817

INTRODUCTION

At 2:28 PM Beijing Time, on May 12, 2008, a magnitude 8.0 earthquake hit the densely populated region in Sichuan, China. This disaster injured approximately 374,643 people. As one of the important rescue centers immediately following the earthquake, a total of 2674 wounded patients presented to our hospital by June 7, 2008. This 4300 bed key university hospital is located 57 miles away from the Wenchuan County epicenter and was not damaged by the earthquake. Patients were transported to the facility mainly by vehicle or helicopter.

Chest traumas comprise 7.6–15.9% of earthquake-related traumas,¹⁻³ and 10–15% of all other trauma. Patients with chest traumas may carry a mortality rate ranges from 8.2–33.3%.⁴⁻⁷ The incidence of disaster-related crush injuries is high.⁸ Crush injuries, which were the main cause of thoracic trauma during the Sichuan earthquake, were significantly different from the major etiologies of other common thoracic traumas, which generally include traffic accidents, falls, assault and work-related accidents.⁹ We propose that there is a difference between earthquake-related crush traumas and other common types of injuries from different injury mechanisms. Previously, we performed a retrospective study using multi-detector CT as a reliable modality to determine thoracic traumas¹⁰ and reported that thoracic crush traumas resulting from the Sichuan earthquake might differ from other common thoracic traumas.¹¹ To verify these differences,

Copyright © 2011 CLINICS – This is an Open Access article distributed under the terms of the Creative Commons Attribution Non-Commercial License (<http://creativecommons.org/licenses/by-nc/3.0/>) which permits unrestricted non-commercial use, distribution, and reproduction in any medium, provided the original work is properly cited.

we performed the current historical cohort study using multi-detector CT (MDCT) alone. We cite improved disaster preparedness as an overarching goal of this investigation.

MATERIALS AND METHODS

Patients

The study was approved by the ethics committee of the medical school, and because of the retrospective nature of this historical cohort study, informed consent was waived. We consecutively enrolled patients into the earthquake-related cohort (exposed cohort) according to the following criteria: (1) the etiology of the injuries was associated with the 2008 Sichuan earthquake, (2) thoracic traumas were evaluated using multi-detector CT, and (3) the patients had not received a related thoracotomy (excluding chest tube drainage) before the chest multi-detector CT examination. We excluded patients who had jumped or accidentally fallen from heights because of the earthquake and those who were injured in an earthquake-related motor vehicle collision. Similar inclusion criteria were used to enroll patients into the non-earthquake-related cohort (unexposed cohort), except that the etiology was not associated with the earthquake. By examining patient records from May 12, 2008 to June 7 2008, we identified and consecutively enrolled 215 patients with clinically relevant thoracic traumas from the Sichuan earthquake who met the inclusion criteria. In order to gather an unexposed cohort of the same size, we examined patient records from May 1, 2008 to July 8, 2008 and identified and consecutively enrolled 215 thoracic trauma patients who met the inclusion criteria.

MDCT Protocols

From the earthquake-related cohort, chest CT scans of 122, 71 and 22 patients were obtained by using a 16-section scanner (Somatom Sensation 16; Siemens Medical Systems, Forchheim, Germany), a 4-section scanner (Somatom Plus 4; Siemens Medical Systems) and a 64-section scanner (Brilliance 64; Philips Medical Systems, Eindhoven, the Netherlands), respectively. For the non-earthquake, common injury cohort, the 215 chest CT scans were performed using the 16-section scanner. Each patient underwent a multi-detector CT scan of the lungs from the neck to the lower pole of the right kidney. Scanning parameters were as follows: 120 KV, 100 mAs, rotation time 0.5 s, pitch 0.85 and collimation 16×0.75 mm for the Siemens Somatom Sensation 16-MDCT scanner; 120 KV, 200 mAs, rotation time 0.5 s, pitch 1.5 and collimation 4×2.5 mm for the Siemens Somatom Plus 4-MDCT scanner; and 120 KV, 200 mAs, rotation time 0.5 s, pitch 0.891 and collimation 64×0.625 mm for the Philips Brilliance 64-MDCT scanner. Contrast-enhanced CT examinations for suspected injuries to the pectoral vessels or mediastinum were performed on 8 patients in the earthquake-related cohort and 2 patients in the non-earthquake cohort. Contrast-enhanced CT examinations were performed by administering 100 ml of nonionic contrast agent (iohexol, 300 mg of iodine per milliliter; Beijing Beilu Pharmaceutical, Beijing, China), which was infused using a power injector (Stellant; Medrad, Indianola, Pa.) with a flow rate of 3.0 ml/sec through an intravenous antecubital catheter. The sagittal and coronal images were reconstructed at 1–3 mm thickness and transferred to a picture archiving and communicating system (PACS) workstation (Syngo; Siemens Medical Systems, Forchheim, Germany).

Image Analysis

All multi-detector CT scans were read independently by 2 radiologists who were experienced with the PACS; they focused on the thoracic cage, the pulmonary parenchyma and pleura and other thoracic injuries. Surface Shaded Display was obtained to support the diagnoses made based on axial source images. Discrepancies between the radiologists' interpretations were resolved by consensus.

The anatomic location of a rib fracture along the rib was described as posterior, lateral, or anterior. For the diagnosis of pulmonary contusions, we excluded patients with fever, in whom infection was suspected by clinicians, and patients with acute renal failure that was due to crush syndrome. Patients who underwent multi-detector CT 14 days after the thoracic trauma were also excluded from the diagnosis of pulmonary contusion.

The presence of pleural conditions (hemothorax, pneumothorax, and hemo-pneumothorax), mediastinum, diaphragmatic or aortic injuries and soft tissue changes of the chest wall were reviewed. An intrathoracic hemorrhage detected in the hemothorax or the hemo-pneumothorax was described as small, moderate or large. The extent of the pneumothorax or hemo-pneumothorax was determined according to the degree of pulmonary collapse and was described as small, moderate or large when the degree of collapse was less than one-third, one-third to one-half, or greater than one-half, respectively. Because of their close associations with the chest wall, clavicular and scapular injuries were also reviewed. When the relevant clinical materials were available, associated extrathoracic injuries, including craniocerebral injuries, extremity fracture, pelvic fracture, cervical or L3-5 vertebral fracture and celiac organ injuries, were also assessed.

Statistical Analysis

Data for each patient were entered into a Microsoft Excel (Microsoft Corporation) database. We performed the data analysis using a statistical software package (SPSS version 13.0 for Windows, SPSS, Chicago, Ill.). The differences between the exposed and unexposed cohorts were determined using a risk ratio (RR) and a U test for gender, distribution of rib fractures (categorized as unilateral and bilateral), severity of rib fractures (including 1 and 2 rib fractures, more than 3 rib fractures, and flail chest), non-rib fractures (including T1 through L2 vertebral body, sternal, clavicular and scapular fractures), pulmonary parenchymal injuries and pleural injuries. The χ^2 test was used to compare the incidence of rib fractures with that of non-rib fractures, that of pulmonary parenchymal injuries, or that of pleural injuries. Additionally, ages were compared using the Mann-Whitney Test. We accepted a two-tailed *p*-value of less than 0.05 as indicating a statistically significant difference.

RESULTS

The earthquake-related cohort included 103 (47.91%) female and 112 (52.09%) male patients, with an age range from 0.5 to 103 years (mean age, 53 years) including 40, 111, and 64 patients in the age groups of < 35, 35–64 and > 64 years, respectively. The mean time from injury to the multi-detector CT examination was 7 days, ranging from 1 hour to 25 days. The non-earthquake cohort included 52 (24.18%) female patients and 163 (75.82%) male patients, with an age range from 2 to 88 years (mean age, 39 years) including 85, 107, and 23 patients in the age groups of < 35, 35–64 and > 64 years, respectively. The mean time from injury to the

Table 1 - Conditions Observed in the Earthquake-related Thoracic Crush Traumas and Non-earthquake Traumas.

Injuries	Earthquake Cases (%)	Non-earthquake Cases (%)	Rate Ratio	P
Bone fractures	150 (69.8)	93 (43.3)	1.6	< 0.001
Rib	143 (66.5)	66 (30.7)	2.2	< 0.001
Non-rib fractures	85 (39.5)	60 (27.9)	1.4	< 0.01
Vertebral body	46 (21.4)	19 (8.8)	2.4	< 0.001
Sternum	12 (5.6)	5 (2.3)	2.4	< 0.05
Scapula	34 (15.8)	29 (13.5)	1.2	NS
Clavicle	22 (10.2)	22 (10.2)	1.0	NS
Pulmonary parenchymal	117 (54.4)	80 (37.2)	1.5	< 0.001
Contusion	113 (52.6)	75 (34.9)		
Laceration	7 (3.3)	9 (4.2)		
Pleura	146 (67.9)	74 (34.4)	2.0	< 0.001
Pneumothorax	8 (3.7)	5 (2.3)		
Hemothorax	92 (42.8)	44 (20.5)		
Hemo-pneumothorax	46 (21.4)	25 (11.6)		
Soft tissue of chest wall				
Muscular swelling and fatty edema	187 (87.0)	174 (80.9)		
Subcutaneous emphysema	39 (18.1)	31 (14.4)		
Others				
Pneumomediastinum	12 (5.6)	12 (5.6)		
Aortic dissection aneurism	1 (0.5)	1 (0.5)		
Hemopericardium	0 (0)	2 (0.9)		
Diaphragmatic hernia	1 (0.5)	1 (0.5)		

multi-detector CT examination was 10 hours, ranging from 0.5 hour to 26 days. Male patients were statistically more common in the non-earthquake cohort (RR=1.5; U=5.14, and $p < 0.001$). Additionally, we found that younger patients presented more commonly in the non-earthquake cohort ($Z = -5.926, p < 0.001$).

Causes and anatomical distribution of thoracic traumas

For the non-earthquake cohort, the causes of injury included motor vehicle accidents (111 patients), falls (53 patients), assault (29 patients), crush injuries (11 patients), and blast or gunshot wounds (5 patients). Bone fractures, pulmonary parenchymal injuries, pleural injuries and soft tissue changes that were detected in the earthquake-related and non-earthquake cohorts are listed in table 1. Types of non-thoracic damage, when a description was available, are listed in table 2. Extremity and pelvic fractures were more frequently found in the earthquake-related cohort, but craniocerebral injuries were more frequently found in the non-earthquake cohort. In the earthquake-related cohort, 14 (6.5%) of the 215 patients were dead by December 20, 2008. For the non-earthquake cohort, 3 (1.4%) patients were dead by December 2, 2009.

Thoracic cage injuries

The mean number of rib fractures per patient was 6 and 5 for the earthquake-related cohort and the non-earthquake cohort, respectively (Fig. 1). Among patients with at least 1

rib fracture, more than 3 rib fractures were frequently seen in the earthquake-related cohort (Fig. 1) (RR = 1.2; U = 1.77, and $p < 0.05$). The 288 cases of multiple fractured ribs observed in the earthquake-related cohort contributed to 45 flail chests (31.5% of 143 patients) (Fig. 2), whereas in the non-earthquake cohort, the 97 cases of multiple fractured ribs contributed to 11 flail chests (16.7% of 66 patients). The incidence of flail chest was higher in the earthquake-related cohort (RR = 1.9; U = 2.24, and $p < 0.05$). Moreover, we found earthquake-related crush injuries to more frequently result in bilateral rib fractures (66/143 in the earthquake-related cohort vs. 18/66 in the non-earthquake cohort; 46.15% vs. 27.27%; RR = 1.7; U = 2.61, and $p < 0.01$). The most common rib fractures were distributed from the third through the seventh rib, and the vast majority were located in posterior and lateral locations (Table 3). However, the incidences of 1 and 2 rib fractures were similar in the two cohorts (70/143 vs. 33/66 patients).

Overall, the incidence of non-rib fractures was higher in the earthquake-related cohort than in the non-earthquake cohort, and, as shown in table 1, vertebral body fractures (T1 through L2) and sternal fractures were more frequently observed in the earthquake-related cohort. However, in patients with thoracic vertebral body fractures, no significant difference in the incidence of upper thoracic vertebral fractures (T1 through T10) was found between the two cohorts (36/57 vs. 13/25 63.16% vs. 52.0%; RR = 1.2; U = 1.54, and $p = 0.06$). In the earthquake-related cohort, 79 of the 85 patients had coexisting rib fractures. Similarly, 33 of

Table 2 - Coexisting Non-thoracic Damages in the Earthquake-related and Non-earthquake Cohorts.

	Earthquake Cases (%)	Non-earthquake Cases (%)	Rate Ratio	P
Extremity fracture	24 (11.2)	6 (2.8)	4.0	< 0.001
Pelvic fracture	14 (6.5)	5 (2.3)	2.8	< 0.05
C1-7 or L3-5 vertebral fracture	8 (3.7)	7 (3.3)		
Celiac organ injuries	6 (2.8)	5 (2.3)		
Craniocerebral injuries	3 (1.4)	85 (39.5)	0.04	< 0.001
Multiple system organ injuries	21 (9.8)	29 (13.5)		
Total	76 (35.3)	137 (63.7)		

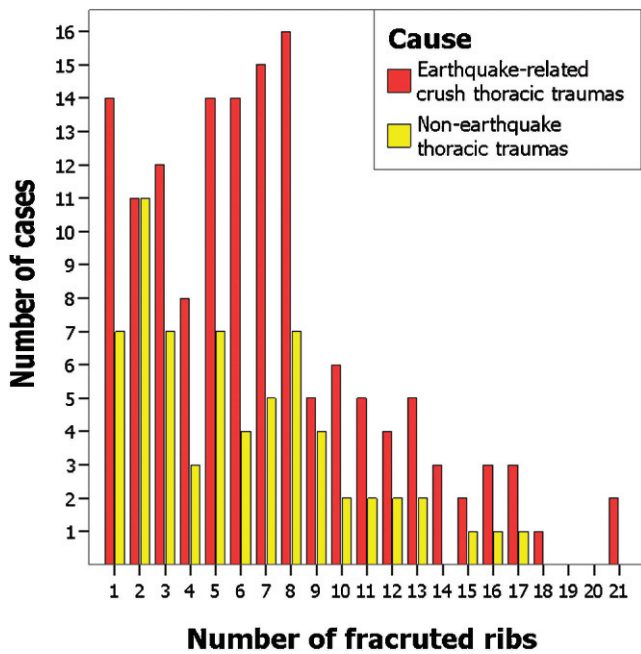


Figure 1 - The cluster bar shows the number of fractured ribs per patient. The mean number of fractures was 6 and 5 for earthquake-related and non-earthquake cohorts, respectively. Of these, 74.1% and 62.1% had more than 3 fractures in earthquake-related and non-earthquake cohorts, respectively.

60 patients had coexisting rib fractures in the non-earthquake cohort. Non-rib fractures had a significant positive correlation with rib fractures in these two cohorts ($P < 0.001$; OR, 13.58; 95% CI, 5.53–33.34 for the exposed cohort; and OR, 4.52; 95% CI, 2.39–8.55 for the unexposed cohort).

Pulmonary parenchymal injuries

Pulmonary parenchymal injuries (Fig. 2) were more frequently observed among those with earthquake-related crush injuries (Table 1). Among the earthquake-related cohort, 100 (85.5%) of the 117 patients with pulmonary parenchymal injuries had coexisting rib fractures. Similarly,

41 (51.3%) of the 80 patients had coexisting rib fractures in the non-earthquake cohort. Pulmonary parenchymal injuries have a significant positive correlation with rib fractures ($P < 0.001$; OR, 7.52; 95% CI, 3.93–14.42 for the exposed cohort; and OR, 4.62; 95% CI, 2.49–8.56 for the unexposed cohort).

Pleural injuries

Pleural injuries (Fig. 2) were more frequently observed among those with earthquake-related crush injuries (Table 1). Among the earthquake-related and non-earthquake cohorts, 123 (84.2% of the 146 patients) and 47 (63.5% of the 74 patients) of these patients had coexisting rib fractures ($P < 0.001$; OR, 13.10; 95% CI, 6.61–25.98 for the exposed cohort; and OR, 11.18; 95% CI, 5.68–21.99 for the unexposed cohort), respectively. The incidence of a moderate or large amount of intrathoracic hemorrhage was higher in the earthquake-related cohort than in the non-earthquake cohort (72/146 vs. 20/74 patients; RR = 1.8; U = 3.17, and $p < 0.001$). Similarly, the incidence of a moderate or large amount of intrathoracic gas was much higher in the earthquake-related cohort than in the non-earthquake cohort (22/146 vs. 4/74 patients; RR = 2.8; U = 2.11, and $p < 0.05$). Among the earthquake-related cohort, all 12 patients with pneumomediastinum had coexisting pleural injuries. Among the non-earthquake cohort, the “Macklin effect” was detected in 3 of the 12 patients with pneumomediastinum, and 5 patients had coexisting pleural injuries.

Soft tissue injuries of the chest wall

Among the earthquake-related cohort, all 18 patients with subcutaneous air collections had coexisting pleural injuries. Among the non-earthquake cohort, 22 of the 31 patients with subcutaneous air collections had coexisting pleural injuries.

DISCUSSION

Thoracic traumas are common both in traumas associated with earthquakes and in other major blunt traumas.¹⁻⁷ In the event of a disaster, if measures, such as the construction of

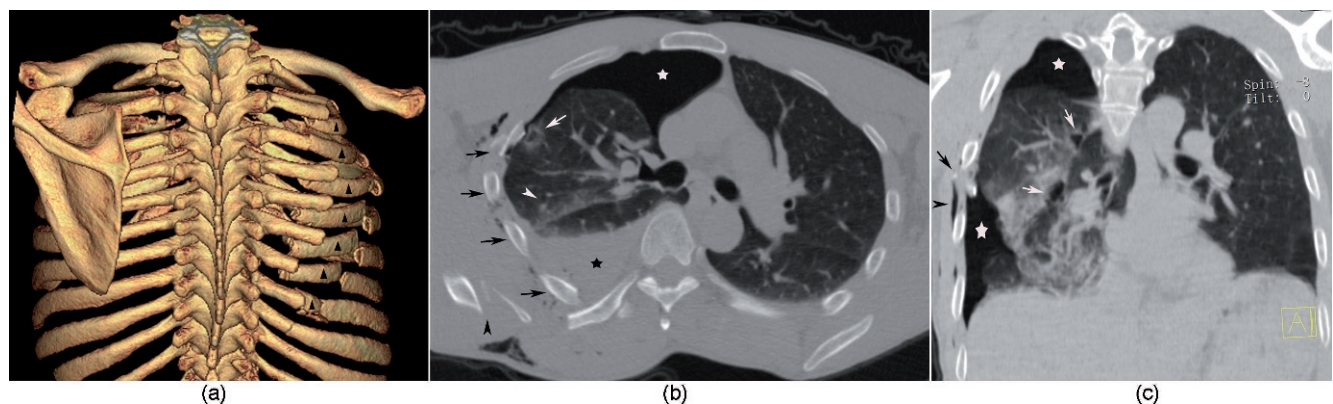


Figure 2 - Flail chest in a 46-year-old man. (2A) The surface-shaded display shows thoracic cage asymmetry caused by right-side rib 2–8 fractures at multiple sites causing flail chest (▲), and fractures of right-side ninth rib of posterior location. (2B) The axial CT scan shows a right-side hemothorax (★), pneumothorax (☆), and pulmonary parenchymal injuries, including contusion (write arrowhead) and laceration (write arrow), thoracic cage asymmetry caused by right-side rib fractures (black arrows), and a right scapular fracture (black arrowhead). Right-side subcutaneous air collection is also depicted. (2C) The coronal multi-planar reconstruction shows a right-side pneumothorax (☆), a pulmonary parenchymal laceration (write arrows) and a contusion, right-side rib fractures (black arrow), and right-side subcutaneous air collection (black arrowhead).

Table 3 - Anatomic Distribution of Rib Fractures in Earthquake-related Thoracic Crush Traumas vs. Non-earthquake Traumas (ribs).

Rib number	Right thorax (Earthquake/Non-earthquake)				Left thorax (Earthquake/Non-earthquake)			
	Ant	Lat	Post	Total	Post	Lat	Ant	Total
First	7/1	4/3	13/15	24/19	10/6	5/0	4/1	19/7
Second	25/7	10/6	14/9	49/22	15/10	16/4	19/7	50/21
Third	29/7	33/15	17/8	79/30	24/10	30/14	27/6	81/30
Fourth	38/6	37/16	11/7	86/29	29/15	36/16	34/6	99/37
Fifth	27/7	47/14	15/8	89/29	29/12	41/17	26/4	96/33
Sixth	23/4	36/13	16/13	75/30	31/12	32/15	23/3	86/30
Seventh	12/2	34/9	20/12	66/23	28/11	25/12	18/1	61/24
Eighth	3/1	27/6	28/11	58/18	23/10	17/6	6/2	46/18
Ninth	3/1	12/4	30/15	45/20	21/12	10/6	0/0	31/18
Tenth	0/0	2/1	27/12	29/13	18/12	3/0	0/0	21/12
Eleventh	0/0	0/0	22/9	22/9	12/5	0/0	0/0	12/5
Twelfth	0/0	0/0	8/1	8/1	6/2	0/0	0/0	6/2
Total	167/36	242/87	221/120		246/117	215/90	157/30	

Ant: anterior; lat: lateral; post: posterior.

high-quality buildings and affixing furniture to the walls have not been taken, the incidence of disaster-related crush injuries often remains high.⁸ In the 2008 Sichuan earthquake, the main cause of thoracic trauma was crush injury. However, non-earthquake thoracic traumas rarely occur as a result of crush injury.^{9,12} To better evaluate the difference between thoracic crush traumas resulting from earthquakes versus thoracic traumas from other common injuries, we performed this cohort study and chose a non-earthquake cohort from a similar time of the year to avoid the confounding effect of seasonal activity and clothing.

Our data shows that younger male patients were more commonly involved in non-earthquake-related thoracic traumas, consistent with previous data. It is likely that this difference between the cohort populations exists because motor vehicle accidents, falls, and assault injuries are the main causes of non-earthquake thoracic traumas, and drivers who are injured in motor vehicle collisions tend to be younger males. Furthermore, the majority of work-related falls from elevated heights and assaults during a conflict occur in young males, which is consistent with previous data from studies in China. In an earthquake, however, agile young males would be more likely to escape danger and avoid thoracic trauma.

Rib fracture is a main type of both earthquake-related thoracic trauma and general or non-specified thoracic trauma.^{1-3,9,12} The number of fractured ribs is a good indicator of the severity of the injury, and the presence of more than 3 rib fractures is associated with the greatest degree of prognostic difference, with a total mortality that ranges from 5.7%–10%.^{6,9} As one of the most severe types of rib fractures, flail chest is life-threatening, with mortality ranging from 10% to 20%.^{13,14} In our study, earthquake-related rib fractures occurred in a significantly higher incidence when compared to common thoracic traumas, with an RR of 2.2. Among patients with rib fractures, the incidence of more than 3 rib fractures and flail chest was much higher in the earthquake-related patients compared to non-earthquake thoracic traumas. These findings reveal that earthquake-related thoracic crush traumas were more severe than common thoracic traumas. Furthermore, bilateral rib fractures were more frequently associated with the earthquake-related cohort. We hypothesize that the force of objects falling on victims who were trapped in prone

postures might cause persistent bilateral compressions and result in severe injuries to the curved thoracic cage. This is strikingly different from the kinetic energy of motor vehicle accidents, falls, assaults (especially stabbings), and blast or gunshot wounds, which often exert force to a comparatively local site of the thorax.

Of non-rib fractures, thoracic spinal, scapular and clavicular fractures are the result of a large force or high-energy injury, and the incidence of these injuries were low.^{12,15,16} In this study, the higher incidence of non-rib fractures, vertebral body and sternal fractures detected in the earthquake-related cohort could be evidence of the severity of earthquake-related thoracic crush traumas. These fractures reveal that the crush energy exerted on the thorax in an earthquake may be more severe than in other common thoracic traumas.

Although fractures in T1–T10 comprised 63.16% of the earthquake-related thoracic spine fractures in this study, and this incidence was much higher than previously reported,¹⁷ there was no significant difference in the incidence of these fractures between these two cohorts. Thus, we hypothesize that the higher incidence of these fractures was, at least in part, the result of the high sensitivity of the multi-detector CT in detecting this type of injury.¹⁸

Although studies about earthquake-related thoracic trauma report a very low incidence of pulmonary contusion,^{1,2} the incidence of pulmonary parenchymal injuries in the earthquake cohort of our study was much higher than that in the non-earthquake cohort. Excluding mechanisms, such as direct compression, counter-coup compression, shearing forces, or laceration by fractured ribs that commonly contribute common blunt traumas,¹⁹ we speculate that the heavy and persistent crush energy experienced in earthquakes could cause persistent high tonicity of the lung, which then could cause severe injury of the alveoli and hemorrhage of the interstitium and result in severe pulmonary contusion. Furthermore, the poor conditions including bad environment status and persistent stress following an earthquake coupled with insufficient rescue efforts might seriously affect the healing of lung contusions.

It was previously reported that the number of rib fractures is significantly related to the presence of pleural injuries.¹⁴ Our results show that pleural injuries had a

significant positive correlation with rib fractures in these two cohorts, consistent with the report by Sirmali et al.⁹ and, as mentioned above, the rib fractures in the earthquake-related cohort were severe. Thus, this positive correlation could explain the higher incidence of pleural injuries, especially moderate or large amounts of intrathoracic hemorrhage or gas, that was detected in the earthquake-related cohort compared to those in the non-earthquake cohort; i.e., these injuries may be the result of the direct laceration of the parietal pleura by splintered ribs.

Earthquake-related rupture of the cardiovascular system is life threatening¹ and can be accurately assessed with multi-detector CT angiography.^{20,21} Although our data show that crush thoracic traumas resulting from the massive earthquake in Sichuan, China, were much more severe than other common thoracic traumas, we observed a low incidence in the diagnosis of aortic dissection, as well as that in the hemopericardium. This may be the result of the delay in transfer to the hospital because the disaster zones of this earthquake were mainly mountainous areas with severe road destruction. Furthermore, some of the hospitals in the disaster zone were severely damaged, with severe casualties among the staff, contributing to the insufficiency of rescue efforts. Thus, victims who suffered from these severe types of injuries were unlikely to survive the disaster.

Study Limitations

First, as was observed in our cohort, the mean time from injury to the MDCT examination was 7 days, and because the victims that developed fatal injuries did not survive the disaster before they were rescued, some deadly injuries, such as aortic injuries and hemopericardium, were detected at a very low incidence. This limitation is also revealed by the incidence of coexisting non-thoracic damages: the incidence of craniocerebral injuries was much lower in the earthquake-related cohort. Second, as a retrospective study, trauma scores were not obtained for these patients, and this may have caused the evaluation of the victims to be insufficient.

CONCLUSIONS

This initial cohort study demonstrated that crush thoracic trauma resulting from an earthquake was life threatening, with a high incidence of bony thoracic fractures. The rib was more frequently involved in bilateral and severe types of fractures and was accompanied by non-rib fractures and pulmonary parenchymal and pleural injuries, which may have been the result of the particular mechanism of this type of injury. The noticeable features of these life-threatening injuries that require appropriate medical treatment include the high incidences of flail chest, T1 through L2 vertebral body fractures, lung contusion and a moderate or large amount of hemo/pneumothorax, as compared with other common thoracic traumas.

ACKNOWLEDGMENTS

This article is supported by the National Nature Sciences Foundation of China: No. 30970820; No. 30870688.

This article is also supported by the Science Foundation for Distinguished Young Scholars of Sichuan Province (Grant No. 2010JQ0039).

Authors' Contributions: Zhi-hui Dong, Zhi-gang Yang, and Tian-wu Chen contributed to the project and the production of the article. Zhi-gang Chu, Wen Deng, and Heng Shao contributed to the production of the article.

REFERENCES

1. Yoshimura N, Nakayama S, Nakagiri K, Azami T, Ataka K, Ishii N. Profile of Chest Injuries Arising From the 1995 Southern Hyogo Prefecture Earthquake. *Chest*. 1996;110:759-61, doi: 10.1378/chest.110.3.759.
2. Ozdogan S, Hocaoglu A, Caglayan B, Imamoglu OU, Aydin D. Thorax and Lung Injuries Arising From the Two Earthquakes in Turkey in 1999. *Chest*. 2001;120:1163-6, doi: 10.1378/chest.120.4.1163.
3. Ghodsi SM, Zargar M, Khaji A, Karbakhsh M. Chest injury in victims of Bam earthquake. *Chin J Traumatol*. 2006;9:345-8.
4. Ziegler DW, Agarwal NN. The morbidity and mortality of rib fractures. *J Trauma*. 1994;37:975-9.
5. Balci AE, Kazez A, Eren S, Ayan E, Ozalp K, Eren MN. Blunt thoracic trauma in children: review of 137 cases. *Eur. J. Cardiothorac Surg*. 2004;26:387-92, doi: 10.1016/j.ejcts.2004.04.024.
6. Freixinet J, Beltran J, Rodriguez PM, Juliab G, Husseina M, Gila R, et al. Indicators of Severity in Chest Trauma. *Arch Bronconeumol* 2008;44:257-62.
7. Virgos Senor B, Nebra Puertas AC, Sanchez Polo C, Broto Civera A, Suarez Pinilla MA. Predictors of outcome in blunt chest trauma. *Arch Bronconeumol*. 2004;40:489-94.
8. Sever MS, Vanholder R, Lameire N. Management of Crush-Related Injuries after Disasters. *N Engl J Med*. 2006 354:1052-63.
9. Sirmali M, Turut H, Topcu S, Gulhan E, Yazc U, Kaya S, et al. A comprehensive analysis of traumatic rib fractures: morbidity, mortality and management. *Eur. J. Cardiothorac. Surg*. 2003;24:133-8, doi: 10.1016/S1010-7940(03)00256-2.
10. Livingston DH, Shogan B, John P, Lavery RF. CT diagnosis of Rib fractures and the prediction of acute respiratory failure. *J Trauma*. 2008;64:905-11.
11. Zhi-hui Dong, Zhi-gang Yang, Tian-wu Chen, Yuan-chun Feng, Zhi-gang Chu, Jian-qun Yu, et al. Crush Thoracic Trauma in the Massive Sichuan Earthquake: evaluation with Multi-detector CT of 223 cases. *Radiology*. 2010; 254:285-91, doi: 10.1148/radiol.09090685.
12. Demirhan R, Onan B, Oz K, Halezeroglu S. Comprehensive analysis of 4205 patients with chest trauma: a 10-year experience. *Interactive CardioVascular and Thoracic Surgery*. 2009; 450-3, doi: 10.1510/icvts.2009.206599.
13. Bastos R, Calhoun JH, Baisden CE. Flail chest and pulmonary contusion. *Semin Thorac Cardiovasc Surg*. 2008;20:39-45, doi: 10.1053/j.semtcvs.2008.01.004.
14. Liman ST, Kuzucu A, Tastepe AI, Ulasan GN, Topcu S. Chest injury due to blunt trauma. *Eur J Cardiothorac Surg* 2003;23:374-8, doi: 10.1016/s1010-7940(02)00813-8.
15. Lomoschitz FM, Eisenhuber E, Linnau KF, Peloschek P, Schoder M, Bankier AA. Imaging of chest trauma: radiological patterns of injury and diagnostic algorithms. *Eur J Radiol*. 2003;48:61-70.
16. Vialle LR, Vialle E. Thoracic spine fractures. *Injury*. 2005;36(Suppl 2):P65-72, doi: 10.1016/j.injury.2005.06.016.
17. Meyer PR. Fractures of the thoracic spine: T1 to T10. In: Merer PR, ed. *surgery of spine trauma*. New York: Churchill Livingstone. 2007:527-71.
18. Wintermark M, Mouhsine E, Theumann N, Mordasini P, van Melle G, Leyvraz PF, et al. Thoracolumbar spine fractures in patients who have sustained severe trauma: depiction with multi-detector row CT. *Radiology*. 2003;227:681-9, doi: 10.1148/radiol.2273020592.
19. Wagner RB, Crawford WO, Schimpf PP. Classification of parenchymal injuries of the lung. *Radiology*. 1988;167:77-82.
20. Alkadhi H, Wildermuth S, Desbiolles L, Schertler T, Crook D, Marincek B, et al. Vascular Emergencies of the Thorax after Blunt and Iatrogenic Trauma: Multi-Detector Row CT and Three-dimensional Imaging. *RadioGraphics*. 2004;24:1239-55, doi: 10.1148/rg.245035728.
21. Steenburg SD, Ravenel JG. Multi-detector computed tomography findings of atypical blunt traumatic aortic injuries: a pictorial review. *Emerg Radiol*. 2007;14:143-50, doi: 10.1007/s10140-007-0620-2.