

LUMBAR ENDOSCOPIC PERCUTANEOUS DISCECTOMY – CLINICAL OUTCOME. PROSPECTIVE STUDY

DISCECTOMIA LOMBAR ENDOSCÓPICA PERCUTÂNEA – DESFECHO CLÍNICO. ESTUDO PROSPECTIVO

DISCECTOMÍA LUMBAR ENDOSCÓPICA PERCUTÁNEA – RESULTADO CLÍNICO. ESTUDIO PROSPECTIVO

ANDRÉ LUÍS SEBBEN¹, XAVIER SOLER I GRAELLS¹, MARCEL LUIZ BENATO², PEDRO GREIN DEL SANTORO², ÁLYNSON LAROCCA KULCHESKI²

1. Universidade Federal do Paraná, Hospital de Clínicas, Curitiba, PR, Brazil.

2. Hospital do Trabalhador, Orthopedics Service, Curitiba, PR, Brazil.

ABSTRACT

Objective: Lumbar disc herniation is a common indication for surgical treatment of the spine. Open microdiscectomy is the gold standard. New surgical techniques have emerged, such as spinal endoscopy. We compared and evaluated two endoscopic techniques: the transforaminal and the interlaminar. **Methods:** Fifty-five patients underwent endoscopic technique and were assessed by VAS and ODI in the preoperative period, and in the first and sixth month after the procedure. **Results:** We had 89.1% of good results and 10.9% of complications. **Conclusion:** We conclude that endoscopic techniques are safe and effective for the surgical treatment of lumbar disc herniation.

Keywords: Spine; Intervertebral disc displacement; Endoscopy.

RESUMO

Objetivo: A hérnia discal lombar é uma indicação comum de tratamento cirúrgico da coluna vertebral. A microdiscectomia aberta é o padrão de referência. Novas técnicas cirúrgicas têm surgido, como a endoscopia de coluna vertebral. Comparamos e avaliamos duas técnicas endoscópicas: a transforaminal e a interlaminar. **Métodos:** Cinquenta e cinco pacientes foram submetidos à técnica endoscópica, e foram avaliados por EVA e ODI no pré-operatório, no primeiro e no sexto mês após o procedimento. **Resultados:** Tivemos 89,1% de bons resultados e 10,9% de complicações. **Conclusão:** Concluímos que as técnicas endoscópicas são seguras e eficazes para o tratamento cirúrgico da hérnia discal lombar.

Descritores: Coluna vertebral; Deslocamento do disco intervertebral; Endoscopia.

RESUMEN

Objetivo: La hernia de disco lumbar es una indicación común para el tratamiento quirúrgico de la columna vertebral. La microdiscectomía abierta es el estándar de referencia. Las nuevas técnicas quirúrgicas se han desenvuelto en la columna vertebral, como la endoscópica. Comparamos y evaluamos dos técnicas endoscópicas: transforaminal e interlaminar. **Métodos:** Cincuenta y cinco pacientes fueron sometidos al procedimiento endoscópico, y se evaluaron mediante EVA y ODI en el pre-operatorio, en el primero y sexto mes después del procedimiento. **Resultados:** Hemos tenido un 89,1% de buenos resultados y el 10,9% de complicaciones. **Conclusión:** Las técnicas endoscópicas son seguras y eficaces para el tratamiento quirúrgico de hernia de disco lumbar.

Descritores: Columna vertebral; Desplazamiento del disco intervertebral; Endoscopia.

INTRODUCTION

Sciatica is one of the most frequent and incapacitating complaints in the daily life of the spine surgeon. Mixer described in detail the etiology of sciatica and its correlation with herniation of the lumbar discs.¹ The surgical treatment of this disease has varied over time. With the popularization of minimally invasive spine surgery, the percutaneous endoscopic lumbar discectomy has become an increasingly present option for the treatment of disc herniation.

Less invasive techniques evolved with the passage of time, demonstrating progressive success.²⁻⁶ This made the emergence of endoscopic transforaminal surgery for the treatment of lumbar disc herniation possible, which was followed by the development of many types of equipment and the improvement of the surgical technique.⁷⁻¹⁰

Choi et al.,¹¹ in 2006, reported the interlaminar approach between L5-S1 for intracanal disc herniation. The following year, a technique

called directed extraforaminal fragmentectomy was introduced with a success rate of 92%.¹²

Literature data shows that spine surgery performed using the endoscopic technique is a safe method and it has been gradually more indicated.¹³

The objective of this study was to evaluate the clinical outcome of patients treated surgically for lumbar disc herniation using the percutaneous endoscopic lumbar discectomy technique.

METHODS

This longitudinal, observational, and prospective study was approved by the Institutional Review Board of the Hospital do Trabalhador as number CAEE 746315.3.0000.5225. The participants signed an informed consent form following an explanation of the study conducted by the authors.

We selected 55 patients who had undergone surgical treatment for lumbar disc herniation at the Hospital do Trabalhador - UFPR using the percutaneous endoscopic transforaminal or interlaminar lumbar discectomy surgical technique. The clinical evaluation of the patients was conducted via the application of the Oswestry 2.0 questionnaire and the visual analog scale (VAS) for pain at the following time points: the day before the surgical procedure, the first day following the surgery, and six months following the surgery. They were evaluated using a combination of epidemiological data, such as sex and age. Postoperative complications data, such as infections of the surgical site, neurological changes (paresis, paresthesia), nerve lesions, iatrogenic durotomy with or without a CSF fistula, and recurrence of disc herniation. The clinical endpoints for male and female patients were compared separately in search of statistically significant differences between the sexes.

Patients who had undergone surgical treatment for lumbar disc herniation using the open surgical technique, those who were older than 80 or younger than 18 years of age, and those who did not elect to participate in the research project were excluded.

The device used for the procedures was the Richard Wolf Vertebris® endoscope.

Two different endoscopic surgical techniques were used: transforaminal and interlaminar. The patients with central and central-lateral disc herniation were submitted to the interlaminar technique, while on the other hand, those with foraminal and extraforaminal herniation were submitted to the transforaminal technique. The procedures were performed by four different surgeons from the Spine Group of the Hospital do Trabalhador, all of whom had the same training and previous experience in performing the endoscopic surgical technique.

The study was conducted from December 2014 to November 2015, totaling a year of endoscopic surgical procedures, with 6 months of postoperative follow-up.

Data analysis was done using R (R Core Team, 2015), version 3.2.3 software. A multivariate analysis conducted with a regression model for longitudinal data was the statistical method used. A level of significance of 5% was adopted, considering it significant when the p-value was < 0.05.

RESULTS

Fifty-five patients were included in the study. All were submitted to surgical treatment for lumbar disc herniation using the endoscopic lumbar technique. Of these patients, 24 (43.7%) underwent the transforaminal technique and 31 (56.3%) the interlaminar technique. Twenty-six (47.2%) patients were male and 29 (52.8%) were female. The age of the patients ranged from 21 to 79 years, the average age being 40.2 years. Most of the patients (78.1%) were treated surgically at only one disc level (n=43), the most operated level being L4-L5 with 20 cases (36.3%), followed by L5-S1 with 19 cases (34.5%), and L3-L4 with 4 cases (7.2%). Twelve patients underwent surgeries at two disc levels, 10 of them at levels L4-L5-S1 and two at levels L3-L4-L5 (Table 1).

The average preoperative Oswestry score was 26.6. On the first day following the procedure, it dropped to 5.5 and 6 months following the procedure, it was 5.3. The Visual Analog Scale for pain score averaged 8.4 in the preoperative period, 2.3 the first day following the surgery, and 1.9 after six months (Figures 1 and 2). Both were statistically significant with p < 0.0001. There was no statistical difference between the sexes when a p-value < 0.05 was used (Figures 3 and 4).

There was a 10.9% incidence of complications in general. The complications evaluated were neurological change, infection of the surgical site, durotomy with or without CSF fistula, and recurrence of the disc herniation. None of the patients had an infection of the surgical site. Two durotomies occurred during the procedures (3.6%), one asymptomatic without clinical repercussions and the other with a CSF fistula associated with postural headache, which was resolved spontaneously 48 hours of rest and did

Table 1. Levels operated and number of patients.

Levels operated	Number of patients and percentage
L5S1	19 (34.5%)
L4L5	20 (36.3%)
L3L4	4 (7.2%)
L4L5S1	10 (18.1%)
L3L4L5	2 (3.6%)

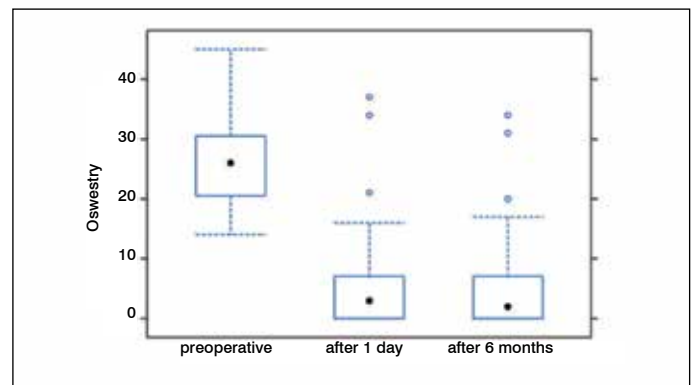


Figure 1. Relationship between the Oswestry Disability Index in the preoperative period, the first day following the procedure, and after 6 months.

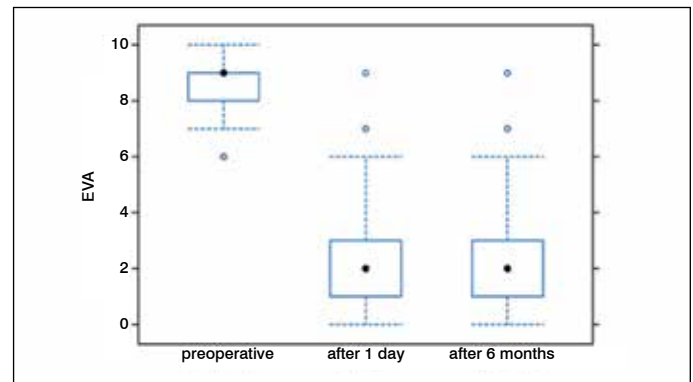


Figure 2. Relationship between the Visual Analog Scale (VAS) for pain in the preoperative period, the first day following the procedure, and after 6 months.

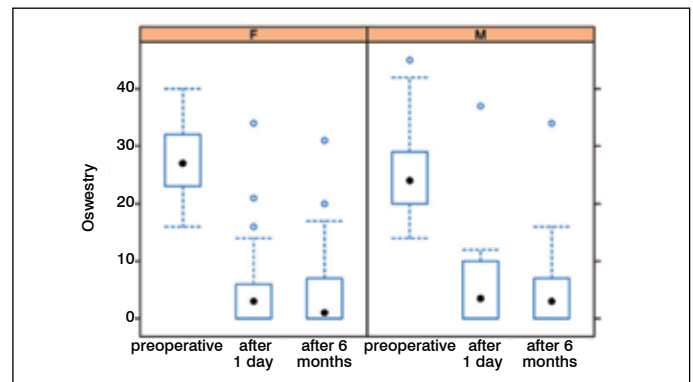


Figure 3. Division between male and female patients and the relationship between the ODI scores.

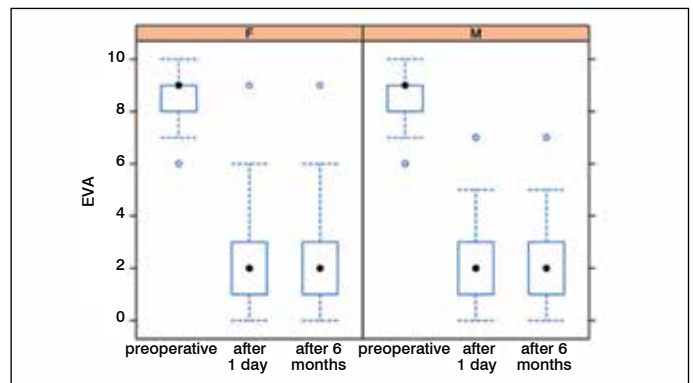


Figure 4. Division between the male and female patients and the relationship between the VAS scores.

not require surgical reintervention. There were no cases of complete neural lesion, but three patients had paresthesia of the lower limbs (5.4%). Only 2 patients underwent surgical reintervention for any of these complications, representing 3.6% of the cases. One of them was reoperated for recurrence of the disc herniation and the other, due to a technical difficulty, for the removal of the entire disc herniation, which proved to be calcified.

DISCUSSION

Open microdiscectomy is the gold standard for the surgical treatment of lumbar disc herniation.¹⁴ New options for surgical treatment have emerged with good results, as is the case with endoscopic treatment of lumbar disc herniations.¹⁵

In this study, the patients were evaluated prior to surgery, on the first day following the procedure, and after 6 months. The ODI and the VAS scores were available and showed that the patients had a statistically significant improvement ($p < 0.0001$) with endoscopic treatment of the lumbar disc herniation, with 89.1% of the patients responding well to the surgical treatment. This value was higher than the success rate of the gold standard, which varies between 70 and 84% of good outcomes according to the study by Dohrmann and Mansour,¹⁶ who analyzed 39,000 patients with lumbar disc herniation. The rate of complications was 10.9%, a value lower than that of the gold standard technique, which was 12.5% according to the study of Shriver et al.¹⁷ The incidence of durotomy in our study was similar to that reported in the literature for the gold standard, which is around 3.1%.¹⁸ It is worth noting that the patient who had the dural lesion with CSF fistula had already had prior open lumbar surgery with dural lesion and signs of pseudomenigocele revealed in the preoperative MRI.

The reoperation rate in the literature for open microdiscectomy is 18.5%, according to Soliman et al.¹⁹ Aichmair et al.²⁰ observed a higher rate, reaching 25%. Each of them reported a follow-up of at least 5 years. Our reoperation rate was only 3.6%, but the patient follow-up of only 6 months must be taken into account. One of the reoperations was required because of the persistence of a disc fragment that was causing nerve root compression and associated symptoms. This patient had a disc herniation that occupied more than 50% of the vertebral canal. The literature shows that these cases are the most difficult in terms of complete removal of the herniation via endoscopy.²¹

Complications are very important factors for evaluating the safety of a surgical procedure. Recently published meta-analysis comparing the clinical endpoints of open microdiscectomy and endoscopic microdiscectomy showed that the complication rate was similar between the two groups, suggesting that the minimally invasive procedure is safe for the surgical treatment of lumbar disc herniation.²²

The surgical procedure from the endoscopic approach has advantages over the traditional open approach. The patient who undergoes a minimally invasive procedure has fewer complaints of postoperative pain, a shorter hospitalization time, a less extensive surgical scar, an earlier rehabilitation and return to work, and a lower complication rate than the traditional method.^{23,24}

It should be taken into account that the endoscopic surgical technique presents greater technical difficulties than the traditional technique and, consequently, a greater learning curve. Among the techniques, the transforaminal is the most accessible at the beginning stages of learning the endoscopic procedures.²⁵ Initial training in the minimally invasive endoscopic techniques is practiced on cadavers and, later, in patients, always supervised and with all the safeguards necessary for the execution of the procedure.

The six-month postoperative follow-up in this study should be considered to be a limitation. However, we know that the main postoperative complications occur during this period. Another limiting factor of this technique is its high cost, making its expansion difficult in the medical environment and increasing healthcare costs. This must be rethought so that the best surgical technique and technology can be made available to the greatest number of patients. Our patients were operated on at a public hospital in which endoscopy devices enters into the bidding process for spinal surgery materials.

CONCLUSION

Spinal endoscopy for the treatment of lumbar disc herniation has approximately 90% good results. New studies with greater numbers of patients and longer follow-ups are necessary. Because of the advantages it offers, endoscopy of the spine has a promising future.

All authors declare no potential conflict of interest related to this article.

CONTRIBUTION OF THE AUTHORS: Each author made significant individual contributions to this manuscript. ALS: conception of the idea, writing of the article, review of the literature, and interviewing the patients; ALK: data analysis and writing of the article; MLB: statistical analysis, review of the article; PGS: processing and compilation of the data and literature review; XSG: review and intellectual concept of the article, final approval of the version of the article submitted.

REFERENCES

- Mixer WJ. Rupture of the intervertebral disk; a short history of this evolution as a syndrome of importance to the surgeon. *J Am Med Assoc.* 1949;140(3):278-82.
- Hijkata S, Nakayama T, Omori K, Yamagishi M. Percutaneous nucleotomy: a new treatment method for lumbar disc herniation. *J Toden Hosp.* 1975;5(1):5-13.
- Kambin P, Gellman H. Percutaneous lateral discectomy of the lumbar spine. A preliminary report. *ClinOrthop.* 1983;(174):150-67.
- Schreiber A, Suezawa Y. Transdiscoscopic percutaneous nucleotomy in disk herniation. *Orthop Rev.* 1986;15(1):35-8.
- Kambin P, Casey K, O'Brien E, Zhou L. Transforaminal arthroscopic decompression of lateral recess stenosis. *J Neurosurg.* 1996;84(3):462-7.
- Mathews RS. APLD: A prospective study in an out-patient surgical setting. *J NeurolOrthop Med Surg.* 1997;17:201-6.
- Yeung AT. Minimally Invasive Disc Surgery with the Yeung Endoscopic Spine System (YESS). *SurgTechnol Int.* 1999;8:267-77.
- Tsou PM, Alan Yeung C, Yeung AT. Posterolateraltransforaminal selective endoscopic discectomy and thermal annuloplasty for chronic lumbar discogenic pain: a minimal access visualized intradiscal surgical procedure. *Spine J.* 2004;4(5):564-73.
- Ruetten S, Komp M, Godolias G. An extreme lateral access for the surgery of lumbar disc herniations inside the spinal canal using the full-endoscopic uniportaltransforaminal approach-technique and prospective results of 463 patients. *Spine (Phila Pa 1976).* 2005;30(22):2570-8.
- Schubert M, Hoogland T. Endoscopic transforaminalnucleotomy with foraminoplasty for lumbar disk herniation. *OperOrthopTraumatol.* 2005;17(6):641-61.
- Choi G, Lee SH, Raiturker PP, Lee S, Chae YS. Percutaneous endoscopic interlaminar discectomy for intracanalicular disc herniations at L5-S1 using a rigid working channel endoscope. *Neurosurgery.* 2006;58(1 Suppl):ONS59-68; discussion ONS59-68.
- Choi G, Lee SH, Bhanot A, Raiturker PP, Chae YS. Percutaneous endoscopic discectomy for extraforaminal lumbar disc herniations: extraforaminal targeted fragmentectomy technique using working channel endoscope. *Spine (Phila Pa 1976).* 2007;32(2):E93-9.
- Nellensteijn J, Ostelo R, Bartels R, Peul W, van Royen B, van Tulder M. Transforaminal endoscopic surgery for symptomatic lumbar disc herniations: a systematic review of the literature. *Eur Spine J.* 2010;19(2):181-204.
- Apostolides PJ, Jacobowitz R, Sonntag VK. Lumbar discectomy microdiscectomy: "the gold standard". *ClinNeurosurg.* 1996;43:228-38.
- Postacchini F, Postacchini R. Operative management of lumbar disc herniation: the evolution of knowledge and surgical techniques in the last century. *ActaNeurochir Suppl.* 2011;108:17-21.
- Dohrmann GJ, Mansour N. Long-Term Results of Various Operations for Lumbar Disc Herniation: analysis of over 39,000 Patients. *Med PrincPract.* 2015;24(3):285-90.
- Shriver MF, Xie JJ, Tye EY, Rosenbaum BP, Kshetry VR, Benzel EC, et al. Lumbar microdiscectomy complication rates: a systematic review and meta-analysis. *Neurosurg Focus.* 2015;39(4):E6.
- Desai A, Ball PA, Bekelis K, Lurie JD, Mirza SK, Tosteson TD, et al. Outcomes after incidental durotomy during first-time lumbar discectomy. *J Neurosurg Spine.* 2011;14(5):647-53.
- Soliman J, Harvey A, Howes G, Seibly J, Dossey J, Nardone E. Limited microdiscectomy for lumbar disc herniation: a retrospective long-term outcome analysis. *J Spinal Disord Tech.* 2014;27(1):E8-E13.
- Aichmair A, Du JY, Shue J, Evangelisti G, Sama AA, Hughes AP, et al. Microdiscectomy for the treatment of lumbar disc herniation: an evaluation of reoperations and long-term outcomes. *Evid Based Spine Care J.* 2014;5(2):77-86.
- Lee SH, Kang BU, Ahn Y, Choi G, Choi YG, Ahn KU, et al. Operative failure of percutaneous endoscopic lumbar discectomy: a radiologic analysis of 55 cases. *Spine (Phila Pa 1976).* 2006;31(10):E285-90.
- He J, Xiao S, Wu Z, Yuan Z. Microendoscopic discectomy versus open discectomy for lumbar disc herniation: a meta-analysis. *Eur Spine J.* 2016;25(5):1373-81.
- Ruetten S, Komp M, Merk H, Godolias G. Full-endoscopic interlaminar and transforaminal lumbar discectomy versus conventional microsurgical technique: a prospective, randomized, controlled study. *Spine (Phila Pa 1976).* 2008;33(9):931-9.
- Ruetten S, Komp M, Merk H, Godolias G. Recurrent lumbar disc herniation after conventional discectomy: a prospective, randomized study comparing full-endoscopic interlaminar and transforaminal versus microsurgical revision. *J Spinal Disord Tech.* 2009;22(2):122-9.
- Hsu HT, Chang SJ, Yang SS, Chai CL. Learning curve of full-endoscopic lumbar discectomy. *Eur Spine J.* 2013;22(4):727-33.