

# PREVALENCE AND CHARACTERISTICS OF UPPER LUMBAR DISC HERNIATIONS IN OUR PRACTICE: A RETROSPECTIVE ANALYSIS

PREVALÊNCIA E CARACTERÍSTICAS DAS HÉRNIAS LOMBARES SUPERIORES EM NOSSO MEIO: ANÁLISE RETROSPECTIVA

PREVALENCIA Y CARACTERÍSTICAS DE LAS HERNIAS LUMBARES ALTAS EN NUESTRO MEDIO: ANALISIS RETROSPECTIVO

DITTMAR-JOHNSON HERMAN MICHAEL<sup>1</sup> , CRUZ-LÓPEZ FRANCISCO<sup>1</sup> , GONZÁLEZ-CAMACHO EDUARDO<sup>1</sup> , CHAVARRETI-GUTIÉRREZ OSCAR MIKHAIL<sup>1</sup> ,

TEJERA-MORETT ALEJANDRO<sup>1</sup> , SÁNCHEZ-GARCÍA FRANCISCO JAVIER<sup>1</sup> , DE HARO-ESTRADA JORGE<sup>1</sup> 

1. Reespalda A.C. Medical Group, Jalisco, Mexico.

## ABSTRACT

**Introduction:** Upper lumbar disc herniations (ULDH) are considered infrequent injuries (1-11%). They present, most often in older adults, with special clinical features that make diagnosis and therapeutic decision-making difficult. The prevalence, location, and management of these herniations and the medical history of our patients were analyzed. **Methods:** Sex, age, injury level, previous surgery, and patient treatment data from July 2018 to May 2021 were collected retrospectively. During this period, 179 patients underwent surgery, 33 of whom patients presented ULDH. **Results:** Thirty-three patients were included in the study (18 male and 15 female). Ages ranged from 39 to 85 years, with a predominance of elderly patients. The levels operated were L1-L2 in seven patients, L2-L3 in ten patients, L3-L4 in fourteen patients, and surgery in two levels (L2-L3, L3-L4) in two patients. In our practice, microdiscectomy is the preferred approach and was performed in all cases, with the addition of fusion in four of the 33 patients. Finally, a history of low lumbar disc herniation (LLDH) surgery was found in 16 patients. **Conclusions:** In our population, ULDHs are a rare entity with lower prevalence at the higher lumbar levels. They occur more frequently in elderly patients and clinical presentation can vary, which is a challenge for surgeons. In older adults, the development of lumbar kyphosis due to vertebral wedging is considered a risk factor for the development of ULDH. Surgical management by microdiscectomy is considered a technique with good results for this pathology. **Level of Evidence III; Retrospective, longitudinal, descriptive, observational study.**

**Keywords:** Hernia; Prevalence; Diagnosis.

## RESUMO

**Introdução:** As hérnias de disco lombares altas (ULDH) são consideradas lesões infrequentes (1% a 11%). Ocorrem principalmente em idosos com características clínicas especiais que dificultam o diagnóstico e a decisão terapêutica. A prevalência, localização, o tratamento e a história de nossos pacientes foram analisados. **Métodos:** Dados sobre sexo, idade, nível das lesões, história cirúrgica e tratamento de nossos pacientes foram coletados retrospectivamente de julho de 2018 a maio de 2021. Nesse período, 179 pacientes foram operados, dos quais 33 apresentavam ULDH. **Resultados:** Trinta e três pacientes foram incluídos neste estudo, sendo 18 homens e 15 mulheres. A faixa etária variou de 39 a 85 anos, predominando os pacientes idosos. Os níveis operados foram L1-L2 em sete pacientes, L2-L3 em dez pacientes, L3-L4 em catorze pacientes e cirurgia em 2 níveis (L2-L3, L3-L4) em dois pacientes. Em nosso meio, a microdiscectomia é o tratamento de escolha, que foi realizado em todos os casos, adicionando fusão em 4 dos 33 pacientes. Finalmente, encontrou-se o antecedente de cirurgia de hérnia de disco lombar baixa (LLDH) em 16 pacientes. **Conclusões:** Em nosso meio, a ULDH é uma entidade rara e com menor prevalência em níveis lombares mais altos. Ocorrem com maior frequência em idosos e seu quadro clínico pode ser variado, o que representa um desafio para o cirurgião. Em idosos, o desenvolvimento de cifose lombar devido ao acunhamento vertebral é considerado um fator de risco para o desenvolvimento de ULDH. A cirurgia de microdiscectomia é considerada uma técnica com bons resultados nessa patologia. **Nível de Evidência III; Estudo retrospectivo, transversal, descritivo, observacional.**

**Descritores:** Hérnia; Prevalência; Diagnóstico.

## RESUMEN

**Introducción:** Las hernias discales lumbares altas (ULDH) son consideradas lesiones infrecuentes (1-11%). Se presentan principalmente en adultos mayores con características clínicas especiales que dificultan su diagnóstico y decisión terapéutica. La prevalencia, localización, manejo y antecedentes de nuestros pacientes fueron analizados. **Métodos:** Los datos con respecto a sexo, edad, nivel de lesión, antecedentes quirúrgicos y manejo de nuestros pacientes fueron recolectados retrospectivamente desde julio del 2018 hasta mayo del 2021. Durante este periodo 179 pacientes fueron operados, de los cuales 33 presentaron ULDH. **Resultados:** Treinta y tres pacientes fueron incluidos en éste estudio, de los cuales 18 eran hombres y 15 mujeres. Los rangos de edad variaron entre 39 y 85 años, predominando pacientes de la tercera edad. Los niveles intervenidos fueron L1-L2 en siete pacientes, L2-L3 en diez pacientes, L3-L4 en catorce

Study conducted at the Centro Médico Puerta de Hierro, Zapopan, Jalisco, Mexico.

Correspondence: Eduardo González Camacho. Periférico Paseo de la República 2121, int 508. Col. Camelinas. C.P. Morelia, Mich. 58290. dr.egonzalezc@gmail.com



pacientes y cirugía en 2 niveles (L2-L3, L3-L4) en dos pacientes. En nuestro medio, la microdiscectomía es el manejo preferido, el cual se realizó en todos los casos, agregando fusión en 4 de los 33 pacientes. Finalmente se encontró antecedente de cirugía por hernias discales lumbares bajas (LLDH) en 16 pacientes. Conclusiones: En nuestro medio, las ULDH son una entidad rara con menor prevalencia en niveles lumbares más altos. Se presentan con mayor frecuencia en personas de edad avanzada y su cuadro clínico puede ser variado, lo cual representa un reto para cirujano. En adultos mayores el desarrollo de cifosis lumbar por acunamientos vertebrales se considera un factor de riesgo para el desarrollo de ULDH. El manejo quirúrgico mediante microdiscectomía se considera una técnica con buenos resultados en ésta patología. **Nivel de Evidencia III; Estudio retrospectivo, transversal, descriptivo, observacional.**

**Descriptores:** *Hernia; Prevalencia; Diagnóstico.*

**INTRODUCTION**

Upper lumbar disc herniations (ULDH) are defined as those that occur at levels L1-L2, L2-L3, and L3-L4.<sup>1</sup> This type of injury is infrequent, accounting for only 1-11% of lumbar disc herniations,<sup>1,2</sup> and they present special clinical characteristics that do not resemble those of lower lumbar disc herniations (LLDH), which makes diagnosis and therapeutic decision-making difficult, generating less favorable results.

There are several factors that have been associated with the presence of upper lumbar disc herniations, such as advanced age, a history of LLDH surgery, and changes in sagittal balance linked to vertebral wedging. The prevalence, location, management, and patient history of these herniations were retrospectively analyzed, reported, and compared with the literature

**METHODS**

We conducted a retrospective study of patients who underwent lumbar disc herniation surgery performed by our medical group at the Centro Médico Puerta de Hierro over a period of three years, from July 2018 to May 2021.

Our study included the data for all patients diagnosed with lumbar disc herniation who were managed surgically having given informed consent for said procedure and divided them into two groups (ULDH and LLDH). Conservatively managed patients were excluded. We conducted an analysis of the characteristics of the ULDH group.

During this period, 179 patients were operated on, 33 of whom were diagnosed with ULDH. All of these were diagnosed and managed surgically by two surgeons with extensive experience in spine surgery.

The patients who underwent surgical management had to satisfy at least two of the following inclusion criteria: back or radicular pain, history of previous crises without resolution using non-surgical methods, failure of conservative treatment of more than a 3-month period, evidence of ULDH in simple magnetic resonance imaging, and sensory or motor deficit (Figure 1).

The following exclusion criteria were considered: patients who

were managed conservatively, who had incomplete medical records, or who had undergone previous surgery and presented degenerative-type involvement of the immediate segment, as it was considered pathology of the adjacent segment.

The population characteristics collected were sex, age, level of the injury, surgical history, and management implemented. Finally, a comparison of the results obtained from the literature was conducted (Figure 2).

**RESULTS**

During the study period, 179 procedures were performed for diagnoses of lumbar disc herniation, of which 33 (18%) corresponded to patients with ULDH and were included in this study.

In the LLDH group, the prevalence by sex was 96 males (65.7%) and 50 females (34.22%). Their ages ranged from 19 to 85 years, with a mean age of 43.5 years (Table 1).

Regarding the demographic characteristics of the study population (ULDH), the prevalence by sex was 18 males (54.4%) and 15 females (45.5%). Their ages ranged from 39 to 85 years (mean of 62 years) and there was a predominance of elderly patients (Figure 3).

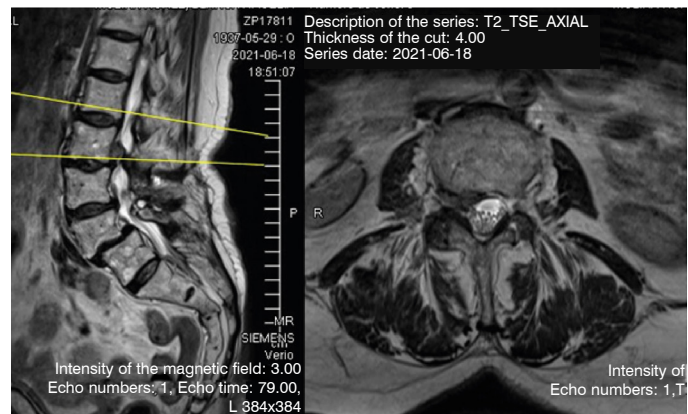


Figure 1. Sagittal and axial MRI cuts ULDH.

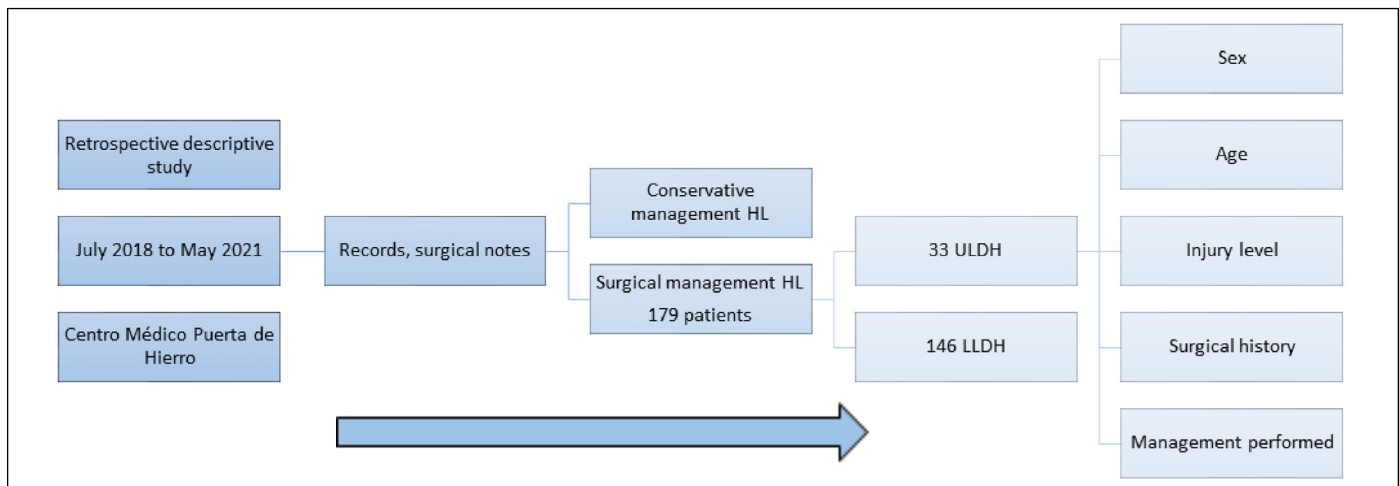


Figure 2. Study characteristics.

The levels operated on were L1-L2 in 7 patients (21.2%), L2-L3 in 10 patients (30.3%), and L3-L4 in 14 patients (42.4%), which was the most frequently affected level, and surgery at two levels (L2-L3, L3-L4) was performed in 2 patients (6.0%) (Figure 4).

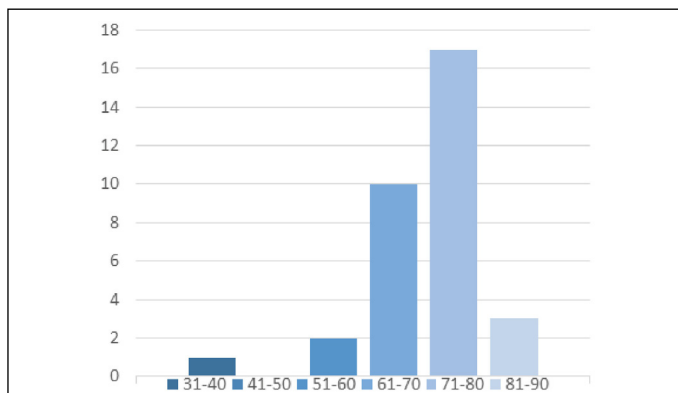
In our practice, microdiscectomy is the preferred technique and was performed in all cases via posteromedial approach. With the use of a surgical microscope, a unilateral paramedian access was performed, allowing the resection of bone and ligamentous tissue in order to finally remove the herniated disc fragment. In 4 of the 33 patients, fusion by means of transpedicular screws, rods, and bone graft was also performed (Figures 5 and 6).

Finally, 16 of the 33 patients had a history of lower lumbar disc herniation (LLDH).

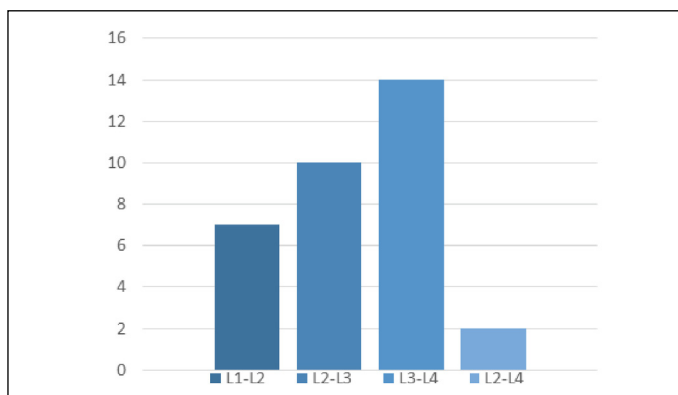
Neither postoperative results nor follow-up were reported, as our study objective was only to determine the characteristics of the patients operated on in our practice.

**Table 1.** Demographic characteristics of ULDH vs. LLDH.

	Males	Females	Mean Age
ULDH	18	15	62.0
LLDH	96	50	43.5



**Figure 3.** ULDH patient age.

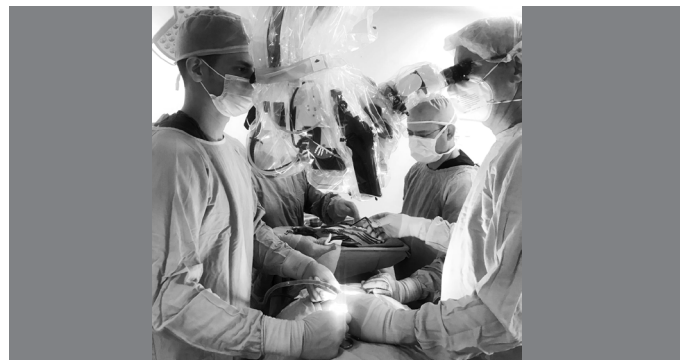

**Figure 4.** ULDH levels operated.

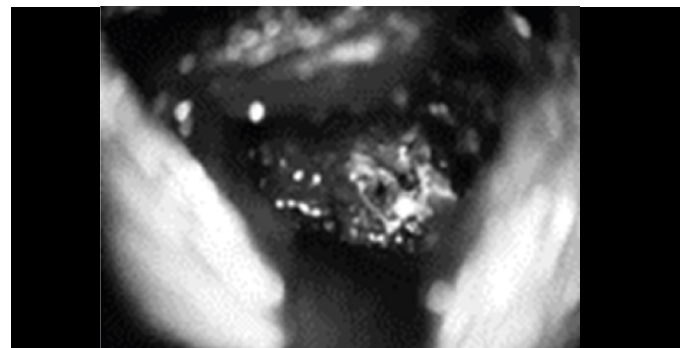
**DISCUSSION**

ULDHs are rare, with a presentation range of between 1 and 11% of all lumbar herniations.<sup>1,2</sup> In our practice the frequency was 18%; however, only patients who underwent surgery for disc herniations were included, so it is possible that the variation in frequency is because we did not include conservatively treated patients. The diagnostic difficulty could have generated more severe conditions due to the longer evolution time and, thus, have caused a more frequent need for surgical treatment.

Clinical diagnosis of ULDH is a challenge because the manifestations of the patient cannot be clearly slotted into a specific



**Figure 5.** Lumbar microdiscectomy.



**Figure 6.** View under the microscope.

myotome or dermatome.<sup>1</sup> Most of the patients present with back pain, pain in the gluteal region, and radicular pain in the posterior region of the thighs; however, none of these symptoms are specific. Classically, the femoral stretch test will be positive in 84 to 94% of patients.<sup>3</sup> In patients with lumbar herniation of L1 to L3 it is possible to find urinary changes secondary to compression of the spinal cord or cauda equina.<sup>4</sup>

Regarding the demographic characteristics of our population, the prevalence by sex was 54.4% males and 45.5% females, that is, with no significant difference. This difference is consistent with that reported in the literature.<sup>5,6</sup> Advanced age is considered an important factor in the pathogenesis of ULDH due to the degenerative changes that affect mobility and, thus, normal spinal biomechanics.<sup>7</sup> The age ranged from 39 to 85 years (mean of 62 years), while the mean age in other studies was lower (55.8 years).<sup>6</sup> The LLDH presentation age is generally considered to be lower. Cummins et al. reported a mean age of 41 years and a slightly higher predominance of males (57% versus 43%).<sup>8</sup> The lower the level of the ULDH, the higher its prevalence, being less frequent at level L1-L2 and more frequent at level L3-L4.

In relation to LLDH surgery as an important antecedent to the development of ULDH, in our study we found both prior surgery and physiological fusion secondary to spondylarthrosis to be present factors. Age-related degeneration of the lumbar canal is considered to contribute to the development of ULDH.<sup>5</sup>

Vertebral wedging is another significant degenerative change. ULDH is related to the presence of an adjacent wedged vertebra and the consequent increase in lumbar kyphosis.<sup>9</sup>

Wedging of the vertebral body can be associated with damage to the vertebral endplate, just as endplate damage is one of the main causes of intervertebral disc deterioration.<sup>10</sup> When the endplate is damaged circulation is affected, promoting damage and degeneration of the disc, which in turn favors its herniation.<sup>11</sup> Consequently, patients with wedging of the vertebrae in combination with kyphotic deformity of the thoracolumbar spine are at increased risk of ULDH.

Microdiscectomy was performed in all cases. It is the most common treatment in our practice because it is less invasive and safer for the patient than the conventional open approach. Microdiscectomy

---

is a term used to describe a surgical technique that involves making a small incision with minimal dissection of the paravertebral muscle using some vision magnification technique, be it microscope or magnifying glass.<sup>12</sup> This technique is considered the gold standard for the treatment of herniated discs.

The endoscopic approach is also considered a good alternative, providing adequate visualization with reduced morbidity, less pain, rapid recovery, and aesthetic benefit, however, it is technically demanding.<sup>13</sup> One of the complications associated with endoscopic management is a higher recurrence rate as compared to other techniques. There are risk factors for this complication such as obesity, advanced age, and Modic changes.<sup>14,15</sup>

## CONCLUSIONS

ULDHs are a rare entity with lower prevalence in the higher lumbar levels. They occur more frequently in elderly people and

their clinical manifestations can be varied, which is a challenge for the surgeon. Both a history of surgical lumbar fusion and spondylarthrosis predispose older adults to the development of lumbar kyphosis due to wedging, which is considered a risk factor for the development of ULDH. Finally, surgical management through microdiscectomy is considered a safe, reproducible technique for the treatment of lumbar herniations with good results.

## ACKNOWLEDGEMENTS

Our thanks to the Reespalda A.C. medical, nursing, and administrative teams. Our thanks to Tanya Carolina Dittmar Penski for her editorial assistance.

---

All authors declare no potential conflict of interest related to this article.

---

---

**CONTRIBUTIONS OF THE AUTHORS:** Each author made significant individual contributions to this manuscript. DJHM, CLF, GCE, CGOM, TMA, SGFJ, HEJ: Substantial contribution to the concept or design of the study, or the acquisition, analysis, or interpretation of the study data. GCE: Writing of the article or critical review of its intellectual content.

---

## REFERENCES

1. Sanderson SP, Houten J, Errico T, Forshaw D, Bauman J, Cooper PR. The unique characteristics of "upper" lumbar disc herniations. *Neurosurgery*. 2004;55(2):385-9.
2. Echt M, Holland R, Mowrey W, Cezayirli P, Ramos R, Hamad M, et al. Surgical Outcomes for Upper Lumbar Disc Herniations: A Systematic Review and Meta-analysis. *Global Spine J*. 2021;11(5):802-13.
3. Nadler SF, Campagnolo DI, Tomaio AC, Stitik TP. High lumbar disc: Diagnostic and treatment dilemma. *Am J Phys Med Rehabil*. 1998;77(6):538-44.
4. Court C, Colliou OK, Chin JR, Liebenberg E, Bradford DS, Lotz JC. The effect of static in vivo bending on the murine intervertebral disc. *Spine J*. 2001;1(4):239-45.
5. Iwasaki M, Akino M, Hida K, Yano S, Aoyama T, Saito H, et al. Clinical and Radiographic Characteristics of Upper Lumbar Disc Herniation: Ten-Year Microsurgical Experience. *Neurol Med Chir*. 2011;51(6):423-6.
6. Yüce İ, Kahyaoğlu O, Mertan P, Çavuşoğlu H, Aydın Y. Analysis of Clinical Characteristics and Surgical Results of Upper Lumbar Disc Herniations. *Neurochirurgie*. 2019;65(4):158-63.
7. White AA, Panjabi MM. *Clinical biomechanics of the spine*. 2nd ed. Philadelphia: JB Lippincott; 1990.
8. Cummins J, Lurie JD, Tosteson TD, Hanscom B, Abdu WA, Birkmeyer NJO, et al. Descriptive epidemiology and prior health care utilization of patients in the Spine Patient Outcomes Research Trial's (SPORT) three observational cohorts: disc herniation, spinal stenosis, and degenerative spondylolisthesis. *Spine*. 2006;31(7):806-14.
9. Xu JX, Yang SD, Wang BL, Yang DL, Ding WY, Shen Y. Correlative analyses of isolated upper lumbar disc herniation and adjacent wedge-shaped vertebrae. *Int J Clin Exp Med*. 2015;8(1):1150-5.
10. Dolan P, Luo J, Pollintine P, Landham PR, Stefanakis M, Adams MA. Intervertebral disc decompression following endplate damage: implications for disc degeneration depend on spinal level and age. *Spine*. 2013;38(17):1473-81.
11. Määttä JH, Kraatari M, Wolber L, Niinimäki J, Wadge S, Karppinen J, et al. Vertebral endplate change as a feature of intervertebral disc degeneration: a heritability study. *Eur Spine J*. 2014;23(9):1856-62.
12. Toyone T, Tanaka T, Kato D, Kaneyama R. Low-back pain following surgery for lumbar disc herniation. A prospective study. *J Bone Joint Surg Am*. 2004;86(5):893-6.
13. Righesso O, Falavigna A, Avanzi O. Comparison of open discectomy with microendoscopic discectomy in lumbar disc herniations: results of a randomized controlled trial. *Neurosurgery*. 2007;61(3):545-9.
14. Kim JM, Lee SH, Ahn Y, Yoon DH, Lee CD, Lim ST. Recurrence after successful percutaneous endoscopic lumbar discectomy. *Minim Invasive Neurosurg*. 2007;50(2):82-5.
15. Yao Y, Liu H, Zhang H, Wang H, Zhang Z, Zheng Y, et al. Risk factors for the recurrent herniation after microendoscopic discectomy. *World Neurosurg*. 2016;95:451-5.