

# PERCUTANEOUS LUMBAR DISC DECOMPRESSION FOR TREATMENT OF DISCOGENIC PAIN

DESCOMPRESSÃO INTRADISCAL LOMBAR PERCUTÂNEA PARA TRATAMENTO DE DOR DISCOGÊNICA

DESCOMPRESIÓN PERCUTÂNEA DE DISCO LUMBAR PARA TRATAR EL DOLOR DISCOGÉNICO

JONAS LENZI DE ARAUJO<sup>1</sup>, PEDRO GREIN DEL SANTORO<sup>1</sup>, HENRIQUE MOTIZUKI<sup>1</sup>, XAVIER SOLER I GRAELLS<sup>1</sup>, ED MARCELO ZANINELLI<sup>2</sup>, MARCEL LUIZ BENATO<sup>1</sup>

## ABSTRACT

**Objective:** Report safety and clinical outcomes of percutaneous intradiscal decompression procedures in patients with discogenic pain that failed conservative treatment. Minimally invasive surgical treatments are a trend. **Methods:** A retrospective study describing the clinical outcomes of patients treated with Nucleoplasty™ and DeKompessor™, with follow up of 5 years. **Results:** Thirty-four (n=34) patients underwent intradiscal decompression with a follow-up period of 5 years, 21 had resolution of pain, eight underwent lumbar interbody arthrodesis, one underwent surgical discectomy and 4 had residual back pain. There were no adverse events. **Conclusion:** It was demonstrated the same safety obtained in other studies that also evaluated the use of triangular safety zone for percutaneous procedures. The success rate with the percutaneous procedure is similar to other studies published in a recent meta-analysis. The comparative studies, prospective and controlled will be useful to better define the effectiveness of percutaneous procedures.

**Keywords:** Intervertebral disc displacement; Decompression; Intervertebral disc; Low back pain.

## RESUMO

**Objetivo:** Relatar a segurança e os desfechos clínicos de procedimentos de descompressão intradiscal percutânea em pacientes com dor discogênica nos quais houve falha do tratamento conservador. Procedimentos cirúrgicos minimamente invasivos são uma tendência de tratamento. **Metodos:** Estudo retrospectivo com descrição dos desfechos clínicos de pacientes tratados com Nucleoplasty™ e DeKompessor™, com seguimento de 5 anos. **Resultados:** Trinta e quatro (n = 34) pacientes foram submetidos a descompressão intradiscal com seguimento mínimo de 5 anos, 21 obtiveram resolução do quadro algíco, 8 foram submetidos a artrodese intersomática lombar, um foi submetido a discectomia cirúrgica e 4 apresentam dor lombar residual. Não ocorreram eventos adversos. **Conclusão:** Foi demonstrada a mesma segurança obtida em outros trabalhos que também avaliaram o uso da zona triangular de segurança para procedimentos percutâneos. O índice de sucesso com o procedimento percutâneo assemelha-se a outros estudos mais recentes publicados em uma metanálise. A realização de estudos comparativos, prospectivos e controlados será útil para definir melhor a efetividade dos procedimentos percutâneos.

**Descritores:** Deslocamento do disco vertebral; Descompressão; Disco intervertebral; Dor lombar.

## RESUMEN

**Objetivo:** Informe de la seguridad y los resultados clínicos de los procedimientos de descompresión intradiscal percutánea en pacientes con dolor de origen discal que fracasó el tratamiento conservador. Tratamientos quirúrgicos mínimamente invasivos son una tendencia está OK. **Metodos:** Estudio retrospectivo que describe los resultados clínicos de los pacientes tratados con Nucleoplasty™ y DeKompessor™, con un seguimiento de 5 años. **Resultados:** Treinta y cuatro (n = 34) pacientes fueron sometidos a descompresión intradiscal y evaluados por período de 5 años, 21 tuvieron la resolución del dolor, 8 se sometieron a artrodesis lumbar intersomática, un paciente fue sometido a una discectomía quirúrgica y 4 tienen dolor lumbar residual. No hubo eventos adversos. **Conclusión:** Se ha demostrado el mismo grado de seguridad alcanzado en otros estudios que también evaluaron el uso de la zona triangular de seguridad para procedimientos percutâneos. La tasa de éxito con el procedimiento percutâneo es similar a otros estudios publicados en un reciente meta-análisis. Los estudios comparativos, prospectivos y controlados serán útiles para definir mejor la eficacia de los procedimientos percutâneos.

**Descriptores:** Desplazamiento del disco intervertebral; Descompresión; Disco intervertebral; Dolor de la región lumbar.

## INTRODUCTION

Low back pain is a very prevalent and disabling symptom, and is the second most common reason for visits to the emergency room. Studies infer that up to 80% of the population has at least one episode of back pain during life.<sup>1-6</sup> Almeida gauged prevalence of low back pain to be 15% in a survey conducted in Salvador (Bahia, Brazil).<sup>7</sup> When stratified, this prevalence accentuated for the older age groups.

Kuslich et al.<sup>8</sup> identified several causes of low back pain. Discogenic pain is very common and results from a complex interaction of biomechanical and biochemical processes. Pro-inflammatory

chemical mediators are released, which perform chemotaxis and cell proliferation. This process can generate a disorganized intradiscal architecture, maintaining the outer surface of the annulus fibrosus. Afterwards, occurs the bulging disc whose manifestation in degenerative disc disease represents the mechanical failure of the fibrous annulus support in relation to the nucleus pulposus. Increased intradiscal pressures, coupled with the low disc compliance, are responsible for the pain complaints. The injury and irritation of the regional dorsal ganglion due to local inflammatory process may be responsible for the chronicity of low back pain.

After exhausting conservative therapies, surgical procedures

1. Spinal Pathology Group, Hospital das Clínicas, Universidade Federal do Paraná (UFPR), Curitiba, PR, Brazil.

2. Department of Spine Surgery, Hospital do Trabalhador, Universidade Federal do Paraná (UFPR), Curitiba, PR, Brazil.

Study conducted by the Spine Surgery Group, Hospital das Clínicas and Hospital do Trabalhador, Universidade Federal do Paraná – UFPR – Curitiba, PR, Brazil.

Correspondence: Rua Eduardo Sprada, 1872 – Curitiba, PR, Brasil – 81210-370. jonaslenzi@gmail.com

are indicated for those with persistent symptoms. There are several surgical modalities, including dynamic stabilization, disc decompression, and interbody arthrodesis, which is considered the gold standard procedure. However, there is a tendency to perform minimally invasive surgeries, aimed at early rehabilitation and minimize the overloading of adjacent levels when compared to arthrodesis.

The main objective of nuclear decompression is to reduce intradiscal pressure. Theoretically, contraction of the whole fibrous annulus is responsible for the intradiscal return of a herniated nucleus pulposus. Intradiscal decompression is indicated to relieve discogenic lumbar pain and pain radiating from the limbs due to root compression by disc herniation.

Nucleoplasty (Nucleoplasty™, ArthroCare Co., USA) is a minimally invasive procedure that uses bipolar radiofrequency energy for coablation. In this process, multiple electrodes emit a fraction of the energy of a conventional radio frequency unit, resulting in ablation of organic molecules with a low temperature. The coablation demonstrates a highly localized and controlled ablation, minimizing damage to adjacent tissues.

Another system of disc decompression, the DeKompressor™ (Stryker Inst, USA) is based on the introduction of cannulated probes that perform rotation and suction to remove the nucleus pulposus. There are published studies that show comparable or better results related to nucleoplasty.

Due to the high prevalence of the disease, the study aims to evaluate the safety and clinical outcomes of patients undergoing percutaneous intradiscal decompression.

## METHODOLOGY

We conducted a retrospective longitudinal non-randomized study through the records of 35 patients with symptomatic lumbar disc disease who had undergone Nucleoplasty™ and Dekompressor™ procedures at the Department of Spine Surgery of the Hospital de Clínicas and Hospital do Trabalhador (Curitiba, Brazil) from January 2005 to January 2006. After surgery, follow-up was conducted for a period of 60 months in 34 patients.

Pain relief and return to their routine activities were analyzed to identify favorable outcomes. The need to perform other procedures for the resolution of pain or the presence of adverse events was also highlighted outcomes in the study.

The inclusion criteria for the patients were persistent pain radiating to the lower limbs after failed conservative treatment, absence of neurological deficit, disc protrusions contained in the annulus fibrous, preserved disc height, and a minimum follow-up of 60 months after the procedure. Discography was not performed prior to the disc decompression. Percutaneous decompression was discarded in the presence of infection, fractures, tumors, uncontained hernias, or previous procedures in the lumbar spine.

The procedures were performed in the operating room with percutaneous technique guided by the image intensifier through the triangular safe zone, according to the recommendations.

Statistical analysis was based on descriptive data of the sample, with the continuous variables described as means ( $\pm$  standard deviation) and the categorical variables as percentages.

## RESULTS

Of the 35 patients who underwent percutaneous disc decompression during the study period, only one was excluded for vertebral fracture in the fourth year of follow-up. The result was a sample of 34 patients. Of these, 10 (29.41%) were female and 24 (70.59%) were male. The mean age and its standard deviation was 38.06 ( $\pm$  5.89).

The intervention was performed at the L3-L4 levels in six (17.64%), L4-L5 in 27 (79.41%) and L5-S1 in 22 (64.7%) patients. In 17 (50%) patients, only one level was decompressed, two and three levels of decompression were performed in 13 (38.24%) and four (11.76%) cases, respectively.

Clinical outcomes revealed that 21 (61.76%) had resolution of pain with return to daily activities, only one (2.94%) patient required surgical discectomy with three months of evolution and eight (23.53%) patients underwent lumbar arthrodesis in an average period of 31.28 months ( $\pm$  18.24). (Figure 1) There were no adverse events in the study sample.

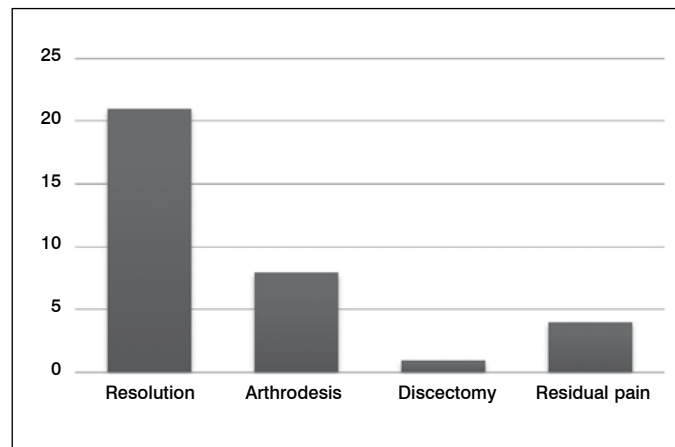


Figure 1. Clinical outcomes for 60 months of follow-up.

## DISCUSSION

The use of percutaneous procedures has emerged as a powerful component in the treatment of spinal diseases. Many studies have been published on the subject, but their results cannot always be reproduced.

Matuoka et al.<sup>9</sup> and Choi et al.<sup>10</sup> studied the anatomy and safety of the insertion of trocars and intradiscal catheters through the triangular safe zone (TSZ). This is the site for the introduction of the apparatus used in various techniques, among them Nucleoplasty™ and Dekompressor™.

Choi and Basile Junior<sup>10</sup> found that the TSZ pattern of the different vertebral levels differed among themselves and resembled the TSZs of the same level in the other samples. The authors concluded that the TSZs had morphology similar to a rectangular triangle at levels L2-L3 and L3-L4, transitioning to an obtuse morphology at the lower levels (L4-L5 and L5-S1). The total area of the TSZ increased progressively the more caudal the level, therefore, larger cannula can be used to access the lower discs.

Even with the aid of anatomical studies, percutaneous techniques are not free of adverse events. Damage to the spinal cord, infection, vascular injury, and even death are early complications. Later, localized pain at the surgical site, biomechanical spinal alteration, adhesive arachnoiditis, nerve root dysfunction, myelocoele, and recurrent disc prolapse may occur.

The lack of adverse events in the series studied, although limited, corroborates data obtained by other authors, demonstrating the safety of using the triangular safe zone for Nucleoplasty™, DeKompressor™ and other percutaneous procedures.

Singh et al.<sup>11,12</sup> showed the clinical efficacy of nucleoplasty. Later, the same authors published a series of 80 cases of nucleoplasty for the treatment of lumbar disc herniations.<sup>13</sup> Of these cases, 75% showed an improvement of pain scores when evaluated 12 months after the procedure. Alexandre et al.<sup>14</sup> assessed the use of nucleoplasty to be good or excellent in 80.7% in their study in 1390 patients.

An effectiveness similar to other studies was demonstrated in this study.<sup>12,15-18</sup> Still, the results are below the good/fair results obtained by Alexander et al.<sup>14</sup> and Choy et al.,<sup>19</sup> which reached 80.7% and 78% good/excellent results with percutaneous discectomy, respectively. Percutaneous techniques demonstrate better results compared to placebo, but surgical discectomy is more effective compared to percutaneous techniques.<sup>20-22</sup>

Gerges conducted a meta-analysis, selecting 14 studies by different authors.<sup>22</sup> Of these, the longest follow-up was that of Masala et al.<sup>23</sup> with 18 (12-21) months, achieving a success rate of 79%.

Although many papers have been published about minimally invasive techniques, there is no consensus among the authors. There is no clear evidence regarding clinical outcomes, there is also no randomized trial comparing them to the gold standard methods.

## CONCLUSION

The benefits of minimally invasive surgery in the treatment of lumbar discogenic pain are clear in the short term. This is justified by noting that the relief of symptoms is satisfactory in an earlier stage. Although the results of the use of percutaneous intradiscal decompression proposed by other authors are encouraging, but

are not faithfully reproduced, Gerges published in his meta-analysis that a satisfaction index greater than 50% was found in 10 of 14 studies evaluated.

There is a dearth of research with long-term follow-up and research that compares the clinical outcomes of minimally invasive surgery with procedures considered to be the gold standard.

Although the early results are satisfactory, the 5-year follow-up showed the evolution of disc disease with the subsequent need for performing interbody arthrodesis in 23.53% of patients at an average period of 31.28 months ( $\pm$  18, 24) after percutaneous decompression.

---

All authors declare no potential conflict of interest concerning this article.

---

## REFERENCES

- Boswell MV, Shah RV, Everett CR, Sehgal N, Mckenzie-Brown AM, Abdi S, et al. Interventional techniques in the management of chronic spinal pain: Evidence-based practice guidelines. *Pain Physician*. 2005;8(1):1-47.
- Bressler HB, Keyes WJ, Rochon PA, Badley E. The prevalence of low back pain in the elderly. A systematic review of the literature. *Spine (Phila Pa 1976)*. 1999;24(17):1813-9.
- Lawrence RC, Helmick CG, Arnett FC, Deyo RA, Felson DT, Giannini EH, et al. Estimates of the prevalence of arthritis and selected musculoskeletal disorders in the United States. *Arthritis Rheum*. 1998;41(5):778-99.
- Cassidy JD, Carroll LJ, Côté P. The Saskatchewan health and back pain survey. The prevalence of low back pain and related disability in Saskatchewan adults. *Spine (Phila Pa 1976)*. 1998;23(17):1860-6.
- Walker BF, Muller R, Grant WVD. Low back pain in Australian adults: prevalence and associated disability. *J Manipulative Physiol Ther*. 2004;27(4):238-44.
- Guo HR, Tanaka S, Halperin WE, Cameron LL. Back pain prevalence in US industry and estimates of lost workdays. *Am J Public Health*. 1999;89(7):1029-35.
- Almeida IC, Sá KN, Silva M, Baptista A, Matos MA, Lessa I. Prevalência de dor lombar crônica na população da cidade de Salvador. *Rev Bras Ortop*. 2008;43(3):96-102.
- Kuslich SD, Ulstrom CL, Michael CJ. The tissue origin of low back pain and sciatica: a report of pain response to tissue stimulation during operations on the lumbar spine using local anesthesia. *Orthop Clin North Am*. 1991;22(2):181-7.
- Matuoka CM, Basile Junior R. Estudo anatômico do pedículo vertebral lombar e estruturas neurais adjacentes. *Acta Ortop Bras*. 2002;10(3):25-34.
- Choi PS, Basile Junior R. Estudo anatômico da zona triangular de segurança aplicada aos procedimentos percutâneos pósterio-laterais lombares. *Coluna*. 2003;2(1):20-6.
- Singh V, Piryani C, Liao K, Nieschulz S. Percutaneous disc decompression using nucleoplasty. In: Proceedings of the Annual Meeting of the Florida Pain Society, Miami, June, 2001.
- Singh V, Piryani C, Liao K. Role of percutaneous disc decompression using coblation in managing chronic discogenic low back pain: a prospective, observational study. *Pain Physician*. 2004;7(4):419-25.
- Smith L, Brown JE. Treatment of lumbar intervertebral disc lesions by direct injection of chymopapain. *J Bone Joint Surg Br*. 1967;49(3):502-19.
- Alexandre A, Corò L, Azuelos A, Pellone M. Percutaneous nucleoplasty for discoradicular conflict. *Acta Neurochir Suppl*. 2005;92:83-6.
- Sharps LS, Isaac Z. Percutaneous disc decompression using nucleoplasty. *Pain Physician*. 2002;5(2):121-6.
- Singh V, Piryani C, Liao K. Evaluation of percutaneous disc decompression using coblation in chronic back pain with or without leg pain. *Pain Physician*. 2003;6(3):273-80.
- Singh V, Piryani C, Liao K, Nieschulz S. Percutaneous disc decompression using coblation (nucleoplasty) in the treatment of chronic discogenic pain. *Pain Physician*. 2002;5(3):250-9.
- Yakovlev A, Tamimi MA, Liang H, Eristavi M. Outcomes of percutaneous disc decompression utilizing nucleoplasty for the treatment of chronic discogenic pain. *Pain Physician*. 2007;10(2):319-28.
- Choy DS, Ascher PW, Ranu HS, Saddeki S, Alkaitis D, Liebler W, et al. Percutaneous laser disc decompression. A new therapeutic modality. *Spine (Phila Pa 1976)*. 1992;17(8):949-56.
- Erdine S, Ozyalcin NS, Cimen A. [Percutaneous lumbar nucleoplasty]. *Agri*. 2005;17(2):17-22.
- Cohen SP, Williams S, Kurihara C, Griffith S, Larkin TM. Nucleoplasty with or without intradiscal electrothermal therapy (IDET) as a treatment for lumbar herniated disc. *J Spinal Disord Tech*. 2005;18(Suppl):S119-24.
- Gerges FJ, Lipsitz SR, Nedeljkovic SS. A systematic review on the effectiveness of the Nucleoplasty procedure for discogenic pain. *Pain Physician*. 2010;13(2):117-32.
- Masala S, Massari F, Fabiano S, Ursone A, Fiori R, Pastore F, et al. Nucleoplasty in the treatment of lumbar discogenic back pain: one year follow-up. *Cardiovasc Intervent Radiol*. 2007;30(3):426-32.