

POSTOPERATIVE RADIOGRAPHIC CONTROL OF INSTRUMENTATION WITH THORACIC PEDICLE SCREWS IN ADOLESCENT IDIOPATHIC SCOLIOSIS

CONTROLE RADIOGRÁFICO PÓS-OPERATÓRIO DE INSTRUMENTAÇÃO COM PARAFUSOS PEDICULARES TORÁCICOS EM ESCOLIOSE IDIOPÁTICA DOS ADOLESCENTES

CONTROL RADIOGRAFICO POSTOPERATORIO DE LA INSTRUMENTACION CON TORNILLOS PEDICULARES TORACICOS EN LA ESCOLIOSIS IDIOPÁTICA DEL ADOLESCENTE

PABLO FIORILLO¹, HERNAN HECTOR DEMONTI¹,

ABSTRACT

Objective: To evaluate the efficiency of intraoperative and postoperative radiographs of the dorsal pedicle screw placement and its relationship with computed tomography (CT). **Methods:** Thirty-six patients with adolescent idiopathic scoliosis (AIS) were evaluated. Three different observers classified the placement of screws through radiographs. The responses were compared with CT scans. **Results:** A total of 280 pedicle screws were evaluated. The interobserver assessment was 0.56 (moderate match). The assessment of intraobserver matching was 0.79 (good match). No vascular or neurological lesions have been observed. **Conclusions:** According to the results of intra- and interobservers, the reproducibility of postoperative radiograph is not very effective for diagnosing malposition of spinal pedicle screws. Computed tomography proved very useful for determining the position of spinal pedicle screws.

Keywords: Scoliosis; Adolescent; Bone Screws. Tomography.

RESUMO

Objetivo: Avaliar a eficiência intraoperatória e pós-operatória da radiografia na colocação do parafuso pedicular dorsal e sua relação com a tomografia computadorizada (TC). **Métodos:** Foram avaliados 36 pacientes com escoliose idiopática dos adolescentes (EIA). Três observadores classificam a colocação dos parafusos com radiografias. Estas respostas foram comparadas às com tomografia computadorizada. **Resultados:** Foram avaliados um total de 280 parafusos pediculares. A avaliação interobservador foi de 0,56 (concordância moderada). A avaliação intraobservador foi de 0,79 (concordância). Não se apresentaram lesões vasculares ou neurológicas. **Conclusões:** Segundo os resultados intra e inter-observadores, a reprodutibilidade da radiografia pós-operatória não é muito eficaz para diagnosticar a má posição dos parafusos pediculares dorsais. A tomografia computadorizada foi muito útil para determinar a posição dos parafusos pediculares dorsais.

Descritores: Escoliose; Adolescente; Parafusos Ósseos; Tomografia.

RESUMEN

Objetivo: Evaluar la eficacia intraoperatoria y postoperatoria de la radiografía en la colocación del tornillo pedicular dorsal y su relación con la tomografía computada (CT). **Métodos:** Se evaluaron 36 pacientes con escoliosis idiopática del adolescente (EIA). Tres observadores clasifican colocación de los tornillos con radiografía. Estas respuestas se compararon con la tomografía computada. **Resultados:** Se evaluaron un total de 280 tornillos pediculares. La evaluación interobservador fue de 0,56 (concordancia moderada). La evaluación intraobservador fue 0,79 (concordancia). No se presentaron lesiones vasculares o neurológicas. **Conclusiones:** Según los resultados intra e interobservador, la reproductibilidad de la radiografía postoperatoria no es muy eficaz para el diagnóstico de la mala posición de los tornillos de pedículo dorsales. La tomografía computada fue muy útil para determinar la posición de los tornillos pediculares dorsales.

Descritores: Escoliosis; Adolescente; Tornillos Óseos; Tomografía.

INTRODUCTION

Transpedicular instrumentation, initially combined with plates, was originally used in the 1970s for spinal fixation of lumbar fractures.¹ From 1986, it began to be used for surgical corrections and stabilization of deformities, with hybrid constructions, and from 1994, it was used as a complete construction of pedicular screws.^{2,3} The advantages of pedicular instrumentation over other types of fixation system are its greater power of three-dimensional correction, increased stability of the construction, lower incidence of pseudoarthrosis, and the fact that it does not require postoperative corsets.⁴⁻¹⁰

Thoracic instrumentation has potential dangers, due to the risk of

neurovascular complications due to malpositioned screws, therefore, it is very important to have a diagnostic method that recognizes this risk. Radiographies and tomographies are the diagnostic methods currently used for its control.

The objective was to evaluate the efficacy of intra- and postoperative radiography to assess the position of thoracic transpedicle screws in patients with idiopathic scoliosis.

MATERIAL AND METHODS

The study included a total of 36 patients with adolescent idiopathic scoliosis (AIS) treated with posterior transpedicular instrumentation.

1. Sanatorio Mapaci-Assist Sport de Rosario, Argentina.

Work carried out at Sanatorio Mapaci de Rosario, Santa Fé, Argentina.

Correspondence: Ruta Provincial 34 S 4444 Funes Santa Fe, CP 2132. Rosario, Argentina. demontih@hotmail.com

The patients were operated on between March 2004 and March 2011. The pattern of the scoliotic curve was classified according to the study published by Lawrence Lenke in 2001.¹¹

We analyzed a total of 280 thoracic pedicle screws (TPS), inserted free hand by the technician,¹² with a radioscopic guide in the anteroposterior and lateral planes. Polyaxial titanium screws of 4.5 and 5.5 mm in diameter were used, with lengths ranging, depending on the vertebral level, from 30 to 40 mm. In all the surgeries, continuous intraoperative electrophysiological monitoring was performed, using motor evoked potentials (MEP) and somatosensory evoked potentials (SSEP).

In the second postoperative week, on an outpatient basis, the following images were taken: 1) X-ray of the spine-anterior-posterior and lateral views; and 2) computed tomography of thoracic spine (in bone window, with thin 2 mm slices taken at the widest axis of each screw, with multi-plane reconstruction).

The X-rays of the spine (immediate postoperative and at 2 weeks) were shown to three orthopedists of the spine, at three separate times, one month apart, to analyze the intraobserver variable. The orthopedists were asked to evaluate the position of the thoracic pedicle screws as either inside, outside, or uncertain.

Tomographic classification: The radiographic data were compared with the tomographic images of each screw. The position of the screw was classified based on the work of Bride Upendra of the All India Institute of Medical Sciences (AIIMS) group,¹³ which makes the following divisions, for evaluating the position of thoracic screws:

Type I: position acceptable (Figure 1):

- A - the screw is completely within the pedicle;
- B - the screw is perforating some pedicular cortex, but part of it is still within the pedicle;
- C - the screw is penetrating less than 2 mm through the pedicular cortex;
- D - the screw is located in the costovertebral unit (screw inside-outside-inside).

Type II: placement unacceptable; those that do not correspond to Type I and that do not show signs of neurovascular compromise. (Figure 2)

Type III: screws that are causing neurovascular injury. (Figure 3)

Statistical Analysis

The data collected were analyzed using the kappa method, according to the interpretation by Landis and Koch, who propose margins for assessing the number of agreement based on the kappa method. The evaluations were divided into six groups. (Table 1)

RESULTS

A total of 36 patients with idiopathic scoliosis were analyzed: thirty-one women and five men. The average age at the time of surgery was 16.7 years (range 11-19 years). The distribution of

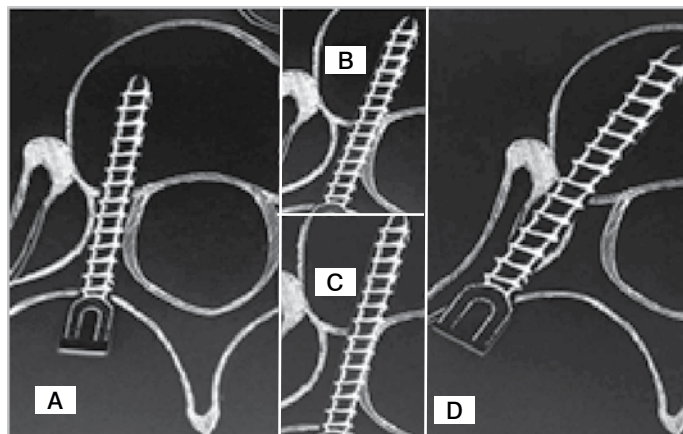


Figure 1. Type I placement acceptable.

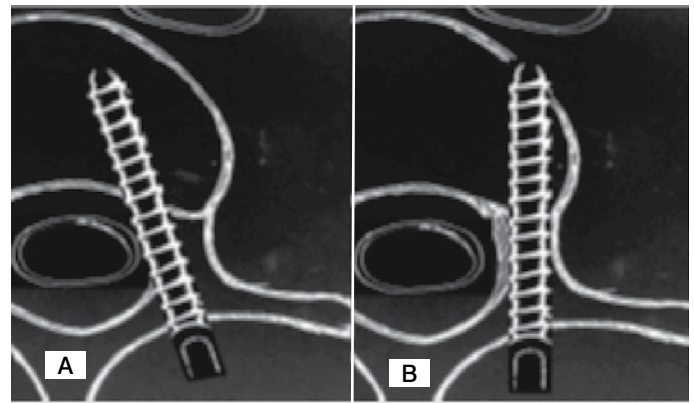


Figure 2. Type II placement unacceptable, without injury to vital structure. A, 2 mm medial perforation. B, perforation of the anterior cortex.

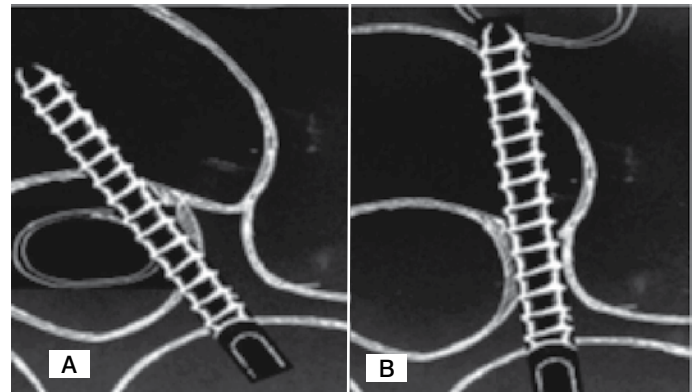


Figure 3. Type III placement unacceptable, without injury to vital structure. A, spinal cord injury. B, Screw impinging the aorta.

Table 1. The data collected were analyzed using the method of Kappa, with interpretation by Landis and Koch.

	Agreement
Zero value	No agreement
0-0.20	Insignificant
0.20-0.40	Low
0.40-0.60	Moderate
0.60-0.80	Good
0.80-1	Very Good

scoliotic curve patterns, according to Lenke, was: 1-12; 2-1; 3-13; 4-1; 5-3 and 6-6. The average Cobb angle of the curves was 58.3°. The total number of thoracic screws analyzed was 280. Radiological evaluation: In the evaluation of the orthopedists (Observers 1, 2 and 3), for screws inside the pedicle was an overall average of 163.3 (58.5%). For the screws outside pedicle, the orthopedists found an overall average of 65 screws (23.2%). And finally, for those whose position was uncertain, they found an overall average of 51 (18.3%). (Table 2)

Tomographic evaluation: The results of the tomographic evaluation are shown in Table 3.

The interobserver evaluation was 0.59 (moderate agreement) and the intraobserver evaluation was 0.79 (good). (Figure 4)

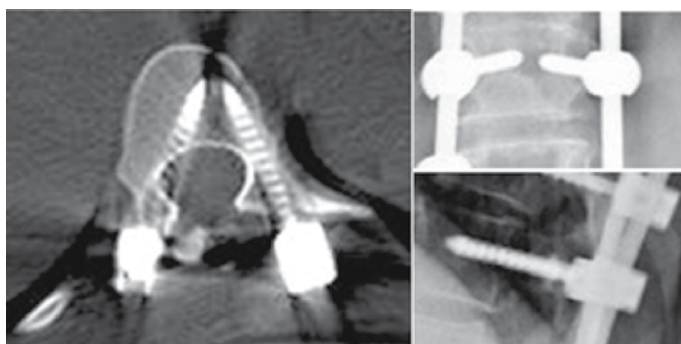
Complications. No vascular or neurological complications were recorded. There were two cases of pull out in high thoracic screws which coincided in the type 2 pattern.

Table 2. Results of the radiological evaluation.

Observer	Within	Outside	Uncertain
1	152 (54.3%)	58 (20.7%)	70 (25%)
2	174 (62.3%)	74 (26.4%)	32 (11.3%)
3	165 (58.9%)	63 (22.5%)	52 (18.6%)
General	163.3 (58.5%)	65 (23.2%)	51 (18.3%)

Table 3. Results of the tomographic evaluation.

Type	No. of screws
I	142 (50.71%)
A	93 (33.21%)
B	14 (5%)
C	28 (10%)
D	7 (2.5%)
II	138 (49.29%)
A	51 (18.21%)
B	87 (31.08%)
III	None

**Figure 4.** Radiographic and tomographic control.

DISCUSSION

In vivo studies on the lumbar spine have established the superiority of CAT compared with conventional radiology for the correct evaluation of penetration of both the pedicular cortex and the vertebral body^{14,15}

Study of pedicle instrumentation has been focused on its effective means of placement, which occurs when the screw is located completely within the limits of the pedicular cortex. This effectiveness is seen at the lumbar level where the pedicle screws are larger in volume than the thoracic screws.¹⁶⁻¹⁸

Some works in the literature have reported the safety of this method in frontal deformities,^{3,5-7,19} beginning with Suk et al. who report 47 patients treated for idiopathic scoliosis with pedicle screws and hybrid constructions, although they do not show the absolute number of thoracic screws, and a total of 3.0% incidence of poorly-positioned screws in the X-ray, without neurological complications.¹⁰ The work of Liljenqvist,²⁰ based on postoperative evaluation with tomography, evaluates 120 thoracic screws in patients with idiopathic scoliosis. Of these 8.3 % penetrated the medial cortex by an average distance of 1.5 mm, without neurological complications. The study of Belmont et al.²¹ reports 279 thoracic screws, with 57% of the screws completely contained in the pedicle, with both medial cortical (14%) and lateral (29%) penetration, and no neurological complications. It is important to recognize that in these publications, minor infringements of the thoracic pedicle screws, although not ideal, are considered perforations within an acceptable range.

CONCLUSION

Based on the intra- and interobserver results, the use of intra-operative and postoperative radiography did not demonstrate great effectiveness in the diagnosis of misplaced thoracic pedicle screws. Tomography showed great usefulness for determining the position of the screws.

All authors declare no potential conflict of interest concerning this article.

REFERENCES

- Roy-Camille R, Sailland G, Mazel C. Internal fixation of the lumbar spine with pedicle screw plating. *Clin Orthop Relat Res.* 1986;(203):7-17.
- Luque ER. Interpeduncular segmental fixation. *Clin Orthop Relat Res.* 1986;(203):54-7.
- Suk SI, Lee CK, Kim WJ, Chung YJ, Park YB. Segmental pedicle screw fixation in the treatment of thoracic idiopathic scoliosis. *Spine (Phila Pa 1976).* 1995;20(12):1399-405.
- Ebraheim NA, Jabaly G, Xu R, Yeasting RA. Anatomic relations of the thoracic pedicle to the adjacent neural structures. *Spine (Phila Pa 1976).* 1997;22(14):1553-6.
- Gaines RW Jr. The use of pedicle-screw internal fixation for the operative treatment of spinal disorders. *J Bone Joint Surg Am.* 2000;82(10):1458-76.
- Lonstein JE, Denis F, Perra JH, Pinto MR, Smith MD, Winter RB. Complications associated with pedicle screws. *J Bone Joint Surg Am.* 1999;81(11):1519-28.
- Kuklo TR, Lenke LG, O'Brien MF, Lehman RA Jr, Polly DW Jr, Schroeder TM. Accuracy and efficacy of thoracic pedicle screws in curves more than 90 degrees. *Spine (Phila Pa 1976).* 2005;30(2):222-6.
- Brown CA, Lenke LG, Bridwell KH, Geideman WM, Hasan SA, Blanke K. Complications of pediatric thoracolumbar and lumbar pedicle screws. *Spine (Phila Pa 1976).* 1998;23(14):1566-71.
- Delorme S, Labelle H, Aubin CE, de Guise JA, Rivard CH, Poitras B, et al. A three-dimensional radiographic comparison of Cotrel-Dubousset and Colorado instrumentations for the correction of idiopathic scoliosis. *Spine (Phila Pa 1976).* 2000;25(2):205-10.
- Suk SI, Lee CK, Min HJ, Cho KH, Oh JH. Comparison of Cotrel-Dubousset pedicle screws and hooks in the treatment of idiopathic scoliosis. *Int Orthop.* 1994;18(6):341-6.
- Lenke LG, Betz RR, Harms J, Bridwell KH, Clements DH, Lowe TG, et al. Adolescent idiopathic scoliosis: a new classification to determine extent of spinal arthrodesis. *J Bone Joint Surg Am.* 2001;83(8):1169-81.
- Kim YJ, Lenke LG, Bridwell KH, Cho YS, Riew KD. Free hand pedicle screw placement in the thoracic spine: is it safe? *Spine (Phila Pa 1976).* 2004;29(3):333-42.
- Uppendra BN, Meena D, Chowdhury B, Ahmad A, Jayaswal A. Outcome-based classification for assessment of thoracic pedicular screw placement. *Spine (Phila Pa 1976).* 2008;33(4):384-90.
- Berlemann U, Heini P, Müller U, Stoupis C, Schwarzenbach O. Reliability of pedicle screw assessment utilizing plain radiographs versus CT reconstruction. *Eur Spine J.* 1997;6(6):406-10.
- Farber GL, Place HM, Mazur RA, Jones DE, Damiano TR. Accuracy of pedicle screw placement in lumbar fusions by plain radiographs and computed tomography. *Spine (Phila Pa 1976).* 1995;20(13):1494-9.
- Gertzbein SD, Robbins SE. Accuracy of pedicular screw placement in vivo. *Spine (Phila Pa 1976).* 1990;15(1):11-4.
- Yalçın S, Güven O. Reversible anterior cord syndrome due to penetration of the spinal canal by pedicular screws. *Paraplegia.* 1995;33(7):423-5.
- Polly DW Jr, Potter BK, Kuklo T, Young S, Johnson C, Klemme WR. Volumetric spinal canal intrusion: a comparison between thoracic pedicle screws and thoracic hooks. *Spine (Phila Pa 1976).* 2004;29(1):63-9.
- Liljenqvist UR, Link TM, Halm HF. Morphometric analysis of thoracic and lumbar vertebrae in idiopathic scoliosis. *Spine (Phila Pa 1976).* 2000; 25(10): 1247-53.
- Liljenqvist UR, Halm HF, Link TM. Pedicle screw instrumentation of the thoracic spine in idiopathic scoliosis. *Spine (Phila Pa 1976).* 1997;22(19):2239-45.
- Belmont PJ Jr, Klemme WR, Dhawan A, Polly DW Jr. In vivo accuracy of thoracic pedicle screws. *Spine (Phila Pa 1976).* 2001;26(21):2340-6.