

# MECHANICAL COMPLICATIONS AND LOSS OF CORRECTION IN OSTEOTOMIES OF THE THREE COLUMNS

COMPLICAÇÕES MECÂNICAS E PERDA DE CORREÇÃO EM OSTEOTOMIAS DAS TRÊS COLUNAS

COMPLICACIONES MECÂNICAS Y PÉRDIDA DE CORRECCIÓN EN OSTEOTOMÍAS DE LAS TRES COLUMNAS

MARCELO SIMONI SIMÕES<sup>1,2</sup>, ERNANI VIANNA DE ABREU<sup>1,2</sup>, SAMUEL BAMBERG PYDD<sup>1,2</sup>

1. Hospital Ernesto Dornelles, Porto Alegre, RS, Brazil.

2. Hospital Mãe de Deus, Porto Alegre, RS, Brazil.

## ABSTRACT

**Objectives:** To observe the degree of correction and postoperative evolution of the spinopelvic parameters in patients with sagittal imbalance submitted to 3-column osteotomies. **Methods:** Retrospective analysis of 20 cases of 3-column osteotomies in patients with evident sagittal imbalance and minimum follow-up of one year, computing evolution of radiological data as a function of time, complications and reinterventions, and classification into subgroups by preoperative spinopelvic measures and complications. The variation of measures, quantitative and categorical variables, and differences between groups were evaluated using the Wilcoxon, Spearman, Fischer's exact test, Kruskal-Wallis and Mann-Whitney tests. **Results:** There was improvement of all the sagittal parameters, ideal correction in 55% of the cases and maintained until the end of the follow-up in 40% of the cases. No correlation was found between obtaining optimal correction and data or preoperative measurements. Clinical and infectious complications did not affect the maintenance of the correction. The most common mechanical complications were pseudoarthrosis-related rod fracture at osteotomy (30%) and failures at the lower fixation level (15%). There was no significant difference in the maintenance of the correction between the groups with and without mechanical complications treated. In the untreated mechanical complications there was a significantly higher radiological worsening ( $p < 0.05$ ) in the maintenance parameters of the curve correction (loss of  $27.5 \pm 14.39^\circ$  vs.  $3.69 \pm 3.68^\circ$ ) and increased pelvic tilt (PT) (increase of  $12.25 \pm 7.27^\circ$  vs.  $1.13 \pm 1.93^\circ$ ). **Conclusion:** The perfect correction was obtained in 55% of cases and the significant loss of correction occurred only in cases of untreated mechanical complications.

**Keywords:** Spine; Osteotomy; Postoperative complications.

## RESUMO

**Objetivos:** Observar grau de correção e evolução pós-operatória dos parâmetros espinopélvicos em pacientes com desequilíbrio sagital submetidos a osteotomias das três colunas. **Métodos:** Análise retrospectiva de 20 casos de osteotomias das três colunas em pacientes com desequilíbrio sagital evidente e seguimento mínimo de um ano, computando evolução dos dados radiológicos em função do tempo, complicações e reintervenções e classificação em subgrupos pelas medidas espinopélvicas pré-operatórias e complicações. A variação das medidas, as variáveis quantitativas, categóricas e a diferença entre grupos foram avaliadas com os testes de Wilcoxon, Spearman, teste exato de Fischer, Kruskal-Wallis e Mann-Whitney. **Resultados:** Houve melhora de todos os parâmetros sagitais, correção ideal em 55% dos casos e mantidas até o fim do seguimento em 40% dos casos. Não foi demonstrada correlação entre obtenção de correção ideal e dados ou medidas pré-operatórias. Complicações clínicas e infecciosas não influenciaram a manutenção da correção. As complicações mecânicas mais comuns foram: fratura de haste relacionada com pseudoartrose na osteotomia (30%) e falhas no nível inferior da fixação (15%). Não houve diferença significativa na manutenção da correção entre os grupos sem e com complicações mecânicas tratadas. Nas complicações mecânicas não tratadas houve piora radiológica significativamente maior ( $p < 0,05$ ) nos parâmetros de manutenção da correção da curva (perda de  $27,5 \pm 14,39^\circ$  contra  $3,69 \pm 3,68^\circ$ ) e aumento da versão pélvica (VP) (aumento de  $12,25 \pm 7,27^\circ$  contra  $1,13 \pm 1,93^\circ$ ). **Conclusão:** A correção perfeita foi obtida em 55% dos casos e a perda significativa de correção ocorreu apenas nos casos de complicações mecânicas não tratadas.

**Descritores:** Coluna vertebral; Osteotomia; Complicações pós-operatórias.

## RESUMEN

**Objetivos:** Observar el grado de corrección y la evolución post-operatoria de los parámetros espinopélvicos en pacientes con desequilibrio sagital sometidos a osteotomias de las tres columnas. **Métodos:** Análisis retrospectivo de 20 casos de osteotomias de las tres columnas en pacientes con desequilibrio sagital evidente y seguimiento mínimo de un año, computando evolución de los datos radiológicos en función del tiempo, complicaciones y reintervenciones y clasificación en subgrupos por las medidas espinopélvicas preoperatorias y complicaciones. La variación de las medidas, las variables cuantitativas, categóricas y la diferencia entre grupos fueron evaluadas con las pruebas de Wilcoxon, Spearman, prueba exacta de Fischer, Kruskal-Wallis y Mann-Whitney. **Resultados:** Hubo mejora de todos los parámetros sagitales, corrección ideal en 55% de los casos y mantenidos hasta el final del seguimiento en 40% de los casos. No se ha demostrado correlación entre obtención de corrección ideal y datos o medidas preoperatorias. Las complicaciones clínicas e infecciosas no afectaron el mantenimiento de la

Study conducted at the Hospital Ernesto Dornelles, Porto Alegre, RS, Brazil.

Correspondence: Samuel Bamberg Pydd. Rua Visconde do Herval, 728 / 202, Bairro Menino Deus, Porto Alegre, RS, Brazil. 90130-150. samuelbamberg@yahoo.com.br

corrección. Las complicaciones mecánicas más comunes fueron: fractura del vástago relacionada con pseudoartrosis en la osteotomía (30%) y fallas en el nivel inferior de la fijación (15%). No hubo diferencia significativa en el mantenimiento de la corrección entre los grupos sin y con complicaciones mecánicas tratadas. En las complicaciones mecánicas no tratadas hubo un empeoramiento radiológico significativamente mayor ( $p < 0,05$ ) en los parámetros de mantenimiento de la corrección de la curva (pérdida de  $27,5 \pm 14,39^\circ$  contra  $3,69 \pm 3,68^\circ$ ) y aumento de la versión pélvica (VP) (aumento de  $12,25 \pm 7,27$  contra  $1,13 \pm 1,93^\circ$ ). Conclusión: La corrección perfecta fue obtenida en el 55% de los casos y la pérdida significativa de corrección ocurrió sólo en los casos de complicaciones mecánicas no tratadas.

**Descriptores:** Columna vertebral; Osteotomía; Complicaciones posoperatorias.

## INTRODUCTION

Posterior approach three-column osteotomies are extremely powerful techniques for the correction of severe rigid deformities,<sup>1</sup> but they are aggressive procedures associated with various complications.<sup>2-4</sup> Their use is justified by the importance of sagittal correction in surgeries for deformity, but few articles describe how much of this correction is maintained because of complications that occur and the duration of follow-up in these cases.<sup>5,6</sup> This study surveys the mechanical complications and the evolution of sagittal spinopelvic measurements of a series of 20 patients with sagittal imbalance who underwent three-column osteotomies with follow-up for at least one year.

## METHODS

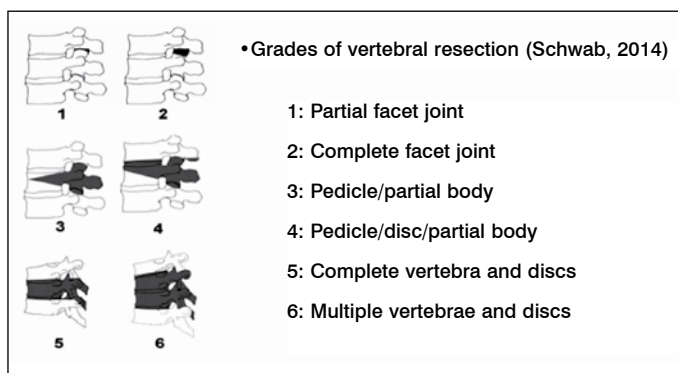
This is a retrospective, observational study in which we analyzed 20 consecutive cases that were operated on by a single surgical team with follow-up for at least one year after surgery. All the patients underwent three-column osteotomies for treatment of sagittal imbalance, defined as a sagittal vertical axis (SVA) greater than or equal to eight centimeters. All the patients signed the Informed Consent Form (ICF) prior to the surgical procedure. Preoperative, early postoperative and late postoperative radiological data were recorded, as well as the most significant complications and any reinterventions performed up until the end of follow-up. The patients were classified into two groups by pelvic incidence (PI), four groups by SVA, and four groups by the difference between PI and lumbar lordosis (LL). (Table 1).

To avoid confusion with the various nomenclatures present in the literature, the types of osteotomies performed were described as grade three, four, or five, according to the classification of Schwab et al.<sup>7</sup> (Figure 1)

Only those cases that presented  $SVA \leq 5$  cm,  $PI-LL \leq \pm 10^\circ$ , and  $PT \leq 24^\circ$ <sup>8-12</sup> were considered to be ideal corrections. Loss of correction was defined as any angular variation greater than  $5^\circ$  or an increase in

**Table 1.** Division into groups by preoperative spinopelvic measurements.

Group	SVA	PI-LL	PI
I	8 to 10cm	$\leq 10^\circ$	$\leq 59^\circ$
II	10.5 to 20cm	11 a $20^\circ$	$\geq 60^\circ$
III	20.5 to 30cm	21 a $30^\circ$	-
IV	$\geq 30.5$ cm	$\geq 31^\circ$	-



**Figure 1.** Schwab classification of the types of osteotomies.

SVA of 2cm or more. Due to the small size of the sample, the quantitative variables were analyzed with the Spearman test, variations of measurements in the same patient with the Wilcoxon test, categorical variables with Fisher's exact test, and the differences between groups with the Kruskal Wallis and Mann-Whitney tests, using SPSS version 21.0 software and considering a level of significance of 5%.

## RESULTS

**Sample data** – We analyzed 18 female and two male patients, between 32 and 70 years of age (average  $58.2 \pm 10.6$  years), with sagittal imbalance defined as  $SVA \geq 8$  cm (8 to 50cm, average  $14.85 \pm 11.14$  cm). Sixteen patients (80%) had previously undergone at least one surgery, of whom 10 (50%) had undergone more than one (up to nine, average  $2 \pm 2.13$  surgeries per patient). The etiology of the deformity was post-arthrodesis hypolordosis in eight cases, junctional kyphosis in four cases, post-arthrodesis hypolordosis complicated by osteomyelitis in three cases, post-traumatic kyphosis in two cases, in addition to one case of ankylosing spondylitis, one of sequela from spinal tuberculosis, and one of primary degenerative kyphoscoliosis. Grade three osteotomy was performed in 14 cases, two of which were at two levels, grade four in five cases, and grade five in one case. The most frequently operated levels were L3 (eight cases) and L4 (seven cases). The other osteotomies were at dorsal levels and in L3 + T8 in one case of two osteotomies in the same procedure. Follow-up time ranged from 15 to 110 months (average  $46.25 \pm 18.1$  months). (Table 2)

**Spinopelvic parameters of the sample** – PI ranged from  $46$  to  $70^\circ$  (average  $59.45 \pm 6.64^\circ$ ), with 11 patients in group I ( $PI \leq 59^\circ$ ) and nine in group II ( $PI \geq 60^\circ$ ). The average SVA was  $14.85 \pm 11.14$  cm, with 11 patients in group I (8 to 10 cm), seven in group II (10.5 to 20 cm), and three in group IV (greater than 30 cm). The average lumbar lordosis was  $25.85 \pm 26.42^\circ$  (minimum lumbar kyphosis of  $34^\circ$ , maximum of  $68^\circ$ ), the average PT was  $33.75 \pm 11.39^\circ$  (minimum 14 and maximum  $54^\circ$ ), and the average SS was  $25.70 \pm 11.95^\circ$  (minimum 10 and maximum  $45^\circ$ ). The PI-LL difference ranged from  $-1$  to  $104^\circ$  (average  $33.60 \pm 28.69^\circ$ ), with 5 patients in group I (up to  $10^\circ$ ), three in group II (11 to  $20^\circ$ ), one in group III (21 to  $30^\circ$ ), and 11 in group IV (greater than  $30^\circ$ ). (Table 3) No relationship between these measurements and the age of the patient or the number of previous surgeries was found ( $p=0.611$ ).

**Postoperative spinopelvic parameters** – In the postoperative period there was a significant improvement ( $p < 0.05$ ) in all parameters, with an average SVA of  $3.33 \pm 3.90$  cm (minimum  $-3.5$  and maximum 11 cm), an average LL of  $55.7 \pm 9.47^\circ$  (minimum  $36^\circ$  and maximum  $70^\circ$ ), an average PT of  $23.15 \pm 4.2^\circ$  (minimum 16 and maximum  $31^\circ$ ), and an average SS of  $36.3 \pm 6.81^\circ$  (minimum 24 and maximum  $51^\circ$ ). (Table 3) The local correction with the osteotomy was  $33.10 \pm 10.60^\circ$  (minimum 20 and maximum  $60^\circ$ ) and the correction of the curve was  $35.20 \pm 23.26^\circ$  (minimum 12 and maximum  $104^\circ$ ). The type of osteotomy did not significantly impact the degree of local correction ( $p=0.494$ ), the correction of the curve ( $p=0.239$ ), or improvement of the SVA ( $p=0.444$ ). The level osteotomized did not significantly impact the degree of correction of the curve ( $p=0.470$ ) or improvement of the SVA ( $p=0.824$ ), but osteotomies of L3 had greater impact on improvement of the PT ( $p=0.014$ ). The ideal correction parameters ( $SVA \leq 5$  cm,  $-10^\circ \leq PI-LL \leq 10^\circ$ , and  $PT \leq 24^\circ$ ) were achieved in only 11 cases (55%) and the average PI-LL difference was  $3.55 \pm 9.07^\circ$ , with 15 patients in group I and five in group II. It was not possible to demonstrate statistically that the PI, the preoperative SVA, the preoperative PI-LL difference, or the type or level of the osteotomy had any influence on obtaining ideal correction.

Table 2. Sample data.

Case	Sex Age	Etiology	Previous surgeries	Level of osteotomy	Type of osteotomy	Levels fixed	Follow-up
01	F-68	PAHL	2	L3	3	T10-S1	+ 5 years
02	F-57	PAHL	1	L4	3	T10-IL	+ 5 years
03	F-66	PAHL+COM	3	L3	4	T5-IL	+ 5 years
04	F-48	PAHL+COM	9	L4	3	T10-S1	18 months
05	M-70	ANK SP	4	L3	3	T9-S1	+ 5 years
06	M-48	Post TBC	0	T5-T6	4	T2-T10	+ 5 years
07	F-54	PAHL+COM	5	T12	5	T8-L3	+ 5 years
08	F-32	PAHL	1	L3	4	T11-S1	+ 5 years
09	F-40	Post TRM	0	L3	3	T10-S1	+ 5 years
10	F-62	Post TRM	0	T7 e T8	3	T4-T11	+ 5 years
11	F-66	Junctional	2	T9	3	T2-L4	29 months
12	F-50	Junctional	1	T8 e L3	3	T2-IL	36 months
13	F-69	DEGEN	0	L4	4	T9-S1	26 months
14	F-64	Junctional	1	L4	4	L2-S1	28 months
15	F-67	Junctional	1	L4	3	T10-IL	31 months
16	F-63	PAHL	2	L3	3	T10-IL	26 months
17	F-54	PAHL	2	L4	3	T10-IL	30 months
18	F-64	PAHL	3	L4	3	T10-IL	15 months
19	F-62	PAHL	1	L3	3	T10-IL	15 months
20	F-70	PAHL	3	L3	3	T11-S1	51 months

HLPA- hipolordose pós artrodese / OMC- osteomielite crônica / ESP ANQ- espondilite anquilosante / DEGEN- degenerativa primária.

Table 3. Spinopelvic measurements and loss of correction.

	Pre op.	Post op.	Final	Average loss
SVA (cm)	14.85 ± 11.14	3.33 ± 3.90	6.75 ± 5.08	3.70 ± 4.59
LL (degrees)	25.85 ± 26.42	55.70 ± 9.47	50.30 ± 14.55	6.65 ± 3.05
PT (degrees)	33.75 ± 11.39	23.15 ± 4.42	25.15 ± 7.24	3.35 ± 5.67
SS (degrees)	25.70 ± 11.95	36.30 ± 6.81	34.30 ± 7.77	-2 ± 7.14
TK (degrees)	42.40 ± 24.90	43.60 ± 15.20	46.75 ± 16.80	5.7 ± 13.90

**Complications** – There were 22 complications that were considered to be significant in 13 of the 20 patients (65% of cases, average of 1.1 complications per patient), with 2 clinical complication in the early postoperative period, seven early surgical complications (up to nine days following surgery), nine late surgical complications, and four surgical complications from reinterventions. There were seven infections in five patients (25%) and 12 mechanical complications in nine patients (45%), with seven rod breaks and one superior junctional kyphosis in 6 patients (30%) and 4 failures of the lower extremity of the fixation in 3 patients (15%), 2 of which were fractures of the lower instrumented level and 2 of which were loosening of the lower extremity of the fixation in 1 patient. (Table 4) There were no neurological complications in this series.

**Reinterventions** – Fourteen reinterventions were performed in 9 patients (45%). Two patients were reoperated during the same hospitalization as that of the osteotomy for debridement of the infected surgical wound. There were four more reinterventions in the first year of follow-up: one removal of a screw that was compressing a dorsal root and causing intercostal pain; one replacement of implants with extension to the ilium, due to the loosening of the sacral implant and loss of correction in a T9-S1 fixation; and two implants removed because of infection, both in patients who presented chronic osteomyelitis prior to the osteotomy. After the first year of follow-up, there were seis reinterventions for broken rods in five patients, all of which occurred in the osteotomized segment and were related to pseudoarthrosis confirmed during surgery.

There were four more indications of reintervention for mechanical complications (three failures of the lower instrumented level and one junctional kyphosis with a broken rod) that were not performed for different reasons. Taking these cases into account, there were indications of reintervention in 12 patients (60%). (Table 4)

**Final spinopelvic parameters** – The average final SVA was 6.75 ± 5.08 cm (minimum 0 and maximum 12.5 cm), the average LL was 50.3 ± 14.55° (minimum 18° and maximum 69°), the average PT was 25.15 ± 7.24° (minimum 14 and maximum 44°), and the average SS was 34.3 ± 7.77° (minimum 21 and maximum 47°). In the final follow-up radiograph, there was a loss of correction (increase of the SVA

≥ 2 cm and/or angular modification > 5° in any of the parameters) in 12 of the 20 cases (60%). The average loss of correction of the curve was 8.45 ± 11.79°, while PT increased an average of 3.35 ± 5.67° and SVA an average of 3.70 ± 4.59 cm. (Table 3) The average of the PI-LL difference was 9.15 ± 14.46°, with 13 patients in group I, three in group II, two in group III, and two in group IV. Of the 11 patients who presented ideal postoperative spinopelvic parameters, only eight (40%) maintained them. It was not possible to demonstrate statistically that PI, preoperative SVA, the preoperative PI-LL difference, and the type or level of osteotomy had any predicative value for the maintenance of the ideal correction at the end of evolution. There was no statistically significant relationship between loss of correction and the occurrence of any type of complications (p=0.062) or reinterventions (p=0.197). Nor was there any significant difference in the loss of correction between patients without mechanical complications and those with treated mechanical complications (p=0.175). Significant loss of correction was directly associated to non-corrected mechanical complications. Comparing the four patients in this situation with the other 16 patients, there was an average increase in the SVA of 8.13 ± 7.72cm versus 2.59 ± 2.87cm (p=0.122), an average correction of the curve of 27.5 ± 14.39° versus 3.69 ± 3.68° (p<0.05), and an average increase in the PT of 12.25 ± 7.27° versus 1.13 ± 1.93° (p<0.05).

## DISCUSSION

Three-column osteotomies are an extremely powerful resource for the correction of rigid deformities and sagittal imbalance, but they are also highly technically complex, aggressive procedures subject to very serious complications.<sup>2,4</sup> Their use is only justified because sagittal correction is of great importance in the context of adult deformities, since it has been shown that pain and disability are directly related to an increased SVA and changes in sagittal spinopelvic parameters.<sup>13-15</sup> When considering a three-column osteotomy, the decision making process should take the possibility of not achieving sufficient correction or of having postoperative loss of correction into account,<sup>5-8</sup> since the procedure is subject to various complications and mechanical failures, and may also be impacted by reinterventions that may occur.<sup>16</sup> However, this point is addressed by few articles, which usually originate in centers of excellence where osteotomy procedures have been developed and perfected, and it is not reasonable to expect the technique to spread to smaller centers.<sup>17</sup> Although classical articles show local mobilizations of 30 to 40° with pedicle subtraction, in multicenter studies the average for the same procedure is only 22°.<sup>8,11,18</sup>

**Table 4.** Complications and reinterventions.

Case	Early clinical	Early surgical	Reoperation hospitalization	Late surgical	Reoperation 1st year	Reoperation 2nd year	Reoperation complication	Late reoperation	Subsequent complication	Subsequent reoperation	No. Of reops
01				Rod breakage		Implant replacement					1
03		Screw in root			Removal of screw						1
04				Osteomyelitis flare-up	Removal of material						1
05		Deep infection	Wound debridement	Uncontrolled infection	Removal of material		Deep infection	Wound debridement			2
07		Osteomyelitis flare-up									0
10		Inferior fracture									0
11	Pe	Inferior fracture									0
12				Rod breakage		Lif + implant replacement					1
13				Loosening of s1	Extension to ilium		Loosening of s1-ilium				1
15		Junctional kyphosis		Rod breakage							0
18	Parkinsonism			Rod breakage		Lif + implant replacement					1
19		Deep infection	Wound debridement	Rod breakage		Lif + rod repair					2
20				Rod breakage		Implant replacement	Rod breakage		Deep infection	Wound debridement	3

Previous observations<sup>19</sup> have shown that in osteotomies performed in patients with dorsal spine pathologies and compensated overall balance, corrections tend to be maintained, such that in this series we opted to use a worse scenario and include only imbalanced patients. Although an SVA above 5cm is defined as imbalance, some authors treat an SVA up to 8cm as acceptable.<sup>12</sup> Because we opted for more stringent criteria, only clearly non-compensated patients with an SVA of at least 8cm were included in the study. Using the same line of reasoning, a correction was considered to be successful only in cases that satisfied 3 postoperative criteria:  $SVA \leq 5\text{cm}$ ,  $-10^\circ \leq \text{PI-LL} \leq 10^\circ$ , and  $\text{PT} \leq 24^\circ$ .<sup>8-11,18</sup> Thus, the effect of the surgery was evaluated not only on overall sagittal balance, but also on the use of compensatory spinopelvic mechanisms. Using these criteria to analyze a multicenter database with 99 cases of pedicle subtraction,<sup>8</sup> corrections were achieved in 55% of cases, while by considering only the normalization of the SVA, success would be 65%, similar to the 62% observed by Schwab. Failure to achieve perfect corrections is more related to the difficulty of surgical planning than to difficulties in executing the surgery itself.<sup>11</sup> A change in a parameter, such as an increase in the LL, is accompanied by reciprocal changes of other parameters, especially increased dorsal kyphosis and alteration of the PT. The correction obtained is proportional to the amount of LL created, but this relationship is not linear.<sup>8,11</sup> Although, we did not succeed in showing it in this article, most likely because of the reduced sample size, other studies show that the degree of local corrections impacts all the balance parameters, but the choice of osteotomized level impacts the PT without changing the correction of the SVA. An exact prediction of the reciprocal changes is difficult, such that the previously proposed direct trigonometric calculations simply do not work. Most surgeons cannot predict the surgical outcomes based on specific parameters, justifying the use of more complex predictive equations or even simulation software.<sup>11</sup>

It is well-known that three-column osteotomies are associated with high complication rates, with such authors reporting that performing a pedicle osteotomy increases the probability of complications in surgeries of deformity in the elderly by seven times.<sup>20</sup>

Analyzing a database of adult osteotomies, Ayhan et al.<sup>21</sup> found the diagnosis to be the factor most associated with the appearance of complications. Based on the regression model, age, sagittal alignment, revision surgery, level operated (thoracic versus lumbar), and type of osteotomy were not shown to be significant, while a diagnosis of degenerative deformity increased the likelihood of complications 4,022 times as compared to a diagnosis of idiopathic deformity. Recently,

Smith observed complications in 78% of cases, severe in 61% of the cases, with neurological deficits and mechanical complications being the most common.<sup>22</sup> In this series, there were significant complications in 65% of the cases, with the occurrence of more infections (25%) and the absence of neurological complications standing out in comparison to other studies. Neurological deficits are usually among the most frequent complications, reported in up to 11% of cases, with up to 6% with permanent damage.<sup>23</sup> It is possible that the very extensive decompressions used in the series were responsible for the absence of neural lesions. It is also possible that the greater number of infections is due to the fact that three of the five cases presented chronic osteomyelitis acquired in previous surgeries as one of the deformity-causing factors and also as a generator of post-osteotomy infection. Infections and mechanical complications, such as junctional kyphosis, pseudoarthrosis, and loosening or fracture of implants, are the most common causes of reinterventions.<sup>4,16</sup>

The most frequent mechanical complications in the series was rod breakage, which occurred seven times in six cases (30%), followed by failure of the lower segment of the fixation, which occurred four times in three cases (15%). The cases of lower failure were interpreted as problems with the surgical technique for not having instrumented enough segments. Rod breakage is one of the most common complications in most studies. Smith et al.<sup>22</sup> reported its occurrence in 26 of 82 cases (32%), requiring reintervention in 14 patients. It is true that the massive instability caused by a three-column osteotomy creates great stress on the implants, but the precise biomechanical explanations for breaks are still speculative.<sup>24</sup>

It is well-established that better corrections are related to the greater clinical improvement of the patient, but some authors postulate that perfect correction of all the spinopelvic parameters should also be sought because insufficient correction would cause mechanical complications,<sup>24</sup> but this relationship is not well-clarified in the literature and in this series a significant relationship between obtaining ideal correction and the occurrence or not of complications was not observed. Although the concept of relating mechanical complications to residual deformity is quite common,<sup>24</sup> there are studies associating breaks with various other factors, such as the magnitude of the sagittal correction performed<sup>25</sup> or the type of instrumentation used.<sup>26</sup> In their series, Le Huec et al.<sup>27,28</sup> reported that 100% of the mechanical complications occurred in patients with residual deformity greater than that considered acceptable by the FBI (Full Balance Integrated) methodology for correction planning. One prospective study of rod breakage in adult deformity surgery showed a risk of breakage of 22%

in cases with a three-column osteotomy versus 4.7% in cases without ( $p=0.001$ ), and that breaks occur at the level or adjacent to the level of the osteotomy, but the univariate analyses did not identify significant relationships between rod breakage and age, body mass index, number of fused segments, pre- or postoperative spinopelvic parameters, or magnitude of correction.<sup>25</sup> The same study also pointed out a higher rate of breakage for chromium-cobalt as compared to titanium or stainless steel rods.<sup>25</sup> Contouring of the rods reduces their fatigue life and can introduce surface irregularities and titanium is a material very sensitive to the propagation of cracks from this type of defect.<sup>29</sup> This is critical in lordotic osteotomies, where contouring of the rod may be extreme.<sup>30</sup> As compared to titanium rods, chromium-cobalt rods are more resistant to fatigue and to the surface defects produced by contouring. On the other hand, they are more rigid and the mechanical loads assumed by the instrumentation are greater, which can lead to a doubly negative effect: the increase of mechanical stresses on the implant alone may promote a fatigue fracture, while reduction of the mechanical loading on the spine may leave the osteotomy more susceptible to pseudoarthrosis.<sup>30</sup> Biomechanical studies point out that deformation on the surface of the rods can be reduced significantly by using accessory rods at the site of the osteotomy (four-rod construction) and more rigid materials, such as chromium-cobalt alloys, but it is not clear whether this implies a reduction in the rate of breakage.<sup>31</sup>

Although various articles address possible causes of and management strategies for breaks and other mechanical failures, we did not find larger studies of the impact of complications and reinterventions on the maintenance of the correction of the deformity. In our series, we did not observe any significant relationship between the loss of correction, the occurrence of reinterventions, or the existence of complications of any kind or at any point in the evolution. In fact, in the patients reoperated for pseudoarthrosis with rod breakage,

the reintervention restored the post-osteotomy parameters or even improved them. Although undesirable, the surgery offered a chance to revisit possible failures in the calculation of the osteotomy or to add structural reinforcement, such as interbody spacers, to the construction. The most commonly used surgical technique for repair was minimally invasive lateral transpsoas approach interbody arthrodesis in the spaces above and below the osteotomy, followed by replacement of the posterior instrumentation.<sup>26</sup>

Loss of correction was directly associated with uncorrected mechanical complications and was only statistically significant for the parameters of the worsening of the curve and an increase in PT. In the four patients in this situation, there was an average increase in SVA of  $8.13 \pm 7.72$  cm, an average loss of correction of the curve of  $27.5 \pm 14.39^\circ$ , and an average increase in the PT of  $12.25 \pm 7.27^\circ$ , while in the other 16 patients the average increase in SVA was  $2.59 \pm 2.87$  cm ( $p=0.122$ ), the average loss of correction of the curve was  $3.69 \pm 3.68^\circ$  ( $p<0.05$ ), and the average increase in the PT was  $1.13 \pm 1.93^\circ$  ( $p<0.05$ ).

## CONCLUSIONS

The results of our series were similar to those published for large series and multicenter studies. The ideal correction was achieved in a little more than half the cases and maintained until the end of follow-up in only 40%. The simple occurrence of complications or reinterventions was not related to important losses of correction, while significant losses occurred in cases of untreated mechanical complications.

All authors declare no potential conflict of interest related to this article.

**CONTRIBUTION OF THE AUTHORS:** Each author made significant individual contributions to this manuscript. MSS (0000-0002-0771-7317) was the key contributor to the intellectual concept and writing of the article, data collection, and conducting the bibliographical research. MSS (0000-0002-0771-7317), SBP (0000-0003-0300-9441), and EVA (0000-0003-0043-2981) performed the surgeries and patient follow-up. MSS and SBP evaluated the statistical analysis data and reviewed the manuscript.

## REFERÊNCIAS

- Bridwell KH, Lewis SJ, Lenke LG, Baldus C, Blanke K. Pedicle subtraction osteotomy for the treatment of fixed sagittal imbalance. *J Bone Joint Surg Am.* 2003;85(3):454-63.
- Bridwell KH, Lewis SJ, Edwards C, Lenke LG, Iffrig TM, Berra A, et al. Complications and outcomes of pedicle subtraction osteotomies for fixed sagittal imbalance. *Spine (Phila Pa 1976).* 2003;28(18):2093-101.
- La Maida GA, Luceri F, Gallozzi F, Ferraro M, Bernardo M. Complication rate in adult deformity surgical treatment: safety of the posterior osteotomies. *Eur Spine J.* 2015;24 Suppl 7:879-86.
- Daubs MD, Brodke DS, Annis P, Lawrence BD. Perioperative complications of pedicle subtraction osteotomy. *Global Spine J.* 2016;6(7):630-5.
- Rose PS, Bridwell KH, Lenke LG, Cronen GA, Mulconrey DS, Buchowski JM, et al. Role of pelvic incidence, thoracic kyphosis, and patient factors on sagittal plane correction following pedicle subtraction osteotomy. *Spine (Phila Pa 1976).* 2009;34(8):785-91.
- Rocha VM, Carrasco FM, Lima GK, Tavares RH, Costa RJF, Moliterno LAM, et al. Loss of correction after vertebroectomy for treatment of spinal deformities. *Coluna/Columna.* 2016;15(3):191-8.
- Schwab F, Blondel B, Chay E, Demakakos J, Lenke L, Tropiano P, et al. The comprehensive anatomical spinal osteotomy classification. *Neurosurgery.* 2014;74(1):112-20.
- Schwab FJ, Patel A, Shaffrey CI, Smith JS, Farcy JP, Boachie-Adjei O, et al. Sagittal realignment failures following pedicle subtraction osteotomy surgery: are we doing enough?: Clinical article. *J Neurosurg Spine.* 2012;16(6):539-46.
- Lafage V, Schwab F, Patel A, Hawkinson N, Farcy JP. Pelvic tilt and truncal inclination: two key radiographic parameters in the setting of adults with spinal deformity. *Spine (Phila Pa 1976).* 2009;34(17):E599-606.
- Schwab F, Patel A, Ungar B, Farcy JP, Lafage V. Adult spinal deformity-postoperative standing imbalance: how much can you tolerate? An overview of key parameters in assessing alignment and planning corrective surgery. *Spine (Phila Pa 1976).* 2010;35(25):2224-31.
- Ailon T, Scheer JK, Lafage V, Schwab FJ, Klineberg E, Sciubba DM, et al. Adult Spinal Deformity Surgeons Are Unable to Accurately Predict Postoperative Spinal Alignment Using Clinical Judgment Alone. *Spine Deform.* 2016;4(4):323-9.
- Kim YJ, Bridwell KH, Lenke LG, Cheh G, Baldus C. Results of lumbar pedicle subtraction osteotomies for fixed sagittal imbalance: a minimum 5-year follow-up study. *Spine (Phila Pa 1976).* 2007;32(20):2189-97.
- Schwab F, Ungar B, Blondel B, Buchowski J, Coe J, Deinlein D, et al. Scoliosis Research Society-Schwab adult spinal deformity classification: a validation study. *Spine (Phila Pa 1976).* 2012;37(12):1077-82.
- Schwab F, Lafage V, Patel A, Farcy JP. Sagittal plane considerations and the pelvis in the adult patient. *Spine (Phila Pa 1976).* 2009;34(17):1828-33.
- Schwab F, Farcy JP, Bridwell K, Berven S, Glassman S, Harrast J, et al. A clinical impact classification of scoliosis in the adult. *Spine (Phila Pa 1976).* 2006;31(18):2109-14.
- Mok JM, Cloyd JM, Bradford DS, Hu SS, Deviren V, Smith JA, et al. Reoperation after primary fusion for adult spinal deformity: rate, reason, and timing. *Spine (Phila Pa 1976).* 2009;34(8):832-9.
- Daubs MD, Lenke LG, Cheh G, Stobbs G, Bridwell KH. Adult spinal deformity surgery: complications and outcomes in patients over age 60. *Spine (Phila Pa 1976).* 2007;32(20):2238-44.
- Lafage V, Schwab F, Vira S, Hart R, Burton D, Smith JS, et al. Does vertebral level of pedicle subtraction osteotomy correlate with degree of spinopelvic parameter correction? *J Neurosurg Spine.* 2011;14(2):184-91.
- Simões MS, Abreu EV, Winkler BC. Posterior three-column osteotomies for the treatment of rigid thoracic kyphosis – a case series. *Rev Bras Ortop.* 2017;52(2):189-96.
- Buchowski JM, Bridwell KH, Lenke LG, Kuhns CA, Lehman RA Jr, Kim YJ, et al. Neurologic complications of lumbar pedicle subtraction osteotomy: a 10-year assessment. *Spine (Phila Pa 1976).* 2007;32(20):2245-52.
- Ayhan S, Aykac B, Yuksel S, Guler UO, Pellise F, Alanay A, et al. Safety and efficacy of osteotomies in adult spinal deformity: what happens in the first year? *Eur Spine J.* 2016;25(8):2471-9.
- Smith JS, Shaffrey CI, Klineberg E, Lafage V, Schwab F, Lafage R, et al. Complication rates associated with 3-column osteotomy in 82 adult spinal deformity patients: retrospective review of a prospectively collected multicenter consecutive series with 2-year follow-up. *J Neurosurg Spine.* 2017:1-14.
- Suk SI, Chung ER, Kim JH, Kim SS, Lee JS, Choi WK. Posterior vertebral column resection for severe rigid scoliosis. *Spine (Phila Pa 1976).* 2005;30(14):1682-7.
- Smith JS, Shaffrey CI, Ames CP, Demakakos J, Fu KM, Keshavarzi S, et al. Assessment of symptomatic rod fracture after posterior instrumented fusion for adult spinal deformity. *Neurosurgery.* 2012;71(4):862-7.
- Smith JS, Shaffrey E, Klineberg E, Shaffrey CI, Lafage V, Schwab FJ, et al. Prospective multicenter assessment of risk factors for rod fracture following surgery for adult spinal deformity. *J Neurosurg Spine.* 2014;21(6):994-1003.
- Luca A, Lovi A, Galbusera F, Brayda-Bruno M. Revision surgery after PSO failure with rod breakage: a comparison of different techniques. *Eur Spine J.* 2014;23 Suppl 6:610-5.
- Le Huec JC, Leijssen P, Duarte M, Aunoble S. Thoracolumbar imbalance analysis for osteotomy planification using a new method: FBI technique. *Eur Spine J.* 2011;20 Suppl 5:669-80.
- Le Huec JC, Cogniet A, Demezon H, Rigal J, Saddiki R, Aunoble S. Insufficient restoration of lumbar lordosis and FBI index following pedicle subtraction osteotomy is an indicator of likely mechanical complication. *Eur Spine J.* 2015;24 Suppl 1:S112-20.
- Lindsey C, Deviren V, Xu Z, Yeh RF, Puttlitz CM. The effects of rod contouring on spinal construct fatigue strength. *Spine (Phila Pa 1976).* 2006;31(15):1680-7.
- Luca A, Ottardi C, Sasso M, Prosdicomo L, La Barbera L, Brayda-Bruno M, et al. Instrumentation failure following pedicle subtraction osteotomy: the role of rod material, diameter, and multi-rod constructs. *Eur Spine J.* 2017;26(3):764-70.
- Gehrchen M, Hallager DW, Dahl B, Harris J, Gudipally M, Jenkins S, et al. Rod Strain After Pedicle Subtraction Osteotomy: A Biomechanical Study. *Spine (Phila Pa 1976).* 2016;41 Suppl 7:S24.