

ADJACENT LEVEL DEGENERATION AND POST-TRAUMATIC DEFORMITY AFTER THORACOLUMBAR FRACTURES

DEGENERAÇÃO DO NÍVEL ADJACENTE E DEFORMIDADE PÓS-TRAUMÁTICA DEPOIS DE FRATURAS TORACOLOMBARES

DEGENERACIÓN DE NIVEL ADYACENTE Y DEFORMIDAD POSTRAUMÁTICA DESPUÉS DE FRACTURAS TORACOLUMBARES

ANDRÉ LUÍS SEBEN¹, XAVIER SOLER I GRAELLS¹, MARCEL LUIZ BENATO², PEDRO GREIN DEL SANTORO², ÁLYN SON LARocca KULCHESKI²

1. Universidade Federal do Paraná, Hospital de Clínicas, Curitiba, PR, Brazil.

2. Hospital do Trabalhador, Curitiba, PR, Brazil.

ABSTRACT

Objectives: To evaluate thoracolumbar fractures and the complications such as adjacent disc degeneration (ADD) and post-traumatic deformity. **Methods:** We evaluated 32 patients divided into two equal groups, 16 in the case group (removal of the synthesis material) and 16 in the control group (not submitted to removal of the synthesis material) in order to verify if there was difference between the incidence of these complications. **Results:** There were no statistically significant differences between the groups regarding the progression of the ADD and the post-traumatic deformity, but both progressed during the 2-year follow-up. **Conclusion:** It was concluded that the removal of the synthesis material was not effective in preventing these complications after surgical fractures of the thoracolumbar spine.

Keywords: Intervertebral disc degeneration; Fractures; Spine.

RESUMO

Objetivo: Avaliar fraturas toracolumbares e complicações como a degeneração do disco adjacente (DDA) e a deformidade pós-traumática. **Métodos:** Avaliaram-se 32 pacientes que foram divididos em dois grupos iguais, sendo 16 no grupo caso (retiraram o material de síntese) e 16 no grupo controle (não foram submetidos à retirada do material de síntese) com o objetivo de verificar se houve diferença entre a incidência dessas complicações. **Resultados:** Não foram encontradas diferenças estatisticamente significativas entre os grupos quanto à progressão da DDA e à deformidade pós-traumática, porém ambas progrediram durante o seguimento de 2 anos. **Conclusão:** Conclui-se que a retirada do material de síntese não foi eficaz na prevenção dessas complicações após fraturas da coluna toracolumbar.

Descritores: Degeneração do disco intervertebral; Fraturas; Coluna vertebral.

RESUMEN

Objetivo: Evaluar fracturas toracolumbares y complicaciones como la degeneración del disco adyacente (DDA) y la deformidad postraumática. **Métodos:** Se evaluaron 32 pacientes divididos en dos grupos iguales, siendo 16 en el grupo caso (retirada del material de síntesis) y 16 en el grupo control (no fueron sometidos a la retirada del material de síntesis) con el fin de comprobar si había diferencia entre la incidencia de estas complicaciones. **Resultados:** No se encontraron diferencias estadísticamente significativas entre los grupos en cuanto a la progresión de la DDA y la deformidad postraumática, pero ambas progresaron durante el seguimiento de 2 años. **Conclusión:** Se concluye que la retirada del material de síntesis no fue eficaz en la prevención de esas complicaciones después de fracturas de la columna toracolumbar.

Descriptores: Degeneración del disco intervertebral; Fracturas; Columna vertebral.

INTRODUCTION

Spine fractures are devastating injuries. In addition to loss of function, many chronic complications develop in these patients, among them post-traumatic deformity and adjacent disc degeneration (ADD).

Most unstable lesions of the spine are treated quickly. The initial treatment is rarely inadequate, but, when it is, it can result in instability and lead to deformity, pain, and/or neurological deficit. Some lesions present occult instability, which may facilitate an erroneous interpretation and lead to incorrect treatment and, consequently, the appearance of residual deformities.^{1,2}

Kyphosis is the most common deformity and is often caused by implant failure, deep infection, pseudoarthrosis, insufficient arthrodesis, and laminectomy. The deformity may cause functional changes

such as pain and neurological deficit. Patients with sagittal imbalance caused by kyphosis display compensatory lordosis of the segments above and/or below the kyphotic segment.³

ADD is defined as an abnormal process that develops at the level above or below the segment where the arthrodesis was performed.^{4,5}

With the consequent increase in the number of arthrodeses to treat traumatic and degenerative spinal instability, ADD has been diagnosed in late postoperative follow-up for vertebral arthrodesis.⁶ The frequency, however, with which ADD occurs, as well as its causes and clinical implications, are still grounds for discussion. Among the possible causes, an increase in the mobility of the segments free from fusion, intradisc metabolic changes, an increase in intradisc pressure, the type of fusion, and biomechanical changes caused

by a change in the spinal axis, as, for example, the loss of lumbar lordosis stand out. This abnormal process may present as disc degeneration (39%), instability (24.6%), disc herniation (28%), and stenosis of the canal (33%).^{7,8} Less frequently, vertebral fracture, and scoliosis may be cited (17%).⁸

While ADD is only imageological in most cases (with prevalence of up to 90%)^{4,9,10} (Figure 1), the percentage of patients with clinical signs is significant, reaching 30% over 5 years.¹¹

According to Ghiselli et al.,¹² ADD develops at 3.9% each year.

Considering the scarcity of data in the literature about ADD and post-traumatic deformity following short fixation of thoracolumbar fractures, we developed this study to evaluate any correlation between these variables.

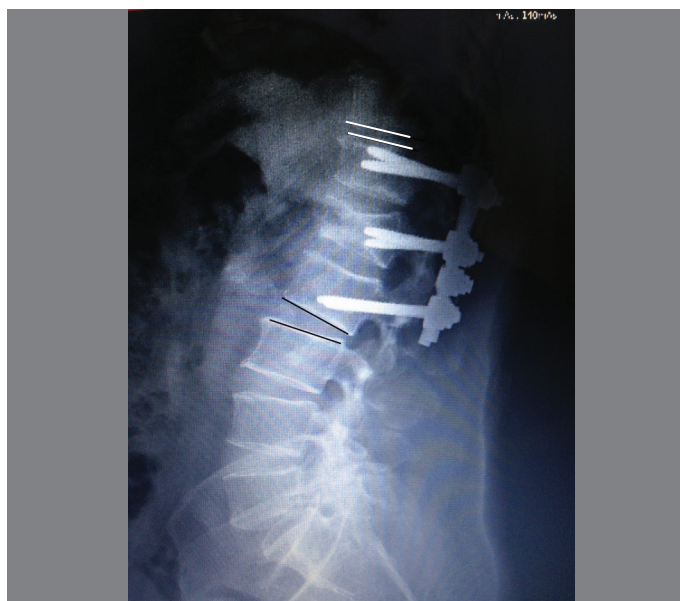

Figure 1. Degeneration of the upper adjacent level following fixation of a thoracolumbar spine fracture.

METHODS

This was an observational, longitudinal, retrospective, case-control, epidemiological study. The study was approved by the Institutional Review Board of the Hospital do Trabalhador – UFPR as number CAAE: 45297815.7.0000.5225. Because it was a retrospective study, the informed consent form was waived.

We evaluated patients who underwent surgical treatment for thoracolumbar spine fracture at the Hospital do Trabalhador-UFPR (HT-UFPR) from January 2009 to December 2013. From among these patients, only those who underwent short fixation with intermediate Schanz-type screws (Exacto® GMReis and USS® Synthes) following the service protocol were included. After one year of postoperative evolution, the practice of the Spine Service of the HT-UFPR, based on the literature,¹³ is to remove the synthesis material if it is already consolidated. The material is removed, since the objective is not the arthrodesis, but the consolidation of the fracture. Other benefits of its removal are to reduce local pain due to its prominence and to prevent breakage of the implant. The patients who were submitted to removal of the material made up the case group. The control group was comprised of the patients who refused to undergo the synthesis material removal procedure or who did not undergo the procedure because of a medical contraindication. Patients less than 10 years of age with surgical fractures of the thoracolumbar spine were excluded, because the intervertebral disc is not yet mature at that age.¹⁴ The patients were evaluated for at least 2 years following the initial surgical procedure with radiographs of the thoracolumbar spine in anteroposterior (AP) and lateral views, in which the levels adjacent to the fracture and the presence of any post-traumatic deformity could be seen. ADD was defined as a reduction in disc height

of 50% compared to the previous radiograph, a criterion established by Booth et al.¹⁵ Post-traumatic deformity was considered to be present when the Cobb Angle measured between the upper plateau of the vertebra above and the lower plateau of the vertebra below was greater than 20° (Figure 2).¹⁶ Vertical translation greater than 4mm was also considered a factor of vertebral segment instability.^{17,18}

We divided the ADD analysis between the thoracic and lumbar segments and each segment was evaluated for statistical significance between the case and control groups.

The linear regression model with mixed effects was the statistical method used. Values of $p < 0.05$ were considered to be statistically significant.

RESULTS

We selected 57 patients who met the inclusion criteria. Of these, 32 had clinical and imageological follow-up and consented to participate in the study. Of these 32 patients, 16 made up the case group (in which the synthesis material was removed after 1 year of follow-up) and 16 made up the control group (patients who had not had the synthesis material removed). Fourteen patients were female and 18 were male, distributed equally between the two groups. Their ages ranged from 15 to 67 years, with an average of 37.5 years of age.

With respect to the adjacent upper disc space, there was no statistically significant difference between the patients who had removed and those who had not removed the material. However, the difference between the measurements of the adjacent upper disc space in the immediate postoperative period, at 1 year, and at 2 years following the fracture were statistically significant and decreased gradually over time ($p < 0.01$) (Figure 3). When we evaluated the patients in both groups, dividing the segments by thoracic and lumbar spine, both showed a decrease of the adjacent upper disc space, regardless of whether or not the synthesis material had been removed (Figure 4).

The Cobb angle increased linearly. There was no statistically significant difference between the postoperative increase in the Cobb angle of the case and control groups. The average Cobb angles 1 and 2 years after surgery were 18.7° and 19.87°, respectively (Figure 5).

There was no statistically significant difference between the case and control groups in terms of vertebral translation. What was different was that in both groups over time there was an increase in the measurements of vertebral translation at 1 and 2 years following surgery of 2.05mm and 2.2mm, respectively (Figure 6).

Care of surgical fractures of the thoracolumbar spine is increasing in our practice¹⁹⁻²¹ and, as a result, studies of ADD and post-traumatic deformity are becoming more important.

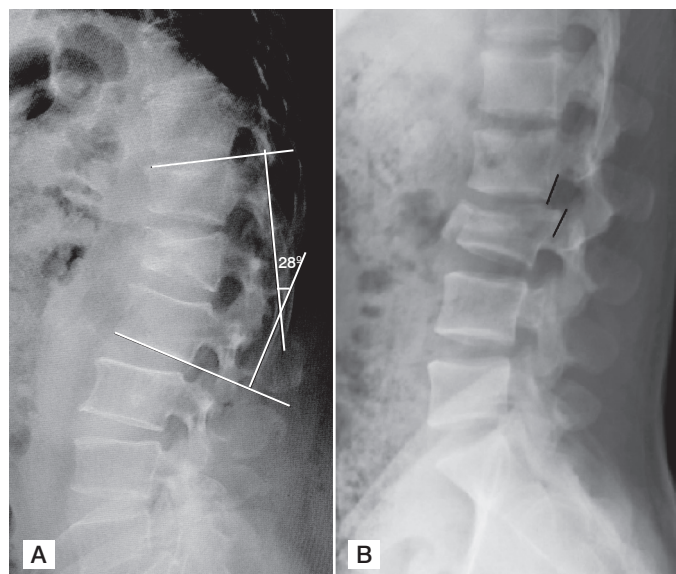


Figure 2. (A) Lateral radiograph showing the Cobb angle, (B) Lateral radiograph showing vertebral translation.

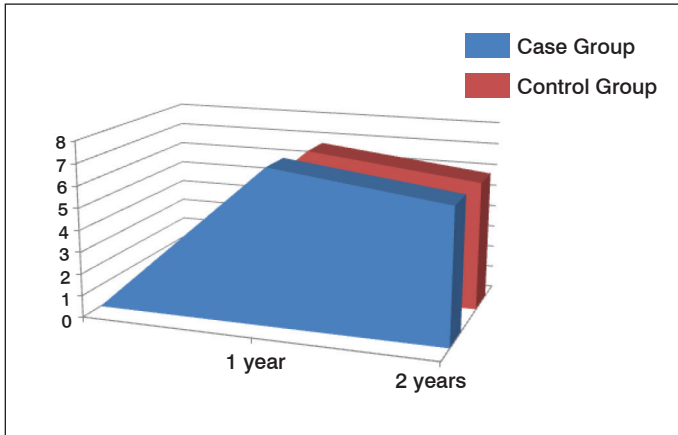


Figure 3. Relationship between the average adjacent upper space and time in the case and control groups.

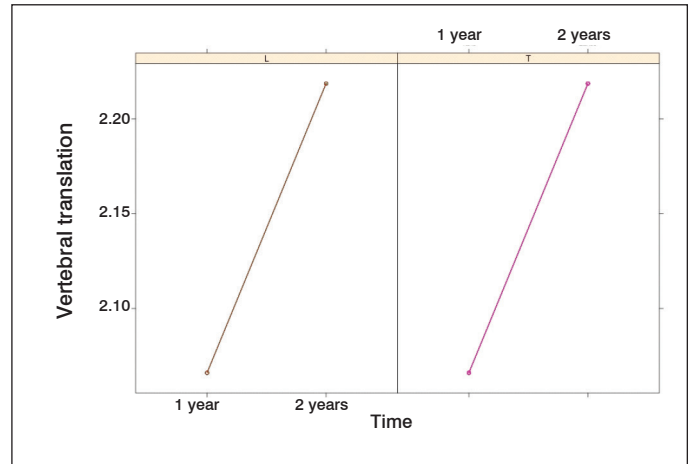


Figure 6. Relationship between time and average vertebral translation for the case and control groups.

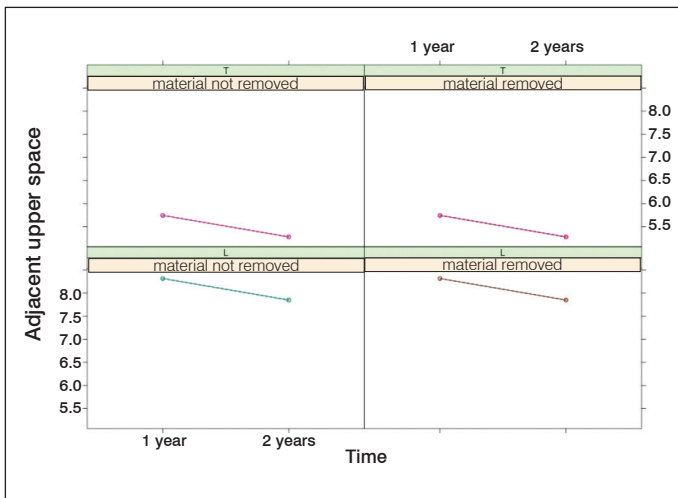


Figure 4. Relationship between the average adjacent upper spaces of the case and control groups, divided into thoracic (T) and lumbar (L) segments.

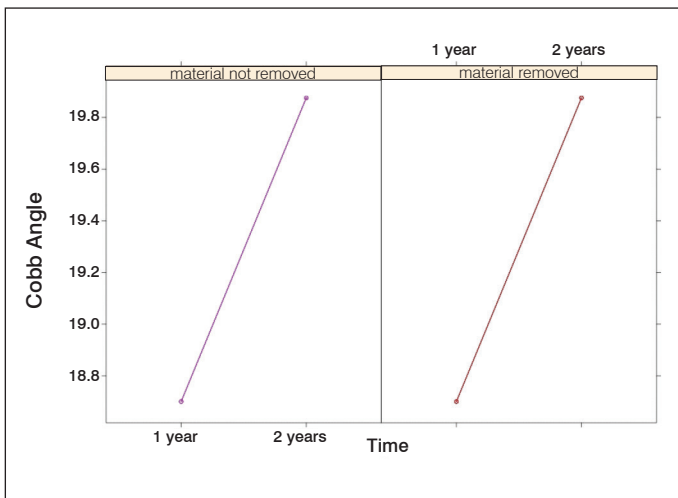


Figure 5. Relationship between the average Cobb angle and time in the case and control groups.

Several authors correlate vertebral arthrodesis surgery with ADD. In the literature, however, there is a lack of information about the association between ADD and vertebral fixation for fractures, followed or not by the removal of the implant material.^{21,22}

Our study shows the statistically significant presence of ADD of the fractured segment both in patients who underwent the removal of the material and those who were not submitted to this procedure. Therefore, the procedure to remove the implant material aimed at preventing ADD was not shown to be effective.

We believed that there would be less degeneration of the upper adjacent disc level in the thoracic segment because of the reduced mobility of this vertebral segment. The results, however, showed the progression of degeneration in the adjacent level to be the same as in the lumbar spine.

The presence of post-traumatic deformity is widely described in the literature.²³ This study showed that the presence of post-traumatic deformity occurs linearly and progressively in patients treated surgically for thoracolumbar fractures with 2-year follow-up. Regardless of whether the synthesis material was removed or not, the study showed that there was statistically significant progression of the Cobb angle. None of the patients, however, experienced progression to the point of causing clinical changes that required a new surgical approach.

The presence of vertebral translation occurred similarly to the progression of ADD and the Cobb angle, once again unrelated to the removal or not of the implant material.

This study evaluated the 2-year follow-up of these patients. New studies with longer follow-ups are necessary in order to evaluate whether an outcome similar to that presented here will be maintained over time.

CONCLUSION

ADD occurred in patients treated surgically for thoracolumbar spine fractures and evolved regardless of whether or not the implant material was removed.

Post-traumatic deformity and vertebral translation also progressed linearly in the two patient groups.

Removal of the synthesis material in order to prevent ADD was not effective. There was no progression of post-traumatic deformity or vertebral translation after removal of the surgical implant.

All authors declare no potential conflict of interest related to this article.

CONTRIBUTION OF THE AUTHORS: Each author made significant individual contributions to this manuscript. ALS: conception of the idea, writing of the article, review of the literature, and patient interviews; ALK: data analysis and writing of the article; MLB: statistical analysis, review of the article; PGS: processing and compilation of the data and review of the literature; XSG: review and intellectual concept of the article, final approval of the version of the manuscript submitted.

REFERENCES

1. Bolesta MJ, Bohlman HH. Late sequelae of thoracolumbar fractures and fracture-dislocations: Surgical treatment. In: Frymoyer JW, editor. *The adult spine: principles and practice*. 2nd ed. Philadelphia: Lippincott-Raven; 1997. p. 1513-33.
2. Keene JS, Lash EG, Kling TF Jr. Undetected posttraumatic instability of "stable" thoracolumbar fractures. *J Orthop Trauma* 1988;2:202-11.
3. Cecchinato R, Berjano P, Damilano M, Lamartina C. Spinal osteotomies to treat post-traumatic thoracolumbar deformity. *Eur J OrthopSurgTraumatol*. 2014;24Suppl 1:S31-7.
4. Park P, Garton HJ, Gala VC, Hoff JT, McGillicuddy JE. Adjacent segment disease after lumbar or lumbosacral fusion: review of the literature. *Spine (Phila Pa 1976)*. 2004;29(17):1938-44.
5. Schlegel JD, Smith JA, Schleusener RL. Lumbar motion segment pathology adjacent to thoracolumbar, lumbar, and lumbosacral fusions. *Spine (Phila Pa 1976)*. 1996;21(8):970-81.
6. Olvera AGR, Arroyo MV, Martínez LMH, Pérez EM, Hinojosa LRR. Adjacent Segment disease in degenerative pathologies with posterior instrumentation. *Coluna/Columna*. 2015;14(1):23-6.
7. Duggal N, Mediondo I, Pares HR, Jhawah BS, Das K, Kenny KJ, et al. Anterior lumbar interbody fusion for treatment of failed back surgery syndrome: an outcome analysis. *Neurosurgery*. 2004; 54(3):636-43.
8. Aota Y, Kumano K, Hirabayashi S. Postfusion instability at the adjacent segments after rigid pedicle screw fixation for degenerative lumbar spinal disorders. *J Spinal Disord*. 1995;8(6):464-73.
9. Guigui P, Lambert P, Lassale B, Deburge A. Long-term outcome at adjacent levels of lumbar arthrodesis. *Rev Chir Orthop Reparatrice Appar Mot*. 1997;83(8):685-96.
10. Miyakoshi N, Abe E, Shimada Y, Okuyama K, Suzuki T, Sato K. Outcome of one-level posterior lumbar interbody fusion for spondylolisthesis and postoperative intervertebral disc degeneration adjacent to the fusion. *Spine (Phila Pa 1976)*. 2000;25(14):1837-42.
11. Cheh G, Bridwell KH, Lenke LG, Buchowski JM, Daubs MD, Kim Y, et al. Adjacent segment disease following lumbar/thoracolumbar fusion with pedicle screw instrumentation: a minimum 5-year follow-up. *Spine (Phila Pa 1976)*. 2007;32(20):2253-7.
12. Ghiselli G, Wang JC, Bhatia NN, Hsu WK, Dawson EG. Adjacent segment degeneration in the lumbar spine. *J Bone Joint Surg Am*. 2004;86(7):1497-503.
13. Baron HC, Ochs BG, Stuby FM, Stöckle U, Badke A. Hardware removal after spinal instrumentation. *Unfallchirurg*. 2012;115(4):339-42.
14. Scott JE, Bosworth TR, Cribb AM, Taylor JR. The chemical morphology of age-related changes in human intervertebral disc glycosaminoglycans from cervical, thoracic and lumbar nucleus pulposus and annulus fibrosus. *J Anat*. 1994;184 (Pt 1):73-82.
15. Booth KC, Bridwell KH, Eisenberg BA, Baldus CR, Lenke LG. Minimum 5-year results of degenerative spondylolisthesis treated with decompression and instrumented posterior fusion. *Spine (Phila Pa 1976)*. 1999;24(16):1721-7.
16. Buchowski JM, Kuhns CA, Bridwell KH, Lenke LG. Surgical management of posttraumatic thoracolumbar kyphosis. *Spine J*. 2008;8(4):666-77.
17. Gillet P. The fate of the adjacent motion segments after lumbar fusion. *J Spinal Disord Tech*. 2003;16(4):338-45.
18. Hazlett JW, Kinnard P. Lumbar apophyseal process excision and spinal instability. *Spine (Phila Pa 1976)*. 1982;7(2):171-6.
19. Zaninelli EM, Graells XSI, Néri OJ, Dau L. Avaliação epidemiológica das fraturas da coluna torácica e lombar de pacientes atendidos no Pronto-Socorro do Hospital do Trabalhador da UFPR de Curitiba - Paraná. *Coluna/Columna*. 2005;4(1):11-5.
20. Graells XSI, Telesca MP, Zaninelli EM, Benato ML. Tratamento das fraturas tóraco-lombares com o uso de fixador interno: análise de 110 pacientes. *Coluna/Columna*. 2008;7(2):119-24.
21. Dekutoski MB, Schendel MJ, Ogilvie JW, Olsewski JM, Wallace LJ, Lewis JL. Comparison of in vivo and in vitro adjacent segment motion after lumbar fusion. *Spine (Phila Pa 1976)*. 1994;19(15):1745-51.
22. Weinshoffer SL, Guyer RD, Herbert M, Griffith SL. Intradiscal pressure measurements above an instrumented fusion. A cadaveric study. *Spine (Phila Pa 1976)*. 1995;20(5):526-31.
23. Vaccaro AR, Silber JS. Post-traumatic spinal deformity. *Spine (Phila Pa 1976)*. 2001;26(24 Suppl):S111-8.