

# SURGICAL TREATMENT OF SPINAL TUBERCULOSIS BY ANTERIOR APPROACH

TRATAMENTO CIRÚRGICO DA TUBERCULOSE DA COLUNA VERTEBRAL POR VIA ANTERIOR

TRATAMIENTO QUIRÚRGICO DE LA ENFERMEDAD DE POTT POR VÍA ANTERIOR

ELIO RAMÍREZ<sup>1</sup>, MARCELO OCHOA<sup>1</sup>, FAUSTO ORDOÑEZ<sup>1</sup>

## ABSTRACT

**Objective:** To evaluate the correction of kyphotic deformity, stability and fusion promoted by titanium implants (Synex - Ventrofix Synthes) in spinal tuberculosis. **Methods:** Between January 2010 and August 2012, eight patients with a diagnosis of vertebral tuberculosis underwent surgery by anterior approach, with follow-up of 18 months. The procedure consisted of wide debridement of the affected body, followed by instrumentation with titanium implants (Synex - Ventrofix Synthes) and rib autograft. The indication for surgery was neurological deficit and kyphosis of the segment. Previously, patients received tuberculosis treatment for three weeks. Imaging studies before and after surgery, as frontal and lateral radiographs, evaluated the kyphosis. Fusion was assessed by postoperative simple CT. Magnetic resonance imaging was performed preoperatively. Besides imaging, the following tests were made: complete blood count, erythrocyte sedimentation rate (ESR), C-reactive protein (CRP) and microbiological examination of urine and sputum smear, sputum or urine culture. **Results:** Eight patients were operated by anterior approach, five males with a mean age of 37.2 years and three women mean age of 56.3 years. All patients had neurological deficit. Six had incomplete lesions and had some degree of neurological improvement. Two paraplegics did not recover neurological function. The average preoperative kyphosis was 14.38 degrees and postoperative 6.8 degrees. There was no significant loss of correction or disease recurrence. **Conclusion:** The anterior instrumentation is an effective method to treat spinal tuberculosis, while avoiding the progression of kyphosis or promotes kyphosis correction.

**Keywords:** Tuberculosis spinal; Spinal fusion; Prostheses and implants; Arthrodesis.

## RESUMO

**Objetivo:** Avaliar a correção da deformidade cifótica, a estabilidade e a fusão promovida por implantes de titânio (Synex – Ventrofix de Synthes) na tuberculose da coluna vertebral. **Métodos:** Entre janeiro de 2010 e agosto de 2012, oito pacientes com diagnóstico de tuberculose de coluna foram submetidos à intervenção cirúrgica por acesso anterior, com acompanhamento de 18 meses. O procedimento consistiu em desbridamento amplo do corpo afetado, seguido por instrumentação com implantes de titânio (Synex – Ventrofix de Synthes) e autoenxerto de costela. A indicação cirúrgica foi déficit neurológico e cifose do segmento. Previamente, os pacientes receberam tratamento para tuberculose por três semanas. Os estudos por imagem antes e depois da cirurgia, como radiografia frontal e lateral, avaliaram a cifose. A fusão foi avaliada por tomografia simples pós-operatória. A ressonância magnética foi realizada no pré-operatório. Além dos exames de imagem, foram feitos os seguintes testes: hemograma completo, velocidade de sedimentação globular (VSG), proteína C reativa (PCR) e exames microbiológicos de baciloscopia na urina e no catarro, cultura da expectoração ou de urina. **Resultados:** Oito pacientes foram operados por acesso anterior, sendo cinco homens com média de idade de 37,2 anos e três mulheres média de idade de 56,3 anos. Todos os pacientes tinham déficit neurológico. Seis deles com lesões incompletas tiveram melhora de algum grau neurológico. Dois paraplégicos não recuperaram a função neurológica. A média da cifose pré-operatória foi 14,38 graus e pós-operatória, 6,8 graus. Não houve perda significativa de correção nem recorrência da doença. **Conclusão:** O acesso anterior com instrumentação é um método eficaz para tratar tuberculose vertebral, ao mesmo tempo em que evita a progressão da cifose ou a corrige.

**Descritores:** Tuberculose da coluna vertebral; Fusão vertebral; Próteses e implantes; Artrodese.

## RESUMEN

**Objetivo:** Evaluar la corrección de la deformidad cifótica, estabilidad y fusión que otorga la utilización de implantes de titanio (Synex – Ventrofix de Synthes) en la tuberculosis espinal. **Métodos:** Entre enero de 2010 y agosto de 2012 ocho pacientes con diagnóstico de enfermedad del Pott se sometieron a intervención quirúrgica por vía anterior, con seguimiento de 18 meses. El procedimiento consistió en desbridamiento amplio del cuerpo afectado seguido de instrumentación con implantes de titanio (Synex – Ventrofix de Synthes) y autoinjerto de costilla. La indicación quirúrgica fue déficit neurológico y cifosis del segmento. Previamente recibieron tratamiento anti-tuberculoso por tres semanas. Estudios de imagen como radiografía frente y perfil pre operatoria y post operatoria evaluaron la cifosis. La tomografía simple post operatoria evaluó la fusión. En el preoperatorio se realizó resonancia magnética. Además de las pruebas de imagen, se realizaron las siguientes pruebas: biometría hemática, velocidad de sedimentación globular (VSG), proteína C reactiva (PCR) y las pruebas microbiológicas baciloscopia en orina y esputo, cultivo de expectoración o de orina. **Resultados:** Ocho pacientes se operaron a través de abordaje anterior, siendo cinco hombres con edad promedio de 37,2 años y tres mujeres con edad promedio de 56,3 años. Todos los pacientes presentaron déficit neurológico. Seis con lesiones incompletas mejoraron algún grado neurológico. Dos paraplégicos no recuperaron la función neurológica. Cifosis preoperatoria promedio 14,38 grados y postoperatoria 6,8 grados. No hubo pérdida significativa de corrección ni recurrencia de la enfermedad. **Conclusión:** El abordaje anterior más instrumentación es un método eficaz para tratar infección tuberculosa vertebral al mismo tiempo de evitar la progresión o corregir la cifosis.

**Descriptores:** Tuberculosis de la columna vertebral; Fusión vertebral; Prótesis e implantes; Artrodosis.

1. Orthopedic and Traumatology Department of the Hospital Eugenio Espejo de Quito, Ecuador.

Study conducted at the Orthopedics and Traumatology Department of the Hospital Eugenio Espejo de Quito, Ecuador.  
Correspondence: Rua Avenue Gran Colombia, s/n. Quito, Ecuador. elioramirezhsr@gmail.com

## INTRODUCTION

Tuberculosis is a systemic granulomatous disease caused by the bacillus *Mycobacterium tuberculosis* and in rare cases, by another agent such as *M. bovis*. Each year, 8 to 10 million new cases of tuberculosis are reported worldwide, and about 3 million die from the disease. Twenty million are active and one third of the world population has been exposed to tuberculosis bacillus (TB). According to the World Health Organization, tuberculosis is the primary cause of death by an infectious agent.<sup>1</sup> Tuberculosis remains endemic in developing countries. There has been a resurgence in immunosuppressed patients (for example, AIDS and chemotherapy patients). In North America, tuberculosis is common in prison populations and among intravenous drug users. Percival Pott was the first to describe spinal tuberculosis in 1779, hence it is known as Pott's disease, accounting for between 1 and 2% of the 400 million cases of tuberculosis worldwide.<sup>2</sup> Spinal tuberculosis is the most severe presentation of those that compromise the musculoskeletal system, and can occur in up to 50% of cases. Neurological disorders are reported in between 10 and 47% of cases.<sup>3</sup> Kyphotic deformity is often present.<sup>4</sup> Surgical indications are severe pain from expansive abscesses, neurological deterioration from compression of the spinal cord, bone and disc sequestration, progressive kyphotic deformity, and instability. The surgical goal is to eradicate infection, prevent or treat the neurological deficit, and correct the spinal deformity.<sup>5</sup> Fusion and posterior instrumentation without anterior debridement fails to stabilize the spine and does not completely control the progression of kyphotic deformity.<sup>5</sup> Combined anterior and posterior approaches increase morbidity and mortality, especially in elderly patients and those in poor health.<sup>6</sup>

Anterior debridement and fusion is the classical surgical treatment for Pott's disease and was popularized by Hodgson et al.<sup>7</sup> and Hsu et al.<sup>8</sup>

We describe eight cases of spinal tuberculosis treated surgically by the anterior approach.

## MATERIAL AND METHODS

Thirteen patients diagnosed with Pott's disease were admitted to the Orthopedics and Traumatology Department of the Hospital Eugenio Espejo in Quito, Ecuador, between January and August 2012. Four patients indicated for surgery did not undergo the procedure due to the lack of availability of implants. One refused surgery. In eight patients, surgery was performed by the anterior approach in a single operation. The procedure consisted of ample debridement of the affected body followed by instrumentation with titanium implants (Synex-Ventrofix from Synthes) and a rib autograft. The surgical indication was neurological deficit and kyphosis of the segment. All patients were operated on by the team of surgeons. The follow-up period was 18 months.

### Preoperative evaluation

Preoperative pharmacological treatment for three weeks. Antituberculosis drugs were administered in the eight cases: isoniazid (5mg/Kg); rifampicin (10mg/Kg); ethambutol (15mg/kg); pirazinamide (25mg/kg).

Five men (62.5 %) and three women (37.5 %). The average age was 51.63 years (R = 32 – 67).

Levels affected: Thoracic spine T8-T9, one case; thoracolumbar segment: T12, three cases; L1, one case; T12-L1, 2 cases; lumbar spine L3, one case. The average preoperative kyphosis was 14.38 degrees (R = 10 - 18). The average erythrocyte sedimentation rate was 30 mm/hr (R = 17 – 44). The average time from the onset of symptoms was 11.50 months (6-20 months).

The neurological state was assessed using the Frankel scale: A, two cases; B, one case; C, two cases; D, three cases.

Surgical technique: Under general anesthesia with the patient in right lateral decubitus propped on two pillows, one proximal and the other distal, at the level of the iliac crests and crossing

the table at 30 degrees to the thoracolumbar level. Level control with fluoroscopy. A transpleural posterolateral thoracostomy was performed to the thoracic spine. A thoracophrenotomy was performed in the thoracolumbar hinge and in the lumbar spine via the retroperitoneal approach. We should mention that our approaches are supported by thoracic and abdominal surgeons. Corpectomy and adjacent discectomies should be performed to enable the removal of infected tissue, leaving the vertebral plates bleeding. Decompression of the anterior side of the spinal cord or medullary cone was performed in all cases where there was neurological deficit. We used titanium implants (Synex-Ventrofix, Synthes) in the instrumentation, filling the cylinder with chips of autograft obtained from the rib above the affected level. We then applied maneuvers to correct the kyphosis, pressing the spine from the posterior side and distracting the vertebral plates and we introduced the implant as the technique demanded, applying compression to keep it firm. Finally, we added interbody screws to the stabilization in the vertebrae above and below the defect, connected by a rod to give greater rigidity to the instrumentation. For the thoracostomy and thoracophrenotomy approaches, a chest tube was left. The tissues obtained were sent for histopathological study.

### Postoperative

In cases of thoracic and thoracophrenic approach, the chest tube was left for an average of four days. Patients were able to sit up on the second day and are allowed to walk with the aid of walker at six days. Radiological and tomographical controls were performed at three, six, and twelve months.

Antituberculosis drug therapy continued for between 3 and 6 months. No patient required orthosis.

Eight men and five women from 32 to 67 years of age, with an average age of 51.63 years.

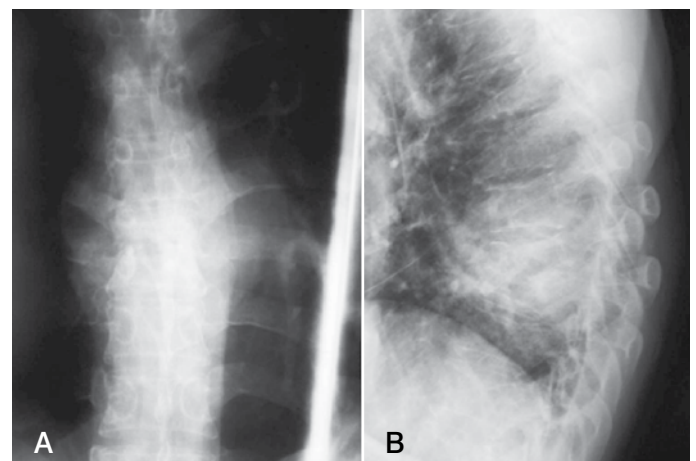
We used the clinical histories of each patient requested from the statistics department.

The inclusion criteria were patients older than years of age and younger than 67, of both sexes, with clinical and radiographic evidence of spinal cord compression, instability, and spinal kyphosis.

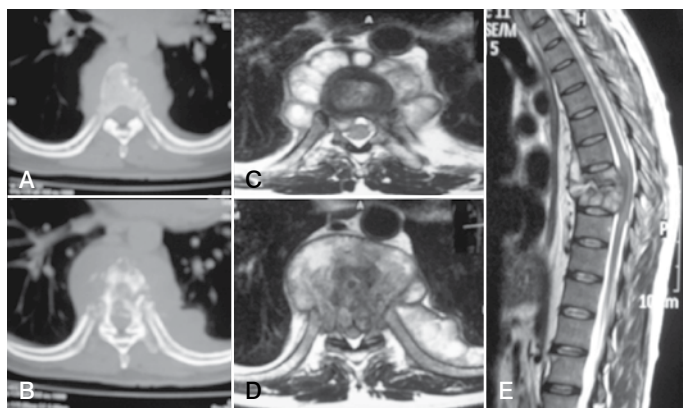
AFB investigation: in urine and expectoration. When it exists: positive values - one cross (+), from 6 to 9 bacilli per field; two crosses (++) , from 12 to 26 bacilli per field; three crosses (+++) more than 26 bacilli per field.<sup>1,9</sup>

Lowenstein Jensen culture: performed by sampling an abscess, obtained during surgery of the Pott's disease focus.

Radiographs generally provide enough information for a diagnosis, but CAT and MRI results are better options for early diagnosis. (Figures 1 and 2)



**Figure 1.** Patient, 44 years of age, with severe thoracolumbar pain, spastic paraplegia, HIV positive. A) Simple AP x-ray of the dorsal spine, showing the destruction of the vertebral body of T8 and T9. B) Simple lateral x-ray showing the collapse of vertebral bodies T8 and T9.



**Figure 2.** (A-B): Axial section of simple CAT scan showing a lytic bone lesion in the vertebral body. (C-D): Axial section of a simple MRI showing compromise of thoracic spinal body T8 and T9 with an extensive mass extending in front of and behind the spinal channel. (E): sagittal section of the MRI showing destructive lesion in T8 and T9, with a large and extensive mass causing compression of the spinal cord. Note the relative preservation of the discs at this stage of the disease, often the case with tuberculosis versus pyogenic spondylitis.

Eight patients underwent surgical intervention using titanium implants such as Synex and Ventrofix. Four patients were not operated on due to the unavailability of materials. One patient asked to be discharged.

#### Medical treatment

All our patients presented neurological compromise. Antituberculosis medical treatment was administered 3 weeks prior to surgery. (Table 1)

Preoperative evaluation: heart and lung exams, CBC and blood chemistry, coagulation profile, urinalysis. Antituberculosis therapy must be followed for 12 months after surgery.<sup>1,11</sup>

Surgical treatment: indications for surgery are: the presence of neurological deficit, spinal collapse, kyphotic deformity of more than 5°, compression of the dural sac by granulation tissue, sequestered bone, discal fragments, and epidural abscess.

Surgical technique: patient in right lateral decubitus, incision at the level of the eighth left intercostal space, approach performed by the cardiothoracic physician on thoracic spinal injuries of the second lumbar vertebra. For low lumbar spinal injuries the approach was performed by the general surgeon with a left anterolateral and retroperitoneal incision.

*Corpectomy, Synex, Ventrofix, autologous bone graft:* with this technique, cleaning of the focus of the Pott's disease or the corpectomy of the affected vertebra(e) is performed, achieving decompression of the dural sac, respecting the posterior arch. The extracted tissue is sent for culture and histopathology.

The previously measured Synex is then inserted, distracting the implant until is anchored in the vertebral platforms; the bone autograft placed inside the Synex can be extracted from the iliac crest or the rib.

For placement of Ventrofix, the screws are anchored in non-damaged vertebrae. This technique must be performed very carefully so as not to damage neighboring structures, which could even lead to death of the patient.

**Table 1.** Antituberculosis medication.

Drug	Dose/kilo of weight	Presentation
a) isoniazid (INH)	5 mg/kg of weight daily	100 mg, 3 times daily
b) rifampicin (RFP)	10 mg/kg of weight daily	300 mg, 2 times daily (fasting)
c) pirazinamide (PZA)	25 mg/kg of weight daily	500 mg, 3 times daily
d) ethambutol (ETB)	20 mg/kg of weight daily	400 mg, 3 times daily

## RESULTS

Eight men and five women who represent 62.5% and 37.5%, respectively. Their average age was 51.63 years with ages ranging from 32 to 67 years. All the patients presented neurological deficit, six with progressive paraparesis, two with spastic and flaccid paraplegia, and pain of moderate to severe intensity accompanied by muscular spasms in the limbs, shoulders, and abdomen.

The damaged levels were T8-T9 in n=1, L1 in n=1, L3 in n=1, T12 in n=2, and T12-L1 in n=3. (Table 2)

The polymerase chain reaction (PCR) and erythrocyte sedimentation rate (ESR) were performed in all patients, presenting elevated values. In eight patients, transsurgical biopsies tested positive for tuberculosis. Positive Lowenstein culture.

Bacilloscopy in the 13 patients for the investigation of serial AFB in sputum and urine, four negative patients, seven positive patients (+++), and two positive patients (++).

Clinically, moderate pain in five patients and mild pain in three patients following surgery for up to two months; mild pain for up to six months in six patients and mild postoperative pain persisting for more than 12 months in only one patient.

In the eight patients, no loosening of the implants was noted, with good graft osseointegration and no problems of recurrence of the disease through May 2012. These patients continue to be the focus of control and study.

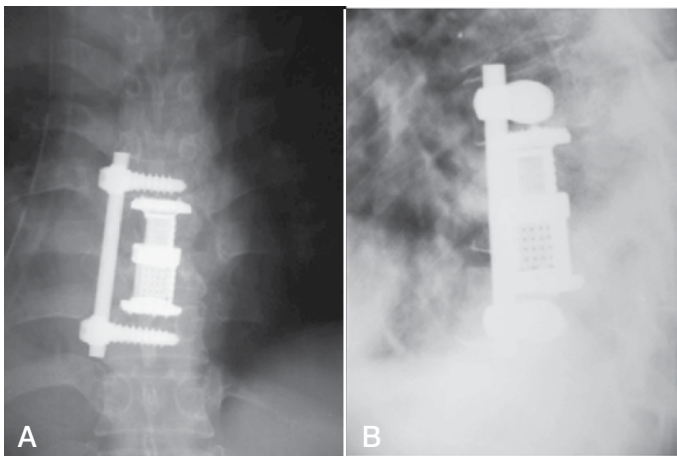
Presurgical kyphosis: measured between 10° and 18°, with an average of 14.38° (±3.33), correction of between approximately 2° and 10° was achieved in the immediate postoperative period with an average of 6.88 (±2.7). (Figure 3)

The average surgical time was 222.5 minutes (180-300). Intraoperative bleeding averaged 391.25 cc (±49.69).

Neurological deficit of the 13 patients: two presented paraplegia, one of the spastic type and the other of the irreversible flaccid type, although one who underwent surgical intervention did not improve during 3 months of follow-up; 11 patients presented paraparesis of the lower limbs; seven had improved neurological deficit following surgery. The neurology of three patients who did not undergo surgery did not improve and one patient who requested a discharge was not able to continue in follow-up.

**Table 2.** The damaged levels.

	Sex	Age	DG	Level affected	Neurological disorder	Onset of symptoms	Instrumentation
1	Man	44	Pott's disease	T12 L1	Spastic paraplegia	8 months	anterior (cylinder and screw)
2	Man	32	Pott's disease	L1	Progressive paraparesis	6 months	
3	Man	28	Pott's disease	T8 T9	Progressive paraparesis	18 months	anterior (cylinder and screw)
4	Man	45	Pott's disease	T12	Progressive paraparesis	8 months	anterior (cylinder and screw)
5	Man	52	Pott's disease	T2	Flaccid paraplegia	12 months	
6	Man	17	Pott's disease	T12	Progressive paraparesis	4 months	anterior (cylinder and screw)
7	Man	52	Pott's disease	L3	Progressive paraparesis	12 months	anterior (cylinder and screw)
8	Man	55	Pott's disease	L2	Progressive paraparesis	6 months	
9	Woman	67	Pott's disease	L1	Progressive paraparesis	10 months	anterior (cylinder and screw)
10	Woman	44	Pott's disease	T12 L1	Progressive paraparesis	10 months	anterior (cylinder and screw)
11	Woman	38	Pott's disease	L4	Progressive paraparesis	8 months	
12	Woman	58	Pott's disease	T12	Progressive paraparesis	6 months	anterior (cylinder and screw)
13	Woman	60	Pott's disease	L1	Progressive paraparesis	6 months	



**Figure 3.** A) Simple posterior anterior chest x-ray, where the implant can be seen at the level of T8 and T9, the vertebrae that were previously dried out. B): Simple lateral x-ray of the thorax, with implant anchored at T7 and T10, correcting the kyphosis presented by the patient.

### Evolution

There were no transoperative or immediate postoperative complications. Physical therapy began immediately after surgery. Post-surgical neurology showed significant improvement in seven patients. One patient continued to have mild pain for around one year.

There was no reactivation of the disease and/or loosening of the implant during the 2-year study and we will follow up on it to observe any complications that might occur in the future.

### DISCUSSION

Spinal tuberculosis is a disease that causes complications such as neurological compromise, kyphotic deformity secondary to vertebral fracture, and instability of the spine.<sup>12</sup>

Today, there are immunological tests with high specificity and sensitivity for the detection of tuberculosis bacillus, but they are not available to all patients due to the extremely high cost.

As regards imaging studies, simple radiographs help us to evaluate spinal stability, paravertebral abscesses, and kyphotic angle. CAT scans assess the invasion of the infection into the body and the spinal channel. MRIs show invasion into adjacent bodies and soft tissue compromise.<sup>10,11</sup>

Medical treatment must be administered for at least 12 months.<sup>1,3</sup> Surgery included corpectomy, placement of the titanium cylinder, rod and screws, ventrofix, and bone graft when there was compromise of the vertebral body and progressive neurological compromise. Treatment with antituberculosis medications for three weeks prior to surgery.

The type of treatment performed at the Hospital Eugenio Espejo gave us excellent results and we will continue with the study, including new cases in the future.

In regards to pain and correction of kyphosis, spinal stability was practically achieved using the implant and arthrodesis, in addition to the neurological improvement presented by the patients.

---

All authors declare no potential conflict of interest concerning this article.

---

### REFERENCE

- González DT, López JG, Meave JAP, Beltrán LG, Gómez DM, Villareal JRB Mal de Pott. Diagnóstico y tratamiento del paciente. *Rev Hosp Jua Mex.* 2006;73(3):96-100.
- Pappou IP, Papadopoulos EC, Swanson AN, Mermer MJ, Fantini GA, Urban MK, et al. Pott disease in the thoracolumbar spine with marked kyphosis and progressive paraplegia necessitating posterior vertebral column resection and anterior reconstruction with a cage. *Spine (Phila Pa 1976).* 2006;31(4):E123-7.
- Dobson J. Tuberculosis of the spine; an analysis of the results of conservative treatment and of the factors influencing the prognosis. *J Bone Joint Surg Br.* 1951;33(4):517-31.
- Al-Sebai MW, Al-Khawashki H, Al-Arabi K, Khan F. Operative treatment of progressive deformity in spinal tuberculosis. *Int Orthop.* 2001;25(5):322-5.
- Hodgson AR, Stokes FE. Anterior spinal fusion for the treatment of tuberculosis of the spine: the operative findings and results of treatment in the first one hundred cases. *J Bone Joint Surg Am.* 1960;42:295-310.
- Hirakawa A, Miyamoto K, Masuda T, Fukuta S, Hosoe H, Iinuma N, et al. Surgical outcome of 2-stage (posterior and anterior) surgical treatment using spinal instrumentation for tuberculous spondylitis. *J Spinal Disord Tech.* 2010;23(2):133-8.
- Hodgson AR, Stock FE, Fang HS, Ong GB. Anterior spinal fusion. The operative approach and pathological findings in 412 patients with Pott's disease of the spine. *Br J Surg.* 1960;48:172-8.
- Hsu LCS, Leong JCY. Tuberculosis of the spine. In: Everts CM, editor. *Surgery of the Musculoskeletal System.* New York: Churchill Livingstone; 1990. p. 299-314.
- Güzey FK, Emel E, Bas NS, Hacısalihoglu S, Seyithanoglu MH, Karacor SE, et al. Thoracic and lumbar tuberculous spondylitis treated by posterior debridement, graft placement, and instrumentation: a retrospective analysis in 19 cases. *J Neurosurg Spine.* 2005;3(6):450-8.
- Raviglione MC, Snider DE Jr, Kochi A. Global epidemiology of tuberculosis. Morbidity and mortality of a worldwide epidemic. *JAMA.* 1995;273(3):220-6.
- Goel MK. Treatment of Pott's paraplegia by operation. *J Bone Joint Surg Br.* 1967;49(4):674-81.
- Babhulkar SS, Tayade WB, Babhulkar SK. Atypical spinal tuberculosis. *J Bone Joint Surg Br.* 1984 Mar;66(2):239-42.