

Histopathology from liver of *tuvira* (*Gymnotus* spp.) parasitized by larvae of nematodes

Histopatologia de fígado de *tuvira* parasitado por larvas de nematoides

Arlene Sobrinho Ventura^I Márcia Mayumi Ishikawa^{II} Andrea Maria de Araújo Gabriel^{III}
Helcy Lylian Nogueira Silbiger^{IV} Fabiana Cavichiolo^{III} Ricardo Massato Takemoto^V

ABSTRACT

The aim of this study was to evaluate the histological changes in the liver of thirty-five *Gymnotus* spp. parasitized by endohelminths collected between April 2012 to October 2013 in commercial bait fish farming of Pantanal basin. Histological cuts of 7µm were stained with hematoxylin-eosin for parasites research and liver changes and have also been submitted to the Perls histochemical method for evaluation of hemosiderosis (Fe⁺⁺⁺) based on the incidence degree and severity of change (Grade I, II and III) and tests for the presence of central melanomacrophages. Parasites identified were: *Brevimulticaecum* sp. with a prevalence of 22,9%, *Eustrongylides* sp 17,1%, *Contracaecum* type I 68,7%, *Contracaecum* type II 5,7%, *Contracaecum* type III 5,7% and larvae of *Anisakidae* 11,4%. Histological analysis showed intense disorganization of hepatic parenchyma with degenerate hepatocytes due to high parasitic infection, changes that can be deleterious and compromise the organism functioning, being harmful to the health of evaluated animals. Also evidencing normal tissue interleaved with different stages of Fe⁺⁺⁺ deposit in grades II and III, injuring or destroying the cell. Histopathological changes in the *tuvira*'s liver suggested a chronic response and the development of a balance relation between *tuvira* and parasitism by endohelminth identified in this study. There are also a testimony to the health condition of commercial bait fish farming on current ecosystem conditions.

Key words: hepatic histopathology, parasitology, commercial bait fish farming, *Anisakidae*, *Gymnotus* spp.

RESUMO

O objetivo deste estudo foi avaliar as alterações histológicas do fígado de trinta e cinco *Gymnotus* spp. parasitados por endohelminthos, coletados entre abril de 2012

a outubro de 2013, em isqueiros da bacia do Pantanal. Cortes histológicos de 7µm foram corados com hematoxilina-eosina para pesquisa de parasitos e de alterações hepáticas; também foram submetidos ao método histoquímico de Perls para avaliação de hemosiderose (Fe⁺⁺⁺) com base no grau de incidência e severidade da alteração (Grau I, II e III) e pesquisa da presença de centro de melanomacrófagos. Os parasitos identificados foram: *Brevimulticaecum* sp., com prevalência de 22,9%, *Eustrongylides* sp. 17,1%, *Contracaecum* tipo I 68,7%, *Contracaecum* tipo II 5,7%, *Contracaecum* tipo III 5,7% e larvas de *Anisakidae* 11,4%. A análise histológica revelou intensa desorganização do parênquima hepático, com hepatócitos degenerados devido à alta infecção parasitária. Essas alterações podem ser deletérias e comprometer o funcionamento do organismo, sendo prejudicial à saúde dos animais avaliados; também evidenciou tecido normal intercalado com estágios diferenciados de depósito de Fe⁺⁺⁺ nos Graus II e III, podendo lesionar ou destruir a célula. As alterações histopatológicas do fígado das *tuviras* sugerem uma resposta crônica e o desenvolvimento de uma relação de equilíbrio entre a *tuvira* e o parasitismo pelos endohelminthos identificados neste estudo. Elas também são um testemunho da condição de saúde dos peixes dos isqueiros nas condições atuais do ecossistema.

Palavras-chave: histopatologia hepática, parasitologia, isqueiros, *Anisakidae*, *Gymnotus* spp.

INTRODUCTION

The *tuvira* (*Gymnotus* spp.), also called “sarapó”, swordfish, “carapó” and “itui” belongs to the same electric fish family. Its occurrence in the Pantanal river basin is in lentic environments with

^IUniversidade Estadual de Mato Grosso do Sul (UEMS), Dourados, MS, Brasil.

^{II}Embrapa Meio Ambiente, Rod. SP 340, km 127,5, CP 69, 13820-000, Jaguariúna, SP, Brasil. E-mail: marcia.ishikawa@embrapa.br. Corresponding author.

^{III}Universidade Federal da Grande Dourados (UFGD), Dourados, MS, Brasil.

^{IV}Universidade de São Paulo (USP), São Paulo, SP, Brasil.

^VUniversidade Estadual de Maringá (UEM), Maringá, PR, Brasil.

turbid water and aquatic vegetation rich in organic matter from flooding where it's their refuge and they can find food (ROTTA, 2004).

According to BARBIERI & BARBIERI (1983ab, 1984) the average size of tuvira's first gonadal maturation can be set between 24,8cm and 25,6cm, reaching maximum average length of 54,6cm. Stands out as live bait to be part of several species feed diet like the piscivorous species fish such as "dourado" *Salminus brasiliensis* and "surubins" *Pseudoplatystoma* sp. (PEREIRA & RESENDE, 2006).

Nematodes of the *Anisakidae* family (RAILLET & HENRY, 1912) and Acanthocheilidae (WULKER, 1929), have been recorded in several species of fishes (REGO, 1979; MORAVEC et al., 1997; ISAAC et al., 2004; PAVANELLI et al., 2004; MARTINS et al., 2005; 2009; GUIDELLI et al., 2006; BARROS et al., 2007; 2009; LACERDA et al., 2008; VICENTIN et al., 2011). Are characterized by being parasites that have heteroxenous cycle with its transmission involving fish, aquatic invertebrates as well as molluscs and crustaceans as intermediary hosts parathenic or definitive (ANDERSON, 2000).

The constant capture *Gymnotoideos* reduced the number of specimens of this species in the natural environment, so the captive production can be an alternative for the local population, and reduce the capture of pressure on the natural environment (MORAES & ESPINOZA, 2001). However, studies on the endoparasite fauna that affects the tuvira in confined environment, demonstrate that the parasites have limited its creation (ISHIKAWA et al., 2014).

Several studies have described the prevalence of parasites in this species (ISSAC et al., 2004; TAKEMOTO et al, 2009); however, there are no studies reporting the disease caused due to infection by these parasites. Due to the wide use of *Gymnotus* spp. as commercial bait fish farming becomes necessary to investigate the parasitic fauna of this species. It is important to know the hygiene and health conditions, and ambient water quality which is the creation of commercial baitfish farming, since the parasite may be related to cultivation environment.

The aim of this study was to evaluate the pathological changes in *Gymnotus* spp. liver caused by endohelminth.

MATERIALS AND METHODS

A total of 35 tuviras (*Gymnotus* spp.) were collected from different commercial bait fish farming (19°00'25.78"S, 57°39'04.63"O; 21°55'44.35"S, 54°34'54.98"O; 21°00'30.92"S, 57°16'51.51"O;

22°08'06.04"S, 53°37'20.58"O) between April 2012 to October 2013, in the Pantanal basin in Mato Grosso do Sul, Brazil. Specimens were transported to Laboratory of Embrapa Agropecuária Oeste and euthanized by means of deep anesthesia with clove oil (150mg L⁻¹). The clove oil (WNF Ind. and Com. Ltda, São Paulo - SP) was obtained in natural food store and due to its oily nature, a stock solution was prepared in the proportion of 1 g of oil to 10ml absolute alcohol or alcohol 95° (1g 10mL⁻¹) (VIDAL et al., 2006). The stock solution calculations were made to obtain the concentration of 150mg L⁻¹, according to the water volume from each tank where the fishes were euthanized.

In each specimen, besides the biometric data of weight and total length, it was also done research about endoparasites. The collected parasites were treated according to EIRAS et al., 2006 and identified based on MORAVEC (1998).

Fish liver samples were also collected infected with nematodes and processed in the Morphophysiology Laboratory of the Agricultural Sciences Faculty from the Federal University of Grande Dourados. Tissue pieces were fixed in 10% formalin, dehydrated in an ethanol gradual series clarified in xylol and saturated in paraffin. Histological sections of 7µm were stained with hematoxylin-eosin for tissue general analysis and also submitted to histochemical reaction from Perls Prussian Blue (Perls) for the evidence of the hemosiderosis degree (Fe⁺⁺⁺).

The hemosiderosis was evaluated in two ways, semi-quantitatively that punctuates from one to three, according to the incidence and severity deposit of Fe⁺⁺⁺ in each liver: a) Mean Value Calculation of Variation (MVV) according to the incidence (I- absence; II-punctual and III- extensive) adapted from SCHWAIGER et al., 1997; b) Calculation of Histopathological Variation Index (HVI), based on the lesion severity (I- does not affect the organ function; II- affects the organ function and III- irreversible), adapted from POLEKSIC & MITROVIC-TUTUNDZIC (1994). Histological changes have been analyzed under a light microscope (in the increases 10x/0,25; 40x/0,65 and 100x/1,25), linked to a camera in order to acquisition of digital images.

RESULTS

Specimens of *Gymnotus* spp. analyzed had a mean weight of 85,54 ± 30,45g and an average length of 29,80 ± 3,91cm (adults specimens). From the 35

evaluated exemplars obtained a prevalence of 100% of nematodes parasitism. Some fishes presented more than one parasite species, being found six species of nematodes, *Brevimulticaecum* sp.; *Eustrongylides* sp.; *Contracaecum* type I; *Contracaecum* type II; *Contracaecum* type III; a few specimens were identified only as larvae of Anisakidae, it was not possible to identify the gender (Table 1).

Macroscopic analysis of *Gymnotus* spp. liver showed red coloring brownish and friable consistency with the presence of several endocysts. Macroscopically, these cysts were whitish and were situated in the hepatic parenchyma near the organ surface, producing infection both in the central and peripheral regions, and in some samples, there was perforation of organ stroma, allowing externally viewing of the cyst.

Microscopic evaluation revealed cysts presence with one or up to five parasites, in 100% of livers analyzed. In some there were entire larvae, in others only intensely fibrous amorphous materials (Figure 1). Several samples presented parasitic thrombus with vessel occlusion; however, it was not observed acute inflammatory process. It was also registered degenerated hepatocytes presence undergoing apoptosis at necrosis areas and hepatic parenchyma disorganization.

The hepatic tissues submitted to Perl's histochemical reaction presented normal tissue interspersed with different Fe⁺⁺⁺ deposit degrees. The importance factor of hepatopathy revealed that 100% of the samples presented hemosiderosis severity in different stages for this metabolic change. The analysis results were as follows: Grade II, moderate intensity and with impaired organ function, 10% and Grade III, severe hemosiderosis with irreversible changes 90%.

In all livers it was also observed many macrophages and melanomacrophages centers

(MMCs) spread throughout the hepatic parenchyma forming small aggregates of heterogeneous materials, involving in an increasing manner all granulomatosis formation, which actively participated in the chronic parasitic and inflammatory reaction. Microscopically the MMCs have shown intensely blue colored (hemossiderin) resulting from the positive Pells reaction (Figure 2).

DISCUSSION

The encysted larvae of parasites are more pathogenic than those that lodge in the digestive tract (DICK & CHOUDHURY, 1995). In general, the nematodes didn't cause specific response, few reports on fish mortality associated with the parasitic nematode (EIRAS et al., 2010). Among the species reported in this study no reports of mortality associated with *Contracaecum* sp in African freshwater fish (GRABDA, 1989).

The microscopic analysis results that denotes cysts and thrombus parasitic found on every livers are at different development stages, while some are fibrosis showing the process chronicity. However, it was not observed acute inflammatory process according to RODRIGUES et al. (2002) in *Salminus maxillosus* parasitized by *Neocuccullanus neocuccullanus*.

The lack of acute inflammatory process indicates that the parasite is not causing to the host a reaction with inflammatory cells, but the compression of the adjacent liver parenchyma, leading to a disorganization of the hepatocyte cords, small areas of necrosis and hemorrhage. Furthermore, the host presents a great amount of melanomacrophages centers and macrophages spread out throughout the parenchyma, as observed by DEZFULI et al. (2015), in the *Perca fluviatilis* liver parasitized by tapeworms, indicate that these individuals are in a chronic process

Table 1 - Parasites taxons reported in *Gymnotus* spp. collected from April 2012 to October 2013 in commercial bait fish farming in the Pantanal Mato Grosso do Sul basin.

Parasites	PF\EF	TP	Prevalence (%)	Mean intensity	Plenty average
<i>Contracaecum</i> type I	24\35	304	68,6	8,7	12,7
<i>Contracaecum</i> type II	2\35	6	5,7	0,2	3
<i>Contracaecum</i> type III	2\35	3	5,7	0,1	1,5
<i>Eustrongylides</i> sp.	06\35	60	17,1	1,7	10
<i>Brevimulticaecum</i> sp.	09\35	99	25,7	2,8	11
<i>Anisakidae</i> larvae	04\35	15	11,4	0,4	3,8

PF- parasitized fishes; EF- examined fishes; TP- total of parasites.

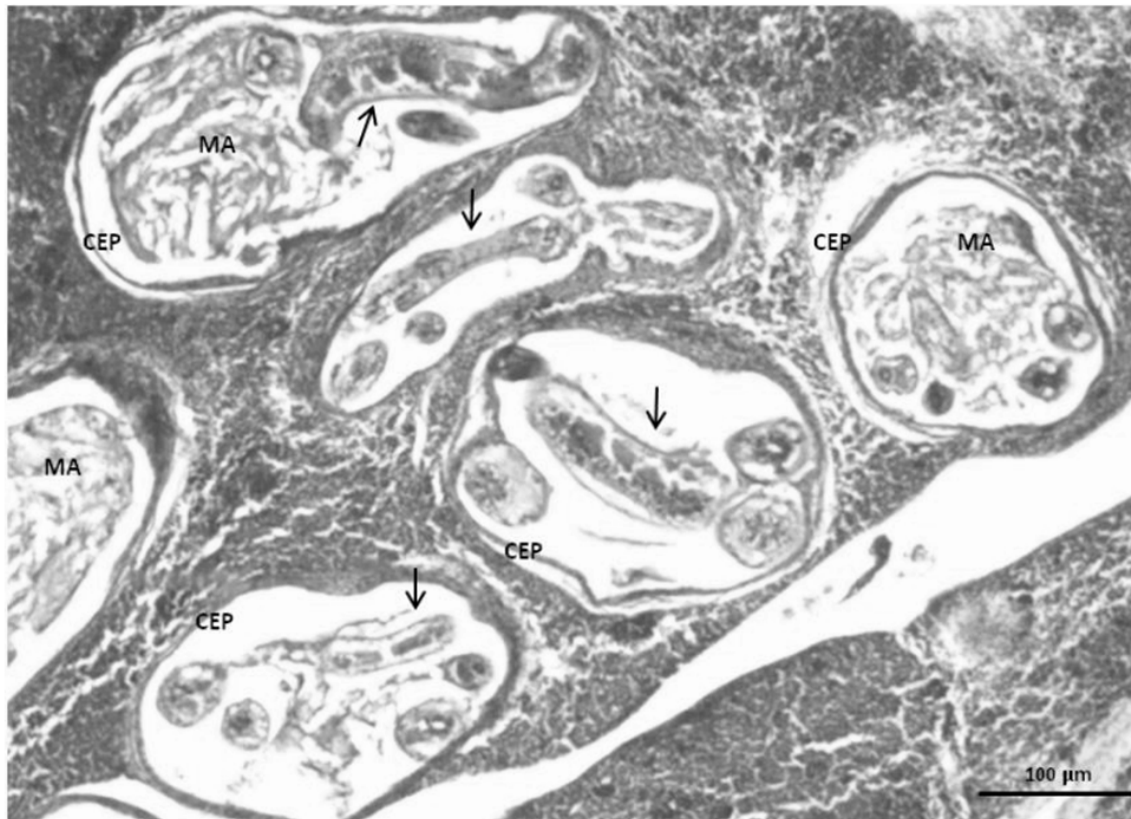

Figure 1 - Liver of *Gymnotus* spp. with capsule that involves the parasite (CEP), amorphous material (MA), encapsulated nematodes (arrows), 400X. HE.

and reacting immunologically to the parasite presence and or the presence of other stress agents.

Fibrosis lesions associated with small necrosis areas have been reported by SANTORO et al. (2013) in antarctic fishes and in this same study it was reported different degrees of chronic inflammation in liver tissue caused by larval forms of *Contracaecum osculatum* and *Diphyllobothriidae*, which corroborates the present study. This fact may explain the apparent tuviras resistance that even with intense parasitism by nematodes, with the presence of several endocysts in the liver, can maintain stable health.

In this way, it can be suggested that there is an equilibrium relation between tuvira and endoparasites, which may be committed in the presence of other stress agents such as management and inadequate water quality for the species, while capturing and commercialization, result in high mortality in commercial bait fish farming. This equilibrium relation can also be changed with the stress resulting from any type of pollution or even

the climate variation naturally presented in the environment where tuviras are captured.

Hemosiderosis also registered in this study has provided a testimony to the condition of commercial bait fish farming in the current ecosystem conditions. The excessive accumulation of hemosiderin pigment is known as hemosiderosis, and reflects hemorrhage or hemolytic anemia (ROBERTS, 2001; WOLKE et al., 1985). In normal cell the Fe deposit may be reversible and does not cause functional change; however, according to the magnitude and persistence, can injure or destroy the cell.

The hemosiderosis of moderate to severe intensity was observed in 100% of livers analyzed and have as etiological agents: parasitic spoliation leading to an anemia and hemorrhage (ROBERTS, 2001; WOLKE et al., 1985), toxins, xenobiotics or iron intake arising from the aquatic environment (AYOADE & ICULALA, 2007). Among other sources, distinct individual metabolic responses or stress might induce cellular changes by increasing

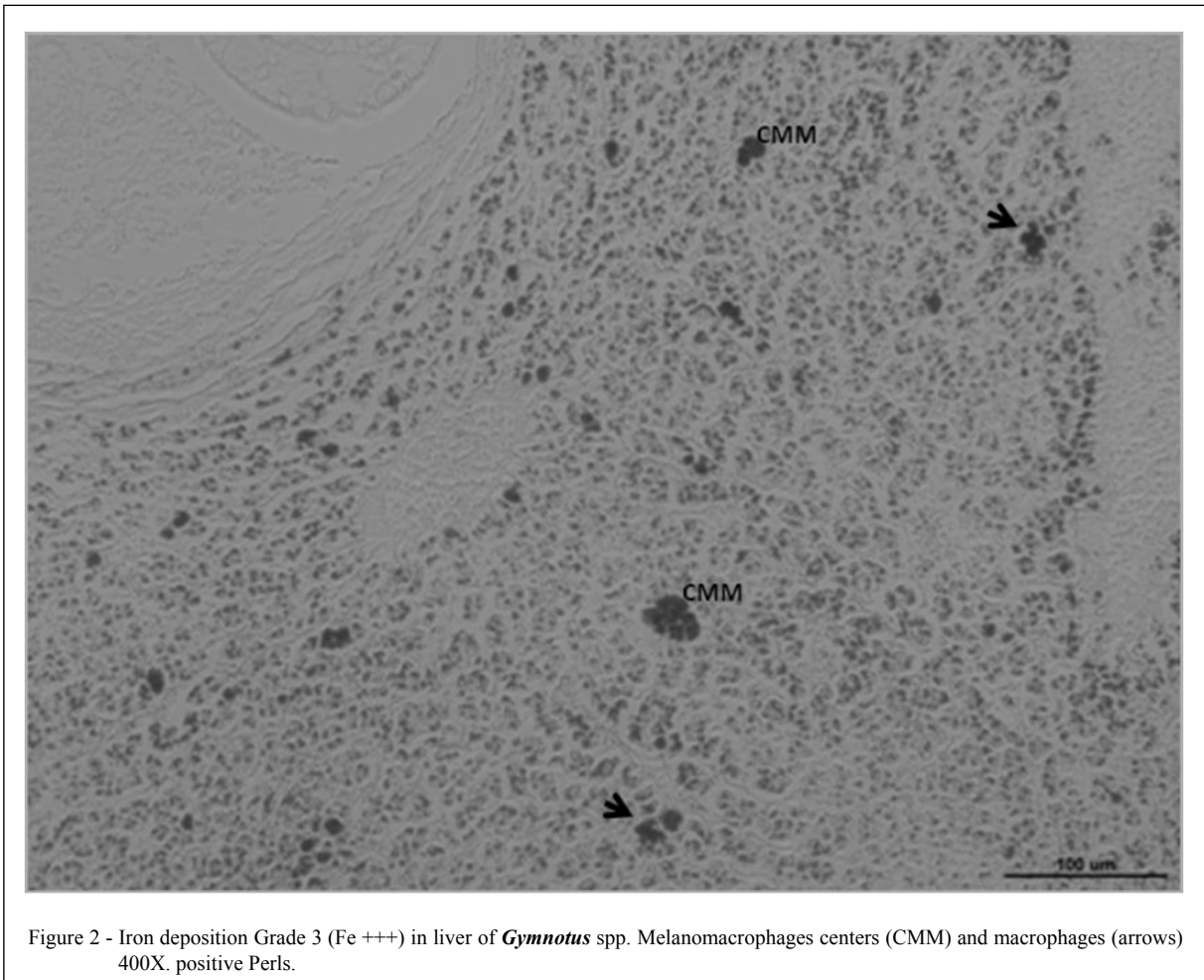


Figure 2 - Iron deposition Grade 3 (Fe⁺⁺⁺) in liver of *Gymnotus* spp. Melanomacrophages centers (CMM) and macrophages (arrows) 400X. positive Perls.

erythrocytes degradation and consequently the hemoglobin breaking, increasing the incidence metabolic Fe deposit. A moderate or severe degree of hemosiderosis observed in this study may indicate that the tuviras source environment is contaminated by endoparasites and/or other pollutant type.

The melanomacrophages center occurs in the fishes hepatic parenchyma. It forms large aggregates and increases in size after active phagocytosis of heterogeneous materials such as detritus, melanin (brown or black color), ceroid or hemosiderin and lipofuscin (natural yellowish color or blue) (AGIUS, 1980; MUNSHI & DUTTA, 1996). Are utilized as bioindicators of water pollution (AYOADE & ICULALA, 2007; BALAMURUGAN et al., 2012), as well as stressful factor indicators (HUR et al., 2006; ALAGAPPAN et al., 2009).

In the present study these results were observed probably due to the chronicity of parasitic infection. It is admitted the hypothesis that the

parasites found in our study and histological changes caused by them may be responsible for the stimulation of the formation mechanisms of these centers. These results are in agreement with the results observed by AGIUS & ROBERTS (2003) in teleost fishes where the presence of MMCs is due to the active phagocytosis period. These changes may be attributed even to age, sex and species of animals evaluated (DABROWSKA et al., 2012).

The studied tuviras come from capturing natural environment and is subsequently wrapped in commercial bait fish farming, in these environments the hygiene conditions are poor, a fact that own the development of diseases and disorders in animals.

CONCLUSION

The intense parasitic infection by nematodes, the histological findings as necrosis, disorganization of the hepatic parenchyma and

pathogenic hemosiderosis, allied to the immunological response to the presence of melanomacrophages centers, suggests a chronic response and development of a balance relation between tuvira and intense parasitism by endohelminth identified in this study.

The data obtained in this study have provided information about the animals health and suggests that the quality of the aquatic environment from commercial bait fish farming and the environment where they were captured, may be compromised. As a suggestion for research development on this species, it is purposed the need for health monitoring studies, especially in the water quality of commercial bait fish farming and the environment where tuviras are captured.

BIOETHICS AND BIOSSECURITY COMMITTEE APPROVAL

This project was approved by the Ethics Committee for Animals Use of the Universidade Federal da Grande Dourados, protocol n. 005/2011.

ACKNOWLEDGEMENTS

This work was supported by the Fundação de Apoio ao Desenvolvimento do Ensino, Ciência e Tecnologia do Estado de Mato Grosso do Sul (FUNDECT), as part of the project Parasitological Evaluation and Hematological Characterization of Tuviras (*Gymnotus* sp.) Coming from commercial bait fish farming of Mato Grosso do Sul. Process: 23/200.202/2010.

REFERENCES

- AGIUS, C. Phylogenetic development of melano-macrophage centres in fish. **Journal of Zoology**, v.191, p.11-31, 1980.
- AGIUS, C.; ROBERTS, R.J. Melano-macrophage centres and their role in fish pathology. **Journal of Fish Diseases**, v.26, n.9, p.499-509, 2003. Available from: <<http://onlinelibrary.wiley.com/doi/10.1046/j.1365-2761.2003.00485.x/full>>. Accessed: Apr. 25, 2015. doi: 10.1046/j.1365-2761.2003.00485.x.
- ALAGAPPAN, K.M. et al. Histopathological alterations in estuarine catfish (*Arius maculatus*; Thunberg, 1792) due to *Aeromonas hydrophila* infection. **World Journal of Fish and Marine Sciences**, v.1, n.3, p.185-189, 2009.
- ANDERSON, R.C. **Nematode parasites of vertebrates**. Their development and transmission. 2.ed. London: CAB Publishing, 2000. p.672.
- AYOADE, A.A. et al. Length weight relationship, condition factor and stomach contents of *Hemichromis bimaculatus*, *Sarotherodon melanotheron* and *Chromidotilapia guentheri* (Perciformes: Cichlidae) in Eleiyele Lake, Southwestern Nigeria. **Journal of Tropical Biology**, v.55, n.3-4, p.969-977, 2007.
- BALAMURUGAN, S.A. et al. Melanomacrophage centers aggregation in *P. lineatus* spleen as bio-indicator of environmental change. **Asian Pacific Journal of Tropical Disease**, v.2, n.2, p.635-638, 2012. Available from: <<http://www.sciencedirect.com/science/article/pii/S2222180812602357>>. Accessed: Apr. 25, 2015. doi: 10.1016/S2222-1808(12)60235-7
- BARBIERI, G.; BARBIERI, C.B. Growth and sexual maturation size of *Gymnotus carapo* (Linnaeus, 1758) in the Lobo reservoir (state of São Paulo, Brasil) (Pisces, *Gymnotidae*). **Revista Hidrobiologia Tropical**, v.16, n.2, p.195-201, 1983a.
- BARBIERI, G.; BARBIERI, C.B. Dinâmica da reprodução de *Gymnotus carapo* na represa do Lobo, estado de São Paulo. Influência de fatores abióticos (Pisces, *Gymnotidae*). **Tropical Ecology**, v.24, n.2, p.244-259, 1983b.
- BARBIERI, G.; BARBIERI, C.B. Crescimento de *Gymnotus carapo* Linnaeus, 1758 na represa do Lobo, estado de São Paulo, pelo método da distribuição da frequência de comprimento (Pisces, *Gymnotidae*). **Revista Brasileira de Biologia**, v.44, n.3, p.239-246, 1984.
- BARROS, L.A. et al. Larvas de nematóides de importância zoonótica encontradas em traíras (*Hoplias malabaricus*, Bloch, 1794) no município de Santo Antonio do Leverger, MT. **Arquivo Brasileiro Medicina Veterinária Zootecnia**, v.59, n.2, p.533-535, 2007. Available from: <http://www.scielo.br/scielo.php?script=sci_arttext&pid=S0102-09352007000200042>. Accessed: Apr. 25, 2015. doi: 10.1590/S0102-09352007000200042.
- BARROS, L.A. et al. Análise do parasitismo por *Contraecium* sp. e *Eustrongylides* sp. em cacharas, *Pseudoplatystoma fasciatum* (Linnaeus, 1766) (Pisces: *Pimelodidae*) provenientes do rio Cuiabá, Mato Grosso, Brasil. **Revista Brasileira Ciência Veterinária** v.16, n.2, p.58-61, 2009.
- DABROWSKA, H. et al. Histopathological, histomorphometrical, and immunohistochemical Biomarkers in flounder (*Platichthys flesus*) from the southern Baltic Sea. **Ecotoxicology and Environmental Safety**, v.78, n.1, p.14-21, 2012. Available from: <<http://www.sciencedirect.com/science/article/pii/S0147651311003678>>. Accessed: Apr. 25, 2015. doi: 10.1016/j.ecoenv.2011.10.025.
- DEZFULI, B.S. et al. Ultrastructural assessment of granulomas in the liver of perch (*Perca fluviatilis*) infected by tapeworm. **Journal of Comparative Pathology**, v.152, n.3, p.97-102, 2015. Available from: <<http://www.sciencedirect.com/science/article/pii/S0021997514003867>>. Accessed: Apr. 25, 2015. doi: 10.1016/j.jcpa.2014.11.007.
- DICK, T.A.; CHOUDHURY, A. Filo nematoda. In: WOO, P.T.K. **Fish diseases and disorders**. New York: CABE Publishing, 1995. V.1, Protozoan and Metazoan Infections, p.415-444.
- EIRAS, J.C. et al. **Métodos de estudo e técnicas laboratoriais em parasitologia de peixes**. 2.ed. Maringá: EDUEM, p.199, 2006.
- EIRAS, J.C. et al. **Diversidade dos parasitas de peixes de água doce do Brasil**. Maringá: Clichetec, p. 333, 2010.
- GUIDELLI, G. et al. Fauna parasitária de *Leporinus lacustris* e *Leporinus friderici* (Characiformes, *Anostomidae*) da planície de inundação do alto rio Paraná, Brasil. **Acta Scientiarum Biological Sciences**, v.28, n.3 p.281-290, 2006. Available from: <<http://periodicos.uem.br/ojs/index.php/ActaSciBiolSci/article/viewArticle/228>>. Accessed: Apr. 25, 2015. doi: 10.4025/actasciobiolsci.v28i3.228.

- GRABDA, J. **Marine fish parasitology**: an outline. Weinheim, Verlagsgesellschaft, p. 306, 1989.
- HUR, J.W. et al. Effects of starvation on kidney melanomacrophage centre in olive flounder, *Paralichthys olivaceus* (Temminck and Schlegel). **Aquaculture Research**, v.37, n.8, p.821-825, 2006. Available from: <<http://onlinelibrary.wiley.com/doi/10.1111/j.13652109.2006.01498.x/abstract?deniedAccessCustomisedMessage=&userIsAuthenticated=false>>. Accessed: Apr. 25, 2015. doi: 10.1111/j.1365-2109.2006.01498.x.
- ISAAC, A. et al. Composição e estrutura das infracomunidades endoparasitárias de *Gymnotus* spp. (Pisces: *Gymnotidae*) do rio Baía, Mato Grosso do Sul, Brasil. **Acta Scientiarum**, v.26, n.4, p.453-462, 2004. Available from: <<http://www.periodicos.uem.br/ojs/index.php/ActaSciBiolSci/article/view/1527>>. Accessed: Apr. 25, 2015. doi: 10.4025/actasciobiols.v26i4.1527.
- ISHIKAWA, M.M. et al. **Recomendações para redução da mortalidade na estocagem de tujurais em isqueiros**. Dourados: Embrapa Agropecuária Oeste, 2014. 5p. (Circular Técnica n.25).
- LACERDA, A.C.F. et al. List of species: Digenea, Nematoda, Cestoda, and Acanthocephala, parasites in *Potamotrygonidae* (Chondrichthyes) from the upper Paraná River floodplain, states of Paraná and Mato Grosso do Sul, Brazil. **Check List**, v.4, n.2, p.115-122, 2008.
- MARTINS, M.L. et al. Larval *Contracecum* sp. (Nematoda: *Anisakidae*) in *Hoplias malabaricus* and *Hoplerhynchus unitaeniatus* (Osteichthyes: *Erythrinidae*) of economic importance in occidental marshlands of Maranhão, Brazil. **Veterinary Parasitology**, v.127, n.1, p.51-59, 2005. Available from: <<http://www.sciencedirect.com/science/article/pii/S0304401704004200>>. Accessed: Apr. 25, 2015. doi: 2004.09.026.
- MARTINS M.L. et al. Sazonality of *Eustrongylides* sp. (Nematoda: *Diocophymatidae*) larvae in fishes from Paraná river, south-western, Brazil. **Boletim Instituto de Pesca**, v.35, n.1, p.29-37, 2009.
- MORAES, A.S.; ESPINOSA, L.W. **Captura e a comercialização de iscas vivas em Corumbá-MS**. Corumbá: Embrapa Pantanal, 2201. 37p. (Boletim de Pesquisa, n.21).
- MORAVEC, F. Nematodes of freshwater fishes of the Neotropical Region. **Praha: Academia**. p. 464, 1998.
- MORAVEC, F. et al. Some nematode of freshwater fishes in Venezuela. **Folia Parasitol (Praha)**, v.44, p.3-47, 1997.
- MUNSHI, J.S.D.; DUTTA, H.M. (Ed.). **Fish morphology**: horizon of new research. USA: Science Publishers, p.300, 1996.
- PAVANELLI, G.C. et al. Helminth fauna of fishes: diversity and ecological aspects. In: THOMAZ, S.M. et al. (Eds.). **The upper Paraná river and its floodplain**: physical aspects, ecology and conservation. Netherlands: Backhuys Publishers, Leiden, p.309-329, 2004.
- PEREIRA, R.A.C.; RESENDE, E.K. **Alimentação de *Gymnotus* cf. *carapo* (Pisces: *Gymnotidae*) e suas relações com a fauna associada às macrófitas aquáticas no Pantanal, Brasil**. Corumbá: Embrapa Pantanal, 2006. p.52. (Boletim de Pesquisa e Desenvolvimento n.68).
- POLEKSIC, V.; MITROVIC-TUTUNDZIC, V. Fish gills as a monitor of sublethal and chronic effects of pollution. In: MÜLLER, R.; LLOYD, R. (Eds.). **Sublethal and Chronic effects of pollutants on freshwater fish**. Oxford: Fishing News Books, p.339-352, 1994.
- REGO, A.A. Contribuição ao conhecimento dos helmintos de rias fluviais *Paratrygonidae*. **Revista Brasileira de Biologia**, v.39, n.4, p.879-890, 1979.
- ROBERTS, R.J. **Fish pathology**. 3.ed. Philadelphia: Saunders, p. 472, 2001.
- RODRIGUES, E. de L. et al. Alterações histopatológicas em fígado de dourado *Salminus maxillosus* Valenciennes Valenciennes, 1840 (Osteichthyes, *Characidae*) causadas por *Neocuccullanus neocuccullanus* Travassos, Artigas & Pereira 1828 (Nematoda). **Acta Scientiarum Biological Science**, v.24, n.2, p.455-459, 2002. Available from: <<http://eduem.uem.br/ojs/index.php/ActaSciBiolSci/article/view/2320>>. Accessed: Apr. 25, 2015. doi: 10.4025/actasciobiols.v24i0.2320.
- ROTTA, M.A. **Aspectos biológicos e reprodutivos para a criação da Tuvira (*Gymnotus* spp.) em cativeiro**. Corumbá: Embrapa Pantanal, 2004. 30p. (Documentos n.74).
- SANTORO, M. et al. Parasitic infection by larval helminths in Antarctic fishes: pathological changes and impact on the host body condition index. **Diseases of Aquatic Organisms**, v.105, n.1, p.139-148, 2013. Available from: <http://www.nwhc.usgs.gov/hfs/Globals/Products/DAO_2013.pdf>. Accessed: Apr. 25, 2015. doi: 10.3354/dao02626.
- SCHWAIGER J. et al. The use of histopathological indicators to evaluate contaminant-related stress in fish. **Journal of Aquatic Ecosystem, Stress and Recovery**, v.6, n.1, p.75-86, 1997.
- TAKEMOTO R.M. et al. Diversity of parasites of fish from the Upper Paraná River floodplain, Brazil. **Brazilian Journal of Biology**, v.69, n.2, p.691-705, 2009. Available from: <http://www.scielo.br/scielo.php?script=sci_arttext&pid=S151969842009000300023&lng=en&nrm=iso&tlng=en>. Accessed: Sept. 28, 2015. doi: 10.1590/S1519-69842009000300023.
- VICENTIN, W. et al. Metazoa parasites of *Serrasalmus marginatus* (Characiformes: *Serrasalminae*) in the Negro River, Pantanal, Brazil. **Revista Brasileira de Parasitologia Veterinária**; v.20, n.1, p.61-63, 2011. Available from: <http://www.scielo.br/scielo.php?pid=S1984-29612011000100012HYPERLINK&script=sci_arttext>. Accessed: Apr. 25, 2015. doi: 10.1590/S1984-29612011000100012.
- VIDAL, L.V.O. et al. Utilização do eugenol como anestésico para o manejo de juvenis de Pintado (*Pseudoplatystoma corruscans*). **Acta Scientiarum Biological Sciences**, v.28, n. 3, p.275-279, 2006.
- WOLKE, R.E. et al. Preliminary evaluation of the use of macrophage aggregates (MA) as fish health monitors. **Bulletin of Environmental Contamination and Toxicology**, v.35, n.1, p.222-227, 1985. Available from: <<http://link.springer.com/article/10.1007%2FBF01636502#page-1>>. Accessed: Apr. 28, 2015.