

## Vaginal leiomyosarcoma in a cow from Uberlândia, Minas Gerais, Brazil

### Leiomiossarcoma Vaginal em uma vaca de Uberlândia, Minas Gerais, Brasil

João Paulo Elsen Saut<sup>I</sup> Patrícia Magalhães de Oliveira<sup>I</sup> Nayara Resende Nasciutti<sup>I</sup>  
Alessandra Aparecida Medeiros<sup>I</sup> Geórgia Modé Magalhães<sup>II</sup> Suzana Akemi Tsuruta<sup>I</sup>  
Paul Hanna<sup>III</sup> Selwyn Arlington Headley<sup>IV</sup>

#### - NOTE -

#### ABSTRACT

*The clinical, pathological, and immunohistochemical findings associated with a vaginal leiomyosarcoma in a 12-year-old, Senepol breed of cow from Uberlândia, Minas Gerais are described. The animal had a large ulcerative neoplastic growth that originated between the base and the left-lateral vaginal wall. Histopathology revealed a tumor formed by muscle-like cells that demonstrated cellular pleomorphism, anisokaryosis, prominent and multiple nucleoli, with rare tumor giant cells. The neoplastic growth invaded adjacent adipose tissue, and contained areas of hemorrhage with discrete accumulations of inflammatory cells. By immunohistochemistry, most neoplastic cells expressed actin, while immunoreactivity to desmin was weakly expressed. These findings support a diagnosis of leiomyosarcoma, and represent the first description of a bovine vaginal leiomyosarcoma from Brazil.*

**Key words:** bovine diseases, immunohistochemistry, reproductive pathology, smooth muscle tumor.

#### RESUMO

*No presente trabalho, foram descritos os achados clínicos, patológicos e imunohistoquímicos de uma vaca da raça Senepol, 12 anos, com leiomiossarcoma vaginal, de Uberlândia, Minas Gerais. O animal apresentou massa ulcerada localizada entre a base e parede lateral-esquerda da vagina. A histopatologia revelou uma neoplasia formada por células fusiformes a arredondadas que demonstraram pleomorfismo celular, anisocariose, nucléolos proeminentes e múltiplos, com raras células gigantes tumorais. O crescimento neoplásico invadiu o tecido adiposo adjacente e continha áreas de hemorragia com discreto acúmulo de células inflamatórias. A maioria das células neoplásicas expressou actina na avaliação imunohistoquímica, enquanto a imunoreatividade para desmina foi fracamente*

*expressa. Os achados suportam o diagnóstico de leiomiossarcoma e representa a primeira descrição de leiomiossarcoma vaginal em bovinos no Brasil.*

**Palavras-chave:** doença de bovino, imunohistoquímica, patologia reprodutiva, tumor de musculo liso.

The incidence of mesenchymal tumors arising from the reproductive tract of large animals is relatively low (ANDERSON & SANDISON, 1969), when compared with small animals. Previously described reports of tumors arising from the vagina of the cow include fibroleiomyoma (TIMURKAAN et al., 2009), fibroma (ANDERSON & SANDISON, 1969), fibrosarcoma (MUSAL et al., 2007; HAMALI & ASHRAFIHELAN, 2010), and fibroleiomyosarcoma (AVCI et al., 2010); a cervical leiomyoma is also described within the reproductive tract of a cow (SENDAG et al., 2008). Within the female genitalia of domestic animals, vaginal leiomyoma is the most frequently occurring neoplasm particularly in the bitch (MCLACHLAN & KENNEDY, 2000) while leiomyosarcomas are considered uncommon lesions (SCHLAFER & MILLER, 2007). Further, genital leiomyosarcomas in cattle are more frequently observed within the uterus (COOPER & VALENTINE, 2002); cases of vaginal leiomyosarcomas have not been found described in

<sup>I</sup>Faculdade de Medicina Veterinária, Universidade Federal de Uberlândia (UFU), Minas Gerais, MG, Brasil.

<sup>II</sup>Hospital Universitário, Universidade de Franca, São Paulo, SP, Brasil.

<sup>III</sup>Department of Pathology and Microbiology, University of Prince Edward Island, Charlottetown, Canada.

<sup>IV</sup>Laboratório de Patologia Veterinária, Escola de Medicina Veterinária, Universidade Norte do Paraná (UNOPAR), PR 218, KM 1, Jardim Universitário, 86702-670, Arapongas, PR, Brasil. E-mail: headleya@gmail.com. Autor para correspondência.

cows from Brazil. This report describes the clinical, pathological, and immunohistochemical findings associated with a vaginal leiomyosarcoma in a cow.

A 12-year-old, Senepol breed of cow that is used exclusively for embryo transfer (ET) and *in-vitro* fertilization (IVF) was brought to the Veterinary Teaching Hospital, Universidade Federal de Uberlândia, Minas Gerais, Brazil, in June 2010 after surgical excision of a mass from the vaginal region was done at a private veterinary clinic, due to prolapse of the cervical-vaginal area. According to the owner, the consulting clinician considered the exuberant mass as granulation tissue.

Clinical examination of the cow revealed cervical-vaginal prolapse, lacerations of the vaginal mucosa, localized hyperemia and accumulation of fetid purulent secretion; rectal palpation diagnosed metritis and a 20cm diameter intraperitoneal abscess. The prolapsed tissue was reduced surgically, the cow treated adequately, and released. However, post-operative visits to the farm where the cow was maintained revealed gradual increase in the size of the vaginal area, and by early October, 2010 there was a severely enlarged mass that protruded through the vulva. The tumorous mass which was located approximately 10cm from the cervix (Figure 1A), and originated between the base and the left-lateral wall of the vagina, was removed surgically, fixed in 10% buffered formalin solution and submitted for routine histopathological evaluation. The health of the cow deteriorated rapidly and by late April 2011 the owner requested euthanasia due to the continued vaginal growth and localized infection; a routine necropsy was performed soon after. Tissue fragments from the vaginal tumor, uterus, and vagina were submitted for routine histopathological evaluation. Duplicate sections of the neoplastic growths were submitted for immunohistochemistry and stained by the Masson trichrome technique.

IHC was done by using the biotin-streptavidin technique in an automated system (Ventana BenchMark). The sections were incubated with the following primary monoclonal antibodies: desmin (Clone D33, Dako, Glostrup, Denmark; 1:100) and smooth muscle actin (Clone 1A4, Ventana BenchMark, Tucson, AZ, USA; 1:250). Positive and negative controls consisted of sections of normal bovine uterus; but for negative controls the primary antibodies were substituted by diluent of the primary antibodies.

Significant gross alterations were restricted to the reproductive tract and consisted of exuberant vaginal tissue, bilateral pneumouterus, mucopurulent metritis and vaginitis, with extensive

laceration and localized infection of the externalized vaginal mucosa. Metastases of the vaginal tumor were not observed and regional lymph nodes were not affected. The mass removed from the vaginal wall was a large 5x20x26cm, 1.4kg, firm, poorly-encapsulated, unevenly surfaced growth (Figure 1B). The sectioned surface was smooth and white-tan in color, with regions of superficial ulceration.

Histologically, the tissue fragments obtained surgically and those from the exuberant vaginal growth during necropsy were similar, and consisted of a tumor formed by the proliferation of spindle-shaped to plump smooth muscle-like cells arranged in interlacing bundles (Figure 1C). The neoplastic cells demonstrated moderate cellular polymorphism, indistinct cellular margins, anisokaryosis, prominent and multiple nucleoli, and rare tumor giant cells; mitotic figures were not observed (Figure 1D). Large amount of extracellular collagenous matrix was identified by the Masson trichrome stain (Figure 1E-F). Within some regions of the tumor, there were varying degrees of hemorrhage, and discrete influx of inflammatory cells; in other areas, the proliferating muscle cells invaded the adjacent serosal adipose tissue. Further, the surface of some sections was ulcerated and hemorrhagic and contained bacterial colonies. Evaluation of other sections confirmed purulent necrotizing vaginitis and metritis; and tumor cells were not observed in any other tissue fragments.

The IHC staining was uniform in all sections evaluated. Approximately 90% of the neoplastic cells demonstrated immunoreactivity to smooth muscle actin (SMA) (Figure 1G); and less than 5-10% of these cells showed weak immunoreactive to desmin (Figure 1H).

A diagnosis of leiomyosarcoma was based on characteristic histological, histochemical, and immunohistochemical features that are consistent with this malignant tumor (COOPER & VALENTINE, 2002, SCHLAFER & MILLER, 2007); the recurrence and rapid locally invasive growth observed clinically and histologically demonstrate the malignant nature of this tumor. In this case, extensive gross and histological evaluation of the tumorous mass, adjacent tissues, and lymph nodes was performed but neoplastic cells were not observed. Nevertheless, the presence of unidentified metastasis foci cannot be totally ignored.

Histopathological differentiation between leiomyomas and leiomyosarcomas in domestic animals is based on mitotic index, tissue invasion, and/or areas of necrosis (COOPER & VALENTINE,

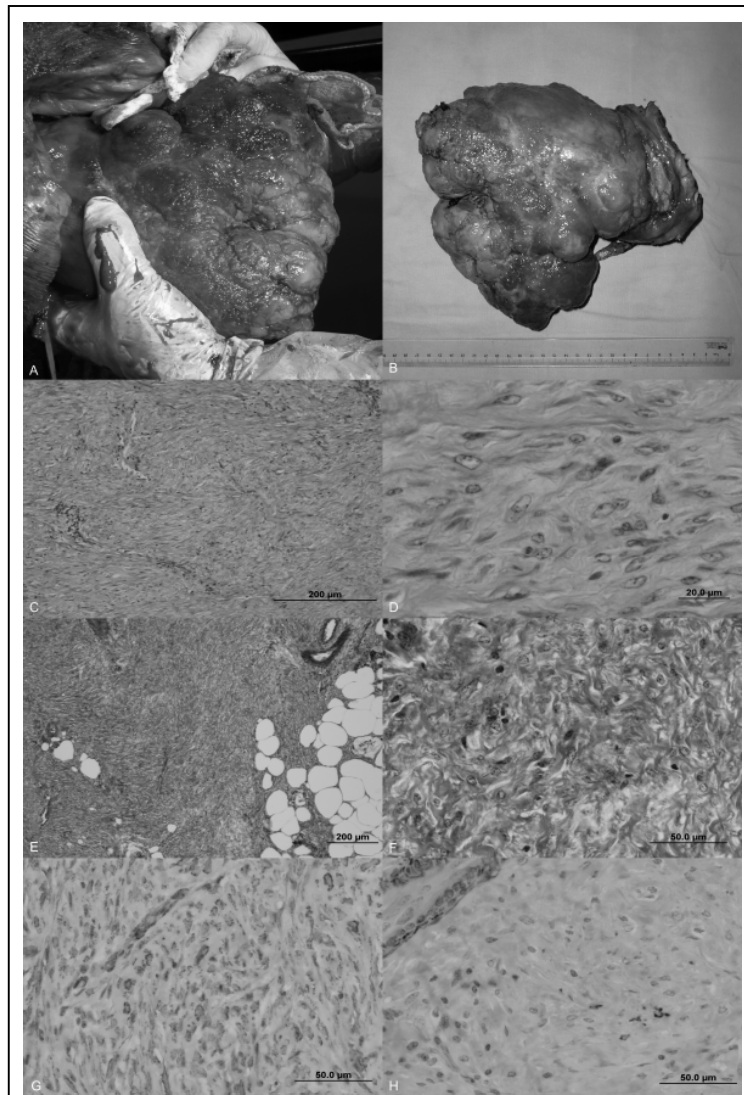


Figure 1 - Characterization of vaginal leiomyosarcoma in a Senepol cow. A large tumorous growth is being surgically removed from the vaginal wall of the cow (Figure 1A). Grossly, the mass is composed predominantly of muscular tissue with some necrotic regions; scale in centimeters (Figure 1B). Microscopically, the neoplastic growth is formed by the proliferation of smooth muscle cells arranged in interlacing bundles (Figure 1C), demonstrated pleomorphism and anisokaryosis (Figure 1D), invaded the adjacent adipose tissue (Figure 1E), and is composed of large amounts of collagenous tissue (Fig. 1F). Immunohistochemistry demonstrated that most neoplastic cells expressed positive cytoplasmic immunoreactivity to actin (Figure 1G); observe similar reaction at the internal control (vascular smooth muscle). Additionally, few neoplastic cells expressed positive cytoplasmic immunoreactivity to desmin (Figure 1H); there is similar staining at the vascular smooth muscle used as internal control. (C-D, Hematoxylin and eosin stain; D-E, Masson's trichrome stain; F-H, Immunohistochemistry; C, E Bar = 200µm; D, F-H, Bar = 50µm).

2002; SCHLAFER & MILLER, 2007). Increased numbers of mitotic figures are present in most malignant smooth muscle tumors of domestic animals

(COOPER & VALENTINE, 2002), and have been observed in reports of genital malignant growths of cattle (ANDERSON & SANDISON, 1969; MUSAL

et al., 2007; AVCI et al., 2010) and goats (WHITNEY et al., 2000). However, in this case there were rare tumor giant cells, but mitoses were not observed; few mitotic figures but with larger numbers of tumor giant cells were described in a bovine vaginal fibrosarcoma (HAMALI & ASHRAFIHELAN, 2010). The relatively abundant connective tissue component identified by Masson's trichrome staining is consistent for smooth muscle tumors of the genital tract (COOPER & VALENTINE, 2002). Although other tumors such as fibroma or fibrosarcoma would also have abundant collagenous matrix, the tumor cells would lack myogenic differentiation (MUSAL et al., 2007; HAMALI & ASHRAFIHELAN, 2010).

IHC staining showed variation in the immunoreactivity of the neoplastic cells to SMA and desmin, but the internal controls (vascular smooth muscle) in both cases validated the efficiency of each assay. Variation in immunohistochemical reactivity to desmin and SMA might be a diagnostic feature of genital leiomyosarcomas of domestic animals (COOPER & VALENTINE, 2002); where there is diffuse and uniform immunoreactivity to desmin and SMA in leiomyomas, but irregular or diffuse immunostaining in genital leiomyosarcomas. Variations in the immunoreactivity of smooth muscle tumors to SMA and desmin might be related to the degree of differentiation of each tumor (COOPER & VALENTINE, 2002). Nevertheless, a bovine vaginal fibroleiomyosarcoma had strong immunoreactivity to desmin and SMA, patchy reaction with vimentin, and negative labeling of CD3, CD68, and S100 (AVCI et al., 2010), while caprine genital leiomyosarcomas were positive for SMA with negative immunoreactivity to desmin, cytokeratin, and vimentin (WHITNEY et al., 2000). Additionally, previously described cases of bovine genital leiomyoma (SENDAG et al., 2008) and fibroleiomyoma (TIMURKAAN et al., 2009) were immunoreactive to SMA, but without reaction to either the S100 protein, cytokeratin, CD68, the proliferating cell number antigen, or p53 (SENDAG et al., 2008; TIMURKAAN et al., 2009).

An unusual feature of this case was the occurrence of Grade IVa vaginal prolapse (ANDERSON & SANDISON, 1969) in a cow that is used exclusively for ET and IVF; vaginal prolapses in cows are predominant during gestation or immediately after parturition (MIESNER & ANDERSON, 2008; PRESTES et al., 2008), and are associated with the hormone-induced relaxation of the pelvic and perianal ligaments (PRESTES et al., 2008). Additionally, other cases of genital tumors described in cows occurred in either gestating (SENDAG et al., 2008; AVCI et al., 2010) or postpartum (TIMURKAAN

et al., 2009, HAMALI & ASHRAFIHELAN, 2010) animals. Although the cause of the vaginal prolapse in this case has not been completely elucidated, studies done in Brazil have observed elevated indices of vaginal prolapse in cows reared intensively and used exclusively for ET and FIV (PRESTES et al., 2008), as was this cow. It has been speculated that cows submitted to repeated episodes of ET and IVF, are more predisposed to vaginal prolapse due to relaxation of the pelvic ligaments and constant contact with the vaginal wall during repeated episodes of rectal collection of oocytes monitored by transvaginal ultrasonography (PRESTES et al., 2008); ET and IVF were the principal economic functions of this cow and might explain the episodes of vaginal prolapse. However, the participation of the effects of feedstuff with elevated levels of estrogen (MIESNER & ANDERSON, 2008) cannot be overlooked.

In summary, a tumorous mass within the vagina of a cow was diagnosed as leiomyosarcoma based on histopathological and immunohistochemical features, and might represent the first description of bovine vaginal leiomyosarcoma originating from Brazil.

## ACKNOWLEDGEMENTS

This study was partially funded by the Office of the Pro-Rector for Research and Graduate Studies, Universidade Norte do Paraná, Londrina, Brazil.

## REFERENCES

- ANDERSON, L.J.; SANDISON, A.T. Tumours of the female genitalia in cattle, sheep, and pigs found in a British abattoir survey. *Journal of Comparative Pathology*, v.79, p.53-63, 1969. Available from: <<http://www.sciencedirect.com/science/article/pii/0021997569900279>>.
- AVCI, H. et al. Primary vaginal fibroleiomyosarcoma in a 4-year-old Holstein-Friesian cow. *Turkish Journal of Veterinary and Animal Sciences*, v.34, p.307-311, 2010. Available from: <<http://mistug.tubitak.gov.tr/bdyim/abs.php?dergi=vet&rak=0812-1>>.
- COOPER, B.J.; VALENTINE, B.A. Tumors of muscle. In: MEUTEN, D.J. (Ed.). *Tumors in domestic animals*. 4.ed. Ames: Iowa State University, 2002. p.319-363.
- HAMALI, H.; ASHRAFIHELAN, J. Vaginal fibrosarcoma in cow (a case report). *International Journal of Veterinary Research*, v.4, p.225-228, 2010. Available from: <<http://journals.ut.ac.ir/page/article-frame.html?langId=en&articleId=390936>>.
- MACLACHLAN, N.J.; KENNEDY, P.C. Tumors of the genital system In: MEUTEN, D.J. (Ed.) *Tumors in domestic animals*. 4.ed. Ames: Iowa State University, 2000. p.547-574.
- MIESNER, M.D.; ANDERSON, D.E. Management of uterine and vaginal prolapse in the bovine. *Veterinary Clinics: Food Animal Practice*, v.24, p.409-419, 2008. Available from: <<http://www.sciencedirect.com/science/article/pii/S0749072008000108>>.

MUSAL, B. et al. Vaginal fibrosarcoma in a cow. **Irish Veterinary Journal**, v.60, p.424-425, 2007. Available from: <<http://www.irishvetjournal.org/content/60/7/424>>.

PRESTES, N.C. et al. Prolapso total ou parcial de vagina em vacas não gestantes: uma nova modalidade de patologia? **Revista Brasileira de Reprodução Animal**, v.32, p.182-190, 2008. Available from: <<http://www.cbpa.org.br/pages/publicacoes/rbra/download/RB181%20Prestes%20vr3%20pag182-190.pdf>>.

SCHLAFER, D.H.; MILLER, R.B. Female genital system. In MAXIE, M. (Ed.). **Jubb, Kennedy & Palmer's pathology of domestic animals**. 5.ed. Philadelphia: Saunders/Elsevier, 2007. v.3, p.429-564.

SENDAG, S. et al. A cervical leiomyoma in a dairy cow during pregnancy. **Animal Reproduction Science**, v.103, p.355-359, 2008. Available from: <<http://www.sciencedirect.com/science/article/pii/S0378432007002047>>.

TIMURKAAN, N. et al. Vaginal fibroleiomyoma in a cow: a case report. **Veterinarni Medicina**, v.54, 138-141, 2009. Available from: <<http://www.vri.cz/docs/vetmed/54-3-138.pdf>>.

WHITNEY, K.M. et al. Caprine genital leiomyosarcoma. **Veterinary Pathology**, v.37, p.89-94, 2000. Available from: <<http://vet.sagepub.com/content/37/1/89.full.pdf>>.