

Mesenchymal stem cell infusion on skin wound healing of dexamethasone-immunosuppressed wistar rats

Infusão de células tronco mesenquimais sobre a cicatrização de feridas cutâneas em ratos wistar imunossuprimidos com dexametasona

Betânia Souza Monteiro^{1*} Roberta Delessa Faria¹ Alessandra Rodrigues Coelho Zanella¹
Emanuelle Pimentel Cruz¹ Noely Pianca Godoi¹ Wagner Alexey Back Fiorio^{1†}
Dominik Lenz¹ Viviane Raposo Fortunato¹

ABSTRACT

To evaluate the therapeutic contribution of MSC intravenous infusion to surgical wound healing in dexamethasone-immunosuppressed rats, thirty-five rats were randomly divided into 2 groups: in the Control Group (CG), five rats received normal saline as 0.2ml subcutaneous (SC) injections every 24 hours, for 30 consecutive days and, in the Dexamethasone Group (DG), 30 rats were given 0.2mL subcutaneous dexamethasone (0.1mg kg⁻¹) every 24 hours, for 30 consecutive days. After 30 days, all rats underwent surgery to create an experimental skin wound. The 30 animals of the DG group were divided into two equal groups, which received different treatments: the dexamethasone group (DG) received a single application of 0.5ml normal saline, via the intravenous route (IV), 48 hours after wound creation; and the Mesenchymal Stem Cells Dexamethasone group (MSCDG) received MSC transplantation at a concentration of 9x10⁶ cells in a single IV application, 48 hours after wound creation. The surgical wounds of CG rats closed on average 14.75 days after creation and DG rats had wounds closed within 22 days; whereas, the surgical wounds of MSCDG rats were closed in 14 days. MSC infusion in dexamethasone-immunosuppressed patients contributed positively to epithelial healing in less time.

Key words: tissue repair, cell therapy, immunomodulation.

RESUMO

O presente trabalho teve como objetivo avaliar a contribuição terapêutica da infusão de células tronco mesenquimais na cicatrização cutânea de ratos imunossuprimidos com dexametasona. Utilizaram-se 35 animais, distribuídos em dois grupos: Grupo Controle (GC), formado por cinco animais que receberam aplicações de 0,2ml de solução fisiológica a cada 24 horas por via subcutânea (SC) e Grupo Dexametasona (GD), formado por trinta animais que receberam aplicações a cada 24 horas de 0,2mL de dexametasona (0,1mg kg⁻¹), por via SC, todos durante 30 dias consecutivos. Após os 30 dias, todos os animais

foram submetidos a procedimento cirúrgico para a criação de ferida cutânea experimental. Os 30 animais do GD foram subdivididos em dois grupos equivalentes, diferenciados quanto ao tratamento: Grupo Dexametasona (GD), que receberam uma única aplicação de 0,5ml de solução fisiológica, por via IV, 48 horas após a criação da ferida; e Grupo Dexametasona Células Tronco Mesenquimais (GDCTM), que receberam o transplante de CTM, na concentração de 9x10⁶ células, em aplicação única, por via IV, 48 horas após a criação da ferida cirúrgica. Os Animais do GC também receberam uma única aplicação de 0,5ml de solução fisiológica, por via IV, 48 horas após a criação da ferida cirúrgica. As feridas cirúrgicas dos animais do GC fecharam em média 14,75 dias após a indução da lesão, os animais do GD tiveram suas feridas cirúrgicas fechadas em até 22 dias, já as feridas cirúrgicas dos animais do GDCTM foram fechadas em 14 dias. A terapia celular realizada em pacientes imunodeprimidos contribuiu positivamente para a cicatrização epitelial em menor tempo.

Palavras-chave: reparo tecidual, terapia celular, imunomodulação.

INTRODUCTION

Healing is the biological process that restores the continuity of the tissue after an injury. It consists of a combination of physical, chemical and cellular events that restores a damaged tissue or replaces it by collagen. Healing is influenced by host factors, wound characteristics and other external factors (MARTIN, 1997; RICHARDSON, 2004). Some drugs delay the healing process, such as corticosteroids (CHOI et al., 2006). Glucocorticoids can inhibit the earliest manifestations of the inflammatory process and, still later, the repair and proliferation of tissue,

¹Programa de Pós-graduação em Ciência Animal, Laboratório de Células Tronco e Terapia Celular, Universidade Vila Velha (UVV), 29102-920, Vila Velha, ES, Brasil. E-mail: betania.monteiro@gmail.com. *Corresponding author.

[†]Centro Avançado de Imagem e Patologia Veterinária, Vila Velha, ES, Brasil.

as well as have immunosuppressive activity (CHOI et al., 2006). In an attempt to minimize the damage caused by the chronic administration of nonsteroidal anti-inflammatory drugs, mesenchymal stem cells (MSC) have emerged as a promising therapeutic alternative (WU et al., 2007; CASADO et al., 2014). These cells can be transplanted into the lesional sites soon after the occurrence of tissue injury and can be applied in the undifferentiated state, being stimulated by the environment to later differentiate or undergo differentiation in culture before implantation (DEL CARLO et al., 2008).

This study aimed to evaluate the therapeutic contribution of MSC intravenous infusion to cutaneous surgical wound healing in dexamethasone-immunosuppressed rats. For this purpose, it was measured healing time (HT) and lesion area (LA) and observed thickness and organization of the collagen deposition in the surgical wounds.

MATERIALS AND METHODS

The *in vivo* study used 35 female Wistar rats (*Rattus norvegicus albinus*), sixteen weeks of age, weighing approximately 300 grams. Animals were kept in groups of five rats and were fed with standard rodent chow and with filtered water *ad libitum*. Before starting the experiment, all animals were dewormed with Ivermectin 2% (0.4mg kg⁻¹), orally administered, added in 700mL water drinkers and repeated 10 days prior to surgery.

Cell Culture

Two Wistar rat pups were used as MSC donors. Isolation, characterization and expansion of MSC were carried out according to the methodology described by MONTEIRO et al. (2012). An aliquot of cells from the fourth passage was characterized by flow cytometric analysis of the expression of CD 34, CD 45, CD 90 and CD 54 on the surface of cells using a FACScan flow cytometer and CellQuest® software, yielding 30,000 events per sample tested.

Another aliquot of cells from fourth passage underwent stages of osteogenic differentiation. Adherent cells were detached with trypsin, counted and replated in 6-wells plates with DMEM medium supplemented with 10% FBS, 10⁻⁸mol/mL⁻¹ dexamethasone (Sigma, St. Louis MO, USA), 5µg mL⁻¹ ascorbic acid 2-phosphate (Sigma, St. Louis MO, USA), and 10mmol L⁻¹ β-glycerophosphate (Sigma, St. Louis MO, USA) and incubated at 37°C for four weeks. On the 30th day after placing the cells in osteogenic medium, the wells were washed in PBS

and stained by the Von Kossa method to observe calcium deposition.

After the fourth passage, the cells were trypsinized, examined in an optical microscope to assess cell viability, counted in a Neubauer chamber and aliquoted at a concentration of 9x10⁶ cells in 0.5mL of PBS (phosphate buffered saline). Each aliquot was stored in a 1.0mL syringe and kept in styrofoam boxes on ice until the time of transplantation.

Experimentation *in vivo*

Thirty days before surgery, 35 animals were individually weighed, identified with ear tags in the left ear and randomly assigned into 2 groups. These groups received different treatments as listed below and observed daily for 2 consecutive months: Control Group (CG) with five rats received normal saline (NaCl 0.9%) as 0.2mL subcutaneous (SC) injections every 24 hours, for 30 consecutive days and Dexamethasone group (GD) with 30 rats were given 0.2mL subcutaneous dexamethasone (0.1mg kg⁻¹) every 24 hours, for 30 consecutive days.

After completing 30 days of the dexamethasone treatment, prior to surgery, all animals (n=35) were anesthetized by intramuscular (IM) injection of an association of 10% ketamine (20mg kg⁻¹), 2% xylazine (4mg kg⁻¹), 0.5% midazolam (2.5mg kg⁻¹) and 1% morphine (1.0mg kg⁻¹). Animals received prophylactic antibiotic treatment with enrofloxacin 10% (10mg kg⁻¹) via SC in the intraoperative period.

After antisepsis, a surgical circular wound of about 1.5cm in diameter was created by removing skin in the dorsal region. A non-absorbable monofilament suture (Nylon 3.0) was used to close the wound edges to the surrounding muscles with separate single points to minimize the retraction of the wound edges. The wounds of all animals were cleaned daily with normal saline-moistened sterile gauze. After surgery, the 30 rats of group DG were divided randomly into two news groups of 15 animals and each group received different treatments: Dexamethasone Group (DG) with fifteen animals received a single application of 0.5mL of PBS, via the intravenous route (IV), 48 hours after wound creation and followed up for 30 days and Mesenchymal Stem Cells Dexamethasone Group (MSCDG) with fifteen animals received MSC transplantation at a concentration of 9x10⁶ cells (final volume 0.5ml) in a single IV application, 48 hours after wound creation.

The five rats of CG received a single IV application of 0.5mL of PBS, 48 hours after the creation of the surgical wound. The intravenous

injections were administered in the lateral tail vein, in all animals of the study.

Six rats from each group (DG and MSCDG) were chosen at random to have the wounds photographed daily throughout the observation period for the evaluation of wound area (WA) and healing time (HT), according to the methodology of ARGOLLO-NETO et al. (2012). Images were transferred to a computer and wound area was measured using Image-Pro Plus® image analysis software. Wound areas were measured three times to obtain an average value for each rat/day and individuals of the same group represented the average for the group.

The remaining 9 rats of each group were chosen at random to be euthanized on days 3, 7 and 15 after surgery (3 rats per day), with an overdose of the anesthetic isoflurane. Then the rats were placed on a surgical table and restrained for incisional biopsy in which samples containing the whole wound area were removed with a small margin of healthy skin around them.

Skin samples were fixed in buffered 4% paraformaldehyde for 24 hours and sent for histopathological examination. Sections were mounted on glass slides and stained with Gomori's Mallory for identification and quantification of collagen fibers, hematoxylin and eosin (HE). The stained slides were examined by light microscopy for descriptive analysis of the healing process through blind histopathological evaluation, where the pathologist is unaware of the treatment status of the animals. Quantification of collagen fibers (CF) was performed on three microscope images (10x) of three different fields for each of the stained histological sections. The captured images were analyzed using CellProfiler®, an open-source automated image analysis software, to evaluate the proportion of collagen fibers in the predetermined area. The program was calibrated for the study, standardizing the staining of collagen fibers to be quantified in a 5mm² area, from which the group means were calculated.

Statistical analysis of data was carried out using Excel® statistical functions. Measurements of wound area (WA) and healing time (HT) were subjected to analysis of variance (ANOVA) and Tukey test at 5% to compare the least significant difference of the means of each treatment.

RESULTS

The bone marrow provided a heterogeneous non-adherent culture, consisting of rounded cells and lipid micelles in the culture supernatant within

24 hours. After 8 days, the cell population became more homogeneous, with a predominance of adherent fibroblastoid cells organized into colonies. Flow cytometry of a sample of cells at the fourth passage and GFP showed that about 43% of homogeneous cells had negative expression for 96.53% of CD34 and 93.89% of CD45 and positive expression for 99% of CD90 and 95.8% of CD54.

Rats that received SC dexamethasone applications had reduction in body weight from the seventh day of the corticosteroid application. At day 14, 26.7% (8/30) of the rats showed a red-brown eye discharge and regions of hypotrichosis. At surgery day, only hypotrichosis persisted. From 8 days after the surgery, there was a slight weight gain in all rats.

In all rats, the wounds appeared dry, crusted erythematous and without exudate, and regressed slowly until loss of surface crust and epithelialization. The variable surgical wound area (WA) was not significantly different among the treatments during 15 days of observation. Initial lesion area was about 3.2cm² at the time the wound was created, regardless of the experimental group, and tended to zero (Table 1). However, when assessing the healing time (HT), the surgical wounds of rats in the CG group showed complete healing at 15 days after the injury, while in DG rats wounds healed at 22 days and, MSCDG rats at 14 days. This result led to significant difference between the treatments when comparing CG x DG and MSCDG x DG, but there was no difference between CG and MSCDG (Table 1). Progress of skin wound healing over 15 days of observation is presented in figure 1.

Histopathological analysis of the wounds in control rats, 3 days after wound creation, showed fibrin material and neutrophils in degeneration and hypersegmentation. The connective tissue was edematous, with formation of fibrin strands with the initiation of proliferation of immature fibroblasts and occasional mitotic figures were present. There was a mild hypertrophy of endothelial cells in vessels, which were moderately dilated in deep planes. The zone of endothelial proliferation was discrete from the remaining congested vessels. Very rare collagen fibers were remaining, with no easily detectable collagen fibers. Evident hyperplasia of the marginal epithelium was observed with clear acanthosis in the wound edge and surrounding tissue. It was observed an intense reactivity with proliferation of fibroblasts located in the periphery of the muscle tissue, which was accompanied by a mild suppurative inflammation. Beyond the edge of the wound, there was also congestion, vascular dilatation and diffuse

Table 1 - Means of wound area (WA) in cm², of rats in the different experimental groups, at days 1, 3, 5, 10, 12 and 15 after wound creation. (CG = control group, DG = dexamethasone group; MSCDG = dexamethasone group treated with mesenchymal stem cells).

GROUP	DAY 0	DAY 1	DAY 3	DAY 5	DAY 10	DAY 12	DAY 15	MEANS
CG	3.337 ^a	2.229 ^a	1.780 ^a	1.543 ^a	0.542 ^a	0.093 ^a	0.000 ^a	21.25 ^a
DG	3.215 ^a	2.804 ^a	2.748 ^a	2.439 ^a	0.967 ^a	0.652 ^a	0.368 ^a	14.75 ^b
MSCDG	3.738 ^a	2.541 ^a	2.288 ^a	2.035 ^a	0.589 ^a	0.113 ^a	0.000 ^a	13.5 ^b

Pairs of means followed by the same letter in the same column are not significantly different by the Tukey's test at 5% significance.

moderate mononuclear inflammatory infiltrate and deposition of perimysial collagen was discreet.

In the dexamethasone group (DG), for the same period of observation, a pyoserous and fibrinous crust, which was more loosened than in CG, was present with the same cell quality. Coconnective tissue showed diffuse edema with delicate fibrin strands, but with less evident vessels and some newly-formed vessels. There was evident polymorphonuclear margination. The wound edge and surrounding tissue had less marginal epithelial hyperplasia. The dermis presented clearly vessel dilation, congestion, and vascular dilatation in planes beyond the cutaneous muscle. There was intense reactivity with proliferation of perimysium fibroblasts along with proliferation of poorly differentiated mesenchymal cells. Rare remaining collagen fibers were also visualized.

The dexamethasone group treated with mesenchymal stem cells (MSCDG), after 3 days of observation, formed crust similar to that found in DG rats. The vasculature had a more branched appearance, with formation of numerous vascular buds, clear proliferative zone with discrete capillary formation as well as evident hyperplasia of the vascular endothelium. The connective tissue, in deep plane, had greater cellularity than the previous groups, with immature mesenchymal cells, but with fibroblast appearance. There were collagen fibers in larger quantities than the previous groups. Edges of the wound and surrounding tissue showed less marginal epithelium hyperplasia than CG, but more than the DG group, with slight acanthosis. The dermis presented clearly vessel dilation, congestion, and vascular dilatation in planes beyond the cutaneous muscle. There was a slight reactivity with proliferation of perimysium fibroblasts.

At day 7, rats of CG showed formation of epithelized tissue with fibroblast deposition and scar formation, with delicate collagen fibers. Rats of DG had the wound bed filled with granulation tissue with moderate, diffuse edema. Epithelization progressed

properly with presence of thin collagen fibers, disorganized and separated by elongated mesenchymal cells in large quantities. In the MSCDG group, collagen fibers were thicker and more compact. The granulation tissue was less thick, more organized and epithelialization was more pronounced, covering more the wound bed. There were elongated multinucleated cells along with the remaining end of the skeletal muscles, which did not occur in the DG group at 7 days.

The slides of the CG samples, at 15 days post-lesion, showed total epithelialization in the wound area, with the scar tissue at early in the organization process and delicate collagen fibers. There was also reactivity of skeletal muscle cells. In the DG samples, the epithelialization was in progress; however, without covering the wound. A large number of elongated cells were among the collagen fibers, which exhibit more delicate pattern in relation to the CG and the discrete presence of lymphocytic inflammatory infiltrate associated with the formed epithelium. The MSCDG group presented wound area epithelialized with scar tissue having thicker collagen fibers and less elongated cells than those of CG and DG. There was formation of dermal papillae and hyperplasia with hypertrophy of the adjacent skin appendages, which was not observed in DG.

The Cellprofler[®] analysis showed that the means of collagen fibers quantified at 15 days were 14.3 fibers in CG, 7.3 fibers in DG and 12.7 fibers in MSCDG, considering the area of 5mm².

DISCUSSION

Patients with chronic use of corticosteroids, when undergoing surgery, have their skin behaving differently from other patients and also respond to the regenerative process differently (CHOI et al., 2006; TENIUS et al., 2007). This different behavior was confirmed in the rats of the DG group, in this study, which required on average eight days more for complete healing than the animals from the other groups (CG

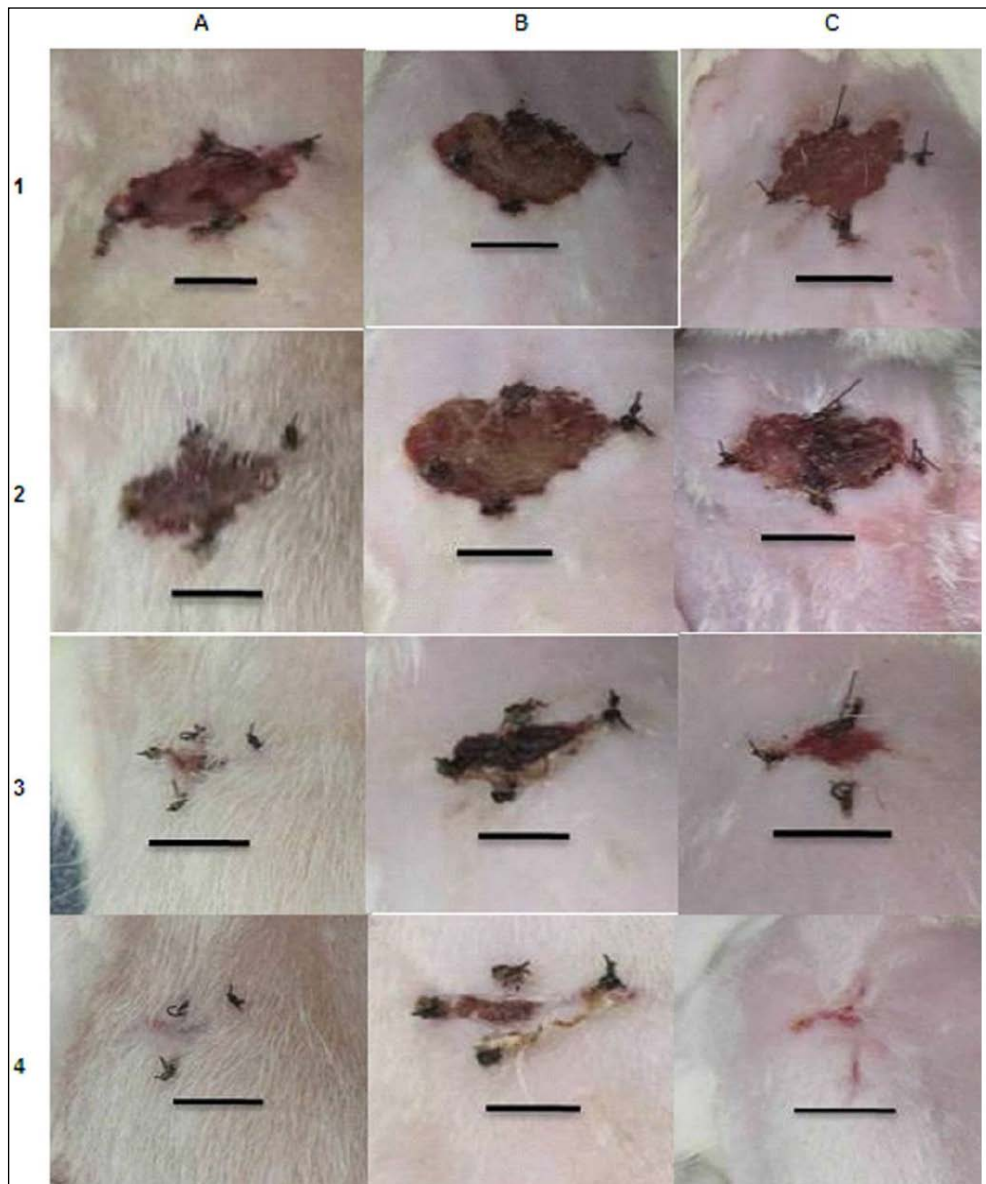


Figure 1 - Progress of skin wound healing over 15 days of observation. The table columns show the experimental groups, with control group (A), dexamethasone group (B) and dexamethasone treated with mesenchymal stem cells (C). The table rows represent the days of observation in post-surgical period, with day 1 (1), day 5 (2), day 10 (3) and day 15 (4) Scale = 1.0cm.

and MSCDG). Experimental immunosuppression should be performed only by constant monitoring of the patient, because immunocompromised patients may have complications (CHOI et al., 2006; ZARGAR-BABOLDASHTI et al., 2011). In this study, the clinical findings were the presence of eye discharge and areas of hypotrichosis in animals after 14 days of dexamethasone application.

MSC protocol used in this experiment was based on similar studies that evaluated the therapeutic

potential of this cell group in skin wounds (WU et al., 2007; MONTEIRO et al., 2012). A recent study described the allogeneic and autologous utilization of MSC in the repair of many tissues (MONTEIRO et al., 2010; MONTEIRO et al., 2012); however, the ability of these cells to restore the dermal tissue is still unclear. Even not having performed the *in situ* stem cell transplantation directly on the skin tissue and having chosen the intravenous application (lateral tail vein), it was reported in the MSCDG group a greater amount of

collagen fibers, which, at day 15, were thicker than in the other groups (MONTEIRO et al., 2010).

CG rats showed complete healing with a mean time of 14.75 days, DG rats had complete healing with a mean of 21.25 days and, in MSCDG rats, the healing process was completed on a mean time of 13.5 days. In view of the clinical evidence of improvement in the wound healing in animals treated with MSC, it is believed that the benefits for the quality of healing resulting from the use of mesenchymal stem cells may be better confirmed at evaluations carried out after 15 days, when a better cosmetic scar quality could be assessed by the organization of collagen deposition (ARGOLO-NETO et al., 2012; CASADO et al., 2014). In this study, the MSC therapy was effective in accelerating the healing process and increasing the formation of collagen fibers, similar to observed by CASADO et al. (2014) and CHUNMENG et al. (2004).

In the conditions that this experiment was performed, it was found that 0.1mg kg⁻¹ SID/SC of dexamethasone for 30 days inhibited the formation of collagen in the epithelial healing of DG rats compared to CG rats; MSC contributed to wound healing, reducing the healing time as much as in the healthy animals, indicating minimal interference of dexamethasone; the transplantation of bone marrow (BM) mesenchymal stem cells contributed positively to skin wound healing time (HT) in dexamethasone-immunosuppressed animals; the intravenous infusion was effective for the action of cells at the wound site.

ACKNOWLEDGMENTS

The authors thank the Conselho Nacional de Desenvolvimento Científico e Tecnológico (CNPq) – Process 552488/2011-9 and Fundação de Amparo à Pesquisa do Espírito Santo (FAPES) for granting the fellowships and financial support that permitted to conduct this study.

BIOETHICS AND BIOSSECURITY COMMITTEE APPROVAL

This project was approved by the Research Ethics and Animal Experimentation of University, with registration number 249/2013.

REFERENCES

ARGOLO-NETO, N.M. et al. Role of autologous mesenchymal stem cells associated with platelet-rich plasma on healing of

cutaneous wounds in diabetic mice. **Clinical and Experimental Dermatology**, v.37, p.544-553, 2012. Available from: <<http://onlinelibrary.wiley.com/doi/10.1111/j.1365-2230.2011.04304.x/pdf>>. Accessed: Dec. 01, 2014. doi: 10.1111/j.1365-2230.2011.04304.x.

CASADO, J.G. et al. Mesenchymal stem cell-coated sutures enhance collagen depositions in sutured tissues. **Wound Repair and Regeneration**, v.22, p.256-264, 2014.

CHOI, E.H. et al. Glucocorticoid blockade reverses psychological stress-induced abnormalities in epidermal structure and function. **American Journal of Physiology Regulatory, Integrative and Comparative Physiology**, v.29, p.1657-1662, 2006. Available from: <<http://ajpregu.physiology.org/content/291/6/R1657>>. Accessed: Dec. 05, 2014. doi: 10.1152/ajpregu.00010.2006.

CHUNMENG, S. et al. Effects of dermal multipotent cell transplantation on skin wound healing. **Journal of Surgical Research**, v.12, p.13-19, 2004. Available from: <[http://www.journalofsurgicalresearch.com/article/S0022-4804\(04\)00171-4/pdf](http://www.journalofsurgicalresearch.com/article/S0022-4804(04)00171-4/pdf)>. Accessed: Dec. 06, 2014. doi: 10.1016/j.jss.2004.04.008.

DEL CARLO, R.J. et al. Células tronco e fatores de crescimento na reparação tecidual. **Ciência Veterinária nos Trópicos**, v.11, p.167-169, 2008.

MARTIN, P. Wound healing – aiming for perfect skin regeneration. **Science**, v.276, p.75-81, 1997. Available from: <<http://www.sciencemag.org/content/276/5309/75.full>>. Accessed: Nov. 20, 2014. doi: 10.1126/science.276.5309.75.

MONTEIRO, B.S. et al. Treatment of critical defects produced in calvaria of mice with mesenchymal stem cells. **Anais da Academia Brasileira de Ciências**, v.84, p.841-851, 2012.

MONTEIRO, B.S. et al. Mesenchymal stem cell. **Ciência Rural**, v.40, p.238-245, 2010.

RICHARDSON, M. Acute wounds: an overview of the physiological healing process. **Nurs Times**, v.100, p.50-53, 2004. Available from: <<http://www.nursingtimes.net/nursing-practice/specialisms/wound-care/acute-wounds-an-overview-of-the-physiological-healing-process/204990.article>>. Accessed: Dec. 05, 2014.

TENIUS, F.P. et al. Effects of chronic use of dexamethasone on cutaneous wound healing in rats. **Anais Brasileiros de Dermatologia**, v.2, p.141-149, 2007.

WU, Y. et al. Mesenchymal stem cells enhance wound healing through differentiation and angiogenesis. **Stem Cells**, v.25, p.2648-2659, 2007. Available from: <<http://onlinelibrary.wiley.com/doi/10.1634/stemcells.2007-0226/abstract;jsessionid=C0A3DBEFA5D8AD9E1CBD1CB2477DC44A.f04t03>>. Accessed: Nov. 16, 2014. doi: 10.1634/stem cells.2007-0226.

ZARGAR-BABOLDASHTI, N. et al. Platelet-rich plasma protects tenocytes from adverse side effects of dexamethasone and ciprofloxacin. **American Journal of Sports Medicine**, v.39, p.1929-1935, 2011.