

# Anticipated Benefit: a new protocol for orthognathic surgery treatment that eliminates the need for conventional orthodontic preparation

Jorge Faber\*

## Abstract

**Introduction:** Conventional orthodontic-surgical treatment for the correction of dentofacial deformities takes up a lengthy period of time preparing the patient orthodontically, which sometimes causes a temporary deterioration in the patient's appearance. This fact has set the stage for the development of a new treatment technique aimed at addressing these issues. **Objectives:** To introduce a new protocol—named Anticipated Benefit—and to illustrate it with a clinical case. **Methods:** The planning stages are presented and then illustrated by treating a patient with a Class III deformity. According to this method, after some careful planning the orthodontic appliance is fixed and subsequently orthognathic surgery is performed. **Conclusion:** Although both the traditional and the Anticipated Benefit techniques provide excellent functional and aesthetic results, the new protocol achieves significant improvements soon after the start of treatment. The new method has proved very convenient, particularly for the patient.

**Keywords:** Orthognathic surgery. Dentofacial deformities. Orthodontic preparation.

## INTRODUCTION

Conventional orthodontic-surgical treatments for the correction of dentofacial deformities comprise—after diagnosis and treatment plan—a presurgical orthodontic stage, the orthognathic surgery *per se* and the orthodontic finishing stage.<sup>1</sup> This treatment method has also been tested by time. It has been used for decades and proved very effective. However, it has limitations because when patients decide to undergo

the treatment they have to wait for almost a year and a half for the surgery<sup>2</sup> and in most cases patients see their facial appearance worsen during this period. This is a paradox, as many patients who seek treatment expect to gain some aesthetic improvement,<sup>3,4,5,6</sup> although the treatment produces a significant functional effect.

This limitation led me to develop and use in my private practice, since 2004, a treatment methodology that anticipates surgery. Applied

\* Editor of the Dental Press Journal of Orthodontics. PhD in Biology – Morphology by the Electronic Microscopy Lab – University of Brasília. MSc in Orthodontics and Facial Orthopedics – Federal University of Rio de Janeiro.

after the diagnostic phase, this protocol is based on planning extensively all treatment stages, installing the orthodontic appliance, operating on the patient and only then proceeding with the orthodontic treatment.

This methodology anticipates the benefits derived from surgery and, accordingly, has been named Anticipated Benefit. It does not change the surgical technique significantly but rather the orthodontic treatment, which becomes more complex as it incorporates skeletal anchorage in most of the cases and requires a commitment by the orthodontist to achieve the goals established at the beginning of treatment. This article aims to describe this protocol by means of a case report.

#### **ESTABLISHING THE GUIDELINES FOR AN ORTHODONTIC-SURGICAL TREATMENT**

The first step is diagnosis, followed by a definition of the treatment guidelines and finally the treatment plan. The diagnosis—which requires anamnesis, physical and complementary examination—is essential. It provides guidance to the surgeon and the orthodontist regarding the needs of the case. However, the diagnosis does not change with this protocol. I therefore suggest the reading of specific articles on this subject.<sup>7,8,9</sup> Once the diagnosis is ready the treatment is outlined. It might involve, for example, combined surgery of the maxilla and mandible for the correction of a Class III deformity. This approach is discussed with the patient and, if necessary, it is also discussed with the persons responsible for the patient. A technically ideal treatment is not always indicated for a specific patient. Cultural, social and economic aspects may have a bearing on the decision made by the patient. However, the doctor should advise the patient of the pros and cons of each treatment option.

Once the patient makes an informed decision the treatment plan is established.

#### **COMBINED TREATMENT OF DENTOFACIAL DEFORMITIES**

The treatment plan requires an integration of every specialty involved in the case. Thus, when a dentofacial deformity is treated by orthognathic surgery there will be at least two distinct but compatible plans, i.e., the orthodontic and surgical plans. Occasionally, a periodontal, prosthetic, restorative treatment, among others, may also be necessary.

In this article, we will focus our discussion on the orthodontic and surgical plans.

#### **Orthodontic plan**

Orthodontic plans are very complex and require that the professional possess a solid background. A treatise in orthodontics is not sufficient to encompass every aspect of the treatment plan. Thus, I will refrain from going into interdisciplinary details or matters that extend beyond the limits of a treatment in which the patient typically has a healthy, non-reduced periodontium with every tooth in place up to the second molars.

One decision should be made at the very start when performing the cephalometric tracing, namely, the final position of the upper and lower incisors. Next, it is very important to carefully assess incisor exposure during resting and smiling. The tracing should take into account both the inclination and the anteroposterior and vertical positions of these teeth. If the professional wishes to make any orthodontic changes in the maxillary or mandibular planes involving the intrusion or extrusion of the posterior teeth then this is the moment to plan it. However, these changes, related to open bite treatments,<sup>10</sup> are very rarely implemented.

Once these positions are established, it is necessary to analyze the cast models and sometimes the patient him/herself. It is necessary to verify that there is appropriate periodontal structure to support tooth movement.

In addition, it is important to evaluate if there is enough space for such movements. For instance, when the upper molars are distalized it is necessary to verify if there is enough space on the tuberosity for the movement. If these changes are feasible, then one can proceed as planned. Otherwise, it is necessary to check it over again. Once incisor position has been established, the next step is making a set-up that simulates the desired orthodontic tooth movement. This technique has been described in detail in other publications.<sup>11,12</sup> The purpose of the set-up is to allow the viewing of the tooth movement as a whole. With it, it is possible to see the prosthetic spaces at the end of treatment, detect the need for dental extractions, adjust the Bolton discrepancies, etc. However, above all, the set-up allows professionals to identify the anchorage required by each case.

After a realistic evaluation of the treatment, tooth movement is transferred to the cephalometric tracing. The molars are traced in their initial and final orthodontic treatment positions.

Currently, I use only *in silico* set-ups, i.e., on the computer. However, I apply the exact same principles used on cast model set-ups.

### **Surgical plan**

Once the orthodontic treatment is viewed on the set-up the surgical plan can be performed. At this time, since there was no orthodontic treatment prior to surgery, the surgeon and the orthodontist should consider both the initial and the final tooth positions, after orthodontics. The surgical prediction tracing is performed along the same lines as the conventional tracing. The only difference is the fact that the whole plan should be carried out with the initial and final tooth positions included in the tracing and using different colors.

### **Orthognathic surgery**

The surgical procedure itself does not

change. But some details should be considered by both surgeon and orthodontist.

The first pertains to the need for interocclusal acrylic trays after surgery. The trays enable the surgeon to find the position of the osseous fragments and give the orthodontist any hints as to the risk of surgical relapse during the first post-operative days. This is because any change in the occlusal relationship can be easily identified by an improper fitting of the tray on the dental arches.

The second detail relates to intermaxillary fixation. The establishment of a intermaxillary fixation after surgery depends on several factors which will not be discussed here such as, for instance, the fragility of the osseous fragments or a bad split. However, a transurgical fixation is almost always necessary. Thus, since the patient is not submitted to an orthodontic preparation and the surgery is performed in the aligning and leveling stages of treatment, specific arrangements are needed for the fixation.

The arrangements may be the preparation of passive rectangular arch wires with prewelded hooks, brackets with hooks on the cuspids and bicuspid, or Kobayashi hooks. Occasionally, intermaxillary screws may be required. Such screws are similar to mini-implants and are inserted directly into the bone through the gingiva while elastics or stainless steel wires are placed on the screws. Orthodontic mini-implants may be used for this purpose. In any case, however, the orthodontic arch wires must be tied with metal ligature. Elastic ligatures are not recommended given the risk that they be dropped into the surgical wound.

Personally, I do not use passive rectangular arch wires. In most cases, patients undergo surgery using active super-elastic arch wires with Kobayashi hooks. Due to the use of surgical acrylic trays for three weeks, orthodontic tooth movement is limited during the immediate post-operative stage.

### Limitations

The main limitations for surgery at the beginning of treatment are severe curves of Spee and vertical asymmetries. The curve of Spee can make it difficult to establish a predictable mandible position. When asymmetries are the challenge, it is difficult to make a proper evaluation of the occlusal plane and the surgical needs to correct the asymmetries, due to the differences in height among teeth. In both cases, a pre-surgical aligning and leveling stage is highly recommended.

### CASE REPORT

#### Diagnosis

A male patient, 18.9 years old, came to my office with a major complaint of facial disharmony. His deformity had appeared in his childhood and there were similar cases in his family, i.e., an aunt and a cousin. His condition exerted

a negative impact not only functionally but also, and very significantly so, aesthetically.

A facial analysis (Fig 1) showed a symmetric Class III dentofacial deformity with concave facial profile. The zygomaticnasolabial line was sinuous in the paranasal area with a disruption in the commissural level.<sup>7,8</sup> The nose was well proportioned with the nasal apex well positioned to the vertical (Fig 4). Tooth exposure was moderate when smiling.

The intraoral clinical examination (Fig 1) and the study model (Fig 2) showed a Class III dental relationship with upper and lower crowding. A cephalometric analysis (Table 1, Fig 4) showed a skeletal Class III and a very significant mandibular prognathism. The upper incisors were buccally tipped and the lower incisors retroclined. In turn, the panoramic (Fig 3), cephalometric (Fig 4) and periapical X-rays of the whole mouth showed a Class III

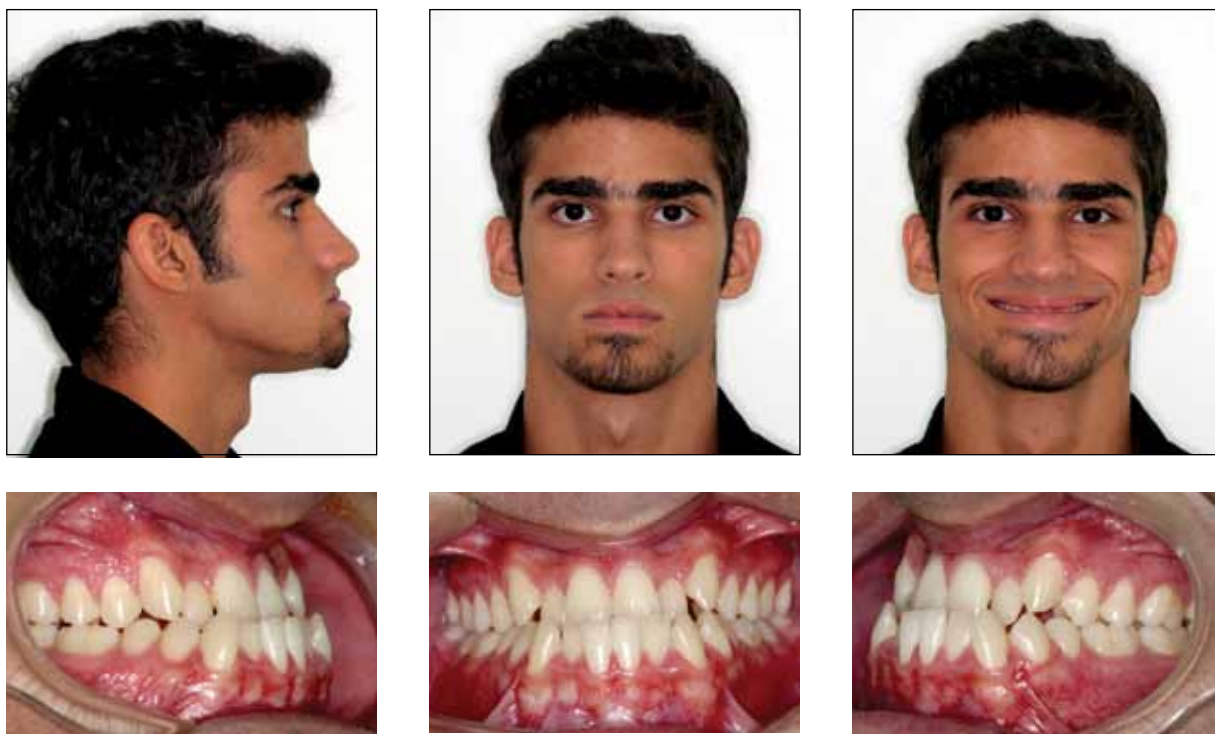


FIGURE 1 - Pretreatment extraoral and intraoral photographs.

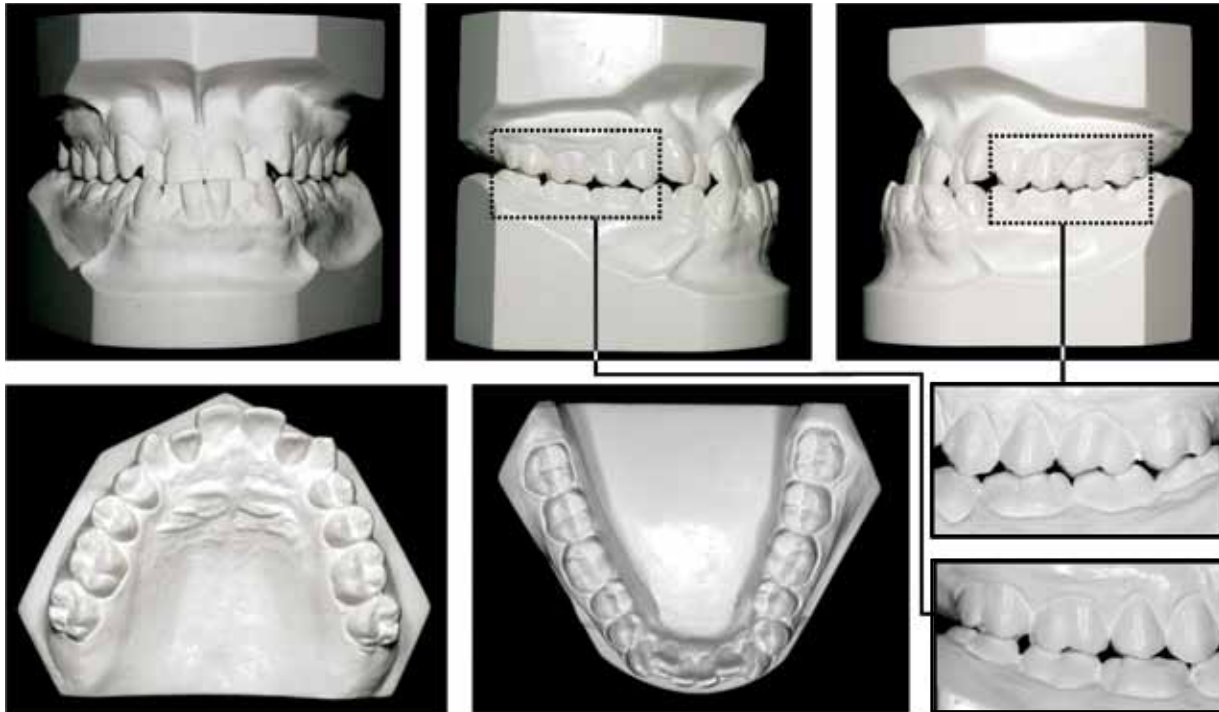


FIGURE 2 - Pretreatment study models. The tracing areas are augmented on the lower right corner. Note the Class III relationship.

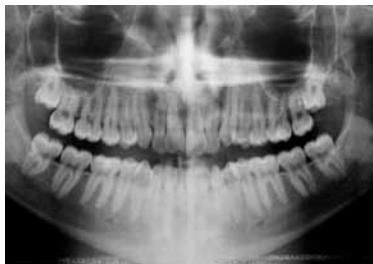

FIGURE 3 - Pretreatment panoramic X-ray.

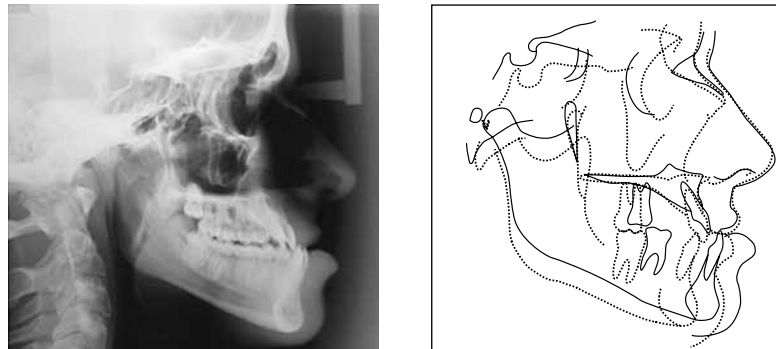


FIGURE 4 - Cephalometric X-ray and pretreatment tracing (continuous line). The pretreatment tracing is overlying the Bolton standard tracing. Note that the superimposition shows the maxilla in a good anteroposterior position, but vertically deficient. The nose is well proportioned ("Bolton Standards of Craniofacial Development & Growth", Bolton-Broadbent-Golden, Case Western Reserve University - Cleveland, Ohio).

deformity as well as good periodontal and dental health. The third molars were in place.

The diagnosis was Class III dentofacial deformity with a Class III malocclusion. The skeletal relations were determined by a significant mandibular prognathism associated with mild to moderate anteroposterior and vertical deficiencies of the maxilla.

### Treatment options

After finalizing the diagnosis, guidelines were established for the treatment. It consisted in the orthodontic-surgical correction of the deformity combining a mandibular setback with potential maxillary advancement. All the treatment options included orthodontic treatment and orthognathic surgery using the Anticipated Benefit protocol. Third molars would be extracted during the orthognathic surgery. The alternatives were:

1. Mandibular setback combined with maxillary advancement. In this treatment option, the mandible would be set back and the maxilla advanced. The lower teeth would be protruded and the upper teeth retracted.

2. Mandibular setback associated with paranasal graft. In this case, there would be no maxillary advancement; the paranasal areas would receive an autogenic or haloplastic graft.

3. Mandibular setback. In this alternative, the maxilla would not be advanced and the paranasal areas would not be filled. The patient and his family chose this treatment option.

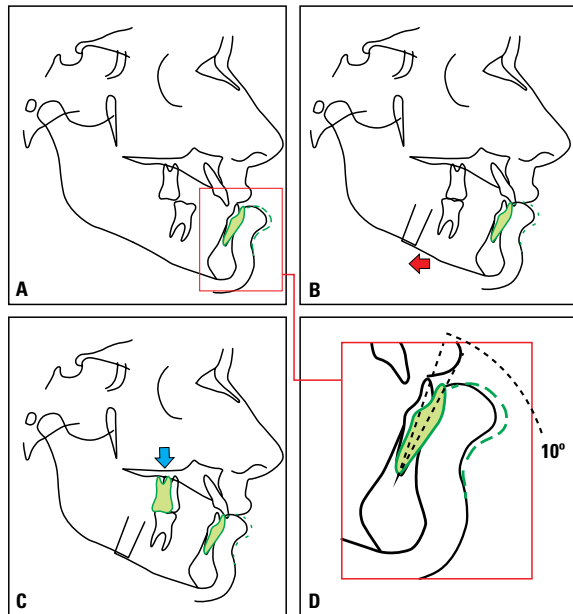
### Treatment plan

The first step in the treatment plan was to establish the final position for the upper and lower incisors. Here, the choice was to keep the upper incisors in position to prevent the upper lip from retracting. This decision was based on aesthetics, as there would be no maxillary advancement. Furthermore, it was also in the plan to protrude the lower incisors. All these tooth

TABLE 1 - Pretreatment, post-operative and final cephalometric measurements.

MEASUREMENT	VALUE	INITIAL	POST-OPERATIVE (AFTER 2 WEEKS)	FINAL (15 MONTHS AFTER THE START)
<b>ANTEROPOSTERIOR ANALYSIS</b>				
SnV - ULP	1 to 2 mm	1 mm	0 mm	0 mm
SnV - LLP	0 to -1 mm	8 mm	-3 mm	-1 mm
SnV - Po'	-1 to -4 mm	3 mm	-10 mm	-6 mm
nasolabial angle	110°	110°	113°	108°
<b>VERTICAL ANALYSIS</b>				
1/Stms	1 to 4 mm	1 mm	-1 mm	0 mm
G - Sn	50%	50,4%	48,5%	50,7%
Sn - Me'	50%	49,6%	51,5%	49,3%
Sn - Stms	33% of lower half	29,8%	30%	30%
Stmi - Me	66% of lower half	70,2%	70%	70%
ILG	0 to 3 mm	1 mm	0	0
<b>INCISORS POSITION ANALYSIS</b>				
1/ - HP	114° to 116°	124°	125°	127°
1/ - PP	110° ± 5°	125°	125°	127°
/1 - GoMe	95 ± 5°	80°	81°	89°
<b>HARD TISSUE ANALYSIS</b>				
NPer - A	1 mm	1 mm	2 mm	0.5 mm
NPer - B	-3 mm	11 mm	-3 mm	0
GoGn-SN	32	21°	26°	25°

movements are similar to when the patient is treated conventionally with orthodontic preparation. Cephalometrics was used<sup>13</sup> to establish the protrusion for the lower incisors. Initially, they were 10° towards the lingual (Table 1). Thus, the plan was to protrude them by 10° (Fig 5, A and D). The lower lip was protruded by 80% of the tooth movement. Nevertheless, no adequate algorithms for predicting lip movement are available to this date for any planning scenario, be it conventional or Anticipated Benefit. As soon as the position for the anterior teeth was established, it was possible to plan the mandibular retraction. It was achieved by



**FIGURE 5 - A** To the pretreatment cephalometric tracing, in black, overlies, in green, the incisor and the lower lip positions. The lower lip had 80% of tooth movement predicted protrusion. **B** The red arrow emphasizes the mandible draw back to a proper incisors relationship. The occlusal plane was used as a reference for the posterior sliding of the mandible. Note that the dental relationship of the posterior teeth is a Class II relationship. **C** After working on the set-up to establish a correct position for the posterior teeth, these positions were traced (blue arrow). In this case, the upper incisors and the lower molars did not change their anteroposterior relationship. The red square in **A** is emphasized in **D**), showing the 10° change in the lower incisors angulation. The treatment plan was discussed with the surgeons who operated the patient (Dr. Frederico Salles and Dr. Marcos Anchieta).

sliding the partial tracing of the mandible towards the posterior region along the occlusal plane until the incisors reached a proper relationship in their final position (Fig 5, B). From this new position, the predicted results could be evaluated. It is important to emphasize that the patient, who had dental and skeletal Class III relationship, would have his osseous base ideally positioned. This would give him—and in fact did—a balanced facial profile. However, the dental relationship would change to a Class II. In some situations from this point on it may be necessary to reassess the results planned for the treatment. Sometimes, it is necessary to consider other treatment options, which may

include other dental and skeletal movement combinations and, sometimes, additional discussion between orthodontist, surgeon and patient.

This was not the case in this treatment. After the position for the anterior teeth was established, it was necessary—as in most cases—to view the position of the posterior teeth on the set-up. I have been using for some time now set-up procedures that are similar to those used on cast models.<sup>11,12</sup> Nonetheless, I scan the models with a 3D scanner, sectioning the teeth with a computer program and thereby establishing the movements.

My clinical experience suggests that this technique takes less working time than the traditional one, allowing as many treatment combinations as possible. Additionally, the set-up findings can be used to assist in communicating with the patient. A demonstration of this technique will be presented in another upcoming article. In the treatment reported here the set-up findings showed that the planned movement allowed an adequate dental relationship at the end of treatment (Fig 6). It was also clear that a minor retraction of the upper posterior teeth would be necessary (video 1, available at [www.dentalpress.com.br/journal](http://www.dentalpress.com.br/journal)). The same study showed that positioning the lower incisors with a protrusion of 10° would enable the alignment of the lower dental arch with no need for stripping or any additional maneuver (video 2, available at [www.dentalpress.com.br/journal](http://www.dentalpress.com.br/journal)). All the data collected studying the set-up was important to determine which anchorage devices to use. Two mini-plates were used on the maxilla to retract the posterior teeth by 2 mm. These mini-plates were inserted during the orthognathic surgery. Tooth movement was transferred to the cephalometric tracing (Fig 5, C).

### Treatment progress and results

After the orthodontic and surgical plans had

been defined the fixed orthodontic appliance was installed with 0.022 x 0.028-in preadjusted brackets on both dental arches. Bands were placed on the molars, except the upper second molars.

The purpose was to facilitate extraction of the upper third molars. NiTi 0.014-in arch wires were engaged immediately after appliance installation.

The patient underwent surgery after appliance installation. During the 11 mm mandibular setback surgery mini-plates were placed on the maxilla for anchorage to retract the upper posterior teeth. The third molars were extracted.

An interocclusal tray was made and served as reference on two occasions. Firstly, to establish fragment relationship during surgery and secondly, to clinically follow up on surgical stability for a period of three weeks. Two weeks after surgery, the facial aspect showed

significant improvement (Fig 7). After surgery, the dental relationship was that of a Class II but with facial Pattern I. Upper and lower crowding did not change (Fig 7). The mandibular setback was considerable and caused very important cephalometric changes (Table 1, Fig 8).

After a three-week post-operative period, NiTi springs were placed from the mini-plates to the upper cuspids. Buccal tubes were bonded to the second molars and these teeth were included in the treatment. The activation aimed at distalizing the upper teeth, creating spaces for upper-anterior alignment. The springs were kept in place as the aligning and the leveling arch wires progressed with treatment. On the lower dental arch the arch wires progressed gradually from 0.014-in NiTi to a 0.017 x 0.025-in stainless steel arch wire.

During finishing, intermaxillary elastics were used for a short period of time to improve

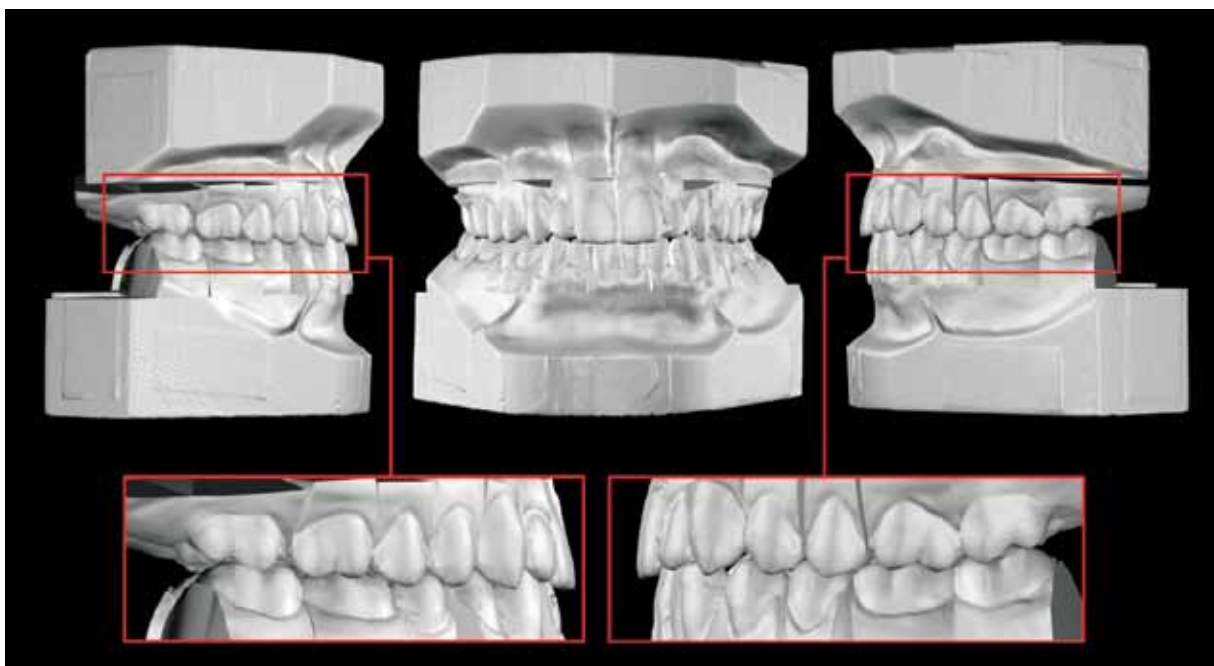


FIGURE 6 - Surgical computerized set-up of the treatment. Study models were scanned in a 3D scanner; teeth were crosscut, in a computer program, and tooth movement established. General procedures applied to the virtual set-up are the same as the ones applied to the physical models. The red squares show details of the teeth relationship after the proposed tooth movement and the mandible draw back.



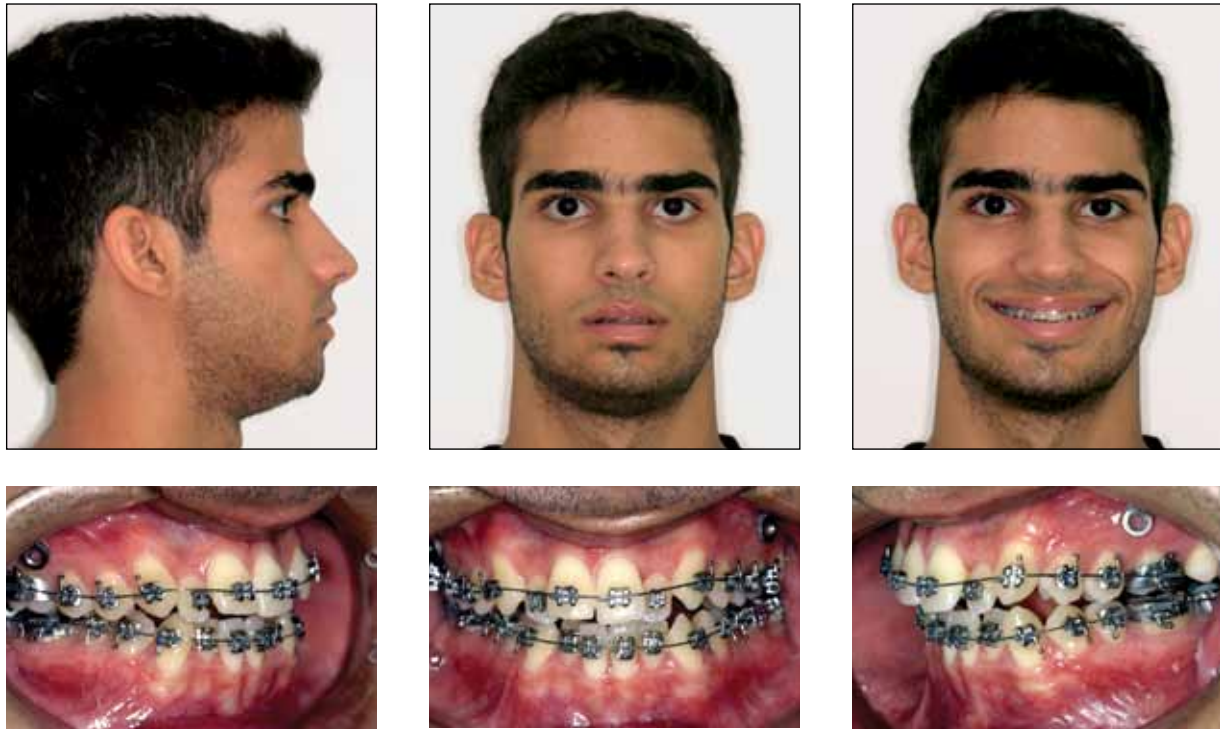


FIGURE 7 - Two weeks after surgery, the facial appearance presented some edema yet. After surgery, the malocclusion was a Class II malocclusion. But, the patient had already a face pattern I (surgeons Drs. Frederico Salles and Marcos Anchieta).

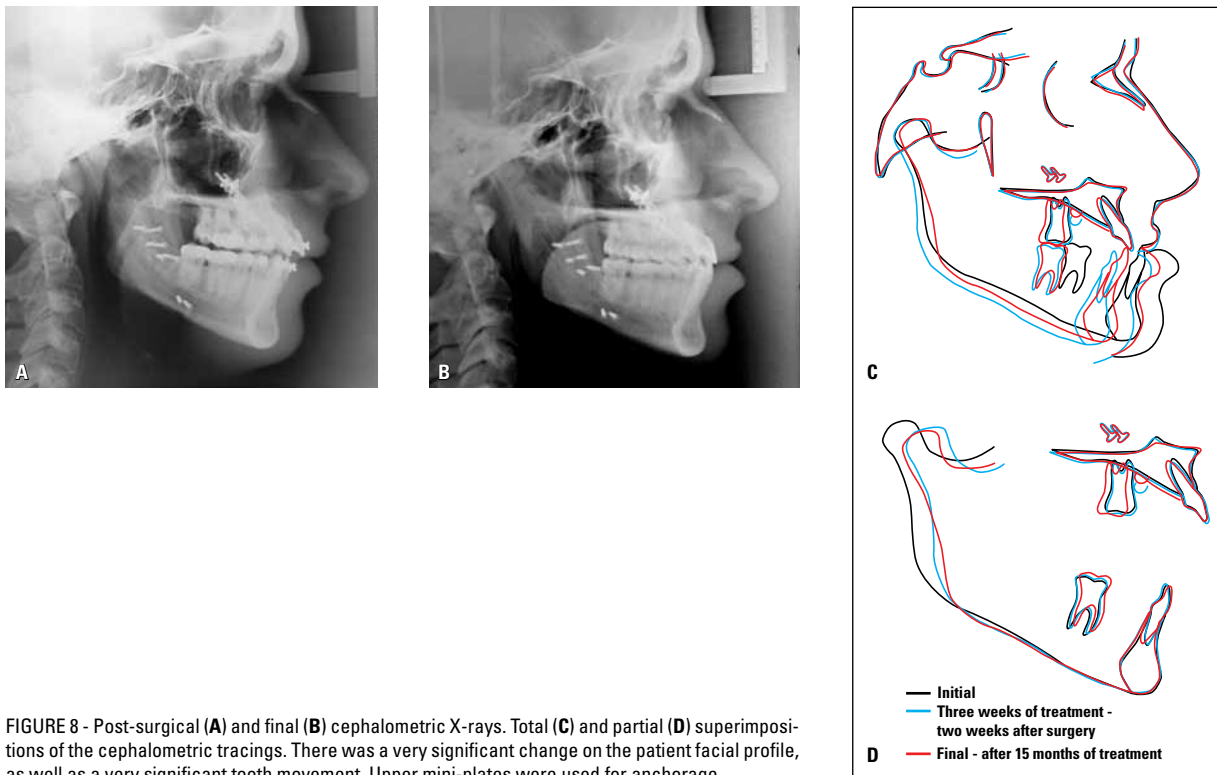


FIGURE 8 - Post-surgical (A) and final (B) cephalometric X-rays. Total (C) and partial (D) superimpositions of the cephalometric tracings. There was a very significant change on the patient facial profile, as well as a very significant tooth movement. Upper mini-plates were used for anchorage.

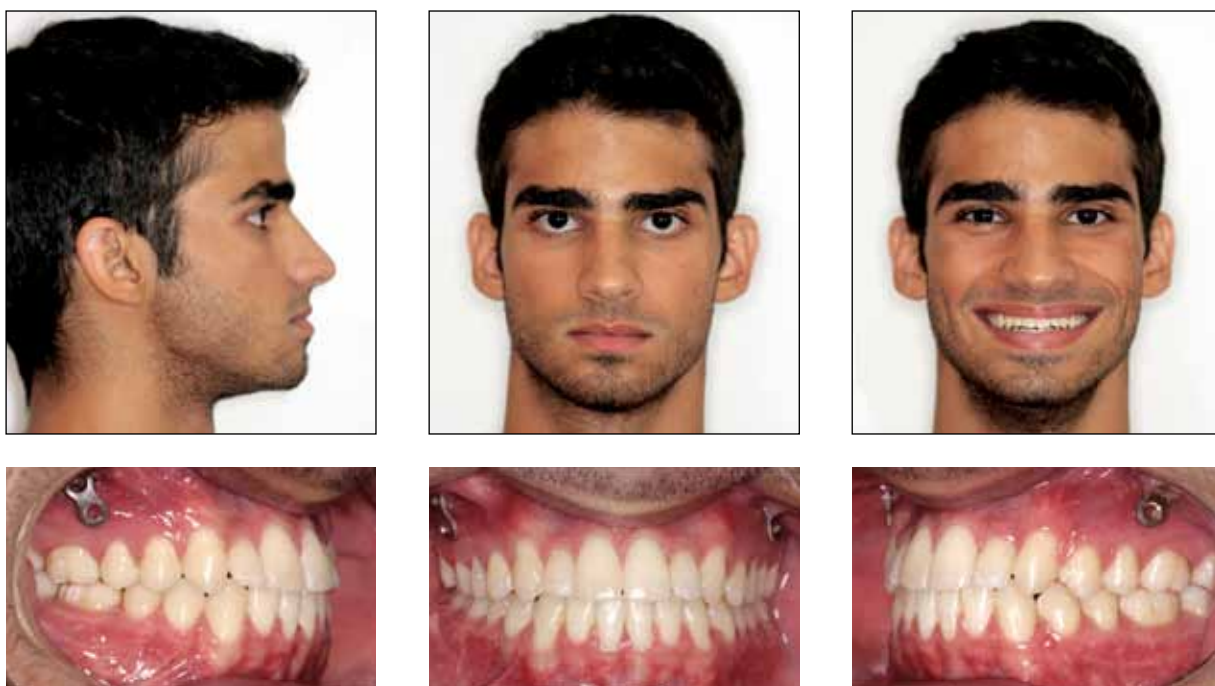


FIGURE 9 - Extraoral and intraoral photographs in the end of treatment (surgeons Drs. Frederico Salles and Marcos Anchieta).

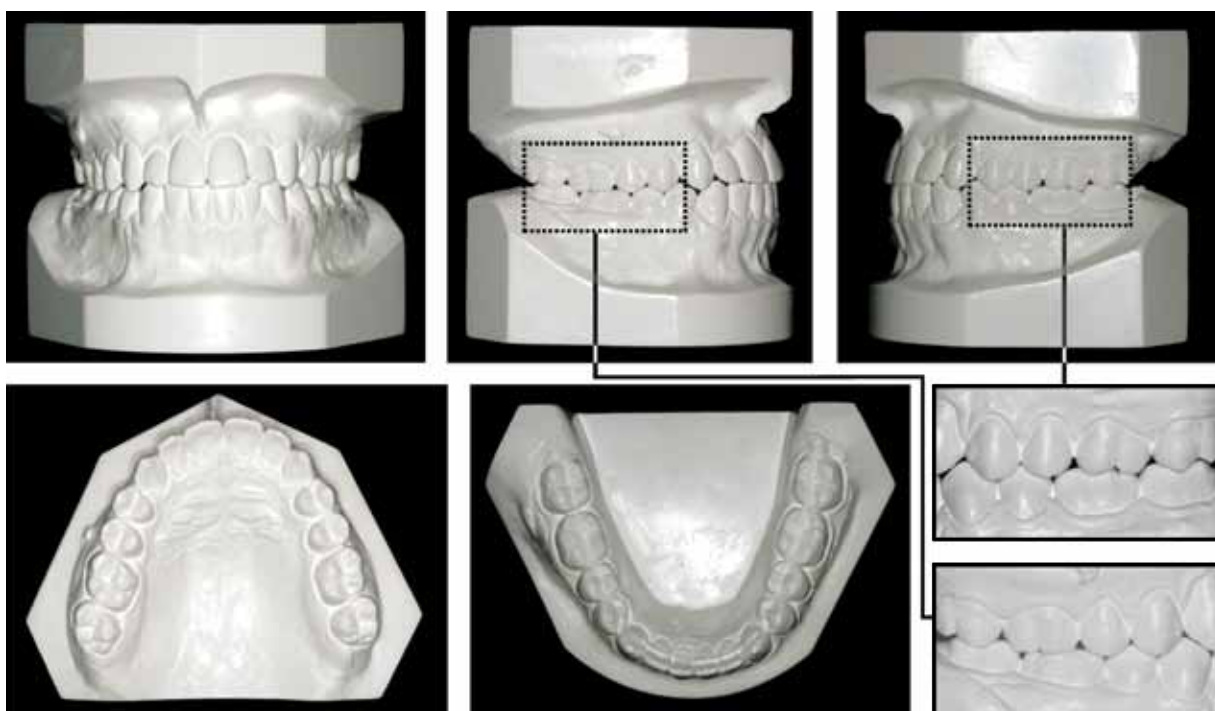


FIGURE 10 - Study models in the end of treatment. The tracing areas are augmented in the lower right corner. Note the molars relationship.

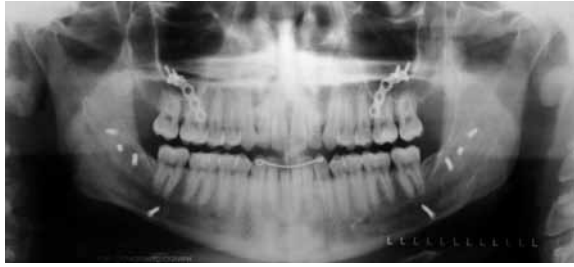

FIGURE 11 - Final panoramic X-ray.

intercuspatation. The patient was very pleased with the end result of treatment as reflected in both facial aesthetics and occlusion. The appliance was removed after 15 months of treatment. A wraparound type removable appliance was used on the upper arch and a 3 x 3 fixed retainer was bonded on the lower arch.

Two years after treatment (Fig 12), the occlusion remained stable.

## DISCUSSION

An orthodontic-surgical treatment that deploys the Anticipated Benefit technique offers valuable advantages to patients. These advantages stem from the fact that the period of conventional orthodontic preparation is eliminated and surgery anticipated. Both techniques provide excellent functional and aesthetic results (Fig 13, C and 14, C). However, by anticipating surgery the treatment focus can be shifted to the patient. Application of the new protocol is justified insofar as it brings about significant improvement of serious health problems, such as obstructive sleep apnea, as well as facial aesthetic issues, right from the start of treatment (Fig 14, A and B).

Therefore, patients are spared the deterioration of their facial appearance typical of most conventional treatments (Fig 13, A and B), particularly in the treatment of Class III deformities. The facial aesthetic deterioration

that accompanies conventional treatment is a paradox. A large number of patients who undergo orthognathic surgery seek aesthetic improvement,<sup>3-6</sup> although the surgery also affords palpable functional gains.<sup>14</sup> In order to benefit from such aesthetic gains, however, patients must endure a transitional—17 months, on average—period of facial aesthetic deterioration.

The core of this technique relies on very careful orthodontic planning. It does not change the diagnosis of dental deformities but makes the treatment plan more demanding as it incorporates the need for viewing the orthodontic goals in the cephalometric tracing and on the set-up.

The set-up plays a vital role in determining the final position of posterior teeth. This prediction is relevant not only for academic purposes but also because it assists the orthodontist in the patient's final occlusion and in identifying the anchorage needs. However, the set-up is not necessary in every single case and can be offset by a professional's skill in treating similar cases.

Perhaps the best general rule one can apply to set-ups is to use one every time there is any doubt about the treatment, especially about anchorage and prosthetic spaces. When using Anticipated Benefit, skeletal anchorage is essential in most but not all cases.

My clinical experience shows that the use of mini-plates as anchorage is an advantage in many treatments, as reported in this article. A very similar article was published recently.<sup>15</sup> However, in some cases mini-implants can be used and skeletal anchorage may not be necessary. Nevertheless, it should be underscored that skeletal anchorage increases orthodontic tooth movement predictability.<sup>10,16,17</sup> This is what makes it possible for tooth movement—which would normally be implemented prior to surgery, according to the conventional treatment method—to be carried out, in many cases,

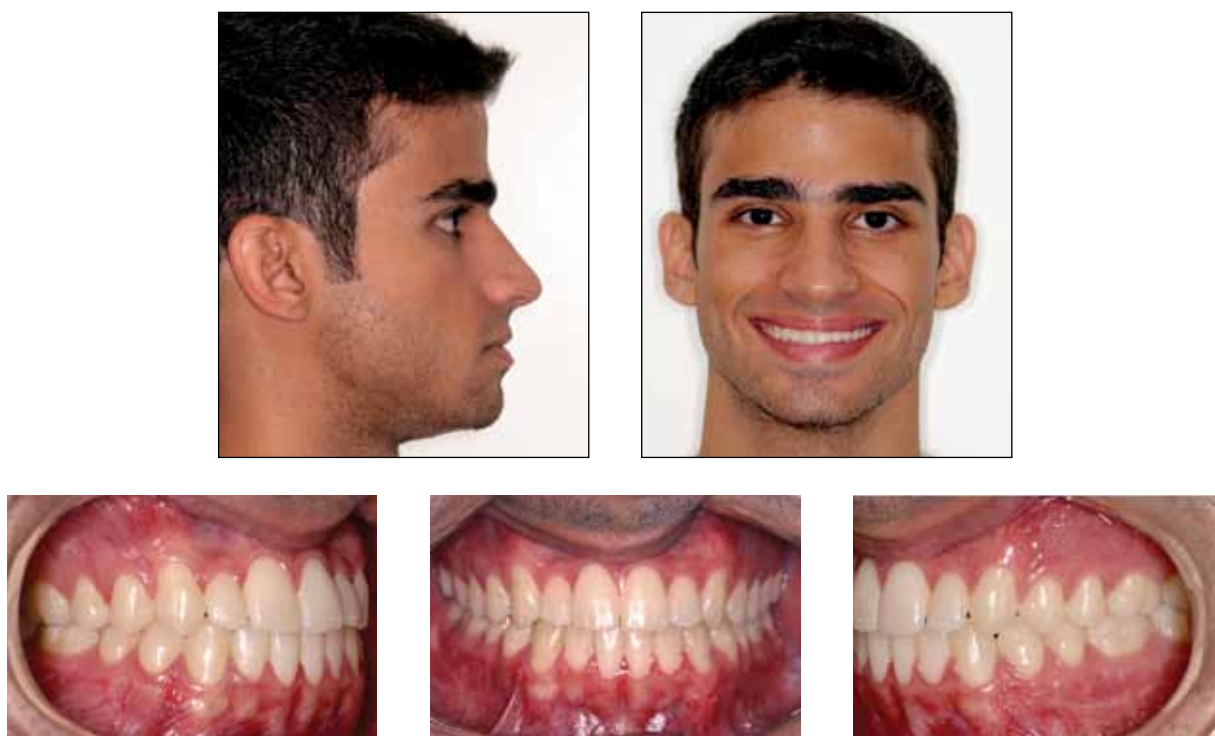

FIGURE 12 - Extraoral and intraoral photographs two years after the end of treatment (surgeons Drs. Frederico Salles and Marcos Anchieta).

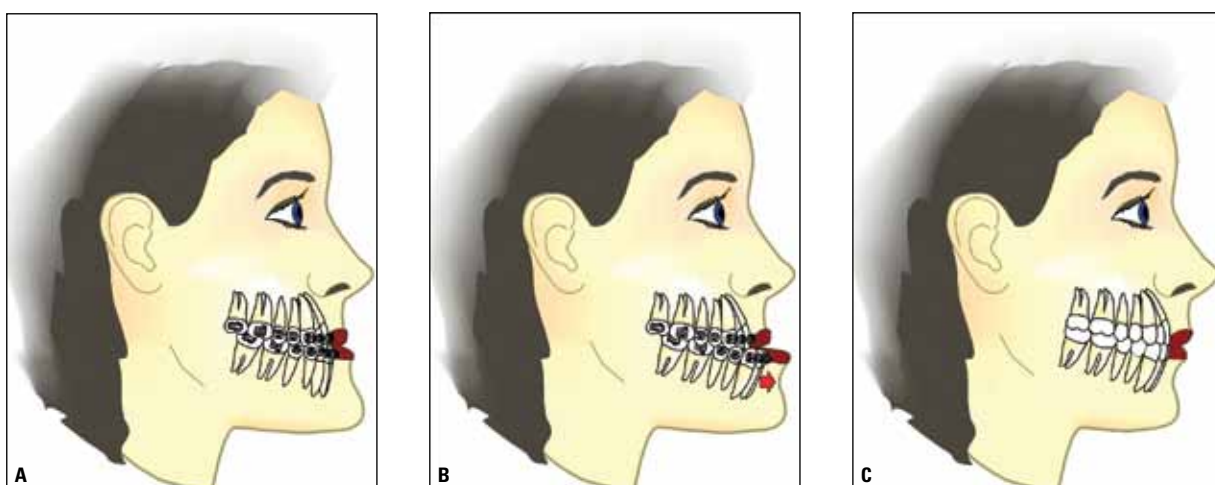


FIGURE 13 - Orthodontic-surgical treatment using the conventional method. **A)** Illustration of a Class III deformity. After orthodontic preparation (**B**), with distal movement of the lower incisors (**arrow**), worsening of the facial pattern III. End of treatment with well-balanced results (**C**).

after the orthognathic surgery.

Although the orthodontic plan is more complex than conventional treatment, surgical plans are not. Surgeons, however, should be

aware of all orthodontic steps taken throughout the treatment. This means that there should be better communication between orthodontist and surgeon than in conventional treatment.

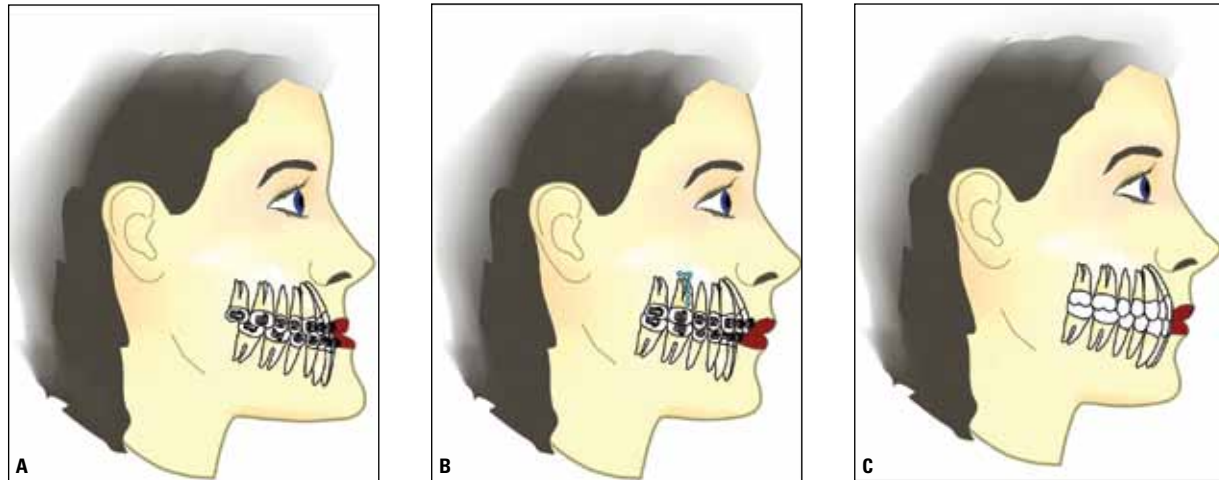


FIGURE 14 - Illustration of an orthodontic-surgical treatment of Anticipated Benefit. **A)** Pretreatment. **B)** The deformity soon after the orthognathic surgery, without orthodontic conventional preparation. Very significant facial change to a facial pattern I, but, the lips do not show a correct relation yet. Mini-plates are used to retract the upper teeth. **C)** End result of treatment very similar to the conventional method.

Orthodontists must feel reassured that surgeons will be able to implement the treatment plan. Surgeons, in turn, must feel confident that orthodontists will finalize the patient's occlusion in a relationship such as the one shown in Figure 7.

It should be emphasized that Anticipated Benefit treatment changes to the dental relationship differ significantly from conventional treatment. In this new method, one type of malocclusion is replaced by another and the new malocclusion is subsequently treated (Fig 14, A and B). In other words, due to the typical pattern of tooth positions in Class III deformities, after surgery the patient will exhibit a balanced facial appearance but very likely combined with a Class II malocclusion (Fig 14, A, B and C). The opposite is true of Class II deformities.

This means that the general pattern of tooth movement accomplished by this new treatment option is very similar to the conventional method except that orthodontic tooth movement tends to occur faster. This probably happens

because tooth movement benefits from—instead of countering—muscular forces, as is the case in the conventional treatment. Furthermore, this factor may— at least partly—account for the fact that most treatments that use this approach require a shorter time period.

## CONCLUSION

In summary, the Anticipated Benefit orthodontic-surgical treatment applies the principles reported in the dental literature to reverse treatment stages and anticipate the surgery. It provides some key advantages such as faster improvement of both aesthetics and function, averting the temporary deterioration of facial aesthetics often found in many treatments of dentofacial deformities.

## ACKNOWLEDGEMENTS

I would like to thank Drs. Frederico Salles, Marcos Anchieta, João Milki Neto and Rogério Zambonato Freitas for their team-work and for dedicating their expertise to the treatment of patients using the Anticipated Benefit protocol.

Drs. Frederico Salles and Marcos Anchieta were responsible for the surgical treatment reported in this article. I am also grateful to Dr. Carla Virginia Araújo Vasconcelos for providing professional services to the patient described in this article for several months in Fortaleza, Ceará State; to Dr. Lilian Fonseca, for her assistance in

illustrating this article, and to Dr. Patricia Berto, for her invaluable input, careful revision of this article and treatment of patients using the Anticipated Benefit technique.

Submitted: November 2009  
Revised and accepted: December 2009

## REFERENCES

- Jacobs JD, Sinclair PM. Principles of orthodontic mechanics in orthognathic surgery cases. *Am J Orthod.* 1983; 84:399-407.
- Luther F, Morris DO, Hart C. Orthodontic preparation for orthognathic surgery: How long does it take an why? *Br J Oral Maxillofac Surg.* 2003 Dec;41(6):401-6.
- Ambrizzi DR, Franz SA, Pereira Filho VA, Gabrielli MAC, Gimenez CMM, Bertoz FA. Avaliação das queixas estético-funcionais em pacientes portadores de deformidades dentofaciais. *Rev Dental Press Ortod Ortop Facial.* 2007 set/out;12(5):63-70.
- Forssell H, Finne K, Forssell K, Panula K, Blinnikka LM. Expectations and perceptions regarding treatment: a prospective study of patients undergoing orthognathic surgery. *Int J Adult Orthodon Orthognath Surg.* 1998;13(2):107-13.
- Vargo JK, Gladwin M, Ngan P. Association between ratings of facial attractiveness and patients motivation for orthognathic surgery. *Orthod Craniofac Res.* 2003 Feb;6(1):63-71.
- Williams AC, Shah H, Sandy JR, Travess HC. Patients motivations for treatment and their experiences of orthodontic preparation for orthognathic surgery. *J Orthod.* 2005 Sep;32(3):191-202.
- Arnett GW, Bergman RT. Facial keys to orthodontic diagnosis and treatment planning - part I. *Am J Orthod Dentofacial Orthop.* 1993;103:299-312.
- Arnett GW, Bergman RT. Facial keys to orthodontic diagnosis and treatment planning - part II. *Am J Orthod Dentofacial Orthop.* 1993;103:395-411.
- Arnett GW, Gunson MJ. Facial planning for orthodontists and oral surgeons. *Am J Orthod Dentofacial Orthop.* 2004;126:290-5.
- Faber J, Morum TFA, Leal S, Berto PM, Carvalho CK dos S. Miniplates allow efficient and effective treatment of anterior open bites. *Rev Dental Press Ortod Ortop Facial.* 2008 set/out;13:144-57.
- Bolognese AM. Set-up: uma técnica de confecção. *Rev SOB.* 1995;2:245-9.
- Tavares CAE, Zanini LK. A confecção do "Set Up" de diagnóstico ortodôntico. *Rev Dental Press Ortod Ortop Facial.* 1999 set/out;4(5):20-3.
- Bell WH, Jacobs JD, Quejada JG. Simultaneous repositioning of the maxilla, mandible, and chin treatment planning and analysis of soft tissues. *Am J Orthod.* 1986 Jan;89(1):28-50.
- Turnbull NR, Battagel JM. The effects of orthognathic surgery on pharyngeal airway dimensions and quality of sleep. *J Orthod.* 2000 Sep;27(3):235-47.
- Nagasaka H, Sugawara J, Kawamura H, Nanda R. "Surgery first" skeletal Class III correction using the Skeletal Anchorage System. *J Clin Orthod.* 2009 Feb;43(2):97-105.
- Janssen KI, Raghoebar GM, Vissink A, Sandham A. Skeletal anchorage in Orthodontics: a review of various systems in animal and human studies. *Int J Oral Maxillofac Implants.* 2008 Jan/Feb;23(1):75-88.
- Yao CCJ, Lai EHH, Chang JZC, Chen I, Chen YJ. Comparison of treatment outcomes between skeletal anchorage and extraoral anchorage in adults with maxillary dentoalveolar protrusion. *Am J Orthod Dentofacial Orthop.* 2008 Nov;134(5):615-24.

### Contact address

Jorge Faber  
Brasília Shopping Torre Sul sala 408  
CEP: 70.715-900 – Brasília/DF  
E-mail: faber@dentalpress.com.br