

Orthodontic movement of teeth with short root anomaly: Should it be avoided, faced or ignored?

Jose Valladares Neto¹, José Rino Neto², João Batista de Paiva³

Introduction: Short Root Anomaly (SRA) is an uncommon disease and a challenge for orthodontic treatment as it tends to increase the risk of root resorption. **Objective:** Assess the current status of the diagnosis, etiology and orthodontic management of teeth with SRA, and present case reports. **Method:** A literature review was carried out in PubMed, SciELO, LILACS, Scopus and Web of Science databases. **Results:** A differential diagnosis of SRA should be conducted for teeth with incomplete root formation, external apical root resorption, dentin dysplasia type I and post dental trauma root hypoplasia. SRA is genetically determined and orthodontic movement requires changes in clinical and radiographic management in order to restrict damage. **Conclusion:** Orthodontic movement of teeth with SRA is contraindicated in extreme cases, only. Caution at all stages could minimize attachment loss and lead to long-term stability.

Keywords: Tooth root. Tooth abnormalities. Root resorption. Orthodontics.

Introdução: a anomalia de raiz curta (ARC) é uma patologia incomum e constitui um desafio para o tratamento ortodôntico, pois tende a elevar o risco de reabsorção radicular. **Objetivo:** revisar a literatura sobre o diagnóstico, a etiologia e a conduta ortodôntica recomendada para esses casos, ilustrando esse tema com relatos de caso. **Métodos:** devido ao baixo nível de evidência sobre o tema, realizou-se a revisão narrativa da literatura com estratégia de busca nas bases de dados PubMed, SciELO, Lilacs, Scopus e Web of Science. **Resultados:** o diagnóstico diferencial da ARC deverá ser realizado entre dentes com rizogênese incompleta, reabsorção radicular externa apical, displasia dentinária tipo I e hipoplasia radicular pós-traumatismo dentário. A ARC apresenta determinantes genéticos para o encurtamento, e a movimentação ortodôntica exige que medidas de controle clínico e radiográfico sejam adotadas, ensejando a restrição de danos. **Conclusão:** a movimentação ortodôntica de dentes com ARC somente é contraindicada em casos extremos. A conduta cautelosa em todas as suas etapas poderá minimizar a perda de inserção e lograr em estabilidade em longo prazo.

Palavras-chave: Raiz dentária. Anormalidades dentárias. Reabsorção da raiz. Ortodontia.

» Patients displayed in this article previously approved the use of their facial and intraoral photographs.

How to cite this article: Valladares Neto J, Rino Neto J, Paiva JB. Orthodontic movement of teeth with short root anomaly: Should it be avoided, faced or ignored? *Dental Press J Orthod.* 2013 Nov-Dec;18(6):72-85.

¹ Assistant Professor, Department of Orthodontics, College of Dentistry, Federal University of Goiás (UFG).

Submitted: August 11, 2011 – **Revised and accepted:** December 03, 2011

² Associate Professor, Department of Orthodontics and Pediatric Dentistry, College of Dentistry, University of São Paulo (USP).

» The authors report no commercial, proprietary or financial interest in the products or companies described in this article.

³ Full Professor, Department of Orthodontics and Pediatric Dentistry, College of Dentistry, University of São Paulo (USP).

Contact address: José Valladares Neto
Rua 132, 113, Quadra F-29, Setor Sul – Goiânia/GO — Brazil — CEP: 74.093-210
E-mail: jvalladares@uol.com.br

INTRODUCTION

The term short root anomaly (SRA),^{12,19} also known as root dwarfism,²⁷ was introduced and first described by Lind,¹⁹ in 1972, to categorize a rare developmental anomaly characterized by full root formation, but with genetically determined foreshortening. The affected root is smaller or presents the same size of the dental crown, has a tendency towards bilateral involvement and presents no other etiological factors.^{2,3,12}

Epidemiologically, the prevalence of SRA ranges from 0.6 to 2.4%,^{2,15} but may reach 10% among the Japanese.⁵ The incidence is higher in females with a ratio that ranges from 1:2.6 to 1:2.7.^{3,15} The most affected teeth are the maxillary central incisors and second premolars, while other teeth may also be affected.^{2,19} Some reports present extreme cases in which all teeth are affected, in which case it is described as generalized or multiple SRA.^{12,24,27} The condition may also be associated with systemic changes or syndromes³¹ and the absence of reports of SRA in primary dentition presupposes that it occurs exclusively in permanent dentition.³

The literature has given little attention to orthodontic movement of teeth with SRA, despite the high risk of root resorption.¹⁷ The fact that the number of cases reported is limited could be partially explained by lack of identification of this anomaly which is misdiagnosed as root resorption.¹⁰ For this reason, concerns about the diagnosis, etiology and orthodontic movement of teeth with SRA led to the objectives of this study.

MATERIAL AND METHODS

The present literature review was undertaken in the form of searches in PubMed, SciELO, LILACS, Scopus and Web of Science databases. Out of a total of 60 articles found, 35 were selected for this review, covering the topics described below.

Short roots: definition and differential diagnosis

Short roots have origin in both physiological and pathological circumstances. When the maxillary central incisors and first molars erupt in the oral cavity, half of the roots are formed while the other teeth erupt with about $\frac{3}{4}$. The canines are an exception, as they erupt with root almost complete. This transitional stage of root formation ends with the full development of the root when it reaches occlusal contact.¹³

Lind¹⁹ developed a radiographic method for measuring the relative length of the root, defined as the ratio between the length of the root and the length of the crown (R/C) (Fig 1). In a sample of 1,038 Swedish children, aged eleven or over, the normative value of R/C was 1.63 for males and 1.55 for females, without any statistical difference.¹⁵ The root is considered short when $R/C < 1.1:1$, in other words, when the root is of the same size or smaller than the crown.^{5,15}

There are several diagnostic possibilities for occlusal teeth with short roots. Several reasons explain the undertaking of a differential diagnosis for teeth with short roots, especially due to the frequency of publications reporting wrong diagnosis¹⁰ (Fig 2):

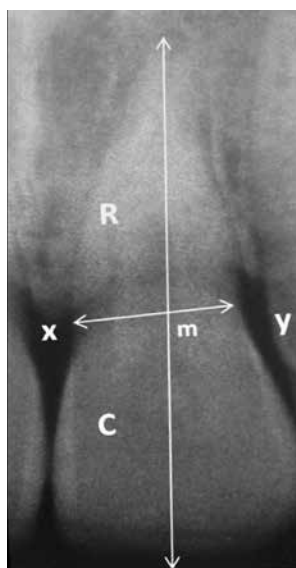


Figure 1 - Measurement of root/crown (R/C) ratio. Points of intersection between the root length, x and y are joined by a straight line. The length of the root (R) is measured by the midpoint below this line (m) at the apex, and the length of the crown (C) from m to the midpoint of the incisal edge (as suggested by Lind¹⁹, 1972).

- Incomplete root formation: a physiological condition, tooth erupting and incomplete apex.¹³
- SRA: congenitally short root, complete root formation, pointed or rounded apexes. Evident bilateral involvement found only in permanent dentition. It mainly affects the central incisors and second premolars, but it may also be generalized.^{2,3,12,19}
- External apical root resorption: decrease in apical root length after full root development. The apical format is typically rounded and irregular. It is triggered by various factors, including: orthodontic treatment, alveolodental trauma, periapical lesions, pericoronal follicle of teeth with deviant eruption, among others.¹⁰
- Dentin dysplasia type 1: short root due to atypical dentinogenesis. It is associated with pulp obliteration and root surrounded by bone radiolucence in cavity-free teeth. There is a possibility of loss and early exfoliation and the involvement of both deciduous and permanent dentitions.²⁸

- Post-trauma root hypoplasia in the deciduous predecessor: short root due to interruption of normal dentinogenesis as a result of alveolodental trauma. Generally unilateral involvement.³⁰

Thus, SRA differs from other conditions characterized by short roots. The diagnosis is randomly made through image, since the condition is asymptomatic. Clinical and radiographic findings are normal, except for shorter roots (Fig. 3). The low collagenolytic activity in periodontal tissues is different from cases of periodontal disease or active root resorption.⁴ In cases of severe root foreshortening, there may be an increase in tooth mobility, indicating loss of periodontal attachment and secondary occlusal trauma. Undoubtedly, the concomitant presence of SRA and apical dental resorption makes the diagnosis more complex.

ETIOLOGY OF SRA

The etiology of SRA has not been fully determined. Isolated cases of unknown origin have been reported, and have been categorized as idiopathic.¹¹

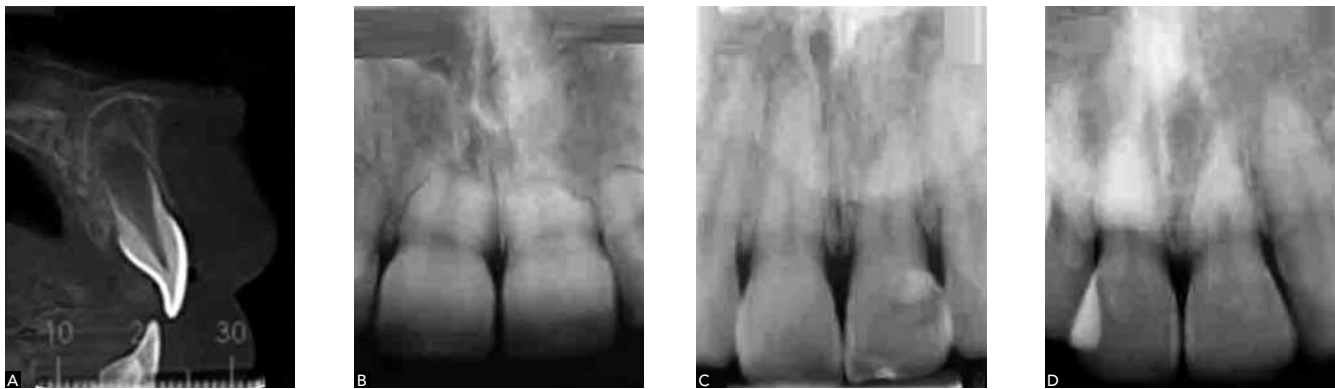

Figure 2 - Short roots due to: A) incomplete root formation, B) external apical root resorption, C) alveolodental trauma, and D) short root anomaly.

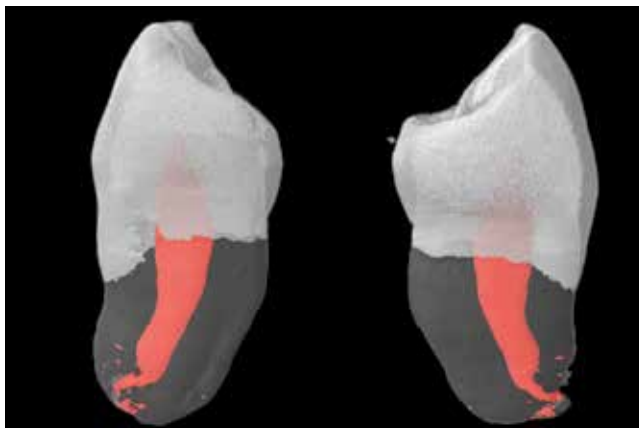


Figure 3 - Three-dimensional computed microtomography of proximal surfaces (distal and mesial) of lower premolar with short root anomaly. In red, the dental pulp, and in white, the enamel (microtomographic X-ray Sky Scan 1076, NRecon and CTan software).

Others have been described as having a congenital origin, compatible with the term anomaly, because the roots are short as a result of a disturbance during dental development.^{2,3,12,19}

In this context, environmental and genetic influences have been suggested. The influence of alveolo-dental trauma,³⁰ masticating stress⁵ and chemotherapy/radiotherapy²² have all been reported as inhibitors of root formation. However, evidence suggests that SRA has strong genetic origins, shown by striking family history.^{2,12,19} Nevertheless, because of the apparent heterogeneity of the lineage, no definitive conclusions regarding the type of inheritance could be reached, so nonsyndromic SRA could be included in the dominant and recessive autosomal models.^{2,12,19} In addition, the genetic theory is reinforced by the intense correlation of SRA with other tooth development anomalies, particularly hypodontia, microdontia (cone-shaped lateral incisor), *dens invaginatus*,

taurodontism, pulp obliteration, supernumerary teeth, root dilaceration and ectopic eruption.^{2,11,28,35} In spite of that, the occurrence of SRA was not higher in people with palate fissures, among whom there is a high prevalence of dental abnormalities.¹

A possible biological basis can be understood from the regulatory role of the *Nfic* gene.²⁴ Immunohistochemistry and *in situ* hybridization in rats has attributed the formation of short abnormal roots to the absence of the *Nfic* gene, responsible for the differentiation of odontoblasts.²⁴ Genetic sustainability is also enhanced by bilateral involvement in the same individual, with a possibility of generalized or multiple involvement.^{12,27} There have been reports associating SRA with systemic changes or syndromes, as in certain types of growth deficiency,^{26,35} scleroderma,¹⁴ hypoparathyroidism,¹⁶ tumoral calcinosis,⁸ congenital dyskeratosis³⁴ and in syndromes, such as Down,²⁵ Stevens-Johnson,³¹ Turner,²¹ Klinefelter,³³ and Laurence-Moon-Bardet-Biedl¹⁷ (Fig. 4).

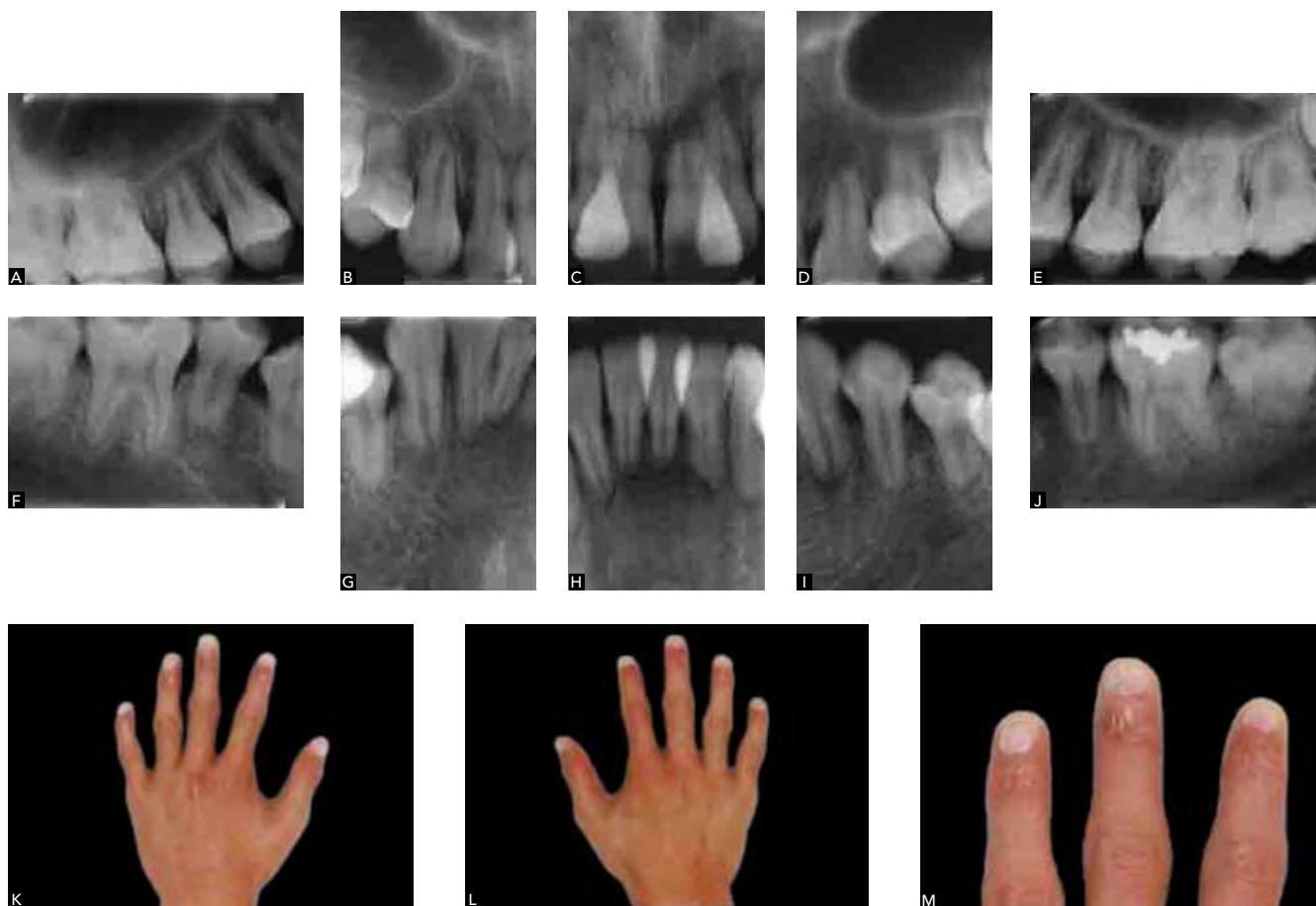


Figure 4 - Generalized short root anomaly in patient with congenital dyskeratosis syndrome (a predominantly recessive X-linked syndrome, characterized by the triad of skin hyperpigmentation, membrane leukoplakia and nail dystrophy). **A-J**) Periapical radiographs; **K-M**) Photographs of right and left hands showing nail involvement.

Implications of orthodontic movement in teeth with SRA

Orthodontic movement in teeth with short roots tends to generate a higher risk of root resorption, probably influenced by a lower R/C ratio.¹⁷ A test carried out with the finite element method showed that short roots concentrate greater mechanical stress in the middle of the root,²³ which would supposedly be harmful to the cementoblast layer because of extensive hyalinization coming from the periodontal ligament.¹⁰

At first, orthodontic movement is only contraindicated for teeth with SRA in extreme cases.¹² In most cases, clinical and radiographic monitoring can be used to control dental resorption.^{20,27,29} The procedure should initially start with a careful

clinical examination to assess the degree of tooth mobility, because if it is excessive, it will restrict the onset or continuity of orthodontic movement. Orthodontic treatment planning should allow an objective and coherent correction of the malocclusion.^{27,29} Light intermittent forces with longer intervals between activation are recommended for the control of dental resorption.¹⁸ Root resorption repair seems to depend on time, with longer intervals between activations producing more extensive repair.⁹ In addition, light forces generate an adequate momentum/force ratio (M/F) resulting from the cervical dislocation of the center of resistance. Periodic periapical radiographs should be taken to monitor orthodontic movement in teeth with critical root length (Figs 5 and 6).

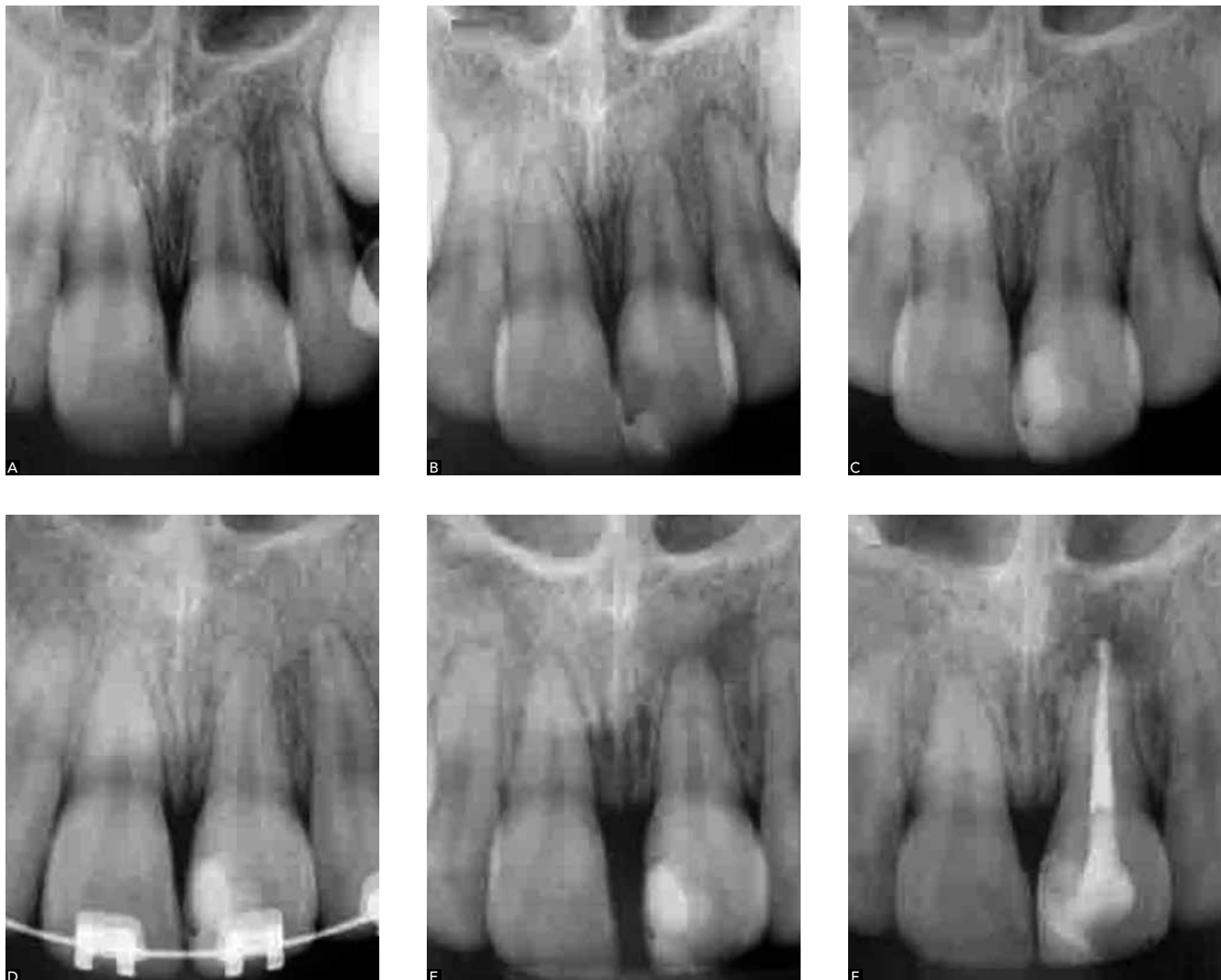


Figure 5 - Radiographic sequence of maxillary central incisors with short root anomaly (SRA). **A**) Mixed dentition indicating early stages of SRA; **B**) before, **C**) during and **D, E, F**) after orthodontic movement, showing relative control of external apical root resorption .

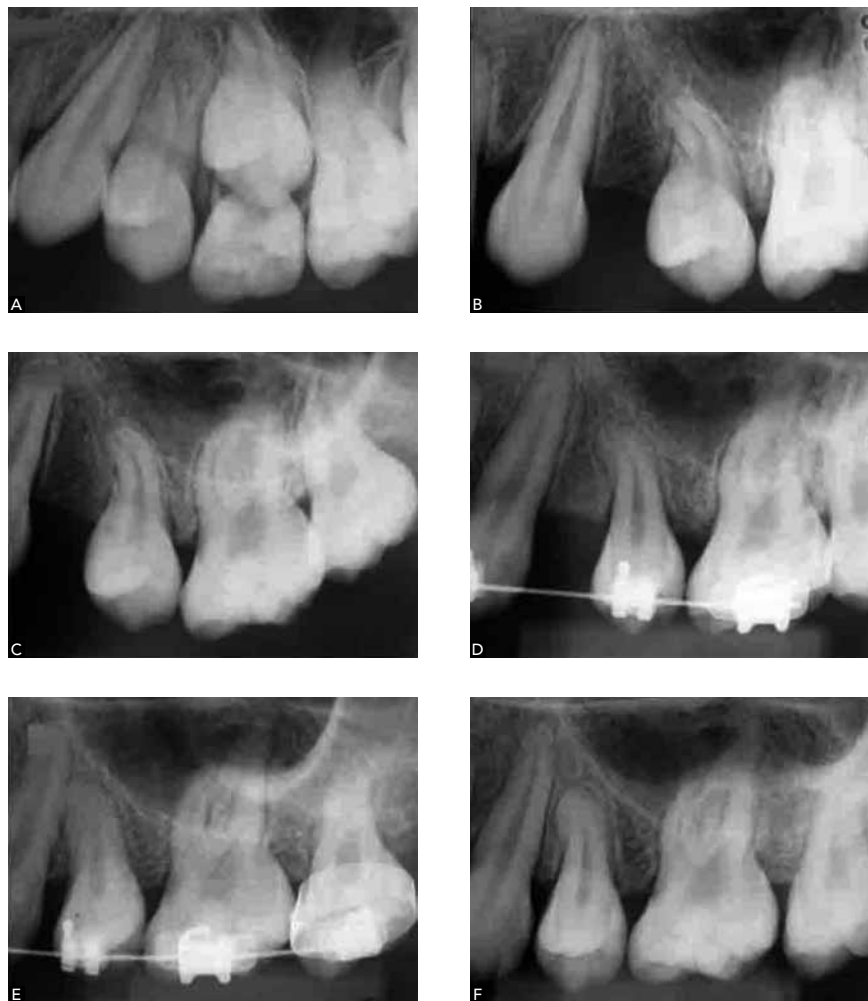


Figure 6 - Radiographic sequence of upper second premolars with short root anomaly (SRA). **A)** Mixed dentition indicating the early stages of SRA; **B)** before, **C)** during and **D,E,F)** after orthodontic movement, showing relative control of external apical root resorption.

Orthodontic movement of teeth with little insertion seems to be faster not because of more intense bone remodeling, but because of excessive inclination. Despite poor evidence, post-treatment relapse seems to be immediate. Case reports involving orthodontic movement in teeth with decreased insertion, as in cases of advanced periodontal disease⁶ or after an apicectomy,³² have recommended the use of a permanent fixed splint. The same procedure should be recommended in cases of movement in incisors with SRA, in order to contain excessive tooth mobility and ensure long-term stability.²⁰

CASE REPORT

A brown-skinned female, aged 12 years and 11 months, complaining about dental esthetics, sought the clinic of Orthodontics specialization course in the Foundation for Scientific and Technological De-

velopment in Dentistry, at the College of Dentistry, University of São Paulo (USP) requesting orthodontic evaluation. The patient and her parents were most concerned about the presence of infralabial inclined canines. The anamnesis showed good general health, no history of dental or facial trauma and no previous orthodontic treatment. At the time, family dental history was not an object of investigation.

The facial examination showed a brachyfacial pattern without any obvious skeletal asymmetry, convex facial profile, small nasal projection, and an acceptable nasolabial angle. The smile analysis showed adequate exposure of the upper incisors, taking her age into consideration, but indicated a slight dental midline deviation to the right and crowding of the upper canines in a marked infralabial inclined position of the right canine (#13) (Fig 7). The intraoral evaluation showed good dental health and healthy periodontal tissues.

As for the dental pattern, it presented Class I relationship of right molars. The dental examination presented left subdivision Class II (1/2) malocclusion. The upper right canine erupted in an infralabial inclined position, while the upper left canine was partially erupted due to space deficiency. Overjet and overbite were moderate and both the upper and lower dental midlines were deviated to the right side (Figs 8 and 9). In addition to these aspects, the upper arch was triangular-shaped due to the absence of canines in the dental arch. The shape of the lower jaw was adequate, but with a slight asymmetry in the position of canines and molars, probably attributed to their displacement as a result of the clinical absence of the right second lower premolar (#45). The second deciduous left lower molar (#75) was still in place (Fig. 10).

The cephalometric analysis showed a mild Class II skeletal pattern ($ANB = 4.5^\circ$), with the maxilla well positioned in relation to the cranial base ($SNA = 83^\circ$)

and slight retrusion of the mandible in relation to the cranial base ($SNB = 78.5^\circ$), with balanced facial growth ($SN-GoGn = 32^\circ$), slightly protruded and labially inclined upper incisors ($1-NA = 6.5$ mm and $1.NA = 25^\circ$) and obvious compensation of the lower incisors ($1-NB = 7.0$ mm and $1.NB = 33^\circ$). The examination of the extraoral radiographs confirmed the absence of significant skeletal asymmetry and the agenesis of the second lower left and right premolars (#35 and 45), as well as the lower right third molar (#48) (Fig 11). The examination of the periapical radiographs showed the presence of short root anomaly for the central incisors (#11, 21, 31 and 41) and upper premolars (#15, 14, 24 and 25), and apical root dilaceration for the upper right incisors (#12) (Fig 12).

Considering that the problem of crowded canines was one of the main reasons why the patient sought orthodontic treatment, straightening and leveling of teeth




Figure 7 - Initial extraoral photographs.

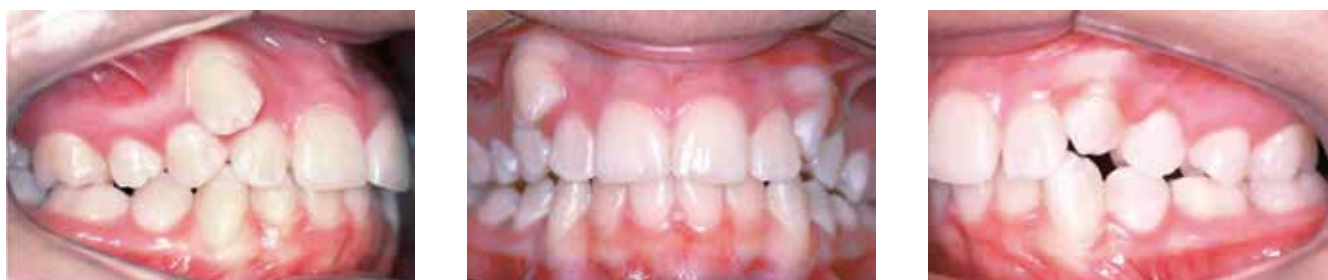

Figure 8 - Initial intraoral photographs.

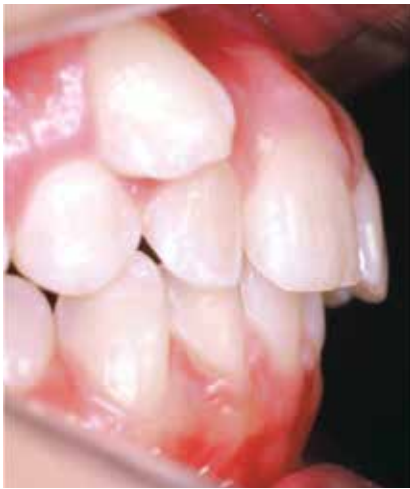

Figure 9 - Intraoral photograph of the infralabial inclination of the upper canine.

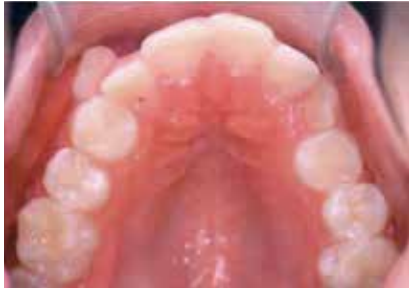

Figure 10 - Initial intraoral occlusal photographs.

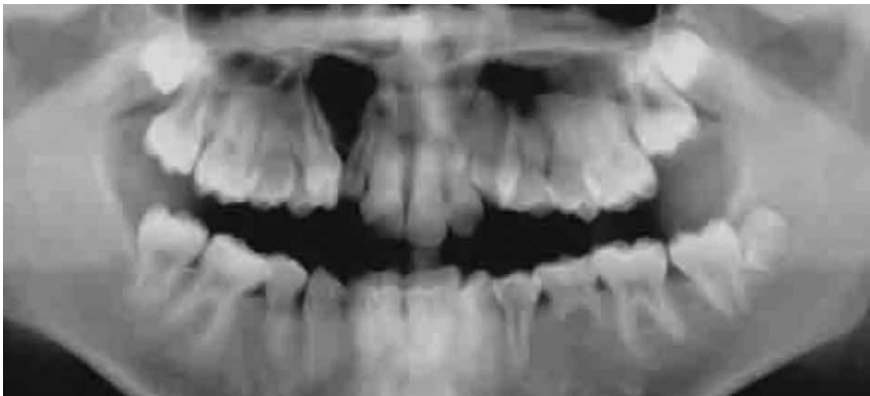
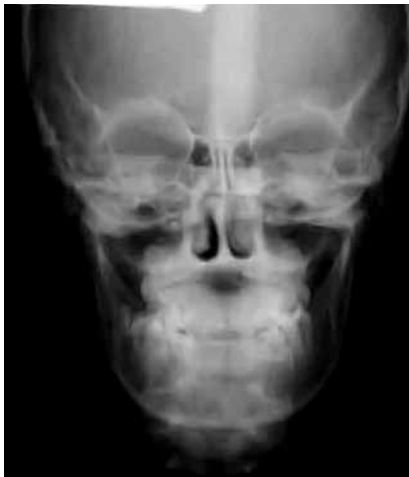
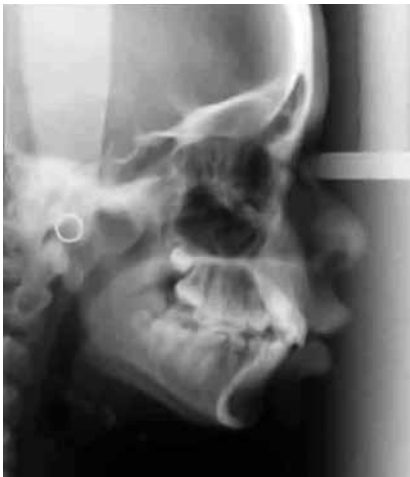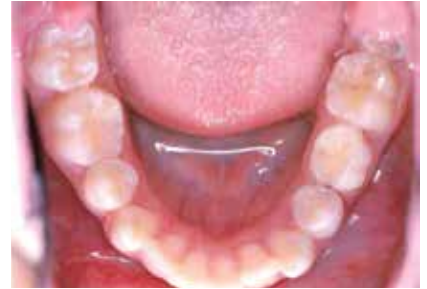Figure 11 - Initial radiographs.

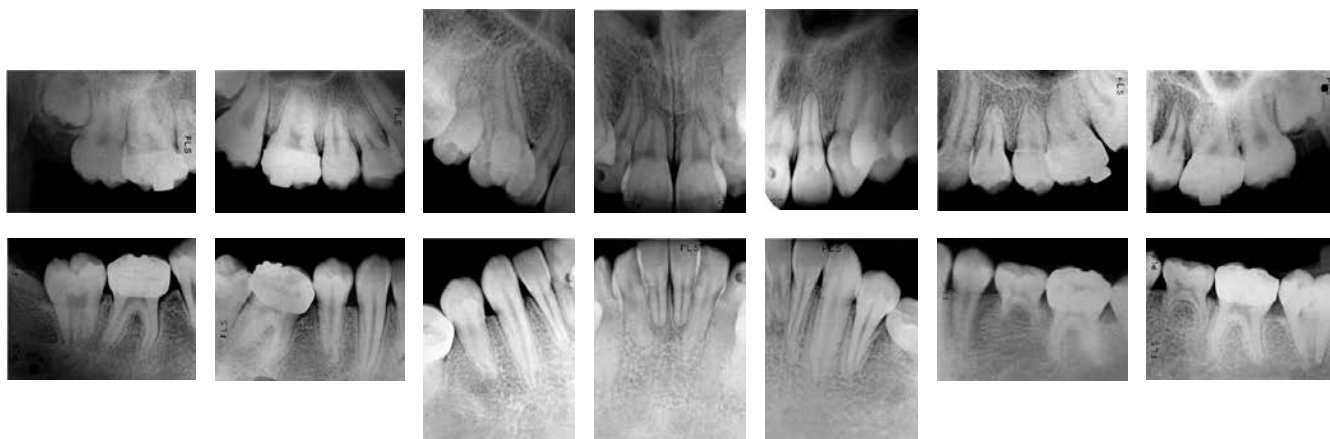


Figure 12 - Initial periapical radiographs.

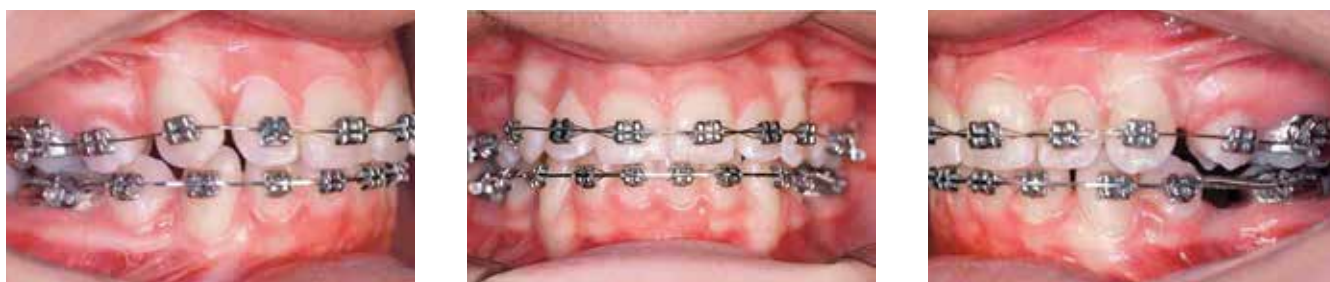

Figure 13 - Intermediate intraoral photographs.

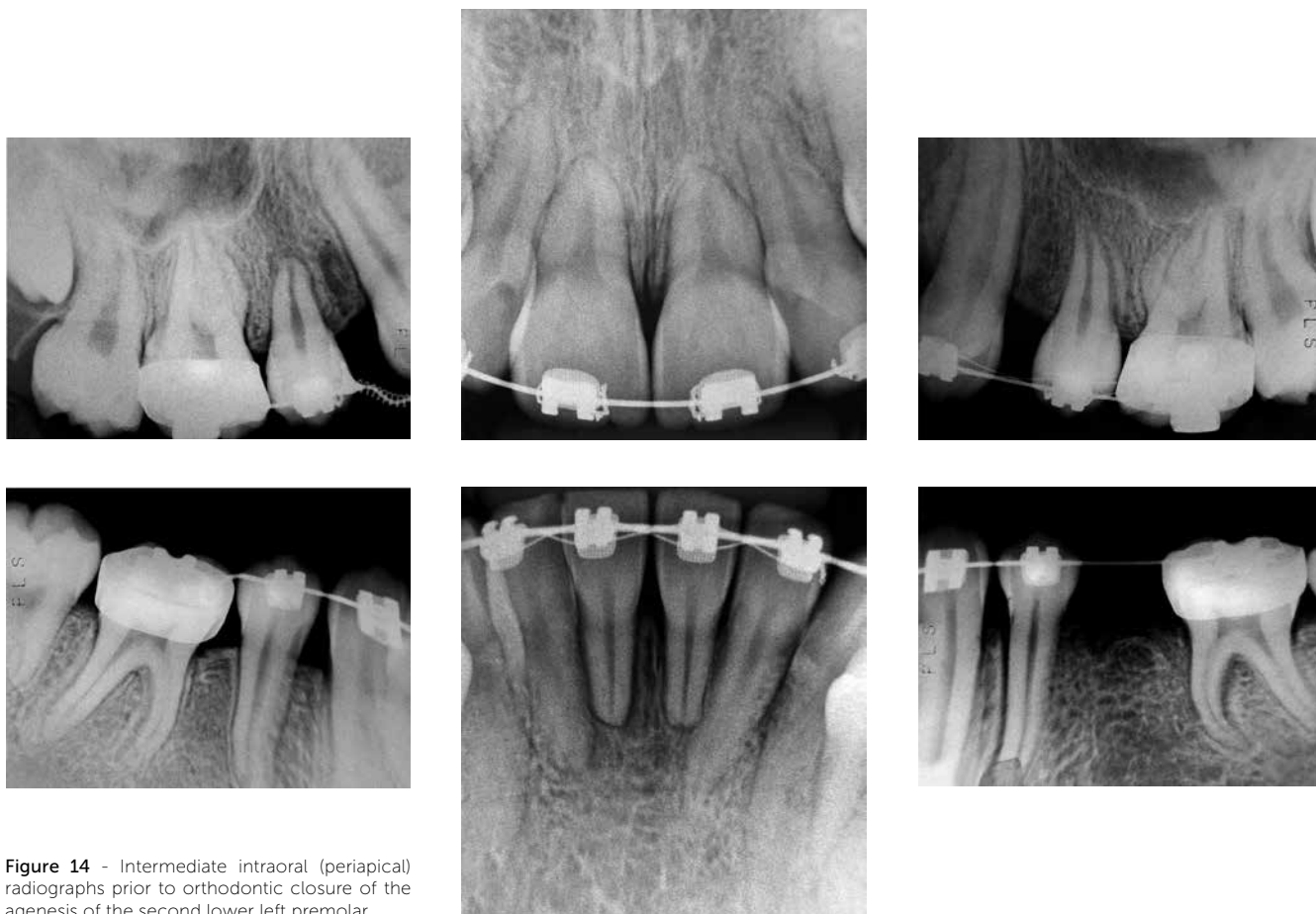


Figure 14 - Intermediate intraoral (periapical) radiographs prior to orthodontic closure of the agenesis of the second lower left premolar.

and correction of the dental midlines were the aims of the treatment. Molar and canine normal relation were achieved, and overbite and overjet were reduced. In addition, it was decided to close the space corresponding to the missing left lower premolar.

Treatment plan and progress were performed with fixed orthodontic appliances on the upper and lower arches, preceded by the extraction of the first upper premolars (#14 and 24), and the installation of Klöehn headgear (350 g/14 hours). Correction of midline deviations was aided by open coil springs, anterior retraction and inferior reciprocal mechanics to close the agenesis space of the left second lower premolar (#35) (Figs 13 and 14).

Extraction space was then closed and orthodontic detailing performed with the inclusion of second

molars and individual bends and torques in the 0.019 x 0.025-in stainless steel arch (Fig 15). Radiographic monitoring was carried out in resorption critical areas, especially after agenesis space closure (Figs 16 and 17). Retention was planned by means of a wraparound removable plate and a fixed intercanine bar with 0.028-in orthodontic wire for the lower teeth.

The esthetic and functional goals proposed at the onset of treatment were achieved, due to the meticulous use of orthodontic mechanics, radiographic monitoring at various stages of the treatment and longer intervals between clinical sessions. As final outcomes, good occlusal relationship between the arches, Class I relationship between molars and canines, and normal levels of overbite and overjet were achieved (Fig 18).

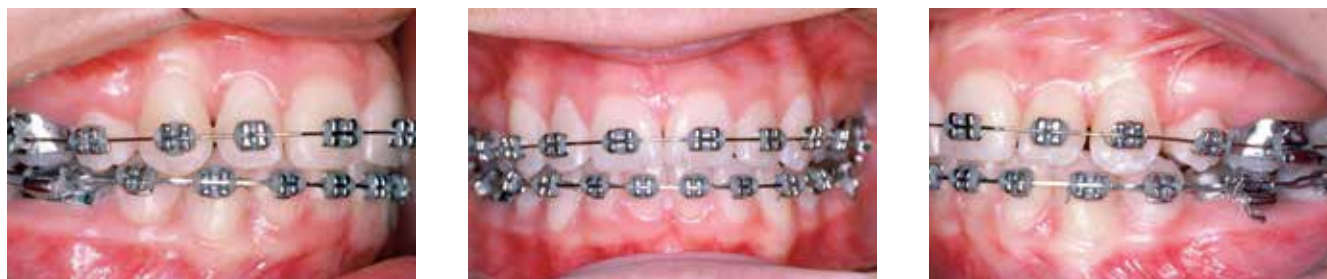

Figure 15 - Intermediate intraoral photographs of finishing phase.

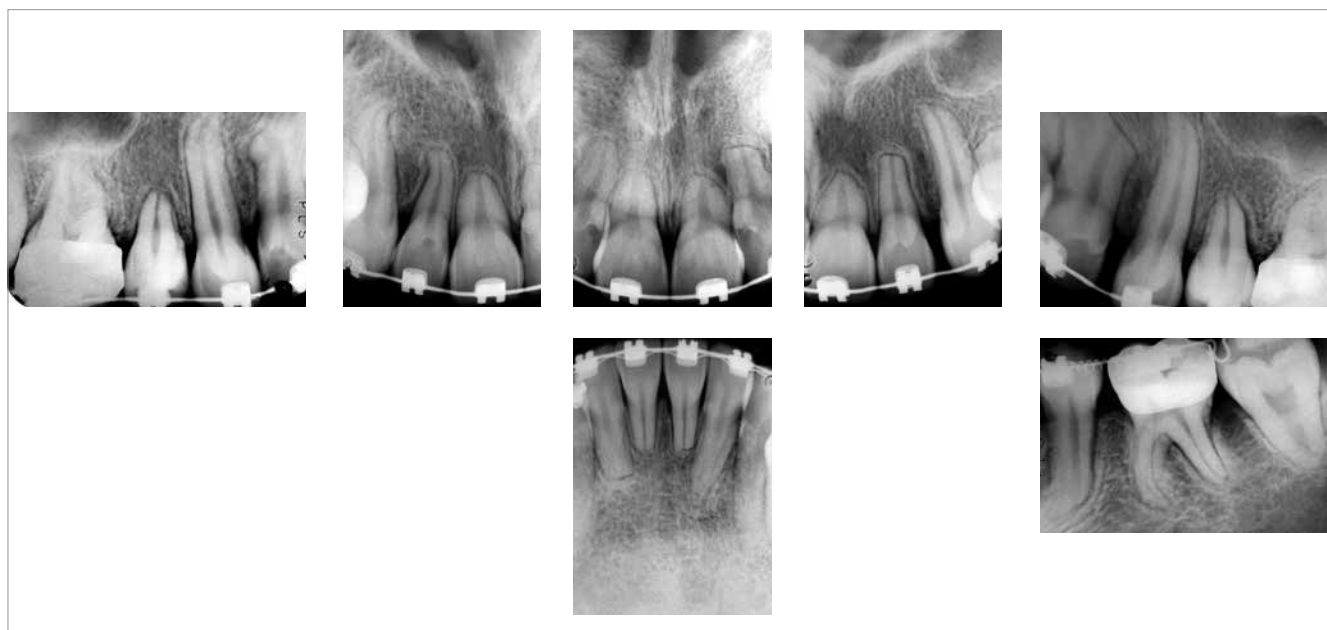


Figure 16 - Intermediate intraoral (periapical) radiographs after closure of agenesis of the left lower second premolar.

These results provided occlusal balance and excursive mandibular movements without interference, and periodontal tissues in good conditions. Dental arch morphology and facial balance were also considered satisfactory at the end of the treatment (Figs 19 and 20). The final extraoral radiographs and cephalometric superimposition are shown in Figures 21 and 22.

Despite the irreversible loss of root length, interruption of the forces that cause resorption tends to paralyze the resorption process and preserve dental insertion (Fig 23). Science has shown that conducting the case without the right care and without the necessary monitoring could culminate in more severe root resorption or even tooth loss.

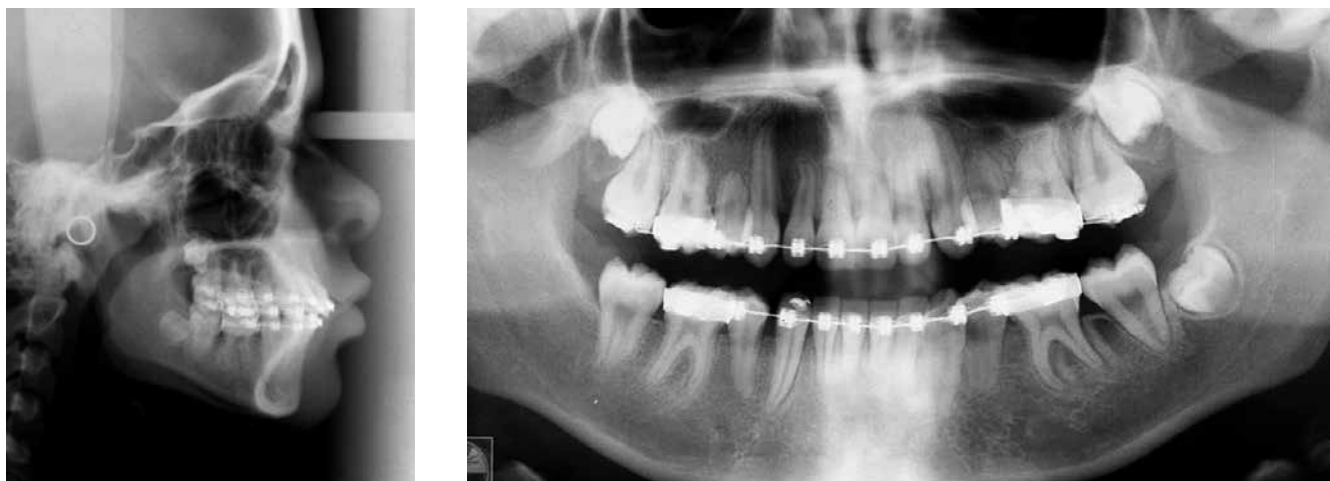

Figure 17 - Intermediate extraoral telerradiograph and panoramic radiographs.

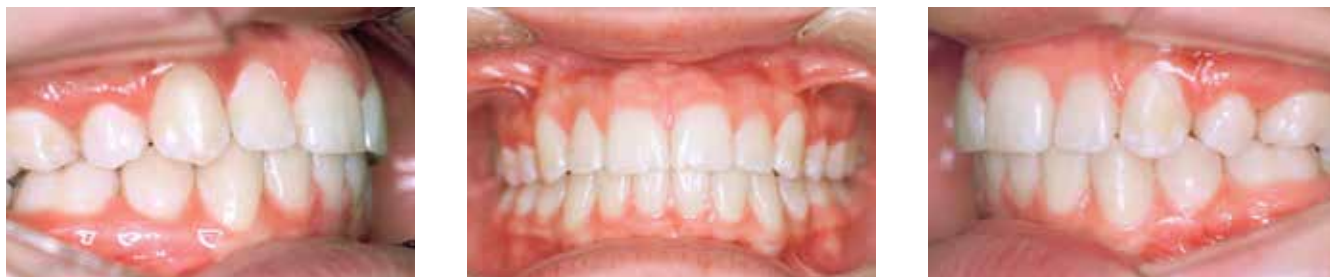

Figure 18 - Final intraoral photographs.

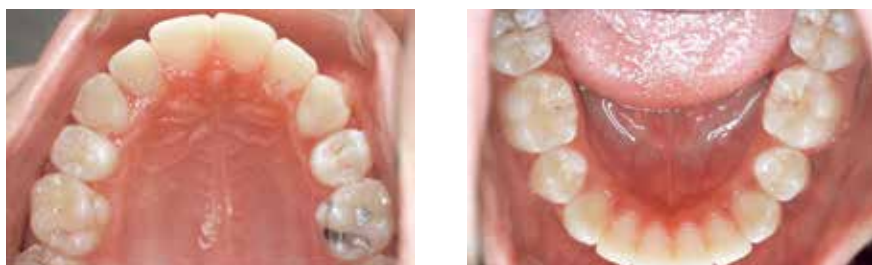

Figure 19 - Final intraoral (occlusal) photographs.

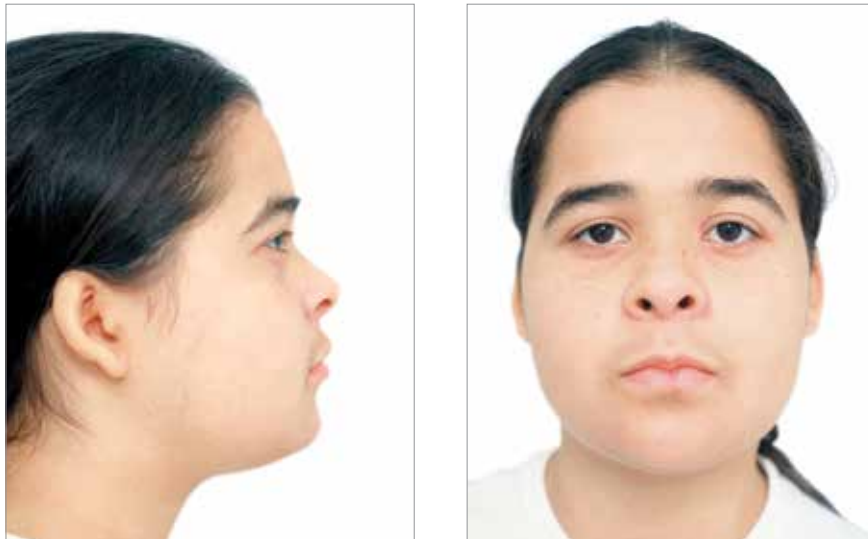

Figure 20 - Final extraoral photographs.

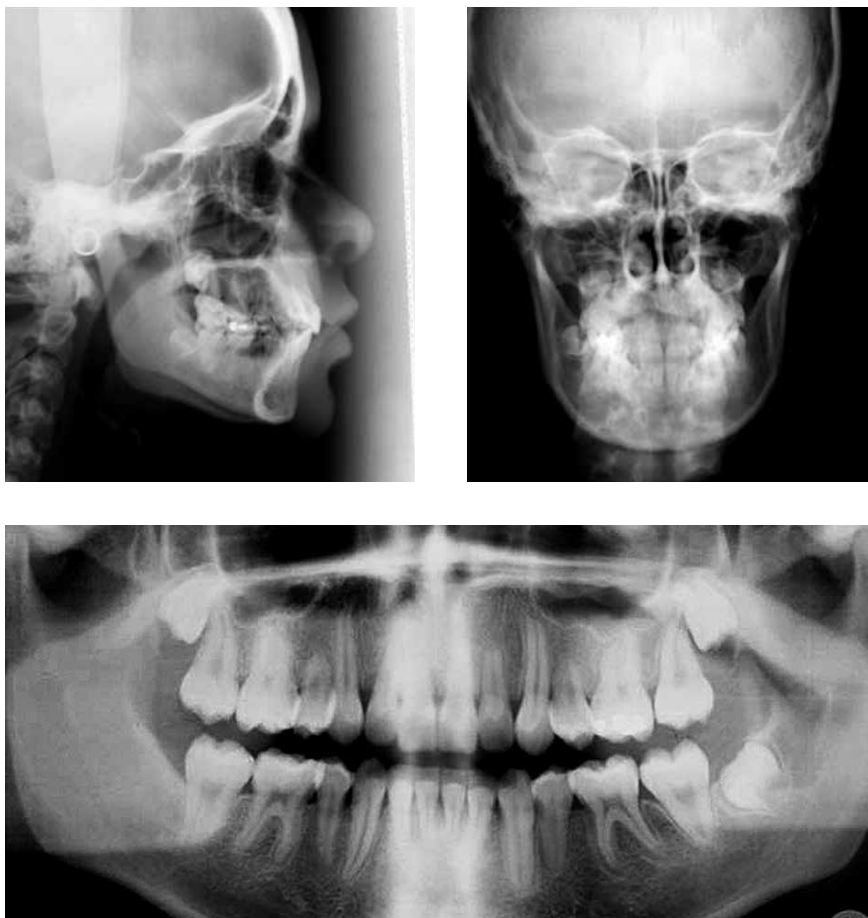


Figure 21 - Final radiographs: lateral teleroadiograph, frontal teleroadiograph and panoramic radiograph.

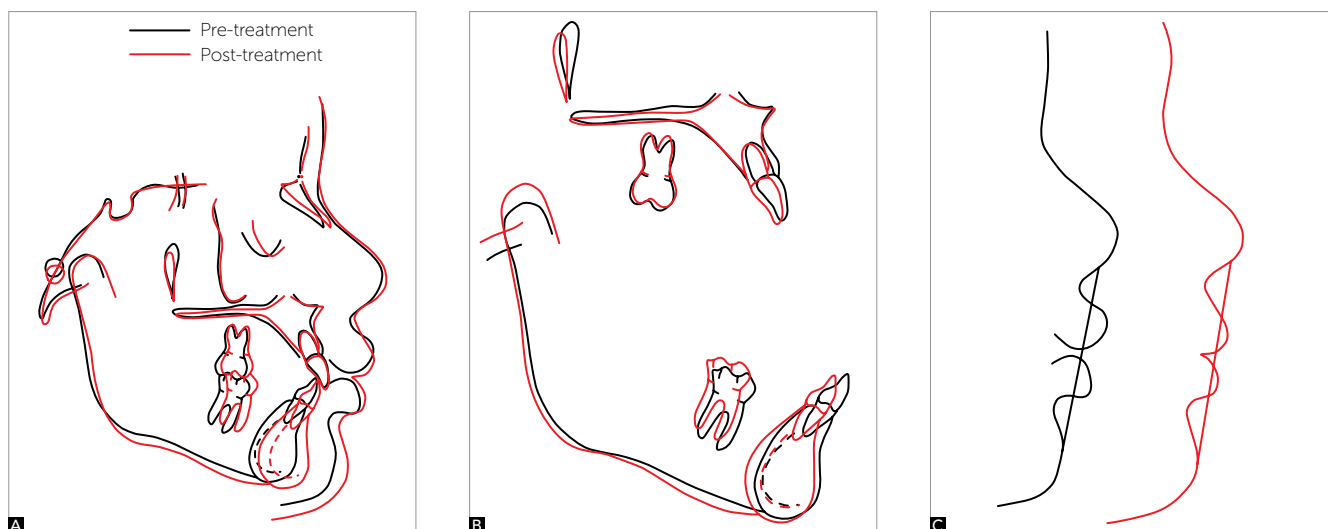


Figure 22 - Cephalometric superimposition before (black) and after (red) orthodontic treatment. A) total; B) partial; C) facial profile and line S.

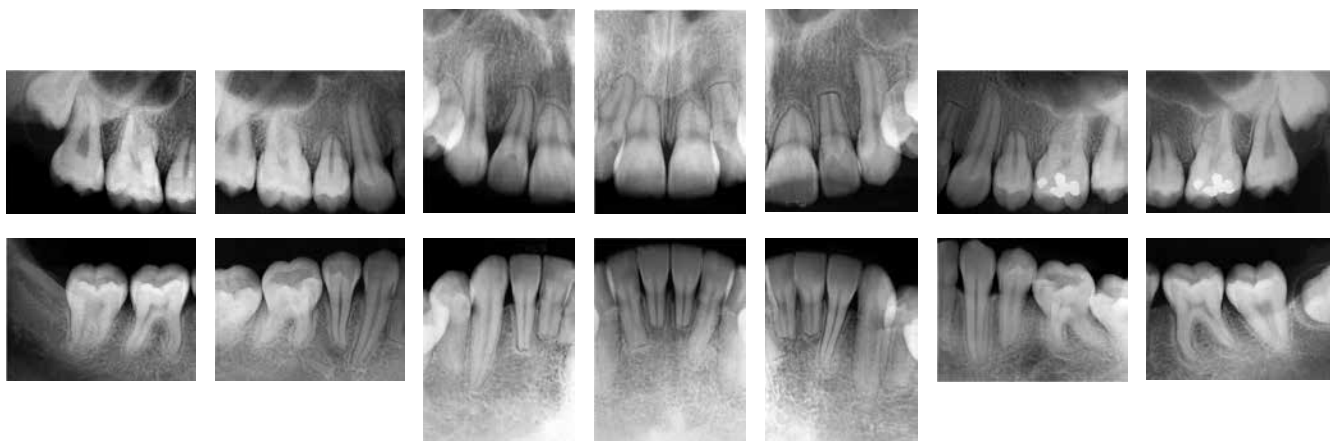


Figure 23 - Final intraoral (periapical) radiographs.

CONCLUSION

Orthodontic movement of teeth with SRA tends to increase the risk of root resorption, however, treatment is contraindicated in extreme cases, only. Differential diagnosis and an understanding of the etiological reasons for teeth with short roots enable orthodontic movement which requires biomechanical adaptations, periodic radiographic monitoring, clinical monitoring of tooth mobility and permanent retention, especially for the incisors.

Acknowledgements

The authors thank the Laboratory of Nanobiotechnology/UnB for making the microtomography device available with which Figure 3 was obtained.

REFERENCES

- Akcem MO, Evirgen S, Uslu O, Memikoglu UT. Dental anomalies in individuals with cleft lip and/or palate. *Eur J Orthod.* 2010;32(2):207-10.
- Apajalahti S, Arte S, Pirinen S. Short root anomaly in families and its association with other dental anomalies. *Eur J Oral Sci.* 1999;107(2):97-101.
- Apajalahti S, Holttä P, Turtola L, Pirinen S. Prevalence of short root anomaly in healthy young adults. *Acta Odontol Scand.* 2002;60(1):56-9.
- Apajalahti S, Sorsa T, Ingman T. Matrix metalloproteinase -2, -8, -9, and -13 in gingival crevicular fluid of short root anomaly patients. *Eur J Orthod.* 2003;25(4):365-9.
- Ando S, Kiyokawa K, Nakashima T, Shinbo K, Sanka Y, Oshima S, et al. Studies on the consecutive surgery of succedaneous and permanent dentition in the Japanese children. 4. Behavior of short-rooted teeth in the upper bilateral central incisors. *J Nihon Univ Sch Dent.* 1967;9(2):67-82.
- Arun T, Sayinsu K, Nalbantgil D. Orthodontic approach for patients with severe periodontal disease. *World J Orthod.* 2005;6(3):275-80.
- Borgström MK, Riise R, Törnqvist K, Granath L. Anomalies in the permanent dentition and other findings in 29 individuals with Laurence-Moon-Bardet-Biedl syndrome. *J Oral Pathol Med.* 1996;25(2):86-9.
- Burkes Jr EJ, Lyles KW, Dolan EA, Giammara B, Hanker J. Dental lesions in tumoral calcinosis. *J Oral Pathol Med.* 1991;20(5):222-7.
- Cheng LL, Türk T, Elekdağ-Türk S, Jones AS, Yu Y, Darendeliler MA. Repair of root resorption 4 and 8 weeks after application of continuous light and heavy forces on premolars for 4 weeks: a histology study. *Am J Orthod Dentofacial Orthop.* 2010;138(6):727-34.
- Consolaro A, Martins-Ortiz MF, Consolaro RB. O primeiro estudo sobre hereditariedade relacionada com as reabsorções dentárias em Ortodontia: uma análise crítica do trabalho de Newman. *Rev Dental Press Ortod Ortop Facial.* 2004;9(2):110-22.
- Desai RS, Vanaki SS, Puranik RS, Rashmi GS, Nidawani P. An unusual combination of idiopathic generalized short-root anomaly associated with microdontia, taurodontia, multiple dens invaginatus, obliterated pulp chambers and infected cyst: a case report. *J Oral Pathol Med.* 2006;35(7):407-9.
- Edwards DM, Roberts GJ. Short root anomaly. *Br Dent J.* 1990;169(9):292-3.
- Estrela C, Valladares-Neto J, Bueno MR, Guedes AO, Porto OCL, Pécora JD. Medidas lineares dos estágios de desenvolvimento da dentição permanente humana usando Tomografia Computadorizada de Feixe Côncavo: um estudo preliminar. *Dental Press J Orthod.* 2010;15(5):44-78.
- Foster TD, Fairburn EA. Dental involvement in scleroderma. *Br Dent J.* 1968;124(8):353-6.
- Jakobsson R, Lind V. Variation in root length of the permanent maxillary central incisor. *Scand J Dent Res.* 1973;81(4):335-8.
- Jensen SB, Illum F, Dupont E. Nature and frequency of dental changes in idiopathic hypoparathyroidism and pseudohypoparathyroidism. *Scand J Dent Res.* 1981;89(1):26-37.
- Kjaer I. Morphological characteristics of dentitions developing excessive root resorption during orthodontic treatment. *Eur J Orthod.* 1995;17(1):25-34.
- Levander E, Malmgren O, Eliasson S. Evaluation of root resorption in relation to two orthodontic treatment regimes. A clinical experimental study. *Eur J Orthod.* 1994;16(3):223-8.
- Lind V. Short root anomaly. *Scand J Dent Res.* 1972;80(2):85-93.
- Marques LS, Generoso R, Armond MC, Pazzini CA. Short-root anomaly in an orthodontic patient. *Am J Orthod Dentofacial Orthop.* 2010;138(3):346-8.
- Midtbo M, Halse A. Root length, crown height, and root morphology in Turner syndrome. *Acta Odontol Scand.* 1994;52(5):303-14.
- Nasman M, Björk O, Söderhäll S, Ringden O, Dahlöf G. Disturbances in the oral cavity in pediatric long-term survivors after different forms of antineoplastic therapy. *Pediatr Dent.* 1994;16(3):217-23.
- Oyama K, Motoyoshi M, Hirabayashi M, Hosoi K, Shimizu N. Effects of root morphology on stress distribution at the root apex. *Eur J Orthod.* 2007;29(2):113-7.
- Park J-C, Herr Y, Kim H-J, Gronostajski RM, Cho M-I. Nfic gene disruption inhibits differentiation of odontoblasts responsible for root formation and result in formation of short and abnormal roots in mice. *J Periodontol.* 2007;78(9):1795-802.
- Prahl-Andersen B, Oerlemans J. Characteristics of permanent teeth in persons with trisomy G. *J Dent Res.* 1976;55(4):633-8.
- Shaw L. Short root anomaly in a patient with severe short-limbed dwarfism. *Int J Paediatr Dent.* 1995;5(4):249-52.
- Silva Filho OG, Mateus SRM, Silva VB, Oliveira GAG. Nanismo radicular. *Ortodontia* 2007;40(4):305-11.
- Steidler NE, Radden BG, Reade PC. Dentina dysplasia: a clinicopathological study of eight cases and review of the literature. *Br J Oral Maxillofac Surg.* 1994;22(4):274-86.
- Tanaka OM, Knop LH, Shintcovsk RL, Hirata TM. Treatment of a patient with severely shortened maxillary central incisor roots. *J Clin Orthod.* 2008;42(12):729-31.
- Tewari N, Pandey RK. Root hypoplasia: an unusual sequel to primary tooth trauma. *Dent Traumatol.* 2010;26(1):115-7.
- Thornton JB, Worley SL. Short root anomaly in a patient with a history of Stevens-Johnson syndrome: report of case. *ASDC J Dent Child.* 1991;58(3):256-9.
- Valladares Neto J, Costa SP, Estrela C. Orthodontic-surgical-endodontic management of unerupted maxillary central incisor with distoangular root dilaceration. *J Endod.* 2010;36(4):755-9.
- Varrela J, Alvesalo L. Taurodontism in 47 XXY males: an effect of the extra X chromosome on root development. *J Dent Res.* 1988;67(2):501-2.
- Yavuzylmaz E, Yamalik N, Yetgin S, Kansu O. Oral-dental findings in dyskeratosis congenital. *J Oral Pathol Med.* 1992;21(6):280-4.
- Witkop Jr CJ, Jaspers MT. Teeth with short, thin, dilacerated roots in patients with short stature: a dominantly inherited trait. *Oral Surg Oral Med Oral Pathol.* 1982;52(5):553-9.