

An interview with

Leopoldino Capellozza Filho

- Dentistry Graduate, Bauru School of Dentistry, São Paulo University (1972).
- M.Sc. in Orthodontics, Bauru School of Dentistry, São Paulo University (1976).
- Ph.D. in Oral Rehabilitation, Area of Periodontics, Bauru School of Dentistry, São Paulo University (1979).
- Began his professional career as founder and head of the Orthodontics Department, aka “Centrinho” (Rehabilitation Hospital of Craniofacial Anomalies, São Paulo University (HRAC-USP).
- Faculty member of the postgraduate department, (HRAC-USP).
- In the early 80’s, started his private orthodontic practice gaining extensive experience in the orthodontic treatment of children and adults with dental and/or skeletal deformities, and dental follow-up.
- Former Assistant Professor and Ph.D., São Paulo University; Professor, Postgraduate (Masters) Program in Orofacial Clefts (HRAC-USP); Visiting Professor, Julio de Mesquita Filho São Paulo State University, Orthodontist, HRAC-USP, Advisor to the Foundation for Research Support, São Paulo. With many publications in national and international journals, and significant participation in orthodontic conferences, currently coordinates the Specialization Program in Orthodontics (Profis) encompassing the Specialization and Masters Programs in Orthodontics, Sacred Heart University (USC), and collaborates with several graduate courses in orthodontics.



I was invited to introduce Prof. Leopoldino Capellozza Filho’s interview under a rather unfortunate circumstance. One of his greatest friends and scientific partners, Prof. Omar Gabriel da Silva Filho, was supposed to do so, but soon after receiving his questions, a health problem no longer allowed him to undertake this task. But with the grace of God he will soon resume his work and enjoy this historic participation.

As regards our illustrious respondent of this issue’s interview, I am sure that many of his friends (and they are many) - had they been invited in my stead - would inevitably feel burdened by the responsibility of introducing “Dr. Dino,” as he is fondly nicknamed. And they would all ask if such introduction was indeed necessary.

It is estimated that over 3,000 copies of his book have been sold, including a best-seller published by Dental Press. Furthermore, this indefatigable master is poised to launch a new book with further innovations, focusing on his concept of an individualized orthodontics, which is at once realistic and minimalist, and according to which—were I to paraphrase him—“minimum can mean maximum.”

Early in my training I was privileged to have Prof. Capellozza as one of my key mentors in Orthodontics. So I feel I am in a position to attest to the character, personal and scientific honesty, and common sense of this undisputed master. I had the chance to learn and awaken to a more open-minded orthodontic approach given his vast experience and his scientific criteria. He spearheaded this approach, based on patients’ morphology, and it has long been his unique diagnostic and treatment method.

During the years I spent in residency at the Department of Orthodontics of “Centrinho” (HRAC-USP, Bauru), I was also able to keep track of his influential and clear minded performance in his daily struggle to enhance the outcomes of cleft patient treatment with the support of the entire Centrinho team.

Countless lines would be needed to describe the impact of his views on the current behavior of Brazilian orthodontists, built over 30 years of orthodontic practice. Starting with his former students, like myself, who today closes ranks on the educational “front” and continues to convey my concepts in the training of new professionals, right down to the new orthodontists, who may have the golden opportunity to start a career very soon. Dino has benefited us all.

Those who know him well also know that a lot more could be said of this ingenious friend.

In this interview one can grasp a bit of Prof. Leopoldino Capellozza Filho’s lucid reasoning as he walks the reader through his treatment of cleft patients and his orthodontic practice, affording insights into compensatory treatment in all three planes (vertical, anteroposterior and transverse). Interviewers included the following distinguished colleagues: Dr. Omar Gabriel da Silva Filho, Prof. Terumi Okada, Prof. Laurindo Furquim, Prof. Suzana Rizzato and Prof. Dione Vale.

Readers can expect to be enthralled by this fertile and unmissable chat with Dino as if they were talking personally with this unique icon of the orthodontic world.

Good reading!
Adilson Luiz Ramos

Upon graduating from FOB-USP (Bauru School of Dentistry), you were invited to work at “Centrinho” (Rehabilitation Hospital of Craniofacial Anomalies, HRAC-USP), Bauru, São Paulo State, Brazil. As the first orthodontist to take part in their multidisciplinary team, you undertook the difficult task of giving back “smile and life” to the complex cases that confronted you there. What were the main challenges you faced in implementing your treatment philosophy? Tell us about your experience there. How worthwhile was it? Terumi Okada

In life, a good start can make a difference. As a student, I was asked to join the team of professionals of what was then known as “Centrinho” (Little Center) at the Bauru School of Dentistry. The invitation came from Professor José Alberto de Souza Freitas (Dr. Gastão), who would, from that moment on, be my mentor in academic life and an example in my private life. This informal invitation would determine to a great extent the sort of professional I would eventually become. For starters, I got used to hard work for it was sweetened by the gratitude I discerned in the eyes of my patients, their mothers and fathers. No doubt I was burdened with tremendous responsibilities. Too big, in fact, for such a young fellow, but impossible to turn down, in view of the expectations, trust and support provided by Dr. Gastão. I started working at Centrinho in early 1973 doing general practice and in August of that year I began to prepare to become their very first orthodontist. I started the postgraduate course in orthodontics, the first class of Bauru School of Dentistry, coordinated by Prof. Décio Rodrigues Martins, another very important person in my orthodontic life. He showed me the way, the importance of basic knowledge, of reading and understanding scientific articles and keeping records of my professional practice. He awakened in us (Jurandir Barbosa, Luis Garcia and Wanderlei Amorin) students of the first class, a huge affection for this specialty.

As I gained a practical knowledge of bands, brackets and Typodont archwires and started planning with cephalometric diagnosis the first cases of our postgraduate course, the difficulties began to pop up at Centrinho. Patients who needed orthodontic treatment were accumulating, and all were complex cases. The presence of clefts of various types created different diseases with skeletal involvement. They had very different ages, from the very young to mature adults. The orthodontics that I was learning reflected the period and was limited to corrective treatment of young patients. The literature was overall scarce, inaccessible and time consuming, and did not provide anything consistent about the treatment of cleft patients. Removable appliances, poor results... Very discouraging! Since I had no idea how to proceed I decided to just let time go by... But who could control Dr. Gastão’s eagerness?

I had to put my shoulder to the wheel. When things get tough, there is no point in brooding over difficulties. You’ve got to find solutions. In the literature, Dr. Pruzansky²⁶ at least said what should not be done: using orthopedic appliances pre-and post surgery, which he condemned at the time based primarily on common sense. Time and scientific research have confirmed such devices are of little value. There were also the articles by Dr. Haas ‘teaching’ us how to perform rapid maxillary expansion. At the FOB Department of Orthodontics I learned to fabricate good bands and to produce tooth movement using leveling loops. All in all, it was still not enough because the concepts of normality defined and assessed by cephalometry and by Angle’s molar key to occlusion did not apply, so we were unable to define therapeutic goals for patients at Centrinho.

It took courage. Is this the right word? I don’t know. What I do know is that at that time I began to schedule patients who were admitted to the Hospital to have the orthodontic appliance set up. We were in the 70s, the era of bands, stainless steel wires with leveling and alignment loops, when a whole lot of time was spent in the procedures. I then started to do to them something similar to

what we did in patients without clefts, and that was setting up the orthodontic appliance. This contact, no longer with models and radiographs, but with patients and parents, made the difference. The confidence with which these people, often of humble origin, entrusted themselves to an institution that was intent on treating them, hoping to recover their "smile and life," left an indelible mark in me. Emotion and willingness. Driven by necessity, I found the courage to do things for the first time. Some had already been described, others not. We are talking

about absolutely individualized diagnosis. Seeing the patient's needs and defining what was needed to address them, whether or not it broke the rules of orthodontics. It was based on morphology, especially of the occlusion, since there were major limitations when dealing with the face. That is when I began to develop the new concept that I currently adopt for diagnosis.⁴

We began to finish treatments with satisfactory results, which greatly surprised people who worked in the area (Fig 1). But this was only the beginning,

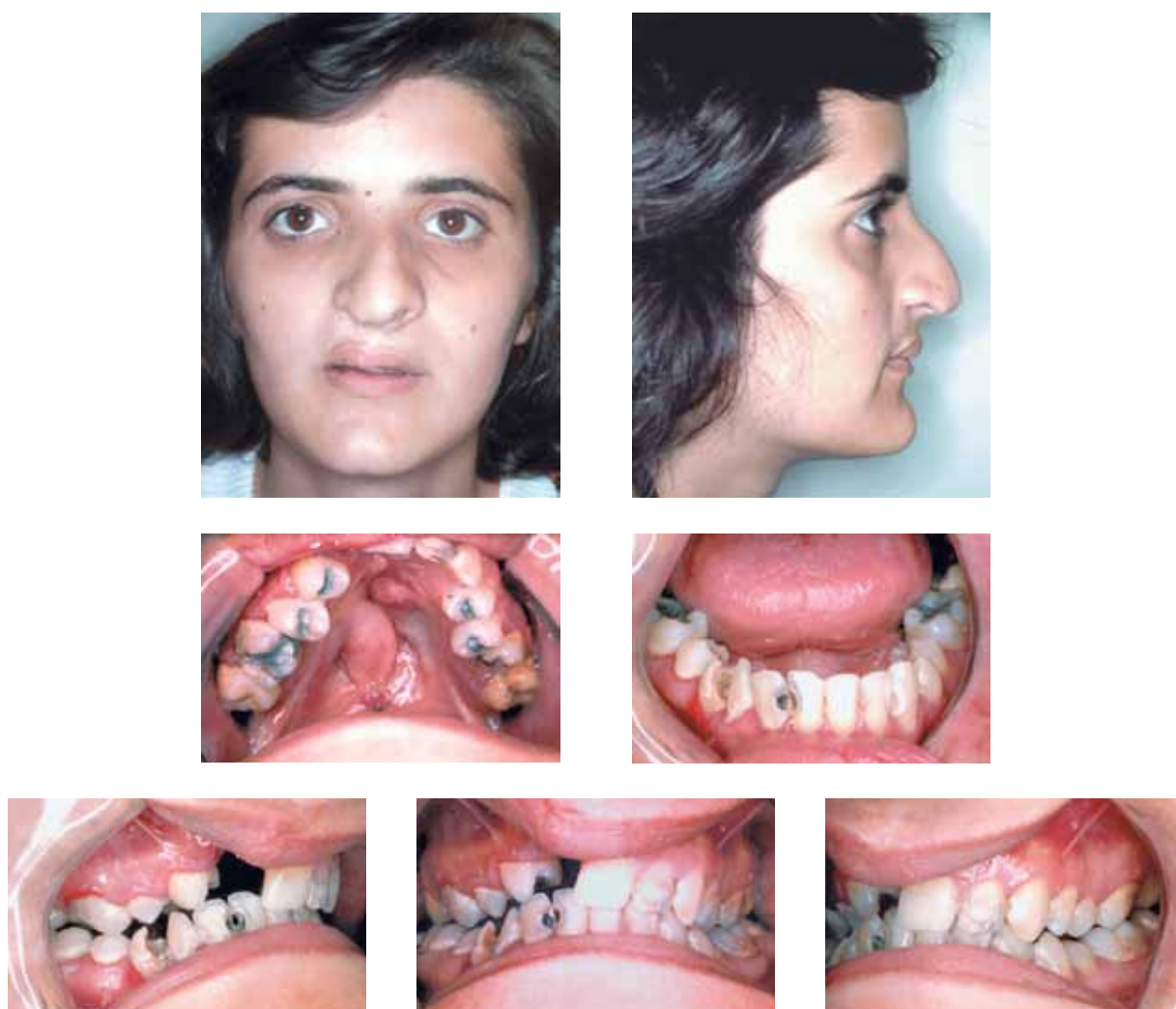

FIGURE 1A - Young patient, 17 years and 3 months of age with unilateral cleft lip and palate operated on as a child, showing scars marking the lip and nasal deformity, but Pattern I face. Class II relationship on the right and Class I on the left side, with right posterior crossbite and retruded anterior teeth. Complicated occlusion due to missing teeth, poor hygiene and remaining teeth in bad condition. This picture clearly reflects the usual conditions faced by these patients at that time (1978).

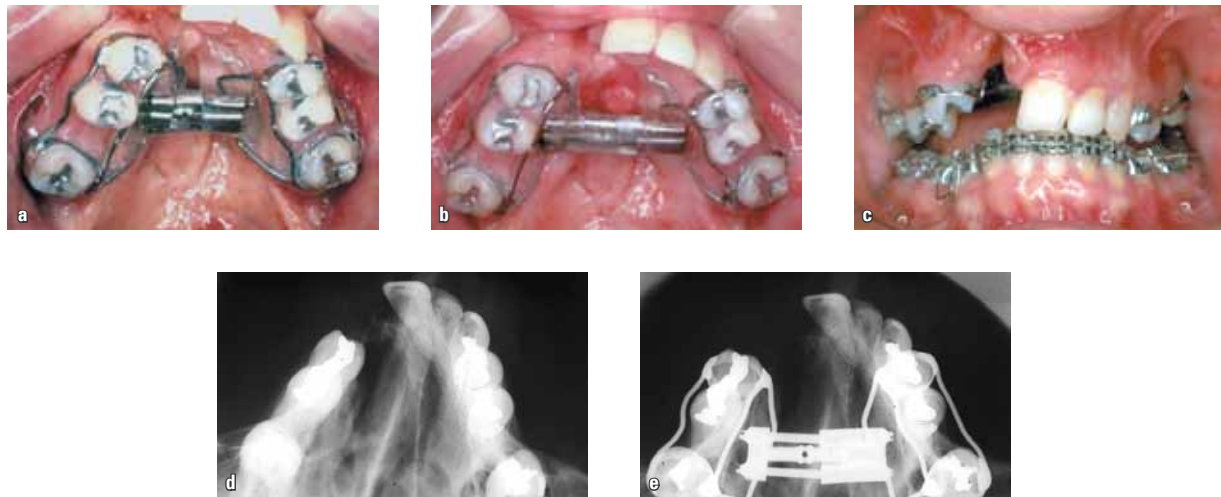


FIGURE 1B - Upper arch with expander in place, before activation (a), after activation (b), frontal occlusion (c), occlusal radiograph of maxilla before (d), and after expansion (e).

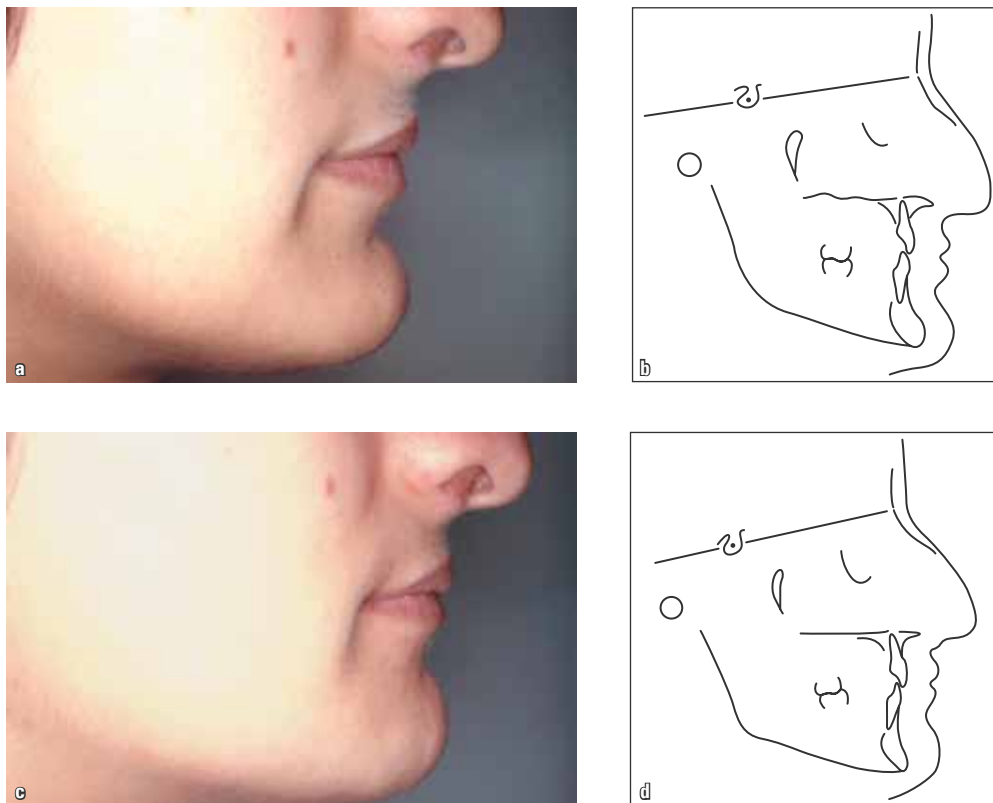


FIGURE 1C - Profile close-up and cephalometric tracings before (a, b) and after (c, d) chin reduction surgery performed by Dr. Reinaldo Mazzottini (Centrinho), with very positive impact on facial profile.

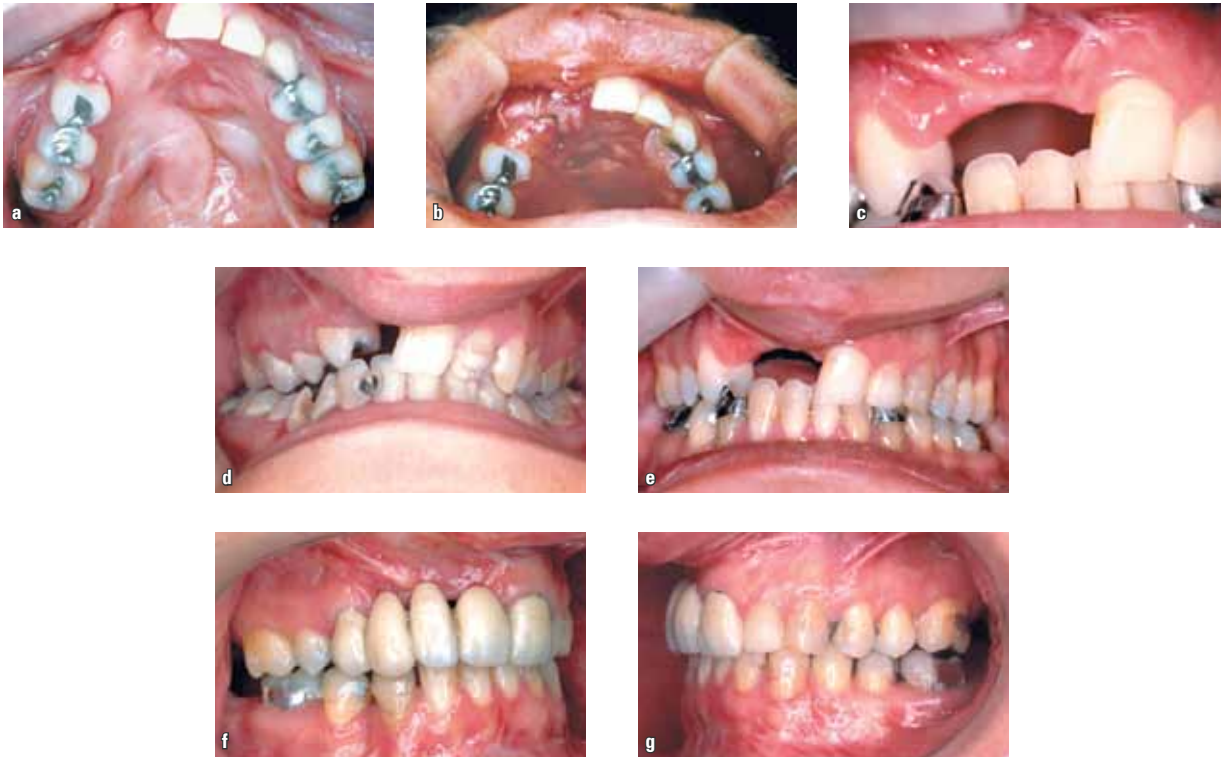

FIGURE 1D - Upper dental arch, before (a), immediately after placement of late bone graft (b), and alveolar area repaired (no cleft) after healing (c). Occlusal correction was complete and missing teeth replaced prosthetically. When critically analyzing these results, consider that they were obtained 30 years ago.

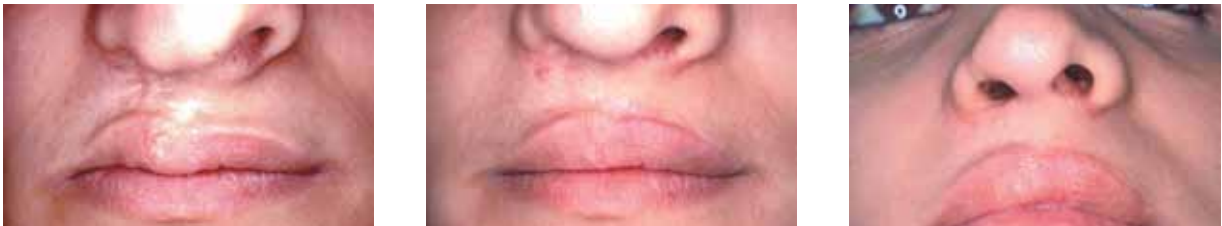

FIGURE 1E - Cosmetic surgeries were performed by Dr. Diogenes Laércio Rocha (Centrinho) to improve the contour of the upper lip and nose shape.

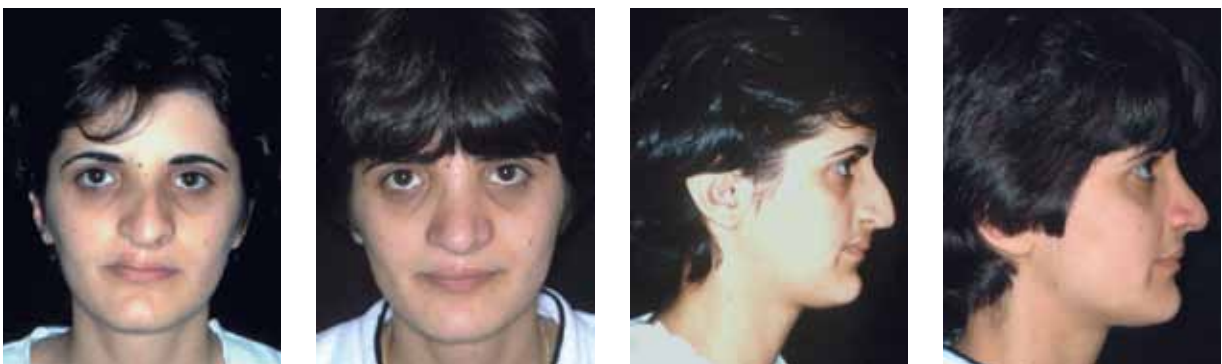

FIGURE 1F - Comparison between initial and final images (frontal and profile) demonstrates very significant aesthetic recovery, considering the complete cleft lip and palate. These results were influenced by an adequate facial growth pattern displayed by the patient. Speech rehabilitation complemented rehabilitation as a whole, attesting to the pioneering efforts of Centrinho in the treatment of cleft patients.

and far from over. Occlusion correction was effective but we still had to grapple with many patients' faces. Although we acknowledged how effective our approach had proven, we were confined to certain dentoalveolar limits.

Patients with deformities and unsightly faces required correction. The quest for surgical resources for these patients was in its infancy. It was the dawn of the history of orthognathic surgery in Brazil. This story is told in the introduction to my interview with Dr. Reinaldo Mazzottini, on the 30th anniversary of this event.⁶ We learned a lot from this experience, starting with facial analysis, the basis for diagnosis in contemporary orthodontics, which I learned from Dr. Larry Wolford. It was 1978 and the first patients were operated on in an unforgettable week for all those who had the privilege to experience yet one more step Centrinho was taking to attain its goal. The "smile and life" were returned to those who were most unlikely to regain them.

Those early days were the happiest. Perhaps because we were young, because everything was still waiting to be accomplished and, of course, because we were naive. We were a fledgling team, but a team nonetheless, sharing ideas in a brotherly atmosphere. Residency in orthodontics was now available. Teaching and research were growing. We investigated the influence of surgical procedures on the correction of cleft lip and palate, as the primary etiological agent in the sequelae of the face. We had to operate seldom, well and in a timely manner. We began to see relapse and instability in patients we had treated. All these aspects were investigated and led to publications. They served as a basis for further actions. I became coordinator of the Hospital's therapy management area, which established conduct protocols for the rehabilitation process, because this function is supposed to be performed by an orthodontist.

More and more orthodontists joined us. Special people the likes of Dr. Reinaldo Mazzottini, Dr. Arlette Cavassan, Dr. Silvia Graziadei, Dr. Omar Gabriel da Silva Filho and Dr. Terumi Okada Ozawa. This was the core of professionals that

surrounded me at a time of intense clinical practice. I learned to respect differences, to admire competence, to be part of a team, to always regard the patient as our primary target.

I think that answers your question. We humans are a result of genetics and whatever experience life allows us. Centrinho meant an opportunity for teamwork in dealing with complex patients, challenges and conditions to face them, early recognition of the limitations of orthodontics, dedication to clinical practice and study. All these were relentless requisites to develop a critical spirit and the confidence to ignore dogmas and shift paradigms. Was it worth it? Each and every day!... Mainly because all those actions took place in an environment of respect for the human being, which pervaded the entire Centrinho team, inspired by Dr. Gastão.

Although your orthodontic practice can sometimes be bold and challenging, it is always based on morphological, scientific and clinical concepts. Do you think this is partly due to your experience in treating those complex and borderline cleft lip and palate patients?

Terumi Okada

I agree that that was the main influence. For one thing, diagnosis is failure-prone if conducted using cephalometry in patients with skeletal deformities, and therefore not applicable to most patients with complete clefts. In these cases, prognosis can prove difficult if made with conventional tools since it is determined by factors beyond genetic inheritance, such as the cleft condition and the treatment it requires, as well as by the functional disorders it causes. This complexity you referred to limited therapy goals and required enough understanding not to transgress those limitations and risk instability. Individualizing and compensating were the keywords in those days. Those were times of dogmas, rigid targets, based on numerical data which I believe nowadays only orthodox orthodontists still pretend to abide by. Shifting those paradigms was quite a challenge, especially for the young man I was at the time.

But the commitment to patients in need of orthodontic treatment as part of an interdisciplinary approach began to dictate the procedures that I would begin to use and gradually organize and protocol.⁴

I believe you will get a clearer picture if I tell you how my first rapid maxillary expansion came about. I learned how to expand the maxilla using a W-shaped archwire. It was a limited resource if your purpose was to expand the basal bone. Rapid maxillary expansion was not routine yet and I had not learned how to perform it, but the potential results were exciting. Haas's articles were clear so I summoned enough courage to perform the first expansion, following his instructions. I told him when we brought him to Bauru in 2001 to teach a course and receive our respects that everyone here had been his students and I, the first and most grateful. It involved the use of elastic separators, banding, impression taking, making a model with the bands in place, and then going to a lab where it was also the technician's first experience fabricating an expander. Fabricating, cementing and activating.

The thrill of seeing the cleft segments moving away and the crossbite being corrected! Excitement and satisfaction. We began to make lots of expansions. In contrast to the prevalent concept at the time, we expanded the maxilla of children in early mixed dentition, youths and adults. This experience was enriched by each and every one of our professionals, who changed the expander design using rectangular wires instead of a buccal bar,¹⁰ used different anchorage teeth depending on patient age,⁹ and allowed continued expansion by replacing the screw^{7,8} (Fig 2C), besides devising specific expansion protocols for different ages.^{5,7,8,13}

That's what those magical days of discovery were always like. Different needs justifying different methods. We used brackets with reversed angulation on central incisors and canines and superangulation on canines near the cleft to respect bone limits. We would level the dental arches in segments and only then expand and perform a complete leveling⁸ (Fig 2B). Cases were finished with class II relations for canines and/or molars,

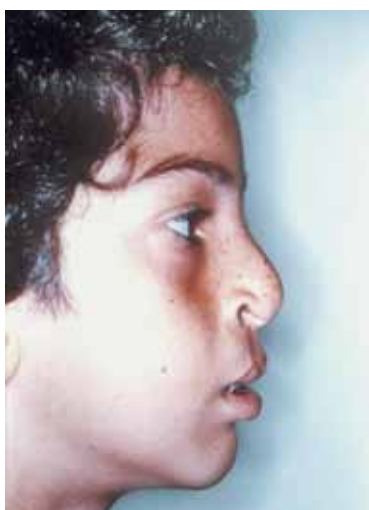
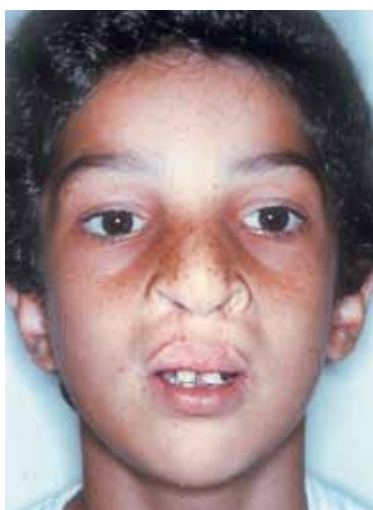
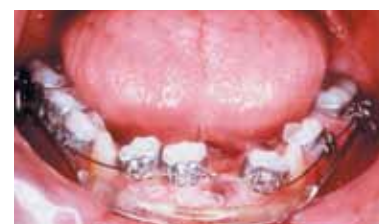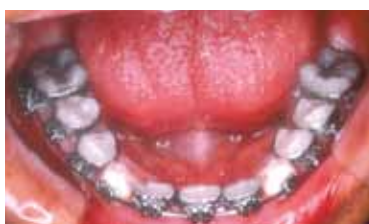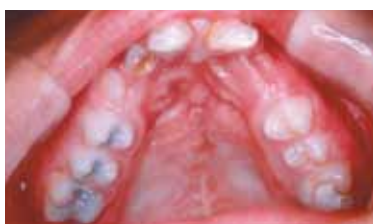FIGURE 2A - As the incisors show a reduction in size in routine bilateral cleft lip and palate, one option to set the perimeters of the anterior upper and lower dental arches was to extract one lower central incisor.



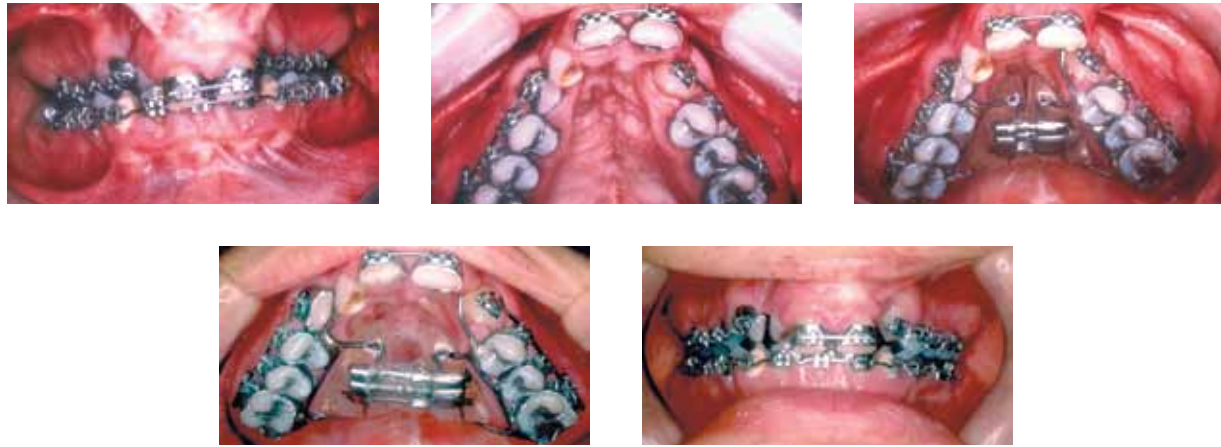


FIGURE 2B - Leveled and aligned dental arches, with the upper arch in segments, which was routine prior to expansion. Expansion was not enough to correct the crossbite, requiring a new appointment with patient for further expansion. This was a problem involving operating times and additional costs.

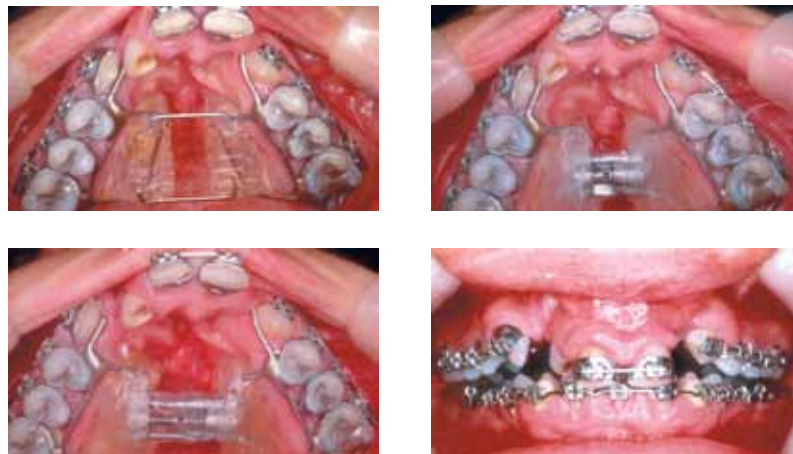

FIGURE 2C - When the expander was exhausted and occlusion not yet corrected, instead of fabricating a new appliance, acting on Prof. Dr. Reinaldo Mazzottini suggestion we would lock the acrylic base of the expansion appliance, remove the screw, close it and once again attach it to the base. The locks were removed and expansion continued. Then the crossbite was finally corrected.

not necessarily symmetrically. We would extract a mandibular incisor of patients with bilateral cleft lip and palate to compensate for the smaller size of maxillary central incisors (Fig 2A). We would compensate by tipping incisors in the opposite direction of the skeletal discrepancy, usually a Pattern III, but preferred to concentrate on compensating the lower arch.

This approach obviously reached beyond the care of cleft patients, and affected my entire universe of orthodontic clinical practice and teaching.

Competent and special individuals, who believed in me—like Dr. João Cardoso Neto, private practice partner for 31 years—allowed the exhaustive application of these concepts. I believe at this point you may have an insight into the root of the concepts that enabled me to develop a diagnosis based on facial growth patterns,⁴ the need to accept the limitations of orthodontic intervention, as a rule curtailed by dentoalveolar limits, and my individualized

brackets.¹² Nothing is by chance. Individualization and compensation are still keywords in my orthodontic philosophy and reflect the influence of having experienced complex and borderline orthodontic patients with cleft lip and palate.

The care of patients with cleft lip and palate is now almost 100% provided by public medical services (SUS), and they thought at first to concentrate it at the Centrinho, in Bauru. However, the current trend is the creation of several mini health centers scattered across different regions of Brazil, coordinated by different professionals with varying protocols. How do you view this policy of decentralization? Terumi Okada

I do not know if the centralization that occurred in the early days had been planned ahead. I rather think it was a consequence of the quality of the interdisciplinary treatment offered at Centrinho, which created opportunities and facilities that patients and their parents could not find elsewhere. As a result, many training centers in the medical field and some other areas now play a very minor role in terms of number of patients. Either that or they discontinued care delivery altogether. At this point, concentrating care delivery at Bauru's Centrinho became almost the only option. Though such centralization may be frowned upon from the perspective of staff training—which is necessary and has been accomplished by HRCA—it was not ideal for the provision of services. I think that decentralization is the best system, and it seems quite feasible with the service virtually supported by public health agencies (SUS). Centers located in strategic areas within our continental country do offer advantages, but provided that one single consistent protocol be applied.²⁹ This protocol, which tends in general to be universal must focus on cost-effectiveness analysis, with results commensurate with all sorts of investments made by the key stakeholders (professionals, patients and health agency). It is not reasonable to assume, however, that after all the experience that

has been documented and is available now, in the 21st century, the protocol—which though not a guarantee of fantastic results, does spare the patient long-term treatments—is deprecated on account of outdated, obsolete preferences or techniques touted with a new name. This is a risk that must be accepted and requires vigilance to avoid.

Based on your experience how do you envisage the rehabilitation of cleft lip and palate patients? Terumi Okada

In order to be achieved, excellence in the rehabilitation of cleft lip and palate patients requires many components. The first such component is an interdisciplinary team where each professional possesses in-depth knowledge of the resources available in their area for diagnosis, prognosis and treatment of these patients. Furthermore, each one should clearly recognize the relevance of their participation in the process while conforming to the hierarchy of established procedures. This should be determined in a protocol which, besides defining conducts, also sets the times at which they will be adopted, determining treatment strategies. The compliance of patients and their guardians seems to play a fundamental part here, and seems to be dependent on their socioeconomic and cultural level. Financial status is obviously required for all this to work satisfactorily, which may be a problem for a system totally dependent on the state.

From a technical standpoint, I think we can afford professional training, and the protocol²⁹ adopted by the HRAC is good. From the standpoint of treatment delivery, it is essential to comply with the strategies, especially regarding the age for adoption of the procedures. The patient's behavior—from simple actions such as performing preventive methods for dental caries to a dedication to the procedures recommended by therapists—also contributes to the quality of the rehabilitation process.

In private practice, where the constraints that influence the context for excellence are more easily controlled very interesting results can be obtained for facial growth and development of dental arches,

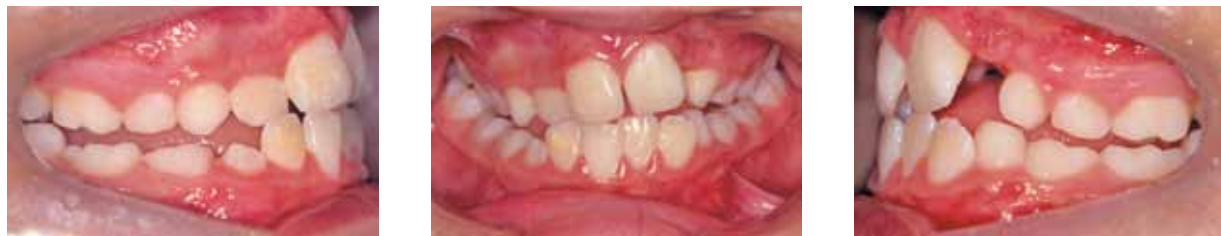
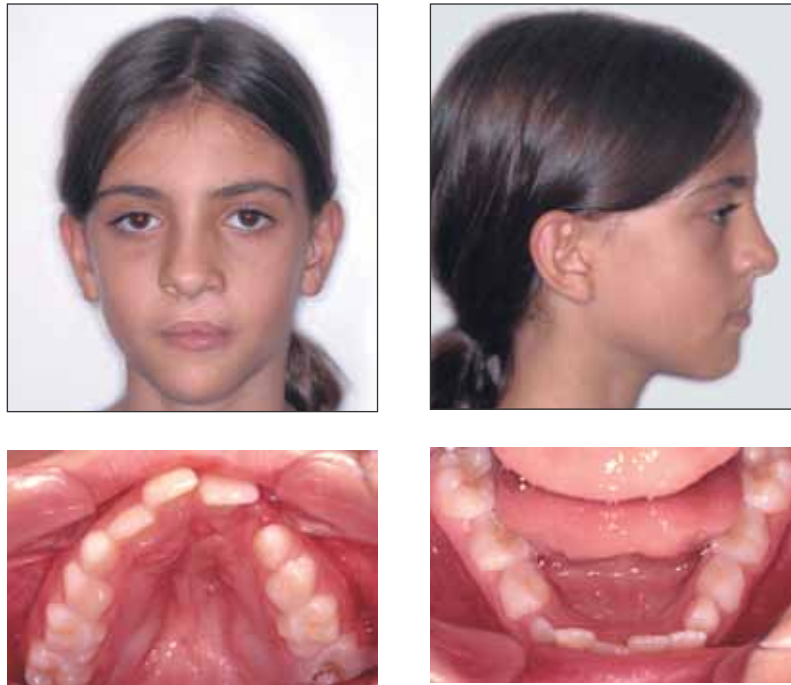
FIGURE 3A - Patient aged 10, presenting with right unilateral cleft lip and palate, had undergone lip and soft palate surgery (when 3 months old), hard palate, nasal septum and alveolar ridge surgery (at 5 years and 10 months), and alveolar bone grafting 6 months earlier (at age 9 years 6 months). This is a Pattern III face with moderate maxillary retrusion, whose etiology seems to have been determined by the cleft. Typical occlusal relationships, with canines and anterior teeth in Class III, bilateral posterior crossbite and anterior end-on bite.

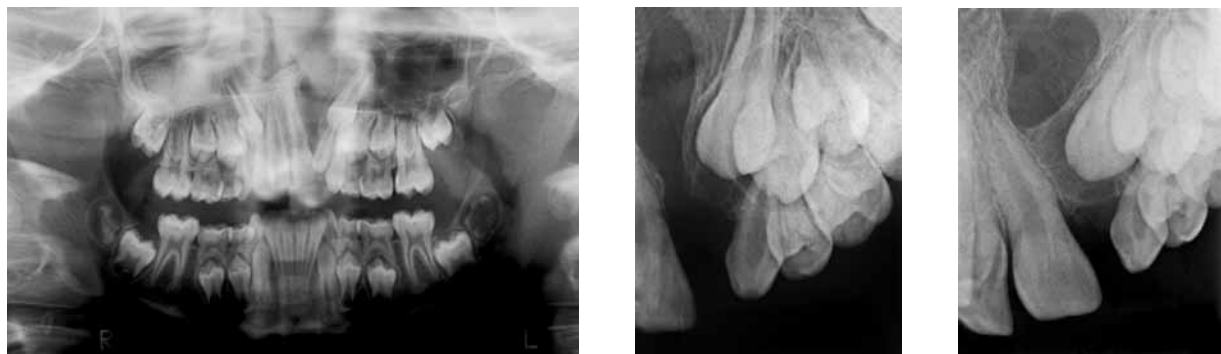

FIGURE 3B - Panoramic radiograph taken before alveolar bone grafting surgery shows the presence of a pre-canine in cleft area, which was removed before grafting surgery. Periapical radiographs enable assessment of outcome 3 months after grafting surgery. A bone tissue bridge was formed, and cleft is no longer present.

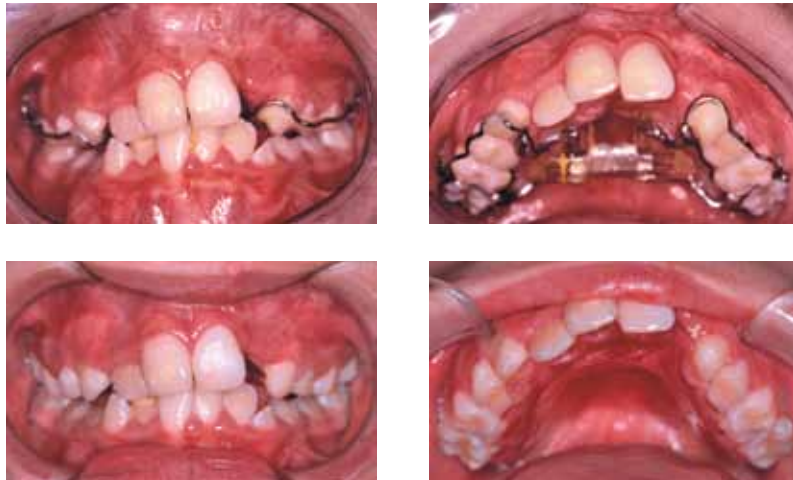

FIGURE 3C - Treatment with rapid maxillary expansion and maxillary traction performed 6 months after bone grafting, corrected the crossbite, but did not split the midpalatal suture.

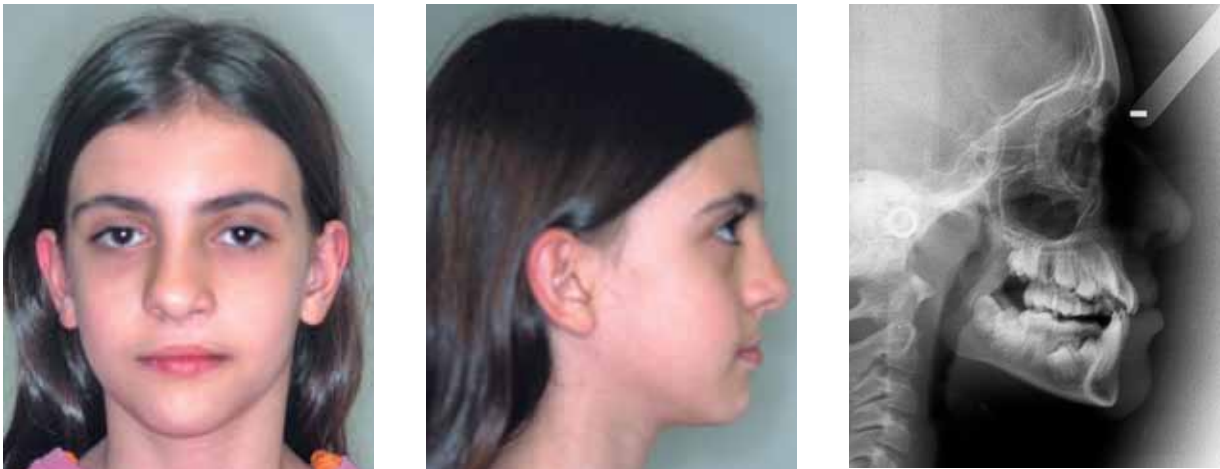

FIGURE 3D - Although the impact of rapid maxillary expansion and maxillary traction on the face was relative it was still able to improve the malocclusion.

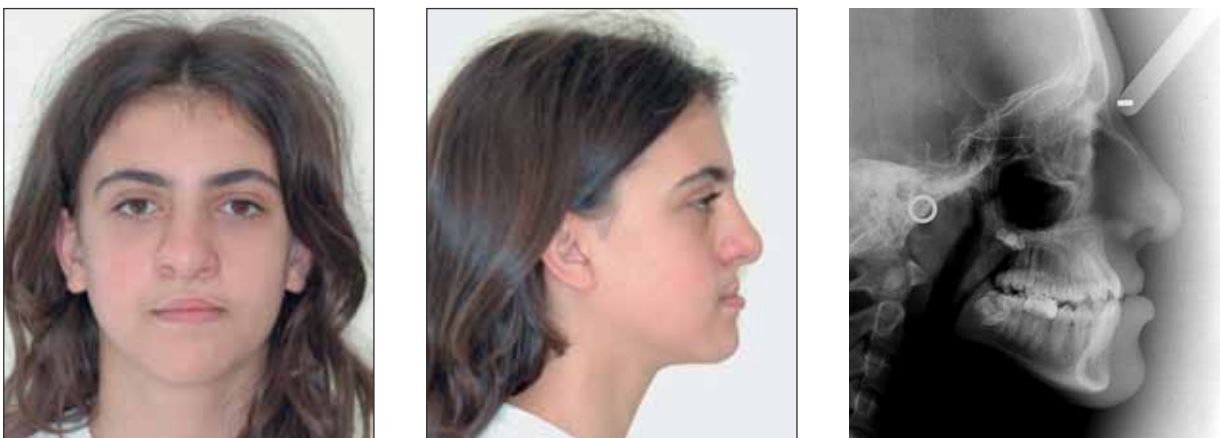

FIGURE 3E - Patient 13 years and 9 months old at the end of growth spurt; Pattern III maintained; face acceptable.

occlusion and speech. The conditions for facial esthetics depend on the type of cleft, facial pattern of the patient and the patients' / guardians' willingness to invest. As a routine results are good, although more or less subtle signs of injury do remain.

The treatment progress of the patient depicted in Figure 3 clearly portrays what in my view can be defined as excellence in the rehabilitation of cleft lip and palate. In summary, the protocol provides: conservative primary surgeries performed with quality in the

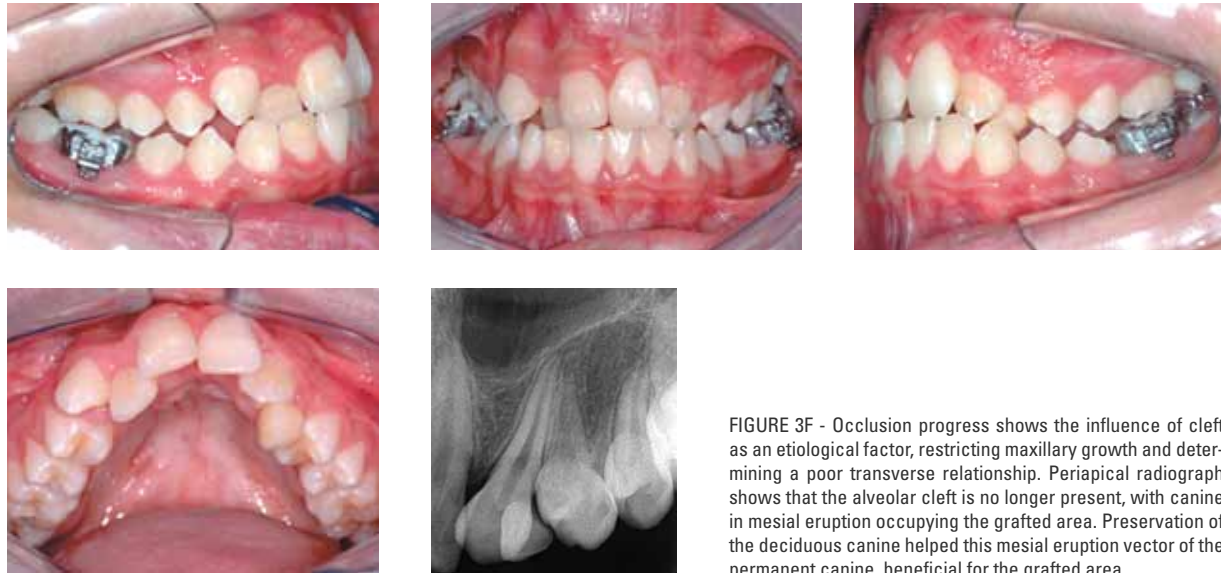


FIGURE 3F - Occlusion progress shows the influence of cleft as an etiological factor, restricting maxillary growth and determining a poor transverse relationship. Periapical radiograph shows that the alveolar cleft is no longer present, with canine in mesial eruption occupying the grafted area. Preservation of the deciduous canine helped this mesial eruption vector of the permanent canine, beneficial for the grafted area.

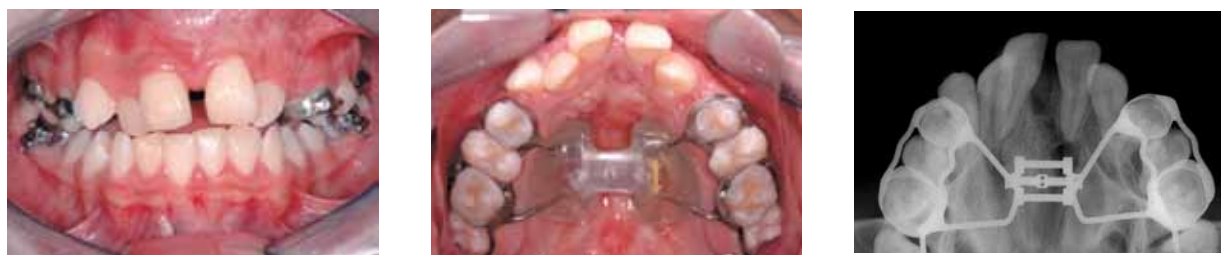

FIGURE 3G - Compensatory orthodontic treatment was performed according to the protocol for standard III malocclusions. Conventionally performed rapid maxillary expansion this time was able to split, albeit partially, the mdpalatal suture. This result is not frequent, but when it occurs, it favors final treatment outcome.

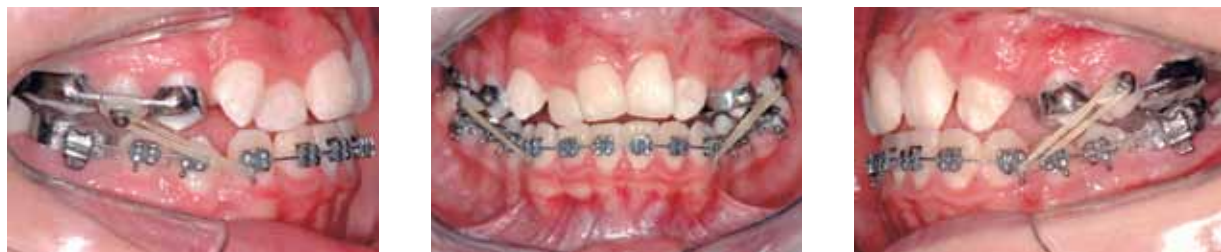

FIGURE 3H - Treatment was conducted according to protocol, beginning with the upper arch, using prescription III brackets, stripping the mesial side of the first premolars and distal side of lower canines, and the use of canine-supported Class III elastics since the beginning of lower arch leveling.

first year of life by an experienced surgeon, cosmetic revisions of the lip and nose, made increasingly early (which is not necessarily good); specific monitoring by a speech therapist, and a dental caries preventive program for monitoring eruption (looking out for dysgenesis) and growth until the pre-grafting phase

(9-11 years). At this point the maxilla is prepared, usually by expanding it. Retention is introduced to preserve the form obtained by the treatment, and bone grafting is made according to protocol.²⁹ Later, in the permanent dentition, orthodontic assessment and planning are performed—in cases for which

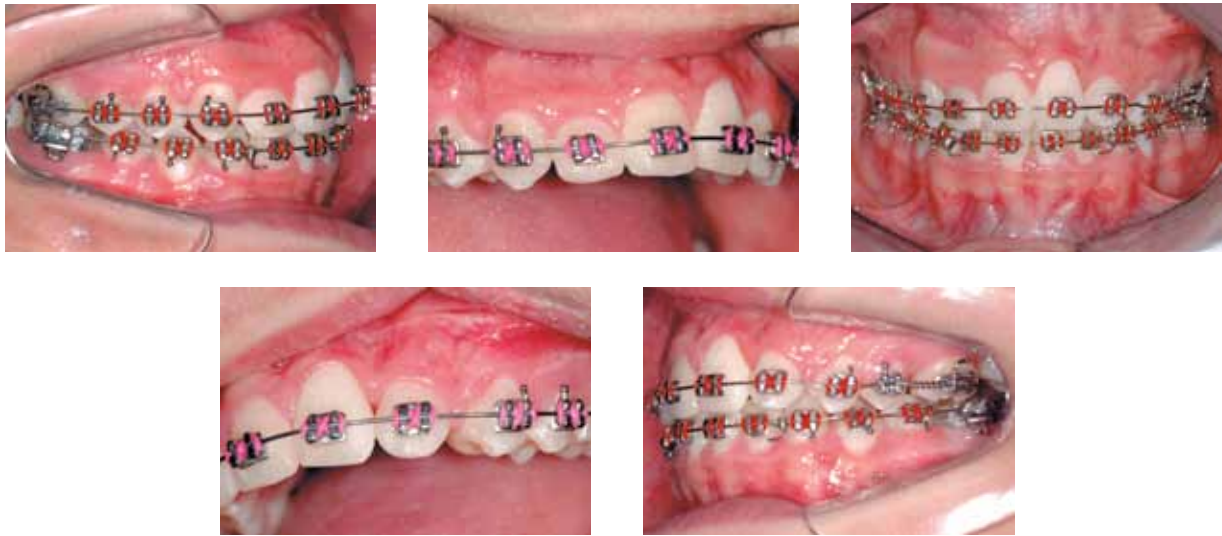


FIGURE 3I - At the end of leveling, occlusion was corrected with molar and canine in Class I relationship on the right side, and tooth 23 in the position of the lateral incisor (canine bracket placed upside down), tooth 24 in the position of the canine (with a canine bracket). Prescription I brackets were used in the upper arch to avoid closure of the nasolabial angle. Treatment protocol is compensatory for pattern III malocclusions in Caucasians. See how repair of the cleft in the alveolus is clinically optimal.

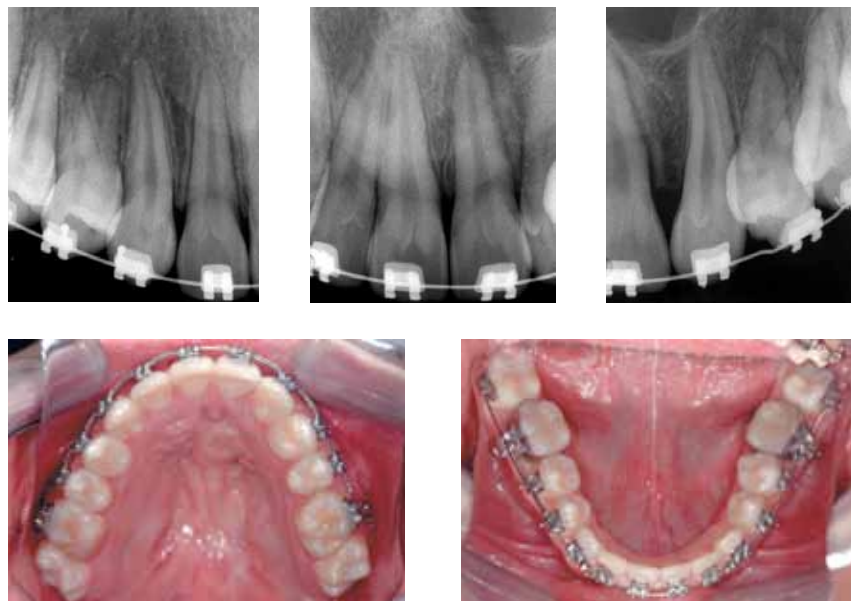


FIGURE 3J - Showing that the shape of the upper arch is similar to what can be achieved in a non-cleft maxilla, and teeth position in the anterior maxilla is symmetrical.

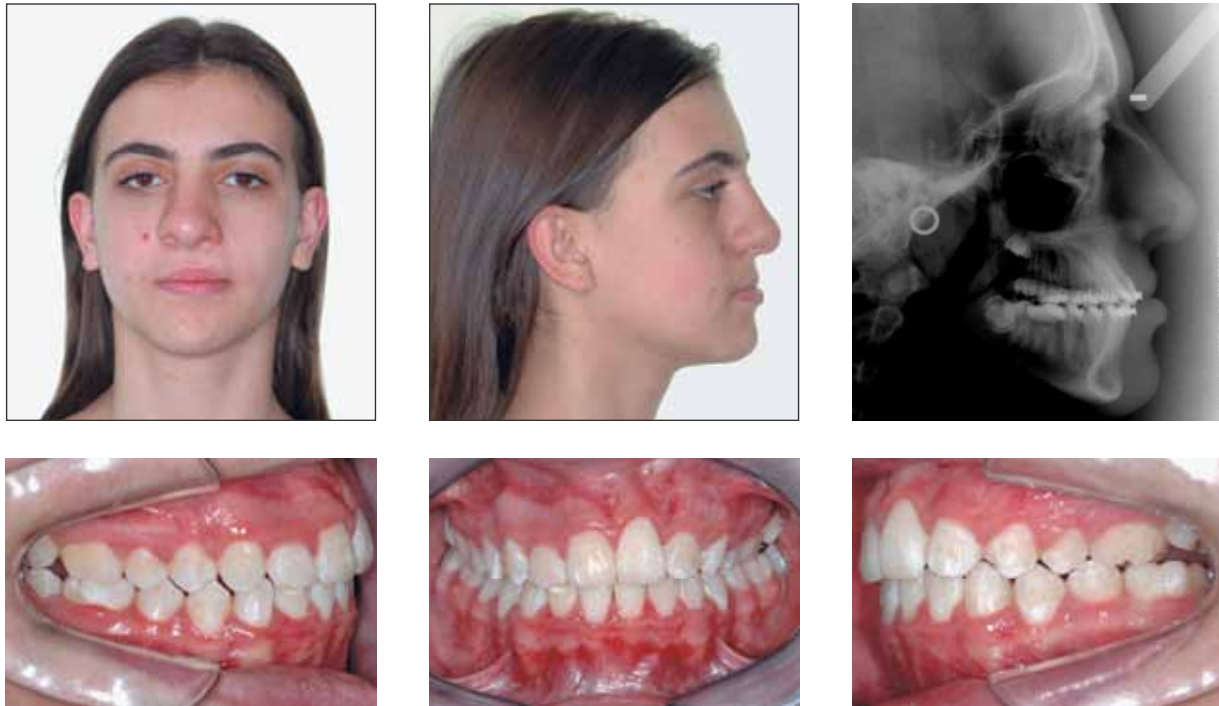


FIGURE 3K - At the end of treatment, adequate occlusion outcome. The face features pattern III characteristics due to maxillary deficiency, with greater soft tissue involvement, acceptable skeletal and dental relations (see lateral cephalogram). Esthetic deficit related to soft tissue can be greatly alleviated by refining surgery on the lip and nose, which is comprised in the final stage of the treatment protocol that the patient has to undergo.

treatment has been successful, orthodontic treatment is often found to be very similar to patients without cleft. Specifically in the case of the patient shown in Figure 3, rapid maxillary expansion was performed after bone grafting, and the mid-palatal suture was split (Fig 3G). This can happen¹⁵ and it adds value to treatment, leading to a final occlusion that resembles even more the one achieved in patients without cleft.

Orthognathic surgery may be used when the patient requires a greater closeness to normality, and serves as an effective and absolutely essential resource to resolve major discrepancies.

Your unorthodox position on the use of cephalometry as the main tool in the diagnosis of malocclusion has been much discussed and, for that matter, criticized. Could you make some comments about this position? Dione do Vale

Since the end of the last decade, convincing evidence has been produced to prove that the use

of cephalometric diagnosis is absolutely unjustified. Those who insist on using it are departing from the key diagnostic concepts that govern contemporary orthodontics. I think it is up to them to try and defend this anachronistic and meaningless position. Cephalometry remains a useful tool for the evaluation of orthodontic patients. Not for diagnostic purposes, but for studying growth, the effects of appliances on teeth or on the skeleton, and so on. From this perspective, cephalometric analysis should be taught within the scope of a subject like the history of orthodontics, and presented as orthodontic culture, but not as a viable method for treatment planning.

Acknowledging that growth pattern is the primary etiological factor in determining malocclusions, considering and investigating the set of changes that defines them beyond the limitations of Angle's classification, are all mandatory. In other words, personal preferences should yield to current

knowledge. Qualitative facial analysis, morphological analysis of radiographs or CT scans of the face and dental arch models are efficient methods in orthodontic diagnosis and prognosis.⁴

Pattern II and III cases treated with compensation may have their results compromised during the final phase of growth. In an attempt to minimize this problem, you individualize the type of retention to be used. To what extent do you feel that this individualization can minimize the negative effects of growth after treatment? Dione do Vale

I do not believe that the compensatory treatment of pattern II and pattern III malocclusions play out quite the same way during the final stage of growth. For pattern II malocclusions the clinical consensus that finds support in the literature is that, when caused by maxillary protrusion, they must be treated in mixed dentition, and when caused by mandibular deficiency, they should be treated in permanent dentition, preferably during pubertal growth spurt. In both circumstances, the best choice of “retention” to preserve results in the late growth phase and even later depends on establishing proper occlusal relationships and an adequate functional pattern (lip contact, nasal breathing, swallowing pattern compatible with patient age). Thus, the sort of retention used in these patients is conventional, with a Hawley retainer for 6 months of continuous use, then another 18 months of night use, and a 3/3 fixed lingual retainer until age 30, optionally for life.

As regards Pattern III malocclusions, the perspective is rather diverse and concerns about growth after treatment are greater. Given that this malocclusion develops on an ongoing basis throughout growth²⁸ it requires a different protocol. The classical treatment, as described in this interview, comprises rapid maxillary expansion and maxillary traction, which characterizes the first phase in early mixed dentition. The best retention for this procedure is no retention at

all, but rather an overcorrection. Then you have to wait until facial growth spurt is over, usually two years after menarche in girls and after full pubescence in boys, always checking with wrist (carpal) X-ray to detect the IJ stage of Hagg and Taranger,²⁰ which is the landmark indicating that compensatory orthodontic treatment should be started, or to determine the need for corrective treatment with orthognathic surgery.⁴ Any orthodontic treatment performed prior to that period, even with high quality occlusal correction, unlike what is allowed for the treatment of compensatory Pattern II malocclusions, does not ensure stability. If the choice falls on compensatory orthodontic treatment, then after performing it—starting from that point considered the initial landmark—the conventional retention program described above may be further reinforced by adding an Osamu¹⁴ dentoalveolar retainer, whose indication will depend on the amount of compensatory movement performed in the lower arch or, in other words, the amount of lingual tipping applied to the teeth of the lower arch (Fig 4). When indicated, and this is very common, this retainer is used at night for two years. Besides, in controlling the case after removal of the appliance, special attention should be given to the vertical and horizontal incisor relation in order to detect primary impingement in this region, which may result from relapse or instability caused by terminal growth of the mandible. When this happens, removal of the 3x3 retainer is indicated, sometimes associated with interproximal stripping of the lower incisors to allow a lingual movement to adjust these teeth.

To complete my answer to your question, I hope I made it perfectly clear that although these steps are taken in terms of retention, the actions that really matter in minimizing the negative effects of growth after treatment are related to the age at which treatment is performed (this is even more important for Pattern III), the quality of occlusal relations and of the functional pattern allowed to these patients, especially those of Pattern II.

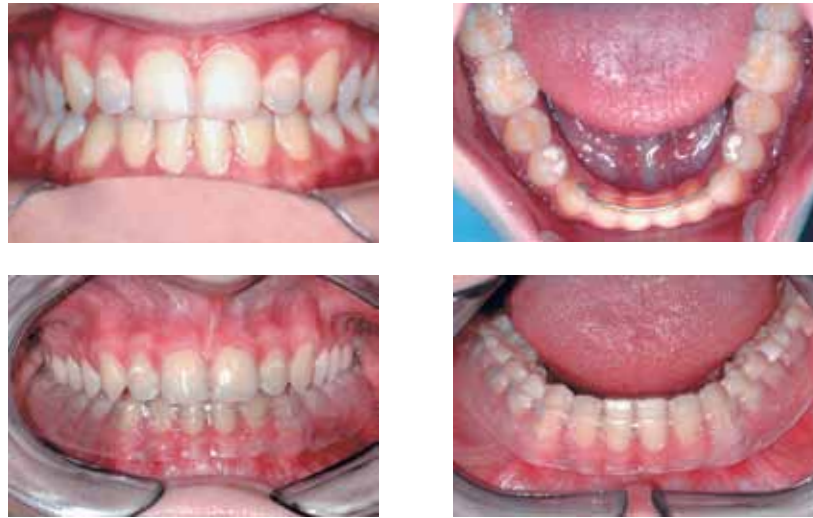

FIGURE 4 - Final occlusion and modified Osamu retainer, without occlusal coverage, placed in order to give stability to the lingual tipping movement applied to the lower teeth during compensatory treatment of a pattern III malocclusion.

Assuming that “normal,” and esthetic occlusion can exhibit many possible angulations and inclinations given the huge morphological variability, do preadjusted brackets offer few prescriptions? Laurindo Furquim

Normal occlusion is not one, but many. We all know that and, increasingly, a greater number of professionals support the thesis behind this reality: the bracket individualization. Originally, from the perspective of the author of the Straight-Wire concept, L. Andrews, the ideal would be a different bracket for each tooth of each patient. This was not, and still is not viable, but I am sure that one day it will be. Because of this limitation, Straight-Wire began with much less than that, but at least with a bracket designed for each tooth. In other words, a bracket for the upper central incisor, another specific bracket for the lateral incisor, and so on. It has been a great evolution. Moreover, without raising widespread interest, brackets were also introduced in order to compensate upper and lower incisors in terms of inclination (torque). As time went by, the understanding of how frequent compensatory treatment² is was established and

other prescriptions have been proposed, including mine.¹² We therefore have many prescriptions available, but they still are not enough for an absolute individualization. What should be done to remedy this limitation is a combination of brackets of different prescriptions, which could provide, overall, the possibility of individualization that is required for each case. It is important that these combinations always be made with the same bracket model and brand so as to ensure standard manufacturing features while preserving other details such as inset and offset positioning. An example of this combination occurs frequently in the compensatory treatment of moderate long face pattern when the therapeutic goal is to keep teeth where they are. In this situation, non-protrusive brackets are used for the upper arch (prescription II plus) and lower arch (prescription III), which is a combination that helps to increase the protrusion typical of leveling and alignment. In addition to the prescriptions built into brackets, remember that in terms of angulations, without a doubt the most important factor in individualization, changes in bracket positioning can create

a wide range of variations. This is so important, and a feature so often used, that my prescription I and prescription II brackets for upper central and lateral incisors (they are the same) were designed without a curved base to allow for this variation in position during direct bonding, so that angulation can be individualized without losing the prescriptions built into the brackets.

Concerning inclination (torque), depending on the accuracy of the available bracket prescription being used in the patient, wires should be used on an individual basis, (a) not to express torque (round wire), (b) to express torque in part (rectangular wire with play, for example 0.019x0.025-in archwire in a 0.022x0.030-in slot), or (c) to express the full bracket torque (rectangular wire with minimal play, for example 0.021x0.025-in in a 0.022x0.030-in slot). Anyway, I am sure that the future will grace us with a wider array of prescriptions. We might even attain what today is still regarded as utopian: a specific bracket tailored for each tooth of each patient.

In my view, the best treatment for Class II patients with mandibular deficiency today is performed by Dr. Carlos Martins Coelho using the Mandibular Protraction Appliance (MPA). His treatment underscores the positioning of lower incisors. Torque control seems pretty consistent. When asked whether these results stem from the application of lingual torque in the lower incisors, Dr. Carlos denies it, saying that this procedure can be adopted in some specific cases, but not as a routine. Dr. Carlos uses incisor brackets with -1 degree torque and 2 degrees angulation, and lower canines with 7° angulation. Assuming that the incisors of patients with Class II mandibular deficiency have a buccal offset, the placement of a rectangular archwire with no torque will apply lingual torque to these teeth. In your view, do angulations and torques in lower brackets make a difference in the treatment

of Class II malocclusion in patients with Class II mandibular deficiency when MPA is being used? Laurindo Furquim

This question encompasses many issues. To address them, I think it is important to review certain concepts underlying the compensatory treatment of Pattern II malocclusions with mandibular deficiency. These should be the foundations for our clinical actions.

- a) Mandibular protraction appliances, including MPA, are clinically effective and accomplish the correction of malocclusion, notably through dentoalveolar changes. The repercussions on the skeleton, including mandibular growth, are of small magnitude and transient, similarly to other mandibular advancement procedures.^{1,16} Even when growth results are significant in terms of mandible management, as shown by the Herbst appliance, they are not maintained consistently by the end of growth.²⁵
- b) From this perspective, the conclusion—also found in the literature—, for all appliances used for the treatment of Pattern II malocclusions with mandibular deficiency, is that the lower teeth are moved forward (incisors are buccally tipped). Whatever the anchoring system, incisor movement is difficult to control.²⁴ Lingual torque in the archwire or lingual torque in the base of incisors brackets cannot stop this tendency. Evidence to prove this assertion comes specifically from the sample of Dr. Carlos Martins Coelho, treated with MPA and which, as you mentioned, has great quality. When analyzed by cephalometry, the results show that the lower incisors are buccally tipped.²⁷ This happens despite the brackets with -1 degree of angulation that would be used by the author.
- c) The occlusal correction achieved with this sort of treatment is stable, provided that adequate dental intercuspation is obtained at the end of therapy, and as long as the patient has a good functional pattern,²⁵ allowing compensatory

adjustments in the posttreatment period. These adjustments mean more movement of the same nature (inclination) and direction as that which is performed during active treatment.

Now, to summarize and focus on the foundation of my answer, it seems that treatment of Pattern II malocclusions with mandibular deficiency is, in fact, compensatory and involves moving the lower arch forward, with inclination of the incisors. That does not seem possible to be controlled. This is the point that lends support to the strategy I use when setting the inclination of brackets in the lower arch of patients with an indication for this treatment: I either agree with or accept the inclination that these teeth already exhibit, and that will be increased.¹²

Thus, incisor brackets have a prescription of 8 degrees of torque, which we call II “plus”, although clinically speaking it is often “minus” because it is common for patients with this malocclusion to have much higher crown inclination during and after treatment.¹⁸ This torque should not be regarded as exaggerated since studies have shown that there are samples of occlusions that have undergone treatment and have been rated as excellent,³ which nevertheless exhibit very pronounced torque values in the lower incisors (maximum: +15 degrees). These values, which correlate with cephalometric values (Wits), suggest that the presence of a Pattern II maxillomandibular relationship is therefore expected and acceptable.

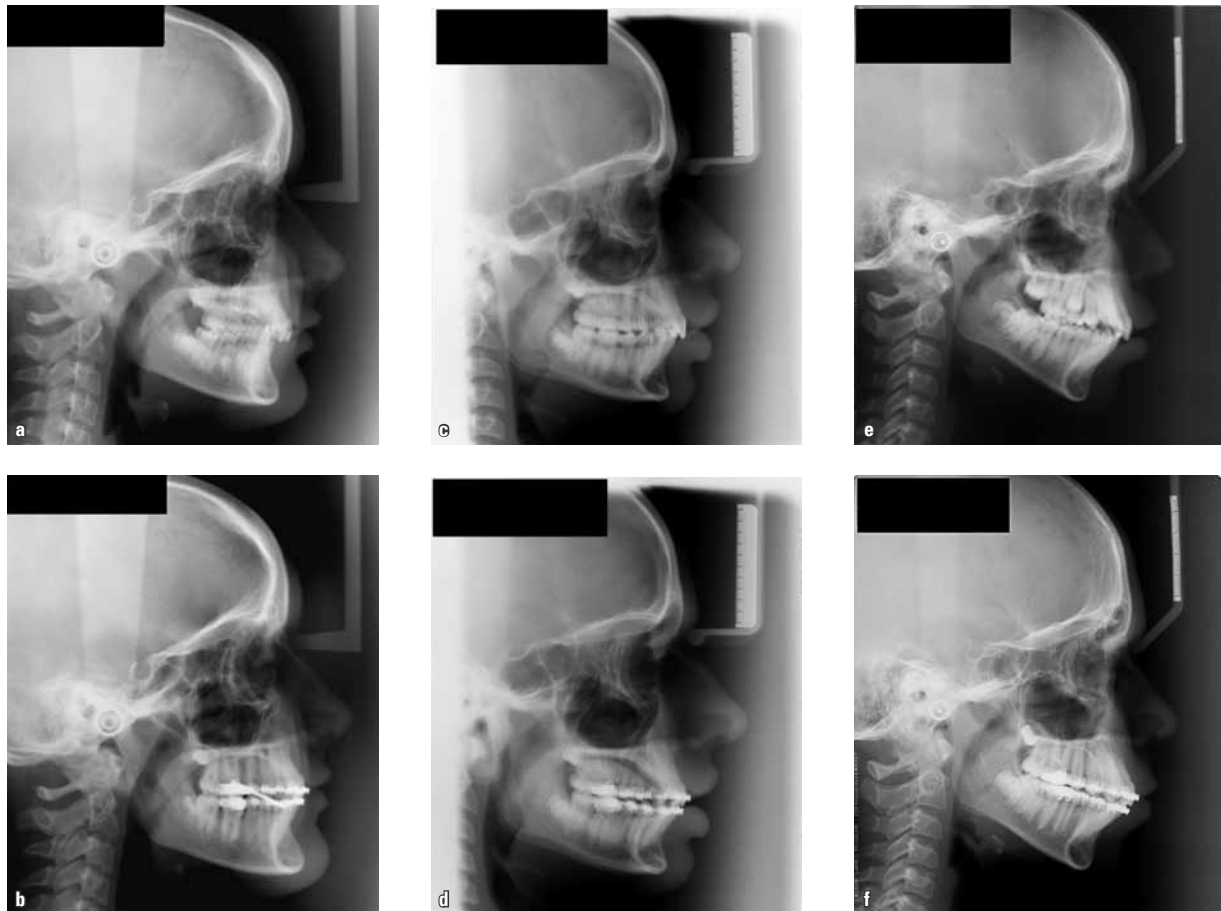


FIGURE 5 - Initial and final lateral radiographs of the face of several patients who made use of MPA and show what appears to be the unavoidable buccal tipping of lower incisors.

Well, +15 degrees is much higher than +8 degrees. How can I adjust this difference, when the lower incisor torque is greater than the torque built into bracket? Basically, I do what everybody does, namely, I use rectangular wires with smaller cross-sections, usually a 0.019x0.025-in wire in a 0.021x0.025-in slot. This creates the so-called clearance angle, which ranges from 7 to 10 degrees (in vitro) and allows a mean, conservative clearance of 7 degrees between the tooth inclination and the torque which was preadjusted in the bracket base.¹¹ Thus, for example, if a patient is using Prescription II Plus bracket (8 degrees) in lower incisors that show a 15° torque, theoretically no clinically significant torque is being delivered to these brackets if the rectangular wire is 0.019x0.025-in. There is evidence to prove that this is true, and here I base myself on results of a CT investigation we conducted in Pattern II patients.¹⁸ My approach therefore relies on a very comfortable safety margin. Supposing that in the same example just given the patient had on a bracket with -1 degree torque, this safety margin would drop to +6 degrees. In other words, if torque values are higher (as is often the case) the lower incisors would presumably undergo lingual torque, which is incompatible with the therapeutic goals and the basal bone conditions shown by the CT scan. Therefore, to give a straightforward answer to your question, any torque pre-built into a bracket can make a difference in the treatment of Pattern II malocclusion with mandibular deficiency. However, this may be masked in most cases by using a progressively smaller rectangular wire gauge as the difference between the torque prescription built into the bracket and the actual torque of the tooth in the basal bone increases.

Since I am searching for brackets that make a difference and allow individualization, which is the essence of the Straight-Wire technique, the idea is to conduct research to support the accurate understanding of this variation and lay

the groundwork for the manufacture of brackets with even greater buccal tipping. This explains why I think it is preposterous, from a logical and biological standpoint, to restrain the buccal tipping movement of mandibular incisors when mandibular advancement is performed in the compensatory treatment of Pattern II malocclusions. There is no support in the literature for any other thesis.

As for angulation, a primary factor in compensation, I think that the brackets you referred to, with +7 degrees angulation in canines and +2 degrees in incisors (which are protrusive brackets) are for the most part suitable for use with devices like the MPA. My prescription II¹² for the lower arch is similar, but with a lower canine angulation (+5). My restriction to the use of these brackets applies to cases where there is crowding in the lower anterior region. In that circumstance, I would use my prescription II brackets, bonding brackets with no angulation on the central and lateral incisors, and with a minimum +3° angulation in canines. The reason being that it doesn't make sense to use brackets that by introducing angulation will create demand for space in a crowded area, and will receive buccal tipping as a result of treatment with mandibular advancement. In so doing, less angulated brackets will require less protrusion for leveling and alignment, and the end-result should be decreased buccal tipping.

What is your opinion about the protocol for orthognathic surgery with anticipated benefit? Do you consider that possibility a reality or a regression? Under what circumstances would you recommend this protocol, considering the risk of instability it involves? Susana Rizzato

It is definitely not a regression. Surely, it is a real possibility in some cases, but seldom a routine approach. Not a regression because, as can be inferred from the article that introduces the

subject,¹⁷ it is only possible by the unrestricted adoption of available knowledge, starting with the adoption of an accurate diagnosis based on current concepts of growth pattern and morphological basis, with a special hierarchical role being played by the face. Moreover, the confidence generated by refinements in surgical technique, the possibility of predicting outcomes, assurance of stable surgical movements given by the use of rigid fixation, and the possibility of movement ensured by orthodontic miniplates, all reflect the evolution of orthodontics and surgery. It would be unreasonable to adopt this procedure in another context, where these technical and scientific developments were not available. Moreover, one should not forget that the main motivation behind this process is to mitigate the esthetic discomfort of the patient, which is commendable and can facilitate treatment for some individuals who would not agree to spend a period of time with their facial relations compromised. In my view, based on my experience with conventional procedures, using this protocol seems more attractive for surgery that targets either bone, maxilla or mandible, mainly for correction of Pattern III malocclusion with maxillary advancement or mandibular setback. I would certainly begin to develop my experience with this procedure through these indications.

In 1996, you published an article with samples of adult patients undergoing orthopedic maxillary expansion, without surgical assistance. In concluding the article about 80% of cases reached the desired therapeutic goals, although with little orthopedic response, and consequently with little opening of the central interincisal diastema. Today, considering the need for a more significant orthopedic response to resolve negative discrepancies of the upper arch; taking into account respiratory status in its relation to nasal resistance, and finally in view of the periodontal condi-

tion resulting from losses in the buccal bone plate of the anchorage teeth, would you still hold your position regarding orthopedic maxillary expansion in adults? Susana Rizzato

This question has the merit of allowing me to update my concepts about rapid maxillary expansion in patients who are out of the growth phase, without surgical assistance. The article to which you refer was published in 1996¹³ and later translated and published in the Dental Press Journal in 1999.⁵ In it, I present the results obtained with rapid maxillary expansion without surgical assistance, in patients no longer in the growth phase, for a period of about ten years. These patients were selected from my private practice, treated in sequence, and after having been advised about the limitations of the research process and the investigative nature of the procedure, all agreed to take part. I was particularly motivated to conduct this research because the literature was unsure about the age limits for rapid maxillary expansion. It was unwilling to conceive of this process after the end of growth. My experience prior to this research gave me grounds to diverge from this concept, since I had performed maxillary expansion in many adult patients. The need, initially for cleft patients and, later, with patients from the postgraduate and specialization programs, had driven the indication for this procedure in adult patients. The results were limited, but enough to treat the malocclusion. With this scenario, the attempt to perform rapid expansion in adults, regardless of age, was proposed and encouraged me to write the article you referred to. The results fully met all my goals, especially owing to the quality of material and methods. After all patients were treated in sequence, always cared for by the same professionals (Dr. João Cardoso Neto and myself), and always using the same type of appliance (Haas modified expander^{5,13}), manufactured by the same laboratory technique. In addition, a history of occurrences was recorded in the chart for further evaluation.

At the end of the experiment, when the sample appeared to be substantive, the results determined the possibilities and limitations of rapid maxillary expansion after the growth phase, and were presented in the article conclusions. Figure 3 shows the possibilities of the process. These possibilities and the experience of going through the treatment of the sample patients, which defies a full definition in so many words,

significantly influenced the protocol that we adopt for this procedure nowadays. After finishing this experiment, I changed my position considerably regarding the indication of rapid maxillary expansion without surgical assistance to patients no longer in the growth phase. In summary, I only indicate this procedure (always using a modified Haas expander) for patients below age twenty, who do not require a significant

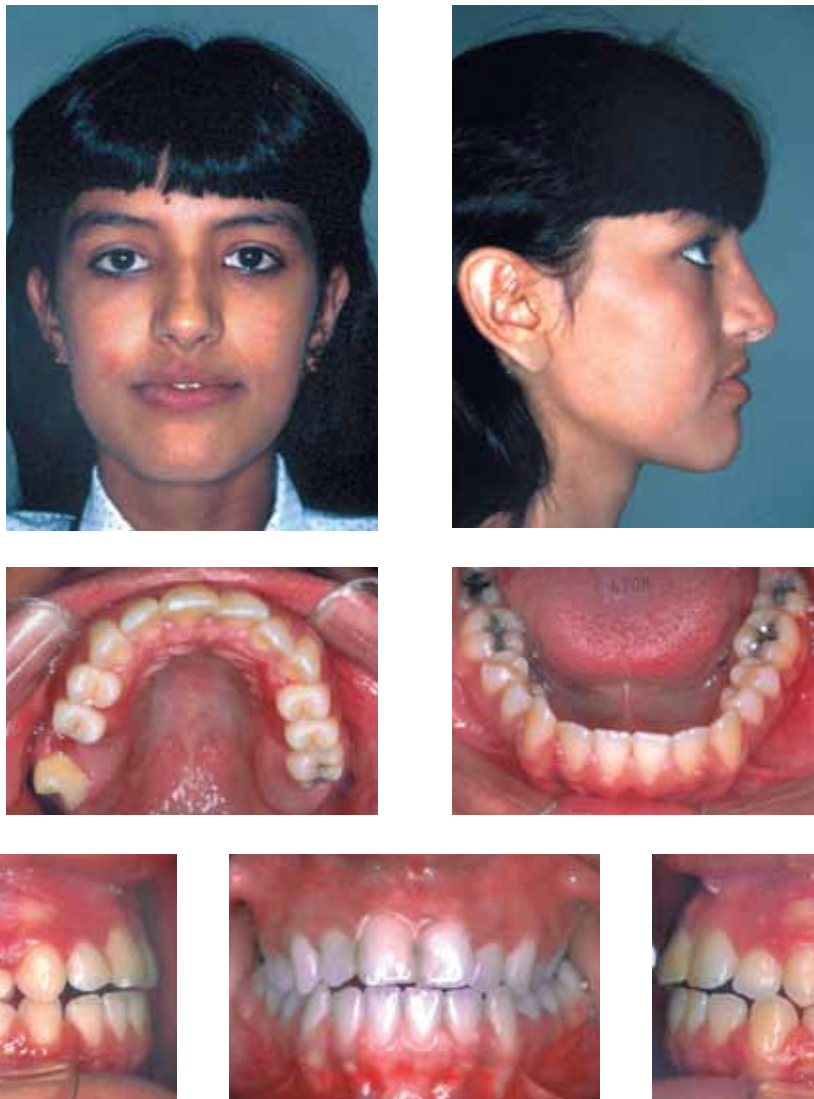

FIGURE 6A - Young adult female patient (21y, 6m), Pattern I borderline to III, due to moderate maxillary deficiency. Half Class II molar relationship on the right, ¼ Class III on the left side, due to early loss of teeth 26, 36 and 46, and recent loss of tooth 16. A moderate expansion of the maxilla could be useful.

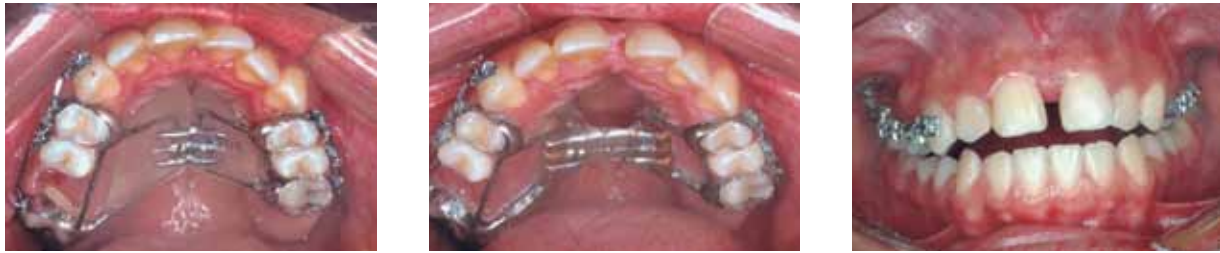

FIGURE 6B - With the patient's consent (limitations), an expansion appliance, adapted to the absence of tooth 16 was indicated, and an expansion that exemplifies the possibilities for patients out of the growth phase was obtained. Note that after activation, it was necessary to grind the acrylic on the right side to relieve pressed area and pain (routine problems in this process).

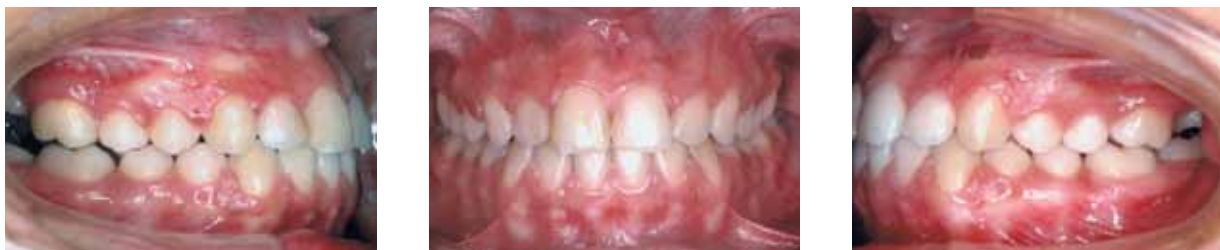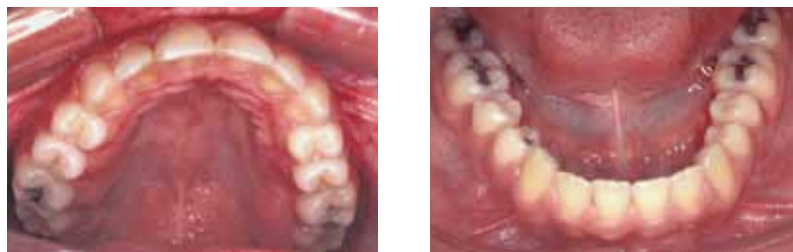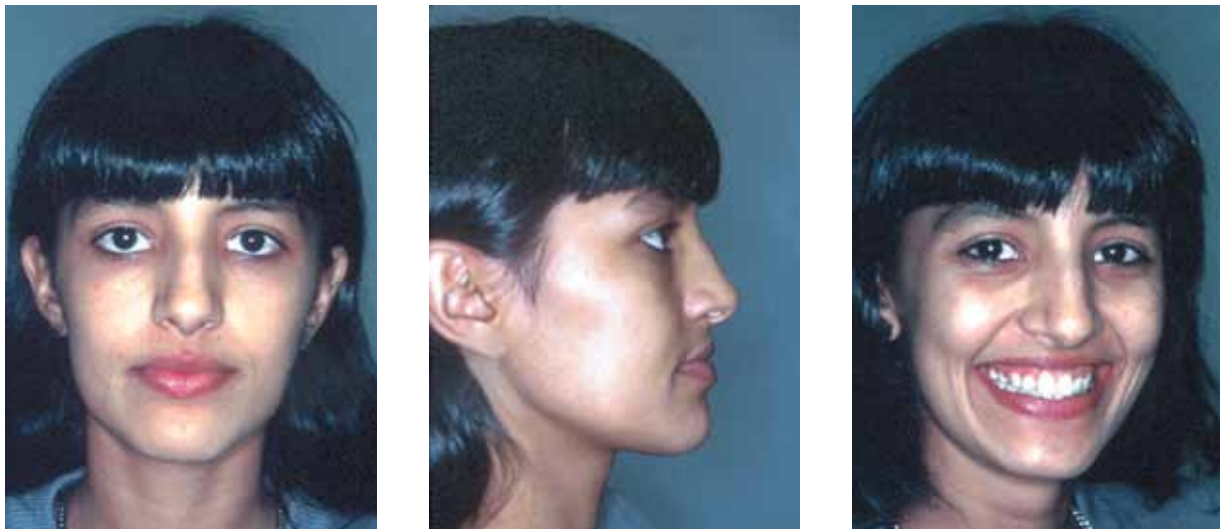


FIGURE 6C - The patient, in addition to expansion, had other benefits, such as replacement of tooth 16 by tooth 17 and improvement in the position of the other second molars, all replacing the first molars, and with all third molars replacing the second molars. This explains the smile that she is displaying, even more than the facial changes which, albeit subtle, were positive.

perimeter gain (maximum opening of the suture = 4 mm), who do not present with periodontal involvement in the teeth supporting the appliance, who are willing to cope with any complications that may arise from the procedure (pain, inflammation, injury), and who can be medicated. Awareness of all these limiting factors and of our ability to perform upper dentoalveolar expansions and lower dentoalveolar constrictions, provided they are supported by a morphological diagnosis, significantly restricts the indication for this procedure today.

Finally, and summarizing the answer to your question, the limitations for rapid maxillary expansion in patients who are no longer in the growth phase without surgical assistance are clear, and circumscribe the effects of the procedure to correction of minor dentoalveolar discrepancies, with no effect on breathing, but jeopardizing periodontal support. Conversely, it would be appropriate to consider that even with rapid maxillary expansion assisted by surgery there is no guarantee of any changes in the

breathing pattern,³⁰ and there are risks to the supporting teeth, including periodontal risks, which has justified the development of implant-supported expansion appliances.²¹

Eventually, orthodontists accepted the orthopedic treatment protocol suggested by Haas and modified by other orthodontists in the correction of Class III malocclusion with anterior crossbite. This approach includes expansion and reverse traction of the maxilla. Do you think transverse mechanics contributes to sagittal response in the early orthopedic correction of Pattern III patients? Omar Gabriel

I would add to your question “wisely”. Eventually, orthodontists wisely accepted the orthopedic treatment protocol suggested by Haas and modified by other orthodontists in the correction of Class III malocclusion with anterior crossbite. It is an absolutely effective protocol, particularly when we achieve the targets set for the treatment by Haas, which is not usual.¹⁹

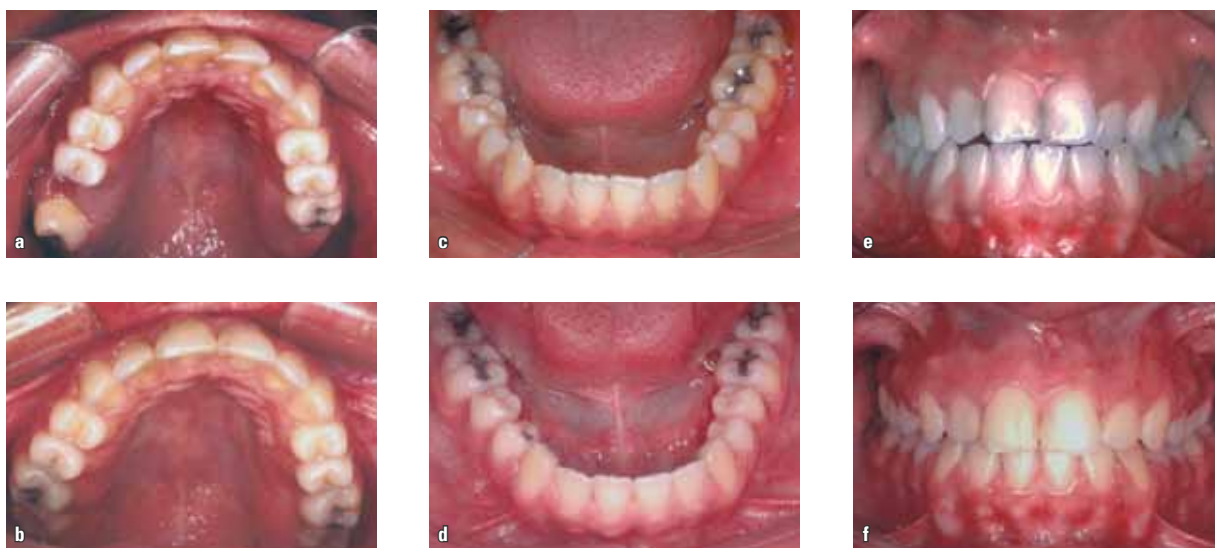


FIGURE 6D - After having been corrected, the arches show (a) expansion in the upper arch (canine = 2 mm, premolar = 4.5 mm, first molar = 4.5 mm), and (b) some constriction in the lower arch (canine = -1.5 mm, premolar = 0 mm, first-molar = 1 mm), sufficient to enable proper occlusion.

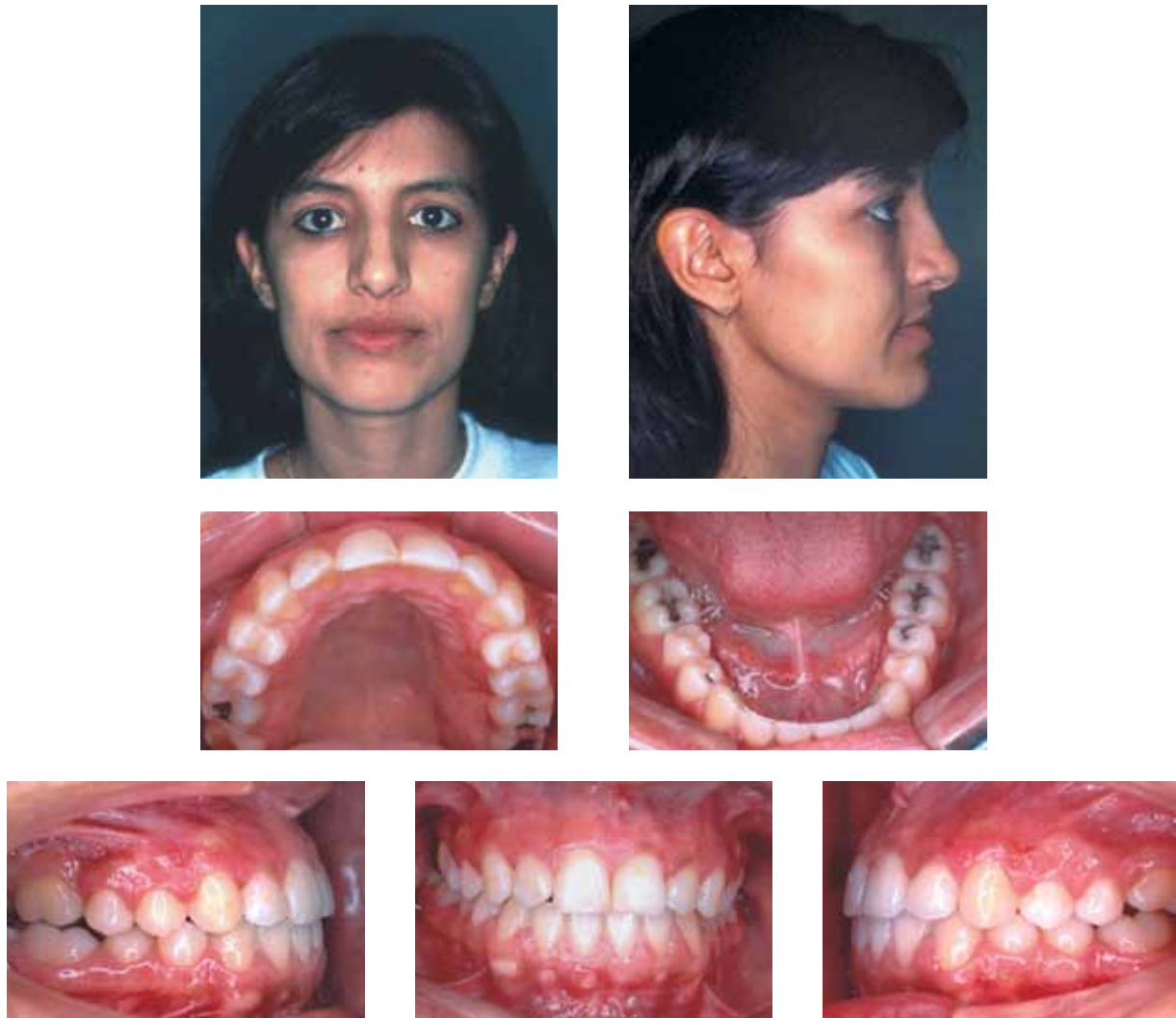

FIGURE 6E - Long-term assessment, eight years after treatment (patient is now 31 years old), seems to justify the treatment.

A large rapid maxillary expansion, and a traction with heavy orthopedic forces are the goals here, and generally good responses are obtained with this protocol. Transverse effects are significant for the sagittal response in the early orthopedic correction of Pattern III malocclusions because, as we already knew and was recently emphasized by the protocol of Liou,^{22,23} a large amplitude rapid maxillary expansion is a critical factor in accomplishing a more significant sagittal response through maxillary traction. Your question

also mentions anterior crossbite. An interesting resource to use under these circumstances is to add anterior bars to the expander passing through the palatal region of the upper incisors (Fig 5), which will prevent the palatal inclination that these teeth perform when filling the space created by the rapid expansion. With the use of these bars fabricated with 0.5mm wire the teeth may move toward the midline, without tipping palatally, which will favor the correction of the anterior crossbite.

The advent of cone-beam computed tomography (CBCT) enabled the viewing of the buccal and lingual bone plates of tooth roots. In what way or to what extent will this influence the freedom to use dental compensation in skeletal discrepancies? Omar Gabriel

The use of CT should be routine soon, allowing very consistent morphological evaluations. I do not think it will modify the classical concepts of compensation and much less change the therapeutic goals for patients who have

this indication. Treatment with these goals has long been made, and with good results. There is positive evidence in the literature, including for the long term, especially for pattern II malocclusions with mandibular deficiency, which are the most frequent malocclusions and are almost always treated compensatorily. We will be able to define the amount of tolerance that normality, expressed by the clinical condition, has with the amount of bone on the buccal and lingual sides of the tooth roots. Certainly once

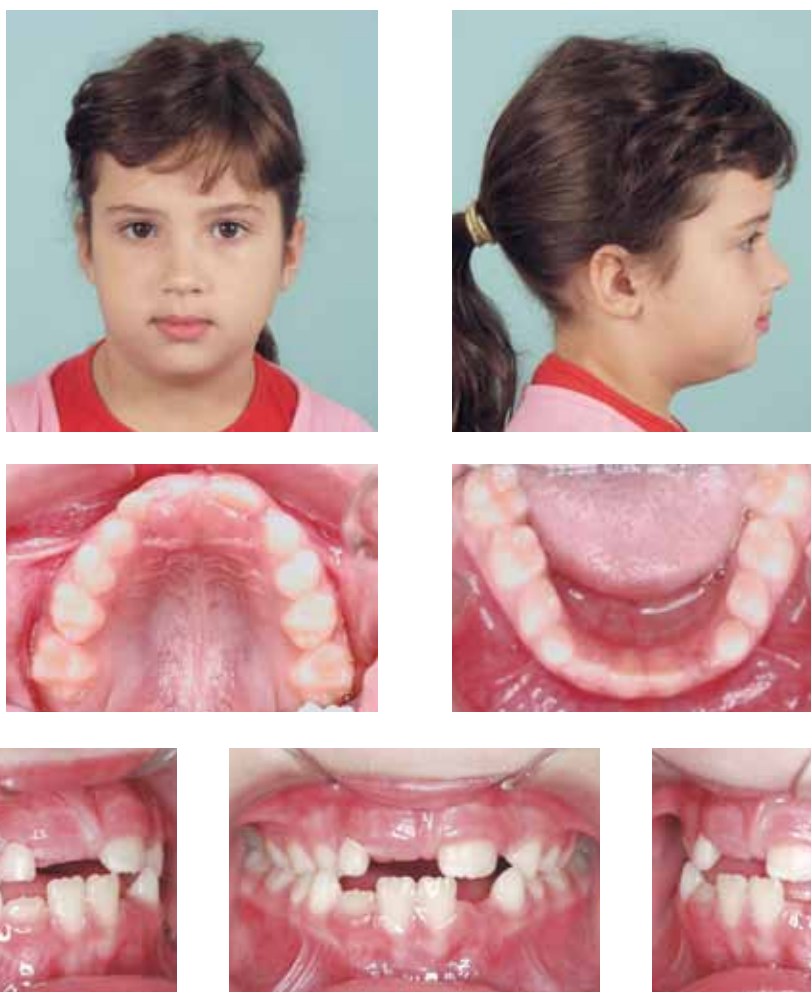

FIGURE 7A - Patient indication for rapid maxillary expansion and risking possible palatal tipping in the central incisors, which could cause anterior crossbite.

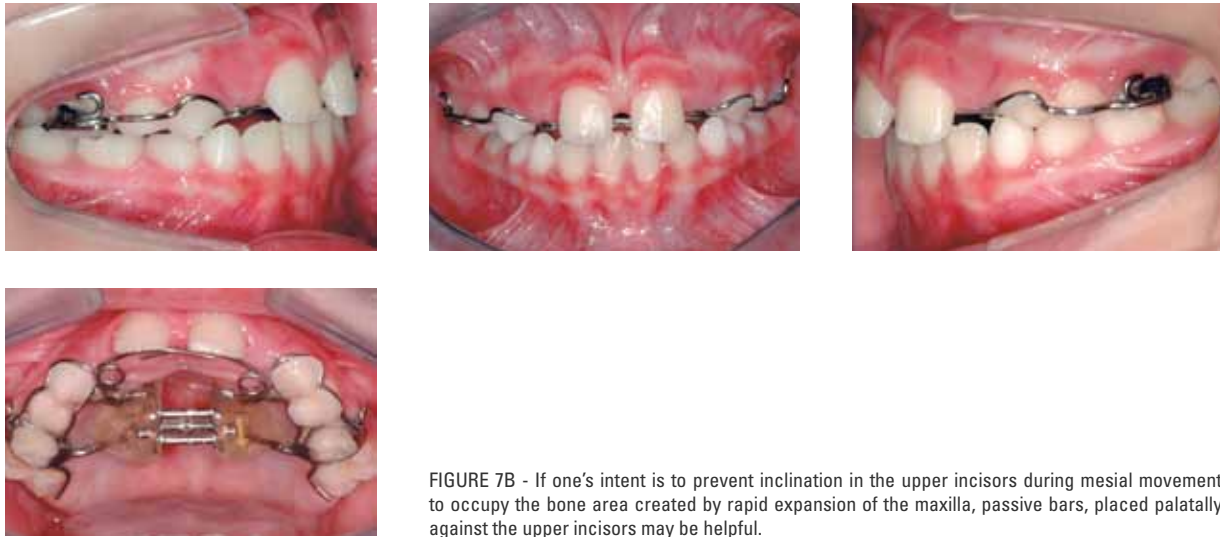


FIGURE 7B - If one's intent is to prevent inclination in the upper incisors during mesial movement to occupy the bone area created by rapid expansion of the maxilla, passive bars, placed palatally against the upper incisors may be helpful.

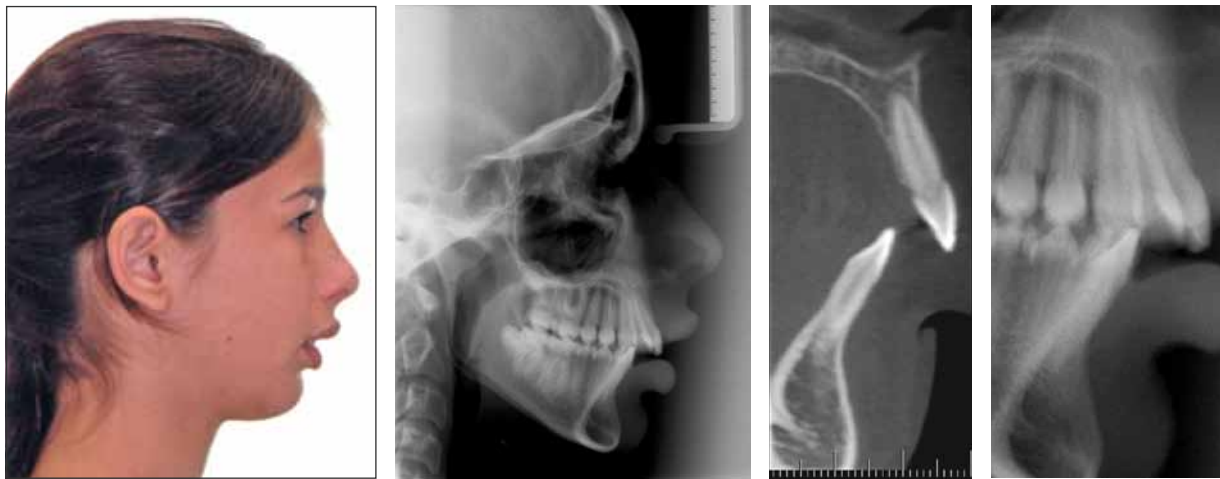


FIGURE 8A - Patient with Pattern II, Class II malocclusion, maxillary protrusion, moderate mandibular deficiency, and CT scan showing more clearly the relationship of the incisors (teeth 21 and 31, image taken by sectioning the center of the clinical crown) and their respective basal bones.

this tolerance is confronted with the tomographic image it will be greater than previously thought. In other words, clinical conditions common to the teeth, especially incisors, in compensatory treatment, are exhibited in CT images with surprisingly scant bone limits. This will underscore the value of clinically assessing the periodontium, especially the attached

gingiva in planning and controlling such movements in daily practice. A quality periodontium can support buccal tipping, either lingual or palatal. Thus, and this is very important, it will become clear that in performing compensatory treatment orthodontists should mimic what nature does when it naturally provides compensation, i.e., buccal, lingual or palatal tipping.

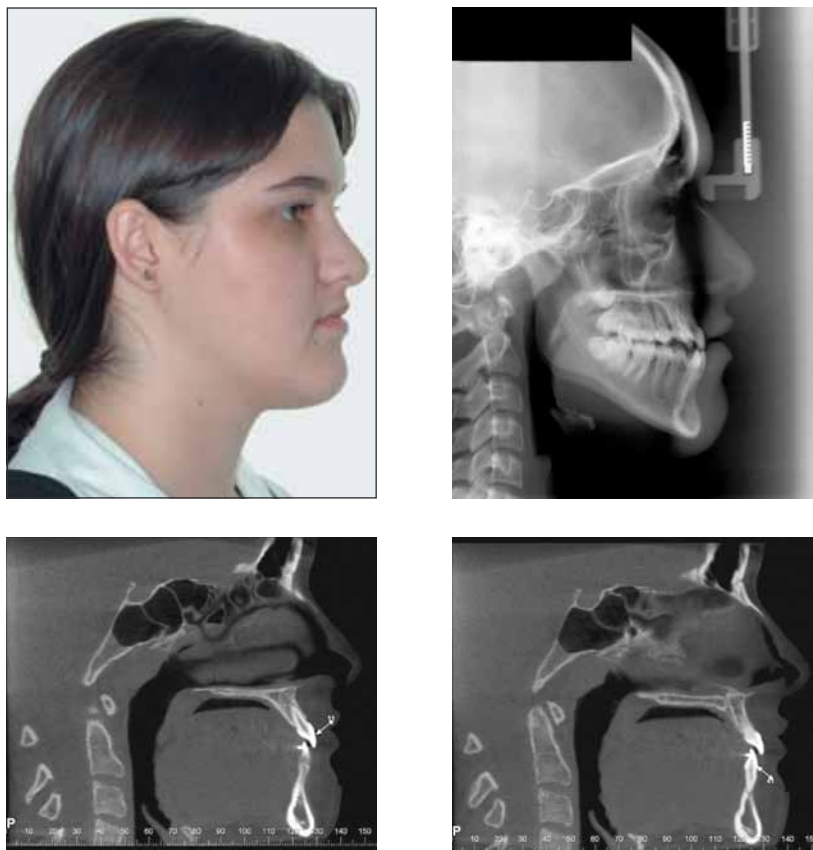


FIGURE 8B - Patient with pattern III, Class III malocclusion, prognathism with CT image clearly showing the limitations of bone support for all incisors (teeth 21 and 31, images obtained by sectioning the center of the clinical crown) and their respective basal bones.

The visualization of teeth in the basal bone, given the quality afforded by CT, lays bare how pretentious it is to try to perform bodily movements (translation) when carrying out compensatory treatment (Figs 8A and 8B). The

scant relationship of the roots on the buccal and lingual surfaces, and often of the root apex with the basal bone, indicates that exerting torque control while performing such movements would not be appropriate.^{10,18}

REFERENCES

1. Aelbers CMF, Dermaut LR. Orthopedics in orthodontics: part I, fiction or reality – a review of the literature. *Am J Orthod Dentofacial Orthop.* 1996 Nov;110(5):513-9.
2. Andrews LF. Entrevista. *Rev Dental Press Ortod Ortop Facial.* 1997 set-out;2(5):6-8.
3. Cabrera CAG, Freitas MR, Janson G, Henriques JFC. Estudo da correlação do posicionamento dos incisivos superiores e inferiores com a relação antero-posterior das bases ósseas. *Rev Dental Press Ortod Ortop Facial.* 2005 nov-dez;10(6):59-74.
4. Capelozza Filho L. Diagnóstico em Ortodontia. Maringá: Dental Press; 2004.
5. Capelozza Filho L. Expansão rápida da maxila em adultos sem assistência cirúrgica. *Rev Dental Press Ortod Ortop Facial.* 1999 nov-dez;4(6):76-83.
6. Capelozza Filho L. Entrevista. Reinaldo Mazzottini. *Rev Clín Ortod Dental Press.* 2008 jan-mar;7(3):48-56.
7. Capelozza Filho L, Mazzotini R. Um recurso clínico: substituição do parafuso expensor em meio à expansão ortopédica da maxila. *Ortodontia.* 1981;14(3):211-20.
8. Capelozza Filho L, Almeida AM, Ursi WJ. Rapid maxillary expansion in cleft lip and palate patients. *J Clin Orthod.* 1994;28(1):34-9.
9. Capelozza Filho L, Reis SAB, Cardoso Neto J. Uma variação no desenho do aparelho expensor rápido da maxila no tratamento da dentadura decídua ou mista precoce. *Rev Dental Press Ortod Ortop Facial.* 1999 jul-ago;4(1):69-74.
10. Capelozza Filho L, Fattori L, Cordeiro A, Maltagliati LA. Avaliação da inclinação do incisivo inferior através da tomografia computadorizada. *Rev Dental Press Ortod Ortop Facial.* 2008 nov-dez;13(6):108-17.
11. Capelozza Filho L, Machado FMC, Ozawa TO, Cavassan AO. Folga braquete/fio – o que esperar da prescrição para inclinação nos aparelhos pré-ajustados. *Rev Dental Press Ortod Ortop Facial.* No prelo. 2010.
12. Capelozza Filho L, Silva Filho OG, Ozawa TO, Cavassan AO. Individualização de braquetes na técnica de Straight-Wire: revisão de conceitos e sugestão de indicações para uso. *Rev Dental Press Ortod Ortop Facial.* 1999 jul-ago;4(4):87-106.
13. Capelozza Filho L, Cardoso Neto J, Silva Filho OG, Ursi WJ. Non-surgically assisted rapid maxillary expansion in adults. *Int J Adult Orthodon Orthognath Surg.* 1996;11(1):57-66.
14. Caricati JAP, Fuziy A, Tukan P, Silva Filho OG, Menezes MHO. Confecção do contensor removível Osamu. *Rev Clín Ortod Dental Press.* 2005 abr-maio;4(2):22-8.
15. Cavassan AO, Albuquerque MD, Capelozza Filho L. Rapid maxillary expansion after secondary alveolar bone graft in a patient with bilateral cleft lip and palate. *Cleft Palate Craniofac J.* 2004 May;41(3):332-9.
16. Cozza P, Baccetti T, Franchi L, Toffo L, McNamara Jr JA. Mandibular changes produced by functional appliances in Class II malocclusion: a systematic review. *Am J Orthod Dentofacial Orthop.* 2006 May;129(5):599.e1-12.
17. Faber J. Anticipated benefit: a new protocol for orthognathic surgery treatment that eliminates the need for conventional orthodontic preparation. *Dental Press J Orthod.* 2010 Jan-Feb; 15(1):144-57.
18. Fattori L. Avaliação das inclinações dentárias obtidas pela técnica Straight-Wire – prescrição Capelozza Classe II [dissertação]. São Bernardo do Campo (SP): Universidade Metodista de São Paulo; 2006.
19. Haas AJ. Entrevista. *Rev Dental Press Ortod Ortop Facial.* 2001 jan-fev;6(1):1-10.
20. Hägg U, Taranger J. Maturation indicators and pubertal growth spurt. *Am J Orthod.* 1982 Oct;82(4):299-309.
21. Koudstaal MJ, Van der Wal KG, Wolvius EB, Schulten AJ. The Rotterdam palatal distractor: introduction of the new bone-borne device and report of the pilot study. *Int J Oral Maxillofac Surg.* 2006 Jan;35(1):31-5.
22. Liou EJ. Effective maxillary orthopedic protraction for growing Class III patients: a clinical application simulates distraction osteogenesis. *Prog Orthod.* 2005;6(2):154-71.
23. Liou E. Entrevista. *Rev Dental Press Ortod Ortop Facial.* 2009 set-out;14(5):27-37.
24. Pancherz H, Hansen K. Mandibular anchorage in Herbst treatment. *Eur J Orthod.* 1988 May;10(2):149-64.
25. Pancherz H. The effects, limitations, and long-term dentofacial adaptation to treatment with the Herbst appliance. *Semin Orthod.* 1997 Dec;3(4):232-43.
26. Pruzansky S. Pre-surgical orthopedics and bone grafting for infants with cleft lip and palate: a dissent. *Cleft Palate J.* 1964;1:164-87.
27. Siqueira DF. Estudo comparativo, por meio de análise cefalométrica em norma lateral, dos efeitos dentoalveolares e tegumentares produzidos pelo aparelho extrabucal cervical e pelo aparelho de protração mandibular, associados ao aparelho fixo, no tratamento da Classe II, 1ª divisão de Angle [tese]. Bauru (SP): Faculdade de Universidade de São Paulo; 2004.
28. Sugawara J, Mitani H. Facial growth of skeletal Class III malocclusion and the effects, limitations and long-term dentofacial adaptation to chin cap therapy. *Semin Orthod.* 1997 Dec;3(4):244-54.
29. Trindade IEK, Silva Filho OG. Fissuras labiopalatinas: uma abordagem interdisciplinar. São Paulo: Ed. Santos; 2007.
30. Warren DW, Hershey HG, Turvey TA, Hinton VA, Hairfield WM. The nasal airway following maxillary expansion. *Am J Orthod Dentofacial Orthop.* 1987 Feb;91(2):111-6.

Dione do Vale

- Master and PhD in Orthodontics, Dental School of Bauru / USP.
- Head of the Orthodontic Care Center of the Defects of Face (CADEFI) in Institute of Integrative Medicine Professor Fernando Figueira (IMIP, Recife / PE).

Susana Maria Deon Rizzato

- Master and Specialist in Orthodontics, UFRGS and PUCRS.
- Graduated by the Brazilian Board of Orthodontics (BBO).
- Professor of Orthodontics at PUC-RS.

Laurindo Furquim

- Degree in Dentistry, Faculty of Dentistry of Lins (1979).
- Specialization in Orthodontics, Faculty of Dentistry of Bauru (1983).
- PhD in Oral Pathology, Faculty of Dentistry of Bauru (2002).
- He is currently a professor of orthodontics at the State University of Maringá (UEM).

Terumi Okada Ozawa

- PhD in Orthodontics, FO-UNESP Araraquara.
- Orthodontist and Director of Division of Dentistry, Hospital for Rehabilitation of Craniofacial Anomalies (HRAC) - USP / Bauru.

Omar Gabriel da Silva Filho

- Coordinator of Update Course in Preventive and Interceptive Orthodontics, promoted by PROFIS (Society for the Social Promotion of Cleft Lip and Palate).
- Professor of the Specialization Course in Orthodontics sponsored by PROFIS.
- Orthodontist in HRAC-USP (Research Hospital and Rehabilitation of Lip and Palate Injuries, University of São Paulo), in Bauru.

Contact address

Leopoldino Capelozza Filho
E-mail: lcapelozza@yahoo.com.br