

Distalization of impacted mandibular second molar using miniplates for skeletal anchorage: Case report

Belini Freire-Maia*, Tarcísio Junqueira Pereira**, Marina Parreira Ribeiro***

Abstract

This study describes a case with an impacted right mandibular second molar which was distalized using miniplates for skeletal anchorage. Uprighting impacted mandibular second molars has been a great challenge for orthodontists and oral surgeons because of the scarcity of anchorage options. Skeletal anchorage was first used in clinical orthodontics in the middle of the 1980s. Since then, several devices have been developed for that purpose, such as mini-screws, tooth implants and, lately, miniplates, which have been tested and showed encouraging results. This topic is relevant for orthodontists and oral surgeons because the use of miniplates may significantly change the treatment of impacted mandibular molars.

Keywords: Skeletal anchorage. Tooth impaction. Molar distalization.

INTRODUCTION

Impacted mandibular second molars are a rather uncommon problem with an incidence of 3 in 1,000 and often pose a challenge for orthodontists and oral surgeons.^{4,8,10} Unilateral impaction is a more common problem and more frequently affects the right side of the mandible of male patients.¹⁰

The possible causes of second molar impaction are the late eruption of second premolars, premature extractions or ankylosis of first molars, dentigerous cysts or odontomas and, finally,

the competition for space by the third molar.⁸ Iatrogenic factors, such as bands and orthodontic loops fixed to the mandibular first molar, may also lead to impactions.¹²

Treatment options depend on tooth inclination, the position of third molars, and the type of movement desired, which may be performed surgically or orthodontically.¹² The best age for treatment is between 11-14 years, when the development of the root of the permanent second molar is still incomplete. Several options have been adopted to treat mandibular molar impaction, and

How to cite this article: Freire-Maia B, Pereira TJ, Ribeiro MP. Distalization of impacted mandibular second molar using miniplates for skeletal anchorage: Case report. *Dental Press J Orthod.* 2011 July-Aug;16(4):132-6.

» The authors report no commercial, proprietary, or financial interest in the products or companies described in this article.

* MSc in Oral and Maxillofacial Surgery and Trauma (OMFST), Unicastelo. Head of the Specialization Course in OMFST, Pontifícia Universidade Católica de Minas Gerais (PUC-Minas), Brazil.

** MSc in Orthodontics, PUC-Minas. Professor, Specialization Course and Master's Program in Orthodontics, PUC-Minas, Brazil.

*** Senior Undergraduate Student, School of Dentistry, PUC-Minas, Brazil.

one of them is skeletal anchorage, successfully used in orthodontics.

Skeletal anchorage is not a recent procedure. It was first used by Creekmore and Eklund in 1983, who placed screws below the anterior nasal spine for incisor intrusion.⁹

After skeletal anchorage became a regular procedure in orthodontics, several fixation methods and rigid devices have been used for tooth movement,⁵ such as tooth implants,^{3,11,13,17} mini-screws^{2,3,6,7,11,13} and titanium miniplates.^{1,2,3,6,7,11,13}

Miniplates are made of commercially pure titanium, which is biocompatible and adapts to bones.^{1,2,6} Miniplates have been used to treat facial fractures for many years¹ and have recently achieved a prominent place among orthodontic anchorage methods due to its high stability.

Kuroda et al⁶ reported that miniplates provide rigid anchorage for several types of tooth movement, but require patient cooperation after implantation, particularly for oral hygiene. Although infections are rare, they occur in 10% of the cases and are only controlled by strict oral hygiene and, in more severe cases, the use of antibiotics.¹⁵ In addition to infections, other complications such as plate fracture and loosening of screws may occur.

CASE REPORT

A 16-year-old boy sought dental care at an oral surgery service with partial impaction of tooth 47.

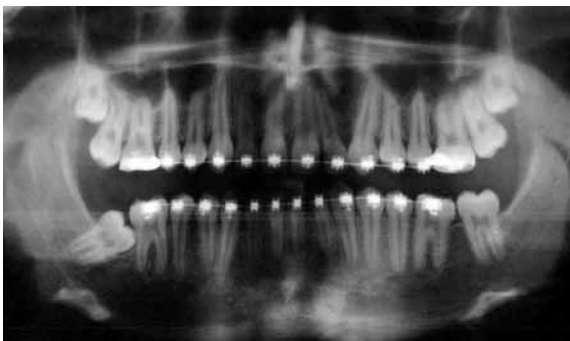


FIGURE 1 - Initial panoramic radiograph shows impacted tooth 47.

A panoramic radiograph confirmed mesial impaction of tooth 47, unerupted maxillary third molars and absence of mandibular third molars (Fig 1). Clinical examination revealed that the crown of the tooth under evaluation was partially exposed in the oral cavity.

The suggestion for treatment was skeletal anchorage using a rigid device placed in the region of the retromolar trigone/mandibular ramus to move the impacted tooth 47 and achieve good occlusion and intercuspation. A 1.0 mm thick straight miniplate with four holes (MDT System 2.0 Ø, MDT®, Rio Claro, Brazil) and two 2.0 mm Ø and 5.0 mm and 7.0 mm long screws.

Surgery for miniplate fixation was performed after the extraction of the maxillary third molars under local anesthesia. A flap was raised by making an incision in the right retromolar region which extended buccally and along the gingival crevice of teeth 47, 46 and 45 to expose the cortical bone (Fig 2).

The selected straight miniplate was previously molded to adapt better to the retromolar region/mandibular ramus, and the screws were fixed after a 1.5-mm bur was used to make the holes in the cortical bone (Fig 3).

The end of the miniplate to be used for orthodontic anchorage was exposed in the oral cavity. Immediately after the surgery, an orthodontic device was placed on the distal face of tooth 47 and

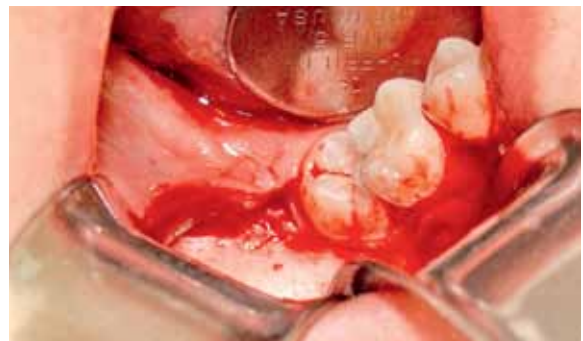

FIGURE 2 - Surgical exposure of the retromolar region/mandibular ramus for miniplate fixation.

traction with an elastic band was initiated.

The incision was closed with 4.0-silk suture, which was removed seven days after the surgery. After the miniplate was fixed, another radiograph was obtained (Fig 4).

For two months, tooth 47 underwent gradual distalization and uprighting produced by the

orthodontic force applied. Three months later, when the tooth had already reached the ideal position (Fig 6), a surgical flap similar to the one used in the first intervention was raised, also under local anesthesia (Fig 7), to remove the miniplate. Total treatment time was three months (Fig 8).

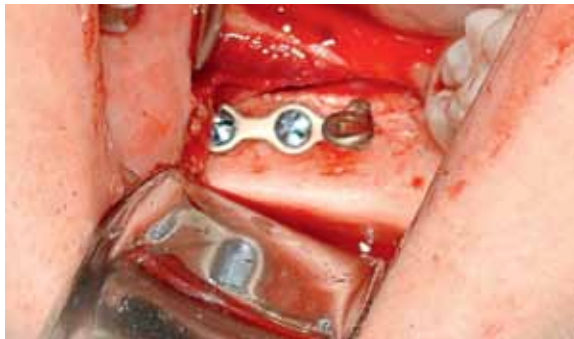

FIGURE 3 - Fixation of miniplate and screws in retromolar region/mandibular ramus.

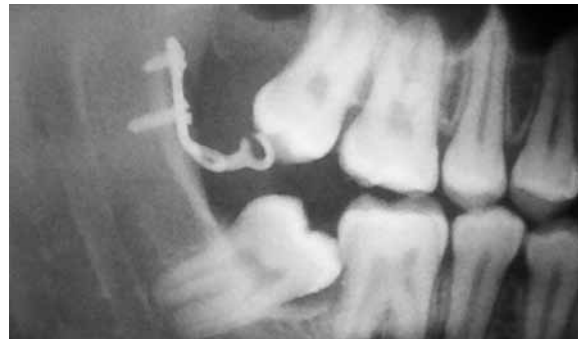

FIGURE 4 - Radiograph obtained immediately after miniplate fixation and before orthodontic movement was initiated.

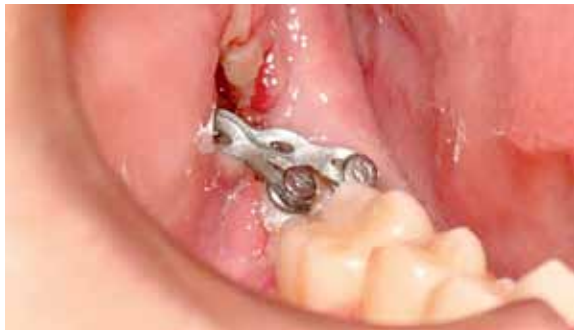

FIGURE 5 - Elastic chain for traction placed from the end of the miniplate to two orthodontic devices bonded to tooth 47.

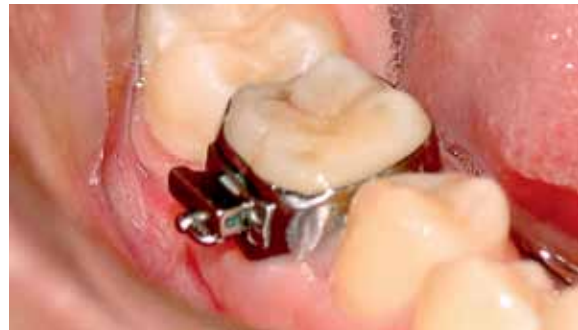

FIGURE 6 - Tooth 47 in upright position after 3 months of treatment.



FIGURE 7 - Miniplate and screws surgically removed after 3-months treatment.

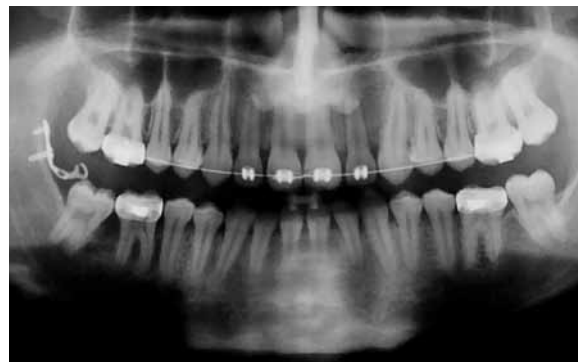

FIGURE 8 - Panoramic radiograph shows tooth 47 in correct position after 3-months treatment.

DISCUSSION

According to Miyahira et al,¹⁰ mandibular second molar impaction is statistically more frequent in the right side of male patients, which was confirmed in the case reported in the present article.

The treatment for second molar impaction, no matter what technique is chosen, should be initiated immediately after the diagnosis because this abnormality may cause caries and periodontal problems, as well as root resorption of the adjacent tooth.

Different treatment options have been discussed in the literature when orthodontic treatment is contraindicated, such as surgical repositioning of the impacted tooth, an option that poses greater risks of complications, such as pulp necrosis, ankylosis and root resorption.¹²

Skeletal anchorage has been evaluated in numerous recent studies and discussions. It provides absolute anchorage, facilitates tooth movement, and is a valuable alternative to orthodontic treatment. Mini-screws,^{2,3,6,11,13} tooth implants^{3,11,13,17} and miniplates^{1,2,3,6,7,11,13} have been used for that purpose.

Mini-screws used in orthodontic anchorage have the advantage of fewer adverse effects and lower operational costs than tooth implants,¹¹ which, according to Miyahira et al,¹⁰ require a longer time for osseointegration, have a higher cost and are difficult to remove.

Mini-screws, however, are not free of complications. Substantially high fracture rates, including fractures that result from their placement, have been reported.²

Choi et al¹ investigated complications after the placement of miniplates for orthodontic anchorage and found high postoperative infection rates. Of the 69 miniplates used in mandibles and maxilla, five led to infection and had to be removed.

Other reasons may also explain miniplate failure, such as the surgical techniques used for insertion, the amount of force, the patient oral hygiene habits and the thickness of the cortical bone, which may contribute to the loss of implanted material.

Sugawara et al¹⁴ showed that skeletal anchorage using miniplates was successful for molar intrusion, distalization and protrusion, which are hardly achieved when using conventional mechanical techniques. Sugawara and Nishimura¹⁵ used the same technique as in our case and achieved success in about 85% of their cases, with plate loosening in only 1% of the cases.

In a recent study, miniplates had a success rate of 96.4% because they resisted reciprocal forces of several traction movements.⁶ Miyawaki et al¹¹ found similar success rates when fixing miniplates with screws longer than 5.0 mm and with a diameter greater than 2.0 mm, a screw size that ensured stability. Similar results have been reported by several authors, who found that miniplates were stable after fixation.^{7,10,13}

CONCLUSION

Miniplates, due to their high stability, may be used for the uprighting of impacted, partially impacted or mesially positioned molars.

In the case reported here, orthodontic treatment was successfully completed after 3 months, and the clinical result was excellent. Based on this experience, we believe that the use of miniplates is a precise, safe and simple method of skeletal anchorage.

Although miniplates are extremely effective, they have some disadvantages, such as the need for surgeries, difficult oral hygiene around the appliance, relatively high cost and the risk of infection and discomfort in the first days after fixation.

REFERENCES

1. Choi BH, Zhu SJ, Kim YH. A clinical evaluation of titanium miniplates as anchors for orthodontic treatment. *Am J Orthod Dentofacial Orthop.* 2005;128(3):382-4.
2. Cornelis MA, Scheffler NR, Nyssen-Behets C, De Clerck HJ, Tulloch JF. Patients' and orthodontists' perceptions of miniplates used for temporary anchorage: a prospective study. *Am J Orthod Dentofacial Orthop.* 2008;133(1):18-24.
3. Eziroglu FV, Uckan S, Ozden UA, Arman A. Stability of zygomatic plate-screw orthodontic anchorage system. *Angle Orthod.* 2007;78(5):902-7.
4. Giancotti A, Arcuri C, Barlattani A. Treatment of ectopic mandibular second molar with titanium miniscrews. *Am J Orthod Dentofacial Orthop.* 2004;126(1):113-7.
5. Kim S, Herring S, Wang IC, Alcalde R, Mak V, Fu I, et al. A comparison of miniplates and teeth for orthodontic anchorage. *Am J Orthod Dentofacial Orthop.* 2008;133(2):189-97.
6. Kuroda S, Sugawara Y, Deguchi T, Kyung HM, Takano-Yamamoto T. Clinical use of miniscrew implants as orthodontic anchorage: success rates and postoperative discomfort. *Am J Orthod Dentofacial Orthop.* 2007;131(1):9-15.
7. Leung MTC, Rabie ABM, Wong RWK. Stability of connected mini-implants and miniplates for skeletal anchorage in orthodontics. *Eur J Orthod.* 2008;30(5): 483-9.
8. McAboy CP, Grumet JT, Siegel EB, Iacopino AM. Surgical uprighting and repositioning of severely impacted mandibular second molars. *J Am Dent Assoc.* 2003;134(11):1459-62.
9. McNamara JA. Microimplants as temporary orthodontic anchorage. Michigan: Ann Arbor; 2007.
10. Miyahira YI, Maltagliati LA, Siqueira DF, Romano R. Miniplates as skeletal anchorage for treating mandibular second molar impactions. *Am J Orthod Dentofacial Orthop.* 2008;134(1):145-8.
11. Miyawaki S, Koyama I, Inoue M, Mishima K, Sugahara T, Takano-Yamamoto T. Factors associated with the stability of titanium screws placed in the posterior region for orthodontic anchorage. *Am J Orthod Dentofacial Orthop.* 2003;124(4):373-8.
12. Sawicka M, Racka-Pilszak B, Rosnowska-Mazurkiewicz A. Uprighting partially impacted permanent second molars. *Angle Orthod.* 2007;77(1):148-54.
13. Sherwood KH, Burch JG, Thompson WJ. Closing anterior open bites by intruding molars with titanium miniplate anchorage. *Am J Orthod Dentofacial Orthop.* 2002;122(6):593-600.
14. Sugawara J, Baik UB, Umemori M, Takahashi I, Nagasaka H, Kawamura H, et al. Treatment and posttreatment dentoalveolar changes following intrusion of mandibular molars with application of a skeletal anchorage system (SAS) for open bite correction. *Int J Adult Orthodon Orthognath Surg.* 2002;17(4):243-53.
15. Sugawara J, Nishimura M. Minibone plates: the skeletal anchorage system. *Semin Orthod.* 2005;11(1):47-56.
16. Tseng YC, Chen CM, Chang HP. Use of a miniplate for skeletal anchorage in the treatment of a severely impacted mandibular second molar. *Br J Oral Maxillofac Surg.* 2008;46(5):406-7.
17. Yanosky MR, Holmes JD. Mini-implant temporary anchorage devices: orthodontic applications. *Compend Contin Educ Dent.* 2008;29(1):12-20.

Submitted: September 19, 2008
Revised and accepted: November 24, 2008

Contact address

Belini Freire-Maia
Avenida Contorno, 4747 conjunto 1011 – Serra
CEP: 30.113-921 – Belo Horizonte/MG, Brazil
E-mail: belinimaia@gmail.com