

# Conservative treatment of a Class I malocclusion with 12 mm overjet, overbite and severe mandibular crowding

Marcos Alan Vieira Bittencourt<sup>1</sup>, Arthur Costa Rodrigues Farias<sup>2</sup>, Marcelo de Castellucci e Barbosa<sup>3</sup>

**Introduction:** A female patient aged 12 years and 2 months had molars and canines in Class II relationship, severe overjet (12 mm), deep overbite (100%), excessive retroclination and extrusion of the lower incisors, upper incisor proclination, with mild midline diastema. Both dental arches appeared constricted and a lower arch discrepancy of less than -6.5 mm. Facially, she had a significant upper incisors display at rest, interposition and eversion of the lower lip, acute nasolabial angle and convex profile. **Objective:** To report a clinical case consisting of Angle Class I malocclusion with deep overbite and overjet in addition to severe crowding treated with a conservative approach. **Methods:** Treatment consisted of slight retraction of the upper incisors and intrusion and protrusion of the lower incisors until all crowding was eliminated. **Results:** Adequate overbite and overjet were achieved while maintaining the Angle Class I canine and molar relationships and coincident midlines. The facial features were improved, with the emergence of a slightly convex profile and lip competence, achieved through a slight retraction of the upper lip and protrusion of the lower lip, while improving the nasolabial and mentolabial sulcus. **Conclusions:** This conservative approach with no extractions proved effective and resulted in a significant improvement of the occlusal relationship as well as in the patient's dental and facial aesthetics.

**Keywords:** Malocclusion. Angle Class I malocclusion. Comprehensive orthodontics.

**Introdução:** paciente do sexo feminino, 12 anos e 2 meses de idade, apresentava molares em relação de chave de oclusão e caninos em relação de Classe II de Angle, sobressaliência acentuada (12mm), sobremordida profunda (100%), excessiva retroinclinação e extrusão dos incisivos inferiores e projeção dos superiores, com leves diastemas interincisais. Ambas as arcadas apresentavam-se constrictas e a discrepância dentária inferior era de -6,5mm. Do ponto de vista facial, apresentava grande exposição dos incisivos superiores em repouso, interposição e eversão do lábio inferior, ângulo nasolabial agudo e perfil convexo. **Objetivo:** apresentar um caso clínico de má oclusão de Classe I com sobremordida e sobressaliência acentuadas, além de apinhamento severo, tratado com método conservador. **Métodos:** o tratamento foi constituído de leve retração e intrusão dos incisivos superiores, e projeção dos incisivos inferiores até que todo o apinhamento fosse eliminado. **Resultados:** obteve-se sobremordida e sobressaliência satisfatórias, manutenção da relação de chave de oclusão nos molares e obtenção dessa relação nos caninos e linhas médias coincidentes. As características faciais obtidas foram positivas, originando um perfil bastante agradável, com selamento labial passivo, promovido pela leve retração do lábio superior e projeção do lábio inferior, melhorando o ângulo nasolabial e o mentolabial. **Conclusão:** a abordagem conservadora, sem exodontias, mostrou-se efetiva e resultou em sensível melhora do relacionamento oclusal e da estética dentária e facial da paciente.

**Palavras-chave:** Má oclusão Classe I de Angle. Ortodontia corretiva.

» Patients displayed in this article previously approved the use of their facial and intraoral photographs.

<sup>1</sup> PhD and MSc in Orthodontics, UFRJ. Professor of Orthodontics, UFBA. Coordinator of the Specialization course in Orthodontics, UFBA. Director of the Brazilian Board of Orthodontics and Facial Orthopedics (BBO).

<sup>2</sup> Specialist in Orthodontics, UFBA. Master student in Dentistry, UFRN. Orthodontist of the Facial Deformities Unit, UFRN.

<sup>3</sup> MSc in Dentistry, UFBA. Specialist in Orthodontics, PUC Minas. PhD student in Dentistry, UFBA. Professor, Department of Orthodontics, UFBA.

**How to cite this article:** Bittencourt MAV, Farias ACR, Castellucci e Barbosa M. Conservative treatment of a Class I malocclusion with 12 mm overjet, overbite and severe mandibular crowding. *Dental Press J Orthod.* 2012 Sept-Oct;17(5):43-52.

**Submitted:** May 20, 2009 - **Revised and accepted:** July 11, 2012

» The authors report no commercial, proprietary, or financial interest in the products or companies described in this article.

**Contact address:** Marcos Alan Vieira Bittencourt  
Av. Araújo Pinho, 62 – Faculdade de Odontologia da UFBA – 7º andar – Canela  
Salvador/BA - Brazil – ZIP CODE: 40.110-150  
E-mail: alan\_orto@yahoo.com.br

## INTRODUCTION

Orthodontic treatment options to tackle negative discrepancy cases – with or without extractions – have always been controversial.<sup>16</sup>

Crowding usually affects the anterior region and, less frequently, the posterior region, often manifesting itself during puberty. It has a multifactorial etiology and may be linked to a decreased arch length, occlusion maturation, mesial force vector, muscle balance, morphology, tooth loss and retention.<sup>17</sup>

Crowding can be corrected without dental extractions by distalization of posterior teeth, projection of anterior teeth, arch expansion and selective stripping, or with tooth extractions, usually premolars. The position of the teeth in space, their movement, and the stability of the final result, in addition to facial aesthetics, are important conditions that must be considered in treatment planning.

Malocclusions characterized by crowding and severe overjet can interfere with social relations since facial aesthetics is regarded as a determining factor in society's as well as the individual's perceptions of themselves. Moreover, dissatisfaction with one's appearance is the main reason why people seek orthodontic treatment.<sup>6</sup> In this context, the severity of anterior crowding is probably one of the most important elements in the development of a treatment strategy. The approach can vary, however, depending on malocclusion severity and the orthodontist's technical-scientific knowledge.

It is a known fact that depending on how treatment is planned and carried out different responses can be induced in the soft tissues. Positive and negative correlations between incisor positioning and the lips have been found by several authors,<sup>1,2,14,22</sup> who reported that variables such as lip morphology, type of treatment (with or without extraction), gender and age are responsible for individual differences in soft tissue response.

This article aimed to report a case of an adolescent patient with Angle Class I malocclusion, Class II skeletal pattern with 12 mm overjet, 100% overbite and severe crowding in the premolar region, treated without extractions.

## CLINICAL CASE REPORT

Female patient of mixed ethnicity, aged 12 years and 2 months, sought orthodontic treatment at the

Professor José Édimo Soares Martins Center for Orthodontics and Facial Orthopedics, School of Dentistry, Federal University of Bahia, Brazil, with the chief aesthetic complaint of pronounced overjet and severe crowding.

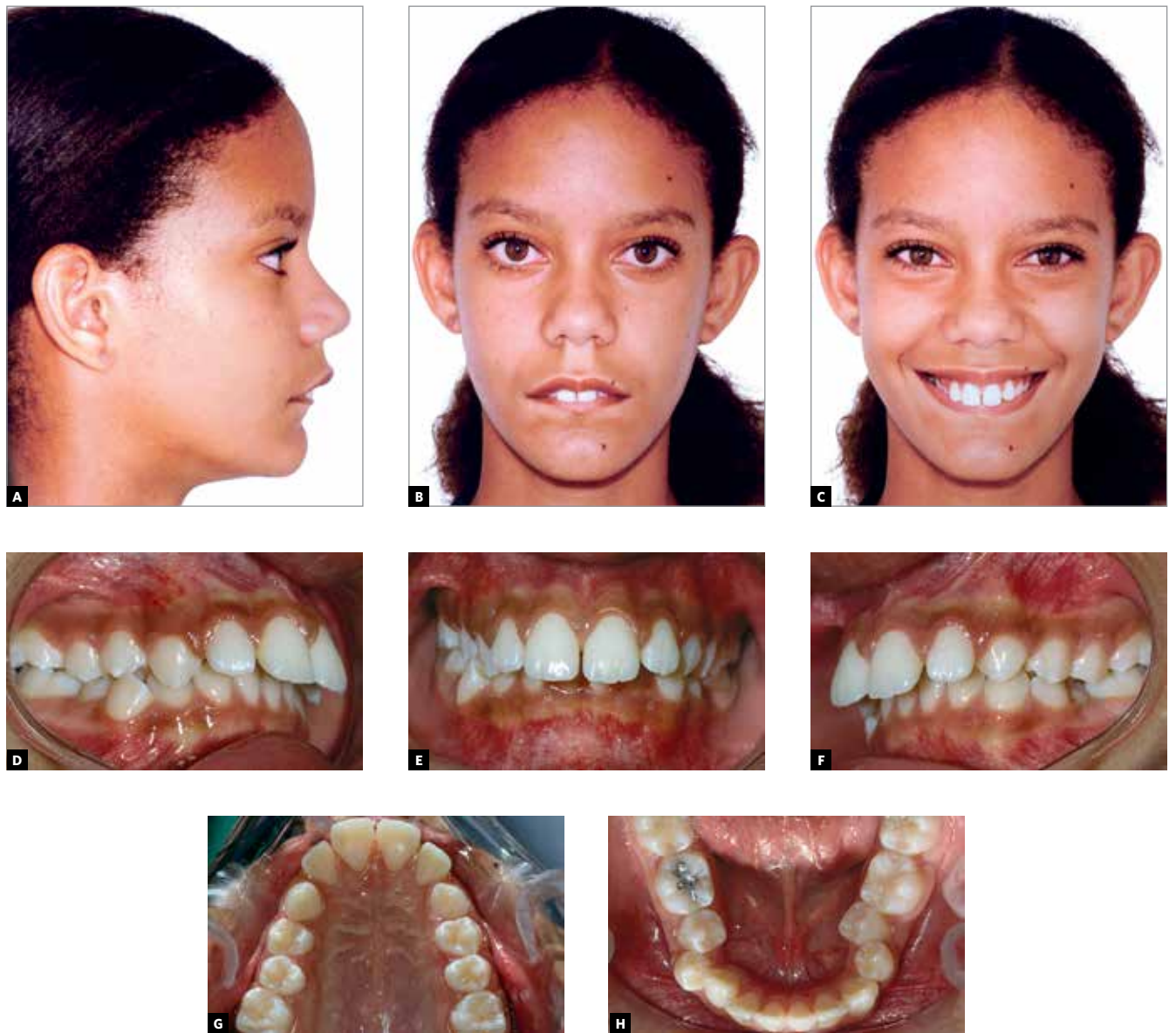She was in good general health. Extraoral analysis disclosed a dolichocephalic, symmetrical facial pattern, with balanced facial thirds, convex profile, proportional nose, lower lip interposition habit, nasolabial angle close to 90° and shallow mentolabial sulcus. When smiling, she displayed a wide buccal corridor (Figs 1A, B and C).

Intraoral examination revealed an elliptical upper arch and square lower arch with considerable crowding in the premolar region, deep curve of Spee and upright mandibular incisors, forming a rather shallow mentolabial sulcus due to insufficient protrusion of the lower lip. The patient presented with Angle Class I malocclusion, with a slight midline deviation to the right, 12 mm overjet and 100% overbite. The arch length discrepancy was less than -6.5 mm (Figs 1D-H). She had healthy periodontal tissues, maintained regular oral hygiene and had a slight biofilm accumulation in the cervical thirds of the regions affected by crowding.

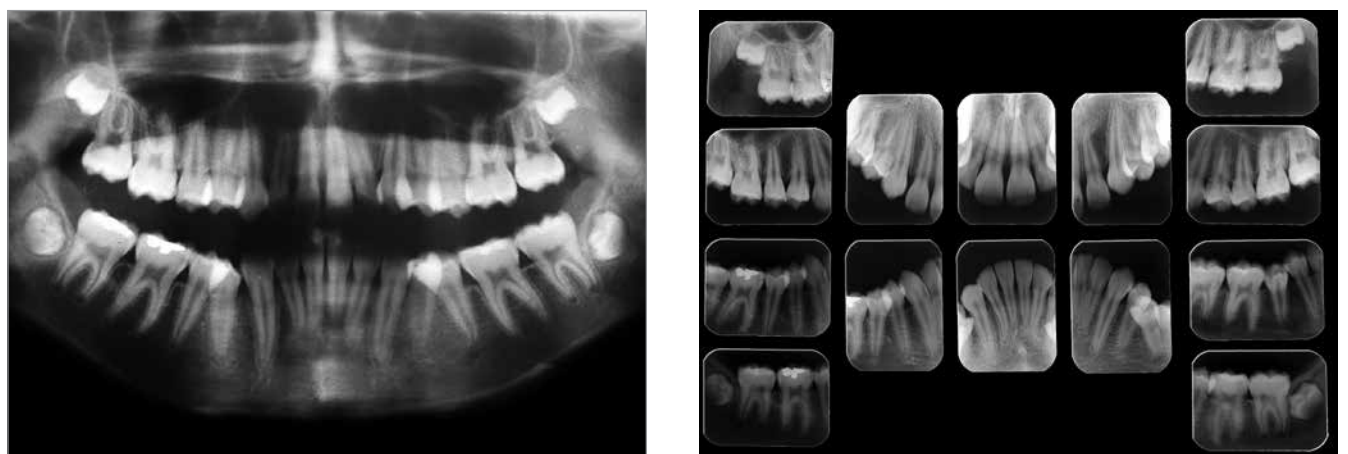The panoramic and periapical radiographs showed the presence of all permanent teeth, including impacted third molars (Fig 2). The lateral cephalogram can be seen in Figure 3. In the cephalometric analysis, an ANB angle of 5° underscored her Class II skeletal pattern, confirmed by analysis of Wits, with a 3 mm maxillomandibular discrepancy. The lower incisors appeared upright in their apical base, and the upper incisors proclined and protruded (I.NA = 32°, I-NA = 9 mm, I.NB = 17°, I-NB = 3 mm, IMPA = 85°). Bolton analysis indicated anterior and total tooth sizes within normal limits. Examination of hand and wrist radiographs revealed that pubertal growth spurt was nearly at its peak (Fig 4).

## Treatment goals

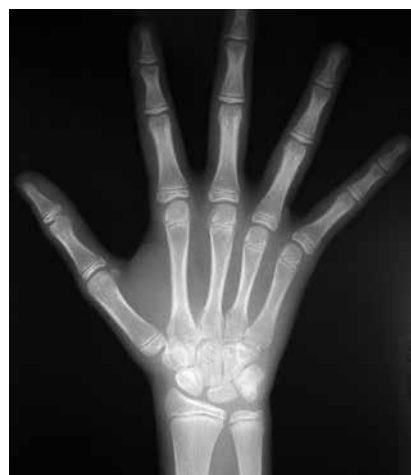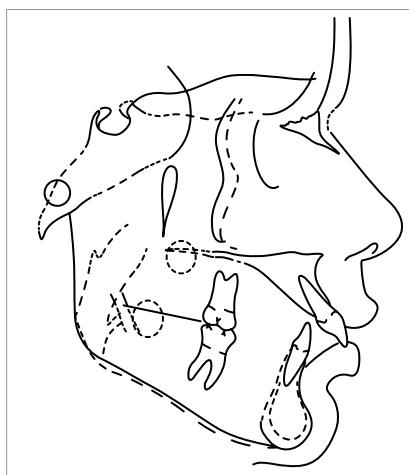
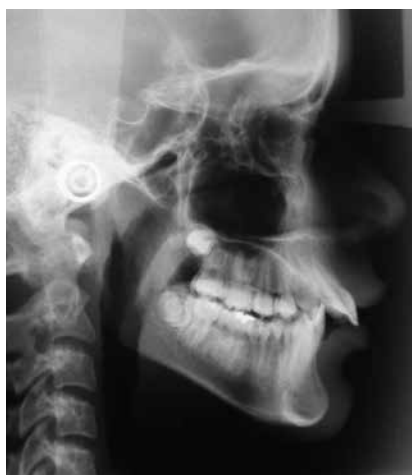The treatment goals were as follows: 1) Ensure proper oral hygiene, 2) improve the skeletal relationship between maxillary and mandibular basal bones, 3) preserve the normal occlusion, 4) establish a normal canine occlusion, 5) correct the upper midline deviation; 6) improve the form of the upper and



**Figure 1** - Pretreatment facial and intraoral photographs.



**Figure 2** - Pretreatment panoramic and periapical radiographs.



**Figure 3** - Pretreatment lateral cephalometric radiographs and cephalometric tracing.

**Figure 4** - Pretreatment hand-wrist radiograph.

lower arches as well as interarch coordination, 7) adjust overbite and overjet at a proper level, 8) eliminate the lower negative discrepancy, 9) restore normal masticatory function with a mutually protected occlusion, 10) enable lip competence, 11) achieve satisfactory facial aesthetics, improving the profile.

### Planning

An important point to consider in the treatment plan is that the facial profile could be severely affected if the option to extract four premolars had been made, which at first seemed to be the wisest choice. However, the patient had a nasolabial angle of  $90^\circ$  and a shallow mentolabial sulcus, which could be worsened by the extractions. After careful study, a diagnostic simulation was carried out (orthodontic setup) without extractions as a guide to planning and to help envisage, as closely as possible, the final treatment outcome.

Based on the data, it was decided that the most suitable option would be to perform orthodontic treatment without extractions, with intrusion and protrusion of the anterior mandibular teeth and arch form adjustment.

### Treatment progress

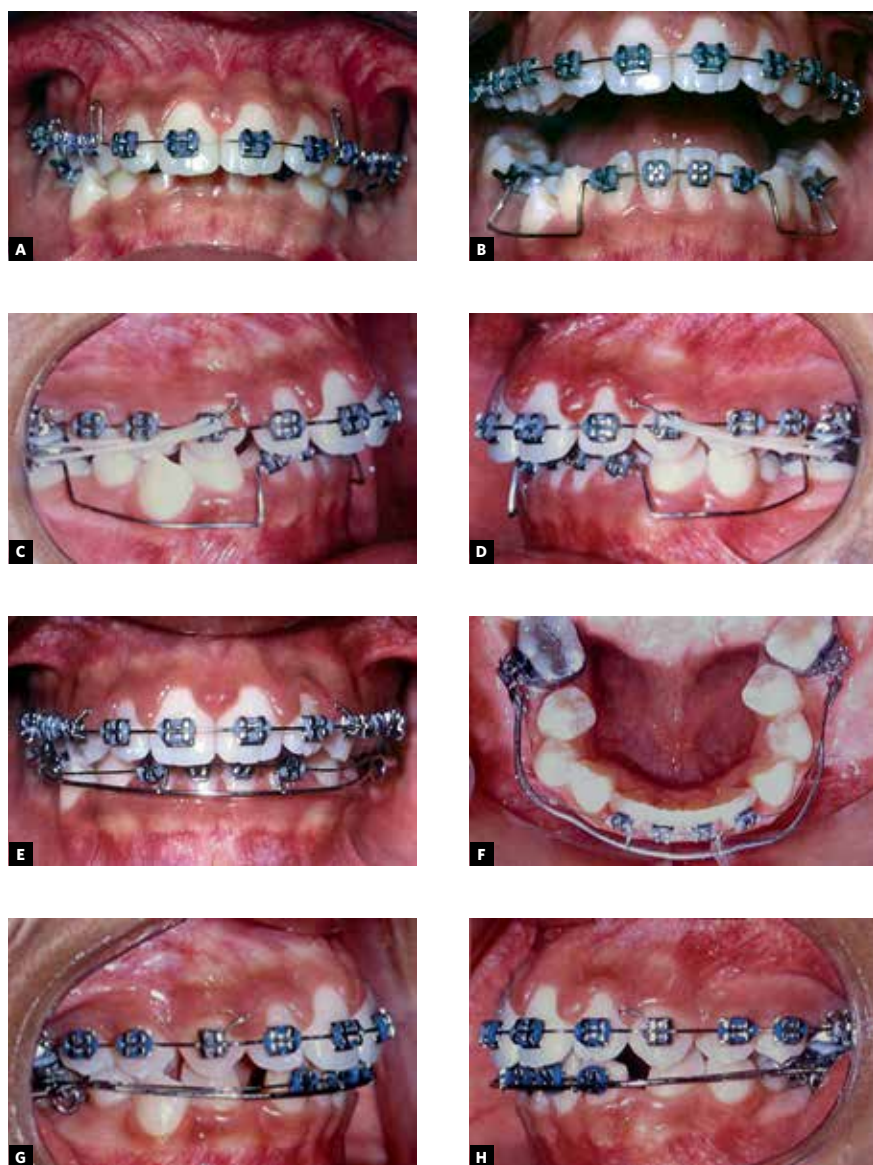
Treatment was initiated by instructing the patient on proper oral hygiene. A 0.022 x 0.028-in fixed Standard Edgewise appliance was placed on the upper arch. Thereafter, the upper arch was aligned and leveled with a 0.014-in Multiloop CrNi archwire and,

subsequently, a sequence of round 0.016-in, 0.018-in and 0.020-in CrNi wires with omega loop at a distance of 0.5 mm from the molar tube to tie-back archwire. In the retraction phase, a combined headgear (350 g of force) was used for anchorage purpose. The case was finished with 0.019 x 0.025-in CrNi archwire with ideal bends and torques.

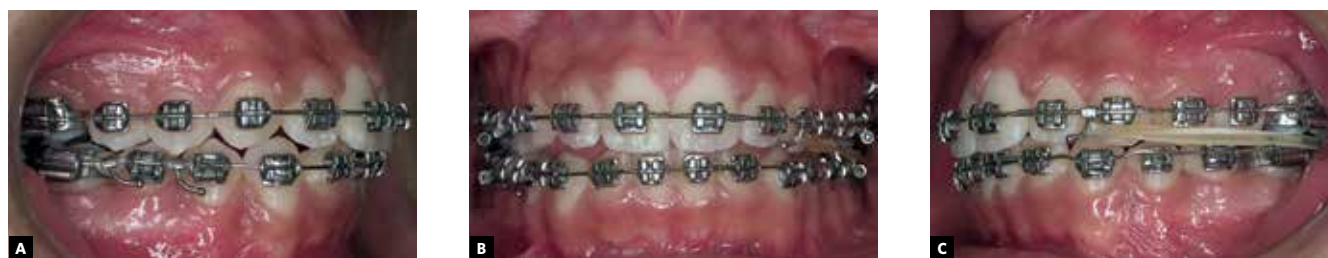Lingual arch was bonded to the mandibular arch and accessories inserted only on the first molars and incisors. Segmental alignment and leveling was performed on these teeth using a sequence of 0.014-in, 0.016-in, 0.018-in and 0.020-in CrNi wires, and subsequently, intrusion was achieved with Ricketts utility arch (RUA) (CrNi 0.019 x 0.025-in). Class II elastics were then used to prevent the RUA from inducing tip-back in the molars, which would yield greater anteroinferior protrusion (Figs 5A-D). After an adequate intrusion was achieved, an archwire with an omega loop beyond the molar tube was placed (increased length), thereby engaging the lower incisor protrusion, which was enhanced due to the placement of a labial arch tied to the anterior mandibular arch with steel ligatures (Figs 5E-H).

After ensuring an adequate protrusion in the lower incisors, space was created to align the canines and premolars, which were bonded and aligned with Multiloop 0.016-in CrNi wire. In view of improved overbite and overjet, alignment and leveling were continued in the lower arch using 0.018-in and 0.020-in straight wires. The case was finished using 0.019 x 0.025-in archwires with ideal bends and torques (Fig 6).





**Figure 5** - Treatment progress: **A**) Alignment and leveling of the upper dental arch with Multiloop archwires; **B**) intrusion of lower incisors with Ricketts utility arch; **C, D**) use of Class II mechanics with orthodontic elastics, enhancing the anterior inferior protrusion and controlling molar inclination; **E-H**) labial archwire as an aid in lower protrusion.



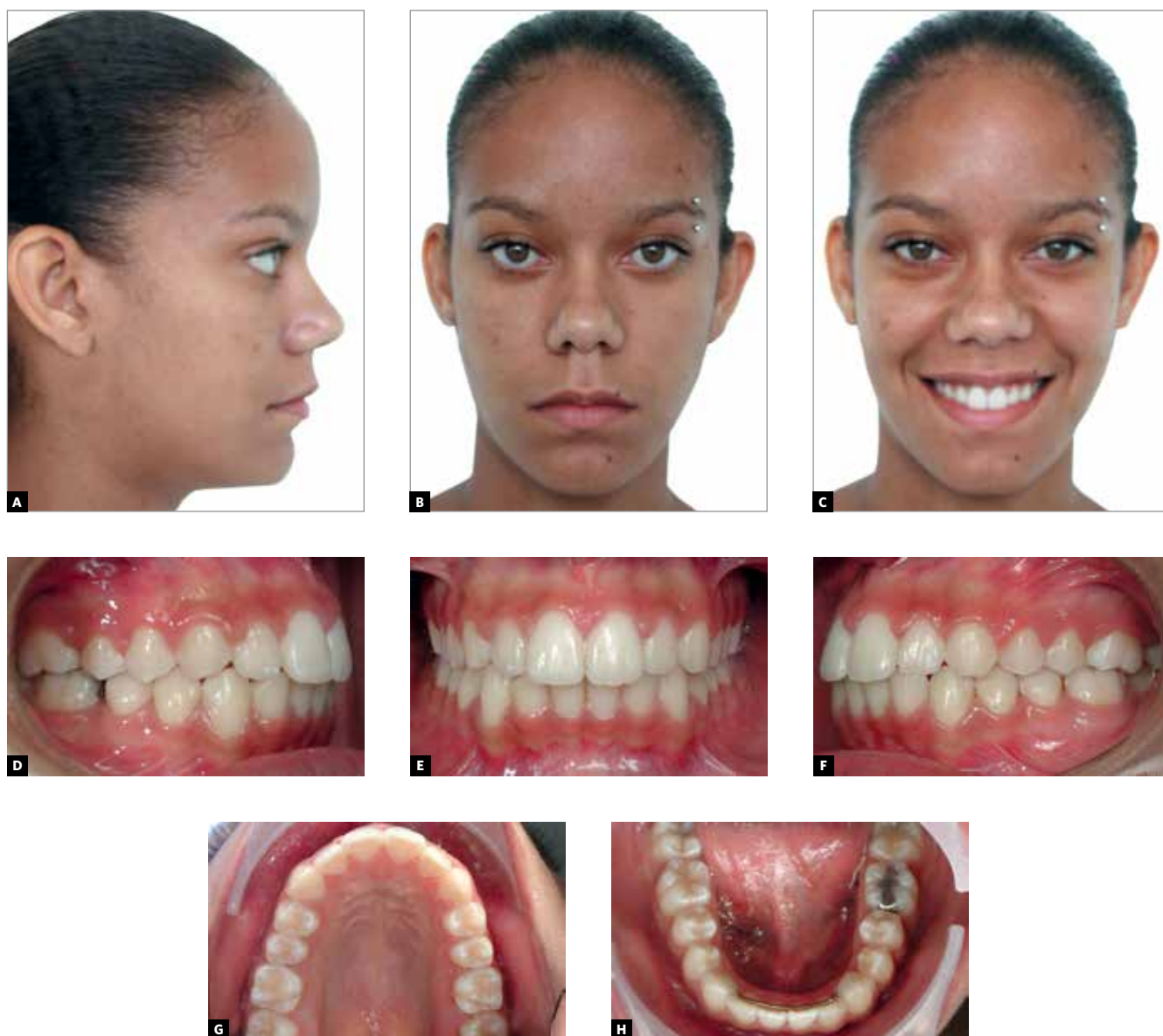
**Figure 6** - Finishing phase. Rectangular 0.019 x 0.025-in CrNi archwires with ideal bends and torques.

## RESULTS

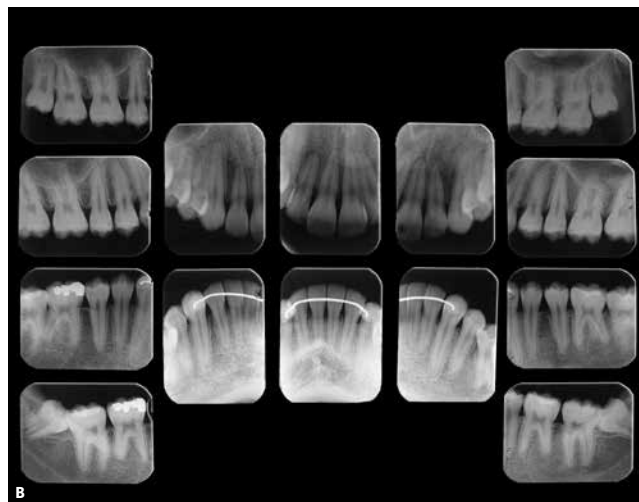
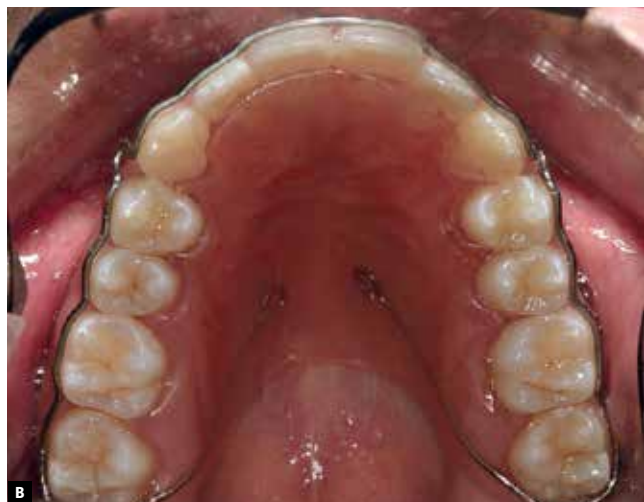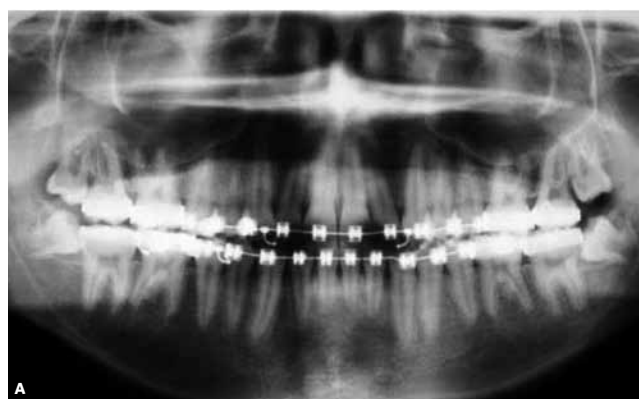
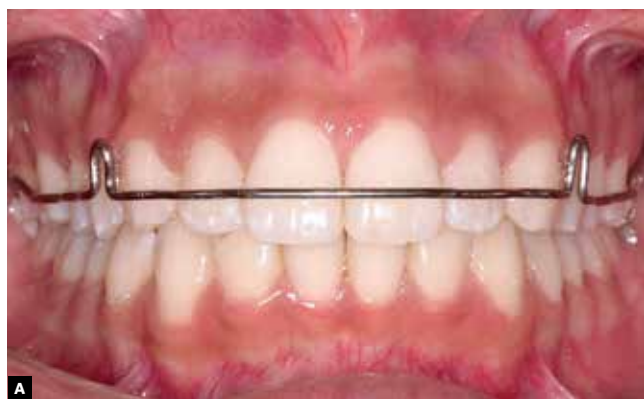At the end of treatment, a proper dental relationship was attained with normal molar and canine occlusions. The final photographs show considerable improvement in facial aesthetics. Facial features were improved, yielding a slightly convex profile with lip competence achieved through a slight retraction of the upper lip and lower lip protrusion while improving the nasolabial and mentolabial sulcus. The final evaluation of the dental arches showed that the lower negative discrepancy had been eliminated, normal overbite and overjet were achieved and the midline corrected. No impact was detected in either the stomatognathic function or the excursive

movements of the mandible. The periodontal tissue remained healthy and the temporomandibular joint (TMJ) function remained normal throughout the treatment period (Fig 7).

After removal of the fixed appliance, a lower lingual retainer was bonded across from tooth 33 to tooth 43, with the recommendation that it be kept in place indefinitely. In the upper arch, a removable wraparound retainer with passive anterior stop was placed and the patient was instructed to wear it 24/7 in the first few months, then eventually remove it at mealtime and for oral hygiene (Fig 8). The patient was seen at regular 3-month intervals to assess the stability of the occlusion and monitor the upper retainer.



**Figure 7** - Finished case. Posttreatment facial and intraoral photographs.

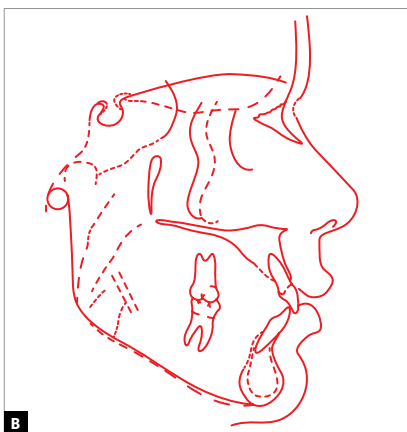
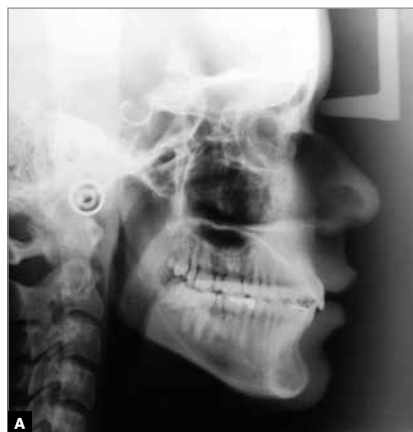

**Figure 8** - Finished case. Intraoral photographs showing the upper wrap-around retainer.

**Figure 9** - **A**) Panoramic radiograph of finished case, and **B**) post-treatment periapical radiographs.


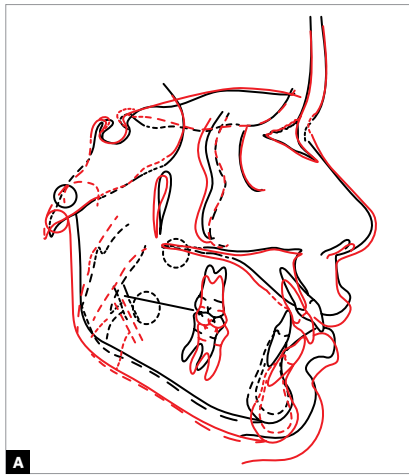
As can be observed in Figure 9, there was no significant root resorption, whereas some apical rounding can be seen in teeth 12 and 22. The post-treatment lateral cephalometric X-ray is shown in Figure 10. The total sphenoid/cribriform superimposition reveals increased vertical growth. In the partial

superimpositions one can notice the lower incisor protrusion, retroclination of the lower incisors, posterior alveolar growth, as suggested by a slight molar extrusion (Fig 11). Figure 12 depicts how occlusion stability and facial aesthetics were successfully maintained after 1 year and 3 months with the retainer in place.

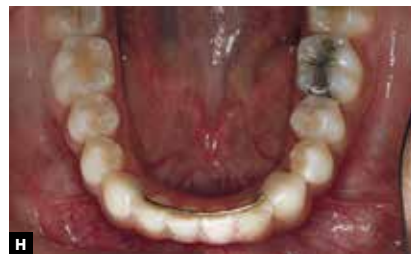
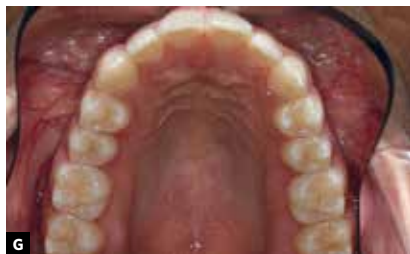
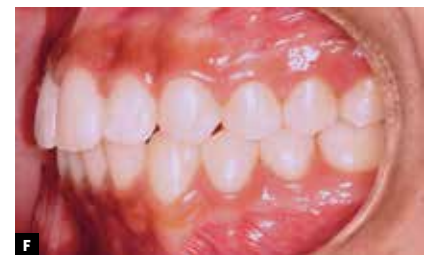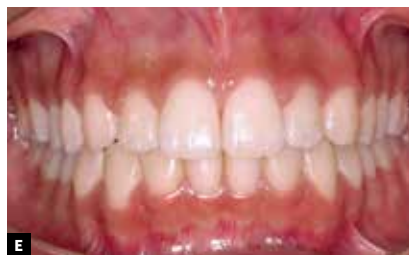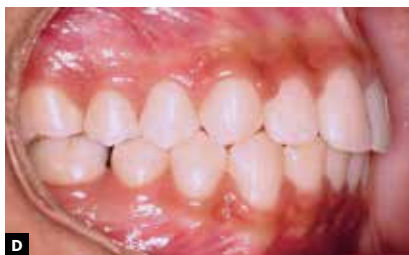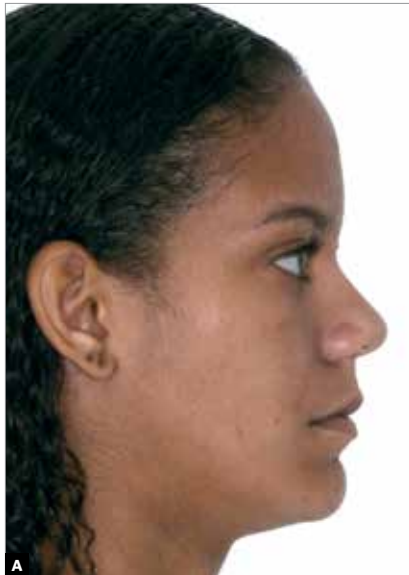**Figure 10** - Post-treatment lateral cephalometric radiograph and cephalometric tracing.





**Figure 11** - Total and partial superimpositions of maxillary and mandibular initial and final cephalometric tracings.



**Figure 12** - Facial and intraoral photographs after 1 year and 3 months retention.



The decision to treat this patient conservatively yielded excellent results. Any extraction could have caused undesirable dental retraction, thereby lessening the likelihood of improving facial aesthetics. More importantly, the treatment fulfilled the patient's actual needs while also meeting her parents' expectations. Besides, it satisfied the professionals who treated her.

## DISCUSSION

In an ideal female profile, the lips should be slightly everted towards their base, displaying several millimeters of vermilion border, and the upper lip should be positioned slightly anterior to the lower lip. The mentolabial sulcus must form an S-shaped curve in both the upper and lower portions. Furthermore, chin prominence should be slightly smaller than lower lip prominence.<sup>11</sup> In this patient, all these characteristics were adversely affected by increased overjet and lower lip interposition, which was adequately resolved by the treatment performed.

In this case, a combined headgear was used as anchorage for upper retraction, and also to control the vertical dimension. The latter was important because in dolichocephalic patients who present with deep overbite, despite a vertical skeletal pattern, reverse lower curve of Spee and an increased upper curve of Spee can lead to extrusion of posterior teeth, with consequent clockwise mandibular rotation, which might worsen the overjet.<sup>3,4,8</sup>

In most clinical conditions, according to studies by Little et al,<sup>5</sup> Shapiro,<sup>18</sup> and Thilander,<sup>20</sup> expanding the intercanine width may lead to a condition

of instability and quick relapse. However, in cases with anteroposterior balance of the basal bones and incompatible arch forms, where there is either collapse or retention of the lower arch, especially in the anterior region, one might question this assertion. One such example is the case presented in this study, characterized by lower negative discrepancy and reduced intercanine width. In this situation, one can perform not simply an expansion of the dental arches, but this distance can be corrected by adjusting the torques and tips in the lower teeth while adjusting the arch forms.

In the posttreatment phase, there was a 0.9 mm increase in intercanine width, and a 1.2 mm increase in the lower arch. The lower incisors were moved forward by 2 mm and inclined buccally by 6°. Thus, the crowding was corrected primarily by slightly expanding the anterior segments along with intrusion and proclination of the mandibular incisors, and slight retraction of the maxillary incisors. Expansion of the arches and protrusion of lower incisors no doubt have limited indication. When carefully planned, however, great results with lasting stability can be achieved.

## CONCLUSIONS

A conservative approach with no extractions proved effective and resulted in significant improvement in the occlusal relationship as well as in the patient's dental and facial aesthetics. The use of light, controlled forces and suitable torques greatly contributed to proper tooth positioning with minimal root resorption.

## REFERENCES

1. Angelle PL. A Cephalometric study of the soft tissue changes during and after orthodontic treatment. *Trans Eur Orthod Soc.* 1973;267-80.
2. Hershey HG. Incisor tooth retraction and subsequent profile change in post-adolescent female patients. *Am J Orthod.* 1972 Jan;61(1):45-54.
3. Houston WJ. Mandibular growth rotations: their mechanisms and importance. *Eur J Orthod.* 1988 Nov;10(4):369-73.
4. Levin RI. Deep bite treatment in relation to mandibular growth rotation. *Eur J Orthod.* 1991 Apr;13(2):86-94.
5. Little RM, Riedel RA, Stein A. Mandibular arch length increase during the mixed dentition: postretention evaluation of stability and relapse. *Am J Orthod Dentofacial Orthop.* 1990 May;97(5):393-404.
6. Marques LS, Barbosa CC, Ramos-Jorge, ML, Pordeus IA, Paiva SM. Prevalência da má oclusão e necessidade de tratamento ortodôntico em escolares de 10 a 14 anos de idade em Belo Horizonte, Minas Gerais, Brasil: enfoque psicossocial. *Cad Saúde Pública* 2005;21(4):1099-106.
7. Moreira TC, Quintão CCA, Menezes LM, Anamaria B. Comparação entre dois instrumentos para medição das distâncias intercaninos e intermolares. *Rev SBO* 1997;3(4):149-56.
8. Nanda SK. Growth patterns in subjects with long and short faces. *Am J Orthod Dentofacial Orthop.* 1990 Sep;98(3):247-58.
9. Pinto MR, Mottin LP, Derech CD, Araújo MTS. Extração de incisivo inferior: uma opção de tratamento. *Rev Dental Press Ortodon Ortop Facial.* 2006 Jan-Fev;11(1):114-21.
10. Proffit WR, Fields Junior HW. *Ortodontia Contemporânea.* 2a ed. Rio de Janeiro: Guanabara-Koogan, 1995. p. 596.
11. Proffit WR, White Junior RP, Sarver DM. Tratamento contemporâneo de deformidades dentofaciais. Porto Alegre (RS): Artmed; 2005.
12. Riedel RA. Review of the retention problem. *Angle Orthod.* 1960;30(4):179-99.
13. Riedel RA, Little RM, Bui TD. Mandibular incisor extraction: post retention evaluation of stability and relapse. *Angle Orthod.* 1992 Summer;62(2):103-16.
14. Roos N. Soft tissue profile changes in Class II treatment. *Am J Orthod.* 1977 Aug;72(2):165-75.
15. Ruellas ACO. O movimento distal de molares em oposição à projeção de incisivos e expansão do arco (casos de má oclusão de Classe I). [Dissertação]. Rio de Janeiro (RJ): Universidade Federal do Rio de Janeiro. Faculdade de Odontologia; 1995.
16. Ruellas ACO, Ruellas RMO, Romanoff FL, Pihoni MM, Santos RL. Extrações dentárias em Ortodontia: avaliação de elementos de diagnóstico. *Dental Press J Orthod.* 2010;15(3):134-57.
17. Shah AA, Elcock C, Brook AH. Incisor crown shape and crowding. *Am J Orthod Dentofacial Orthop.* 2003 May;123(5):562-7.
18. Shapiro PA. Mandibular dental arch form and dimension. *Am J Orthod.* 1974 Jul;66(1):58-70.
19. Strang R. The fallacy of denture expansion as a treatment procedure. *Angle Orthod.* 1949 Mar;19(1):12-22.
20. Thilander B. Biological basis for orthodontic relapse. *Semin Orthodont.* 2000 Sep;6(3):195-205.
21. Tweed CH. Indications for the extraction of teeth in orthodontic procedure. *Am J Orthod Oral Surg.* 1944-1945;42:22-45.
22. Wisth PJ. Soft tissue response to upper incisor retraction in boys. *Br J Orthod.* 1974 Oct;1(5):199-204.