



Horizontal and vertical maxillary osteotomy stability, in cleft lip and palate patients, using allogeneic bone graft

Kelston Ulbricht Gomes¹, Wilson Denis Benato Martins², Marina de Oliveira Ribas²

Objective: This study was carried out to evaluate maxillary stability after orthodontic-surgical treatment of patients with cleft lip and palate. Cephalometric analysis was applied to two different groups, with and without allogeneic bone graft. **Methods:** The sample comprised 48 patients with cleft lip and palate. The test group comprised 25 patients who, after correction of maxillary position, received allogeneic bone graft at the gap created by Le Fort I osteotomy. The control group comprised 23 patients and its surgical procedures were similar to those applied to the test group, except for the use of bone graft. Manual cephalometric analysis and comparison between lateral telerradiographs, obtained at the preoperative phase, immediate postoperative phase and after a minimum period of six months, were carried out. **Results:** A higher horizontal relapse was observed in the control group ($p < 0.05$). There were no statistically significant differences in vertical relapses between test and control groups ($p > 0.05$). **Conclusion:** The use of allogeneic bone graft in cleft lip and palate patients submitted to Le Fort I osteotomy contributed to increase postoperative stability when compared to surgeries without bone graft.

Keywords: Orthognathic surgery. Oral surgery. Bone grafting.

Objetivo: avaliar a estabilidade maxilar após o tratamento ortodôntico-cirúrgico de pacientes portadores de fissura labiopalatal, por meio de análise cefalométrica, em dois diferentes grupos, com e sem utilização de enxerto ósseo alógeno. **Métodos:** a amostra foi constituída de 48 pacientes portadores de fissura labiopalatal. O grupo teste foi composto de 25 pacientes que, após a correção da posição da maxila, receberam enxertia óssea alógena para preenchimento dos espaços gerados pelas osteotomias maxilares do tipo Le Fort I. O grupo controle foi composto por 23 pacientes, com os procedimentos cirúrgicos similares aos do grupo teste, com a diferença de que não se utilizou enxertia óssea. Realizaram-se traçados cefalométricos manuais e comparação entre as telerradiografias em perfil, obtidas no pré-operatório, no pós-operatório imediato e após o período mínimo de seis meses. **Resultados:** ocorreu maior recidiva horizontal no grupo controle ($p < 0,05$). Não houve diferenças estatisticamente significativas nas recidivas verticais entre os grupos teste e controle ($p > 0,05$). **Conclusão:** a utilização de enxertos alógenos em pacientes portadores de fissura labiopalatal submetidos a osteotomias maxilares Le Fort I contribuiu para o aumento da estabilidade horizontal pós-operatória, quando comparada com cirurgias sem enxertia óssea.

Palavras-chave: Cirurgia ortognática. Cirurgia bucal. Transplante ósseo.

¹PhD in Oral and Maxillofacial Surgery, Pontifical Catholic University of Paraná (PUC-PR).

²Professor of Dentistry at PUC-PR.

How to cite this article: Gomes KU, Martins WDB, Ribas MO. Horizontal and vertical maxillary osteotomy stability, in cleft lip and palate patients, using allogeneic bone graft. *Dental Press J Orthod.* 2013 Sept-Oct;18(5):84-90.

Submitted: January 16, 2012 - **Revised and accepted:** August 17, 2012

» The authors report no commercial, proprietary or financial interest in the products or companies described in this article.

Contact address: Kelston Ulbricht Gomes
Av. Silva Jardim, 2042 – Sala 1205 – Curitiba/PR, Brazil
CEP: 80250-200 – E-mail: kelstongomes@yahoo.com.br

INTRODUCTION

Cleft lip and palate deformities are amongst the most common congenital anomalies of the face.¹

Cleft lip and palate surgery as well as orthodontic treatment are amongst the therapeutic possibilities for recovering patients' esthetics and function. In patients with cleft lip and palate, some occlusal deleterious situations such as teeth crowding and unilateral crossbite with segments collapse, open bite on the affected side and retrusion of the maxilla, are identified.²⁻⁶

After the growth spurt, orthognathic surgery is indicated to correct skeletal and dental discrepancies in patients who present dentofacial deformity.

Hirano and Suzuki⁷ described potential aspects which are responsible for maxillary retrusion in adult cleft patients: Unfavorable muscular action due to scars caused by early surgeries in lip and palate, pharyngeal flaps and absence of teeth, which reduces occlusal stability.

The stability of orthognathic surgeries depends on the type and the extent of movements performed by the maxilla. Stability is considered difficult especially in patients with cleft lip and palate. Usually, these patients have undergone surgery in the soft and hard palate, which normally results in fibrosis, limiting the extent of both transverse and anteroposterior movements of the maxilla.⁸⁻¹²

In order to avoid relapses when treating dentofacial deformities in cleft patients, some authors suggest increasing the time of intermaxillary fixation during the postoperative phase, performing bimaxillary surgeries, using face masks with reverse traction of the maxilla and interpositioning bone grafts between the gaps created by maxillary advancement.^{13,14,15}

A successful correction of dentofacial deformities depends on effective stabilization and prompt union of the repositioned bone segments. When there is a large area of contact between the segments, safe and satisfactory bone union is expected. When the contact area is small, there may be instability, relapse or fibrous union (pseudoarthrosis) between segments. In such cases, grafts are recommended. Some authors^{16,17} suggest allogeneic bone graft in orthognathic surgery. However, in the aforementioned studies, allogeneic bone graft was performed in patients without cleft lip and palate.

The study of Precious,¹⁸ in 2007, concluded that scars on the upper lip and on the palate interfere with nose, lips, soft adjacent tissues and skeletal development.

When intervention is performed with bone graft and correction of nasolabial musculature at the age of five or six years old, a symmetric function is established, which improves facial development. The primary muscle surgery improves growth and decreases the chances of undergoing orthognathic surgery.¹⁹

Nique et al² have studied the use of allograft bone for alveolar reconstruction in unilateral cleft patients. The receptor area was radiographically observed for a period of 3 to 6 months. The allograft bone is an excellent alternative to repair alveolar cleft, its use brings significant benefits for the patient, eliminating the morbidity of a second surgical site.

Garrison et al¹⁹ evaluated twenty patients who were simultaneously submitted to both alveolar bone graft and Le Fort I osteotomy. The researchers evaluated the extent of maxilla relapse at the anteroposterior and vertical direction through lateral teleradiographs. They concluded that there was no significant change in the horizontal plan, however, in the vertical direction there was a great tendency to relapse. The intermaxillary fixation time lasted for eight weeks and mandibular fixation was used at the orbital rim and zygomatic crest. For the evaluation, cephalometry was adopted, the SN plan was traced and a perpendicular line was drawn from the Nasion. The researchers measured the distance from this line to point A in order to evaluate potential changes in the horizontal direction (anteroposterior). To determine the vertical movement, a line was drawn perpendicular to the SN up to the point A.

Another research, carried out by Heliovaara et al,²⁰ examined the causes of relapse through a retrospective analysis of 71 patients, 58 of which had unilateral and bilateral clefts. The mean advancement of the maxilla was 6.9 mm. Grafts were harvested from calvaria or mandible and there were used four miniplates for containing the maxilla as well as intermaxillary fixation which was kept during 6 weeks and maintained after releasing fixation with class III elastics. The researchers concluded that the type of cleft (unilateral or bilateral), the scars in the soft palate, muscle tension, adaptation and stability of bone segments are amongst the main causes of relapse in maxillary osteotomies. The occlusal stability is important to prevent relapses.

Hirano and Suzuki⁷ evaluated one group comprised of 14 patients with cleft palate only and other group comprised

of 11 patients with bilateral cleft lip and palate. The gaps created by Le Fort I osteotomy were filled with autogenous bone without applying intermaxillary fixation or surgical guide. Patients were evaluated through lateral telerradiographs and point A was used as the reference point. Patients were evaluated at pre- and immediate postoperative phases as well as one year after the surgery. The average relapse in the group with cleft palate only was 8.5% in the horizontal direction and 16.7% in the vertical direction. In the group with bilateral cleft, relapse was 9.4% horizontal, and 17.8% vertical. The authors suggest that the main factors for relapses are: the method used for fixating the osteotomized segments, neuromuscular adaptation, the extent of movement of the maxilla and previous orthodontic preparation.

Ianetti et al²¹ evaluated the use of bimaxillary surgeries for minimizing potential relapses in patients with cleft lip and palate. They highlight intense scarring and soft tissue tension as being responsible for relapse. To reduce the relapse, authors suggest overcorrection of the maxilla; however, they warn that major advances of the maxilla can result in velopharynx incompetence. These conclusions were based on the evaluation of 15 patients who underwent combined bimaxillary surgery. In order to improve the stability of the maxilla, the authors suggest performing bone graft in the space created by Le Fort I osteotomy, with the indicated use of intermaxillary elastics for three weeks and the surgical guide being removed after six weeks. The stability evaluation was carried out by means of lateral telerradiographs, taken at the preoperative phase, six weeks, a year and two years after the surgery. The references were point A, the posterior nasal spine and point B. For cases in which only the maxilla was operated, relapse was of 25%, and in cases of maxillary and mandibular osteotomy, relapse was of 8%.²¹

In another study, conducted by Erbe et al,²² cephalometric analysis was performed during immediate and late postoperative phases (39-110 months) for patients simultaneously undergoing both Le Fort I osteotomies for advancement and autogenous alveolar bone graft. Operative changes in the position of the maxilla were evaluated in vertical and horizontal directions. All parameters used in the cephalometric measurements were manually measured by one single examiner as an attempt to eliminate observer bias. Some reference points were difficult to identify; however, the careful observation of a series of lateral films of the head increased accuracy and the identification of reference points was made possible.

Even with surgical correction of the maxilla, some degree of relapse is expected due to the aforementioned shortcomings and peculiarities (previous surgery on the palate and lack of occlusal stability by the absence of teeth). Bone grafting performed in the space created by both osteotomy and correction of the position of the maxilla can reduce the occurrence of relapse.

Thus, the objective of this study was to evaluate horizontal and vertical stability of maxillary osteotomy using allogeneic bone graft in patients with cleft lip and palate.

MATERIAL AND METHODS

The stability of orthodontic-surgical treatment of patients with cleft lip and palate was evaluated through cephalometric analysis in two different groups, one with and another without the use of allogeneic bone graft.

The study was approved by the local Institutional Review Board under the number 0003716/10.

Material

The sample consisted of 48 patients with cleft lip and palate, submitted to surgery at the Assistance Center for Cleft Lip and Palate (CAIF) in Curitiba, Paraná, Brazil, from January 2006 to March 2009.

All patients underwent orthognathic maxillary surgery, performed with the Le Fort I technique, with rigid internal fixation and intermaxillary fixation lasting for an average of 4 (four) weeks. The test group (TG) consisted of 25 patients of both genders with unilateral and bilateral clefts, with an average age of 23.16 years. The surgeries were isolated in the maxilla or combined with mandibular surgeries. After the maxilla had been repositioned, allogeneic bone graft, from the Bank of Muscle and Bone Tissue of the Clinical Hospital from Federal University of Paraná, was inserted to fill the gaps created by the osteotomies.

The control group (CG) consisted of 23 patients of both genders with cleft lip and palate, unilateral and bilateral types, with an average age of 25.78 years. Surgical procedures were similar to those applied to the TG, except for the use of bone graft. In the selection of patients, those with cleft lip and palate who underwent orthognathic surgery from January 2006 to March 2009, of both sexes and aged above 18 years were included. Patients submitted to orthognathic surgery only in the mandible, as well as those who had undergone more than one orthognathic surgery were excluded. Patients who did not performed alveolar bone graft in childhood were also excluded.

Methods

a) A blind study in which manual cephalometric analysis of the lateral telerradiographs was carried out by one single examiner. Radiographs were obtained at the preoperative phase, immediate postoperative phase and after a minimum period of six months.

b) The records as well as the cephalometric analysis were carried out using advocated parameters and measures.^{19,23} The anteroposterior position of the maxilla was determined by drawing the SN plane and a perpendicular line in relation to it, from the Nasion (Na) point. The distance from this line to point A was measured, determining the anteroposterior preoperative maxilla position which was compared to the postoperative position, over time (h) (Fig 1).

c) A perpendicular line was drawn from the SN plane towards point A in order to determine the preoperative vertical position of the maxilla which was compared to the postoperative position, over time (v) (Fig 1).

d) Having such reference points as guides, the maxillary tracing in the preoperative radiograph was superimposed over the first postoperative (immediate) radiograph. Tracings were repeated, resulting in horizontal and vertical linear values which correspond to the amount of movement obtained with surgery.

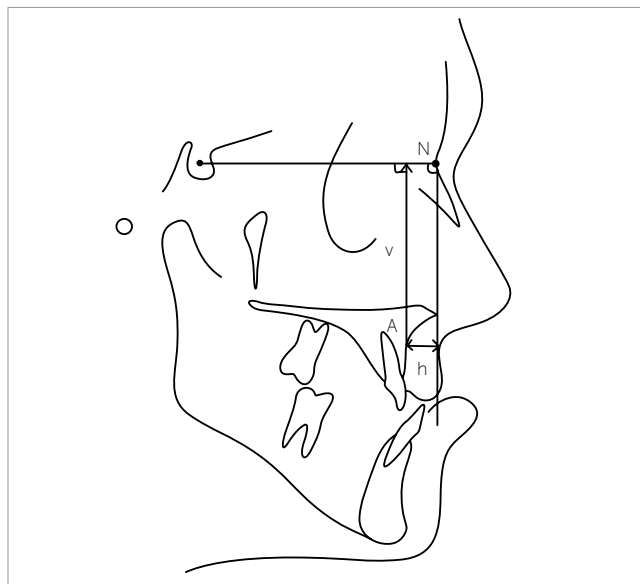


Figure 1 - Cephalometric tracings: reference lines and points used for evaluating postoperative results. S= Sella; N= Nasion; A= Point A; h= horizontal measurement; v= vertical measurement (Adapted from: Garrison et al¹⁹).

e) With a new radiograph obtained afterwards, at least 6 months after the first one, the process of comparison was repeated by means of superimposing the tracings. At this time, the immediate postoperative radiograph was used and the values for assessing the occurrence of relapse were obtained.

f) The purpose of these measurements was to linearly measure possible vertical and horizontal postoperative changes, over time, and relate them to the use of bone grafts.

RESULTS

Both groups (CG and TG) presented normal distribution with regard to the following variables: horizontal advancement, horizontal relapse, vertical movement and vertical relapse. The average horizontal advancement was similar in both groups. The average vertical movement was higher in TG than in CG (Table 1).

Horizontal relapse was higher in CG ($p < 0.05$). There were no statistically significant differences in vertical relapses between TG and CG ($p > 0.05$) (Tables 2 and 3).

Variables such as gender, type of procedure and type of cleft did not influence the stability of the surgery in any group ($p > 0.05$) (Figs 2, 3 and 4).

The CG had a follow-up period longer than the TG. However, despite this difference, there is no correlation between this variable and horizontal or vertical relapses (Pearson Correlation Coefficient $p > 0.05$). (Table 4; Figs 5 and 6).

By using Pearson Correlation Coefficient it was obtained a p -value > 0.05 , indicating that there is no correlation between the two variables. Therefore, despite the follow-up time of the group with graft was smaller than in the group with no graft, there was no correlation between this variable and relapse, both horizontal and vertical.

Table 1 - Descriptive statistics of variables according to each group.

Variable	Group	n	Mean \pm SD	Median
Horizontal advancement (mm)	Without bone graft	23	5.52 \pm 2.25	6.00
	With bone graft	25	5.44 \pm 2.36	6.00
Horizontal relapse (mm)	Without bone graft	23	-1.09 \pm 1.12	-1.00
	With bone graft	25	-0.36 \pm 0.95	0.00
Vertical movement (mm)	Without bone graft	23	1.61 \pm 2.76	2.00
	With bone graft	25	4.00 \pm 3.54	3.00
Vertical relapse (mm)	Without bone graft	23	-0.30 \pm 1.29	0.00
	With bone graft	25	-0.88 \pm 1.48	0.00

Table 2 - Student's t-test carried out in order to assess whether the mean horizontal and vertical relapses are different from zero in the group without bone graft.

Group without bone graft		
Variable	n	Mean ± SD
Horizontal relapse (mm)	23	-1.087 ± 1.124
Vertical relapse (mm)	23	-0.304 ± 1.294

One-sample test Test value = 0			
Variable	T	D.F.	p-value
Horizontal relapse (mm)	-4.635	22	0.0001
Vertical relapse (mm)	-1.127	22	0.271

P-value < 0.05 indicates that the variable mean is different from zero.

Table 3 - Student's t-test carried out in order to assess whether the mean horizontal and vertical relapses are different from zero in the group with bone graft.

Group with bone graft		
Variable	n	Mean ± SD
Horizontal relapse (mm)	25	-0.360 ± 0.952
Vertical relapse (mm)	25	-0.880 ± 1.481

One-sample test Test value = 0			
Variable	T	D.F.	p-value
Horizontal relapse (mm)	-1.890	24	0.070
Vertical relapse (mm)	-2.970	24	0.006

P-value < 0.05 indicates that the variable mean is different from zero.

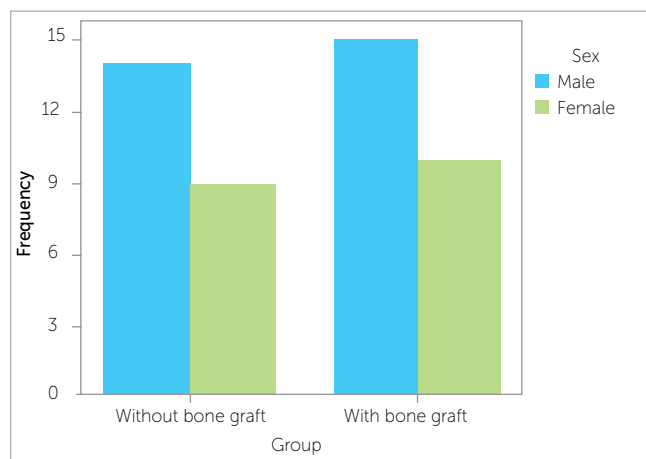

Figure 2 - Distribution frequency according to the variable sex.

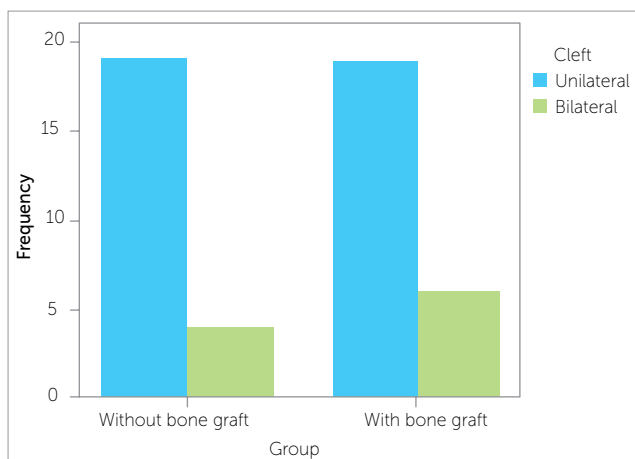


Figure 3 - Distribution frequency according to the variable type of cleft.

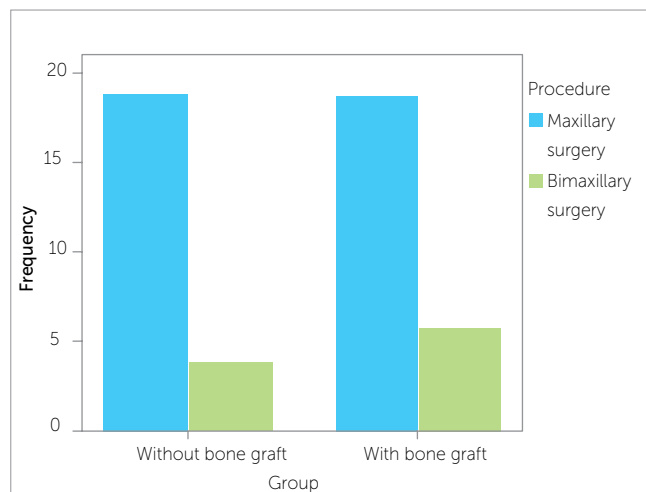


Figure 4 - Distribution frequency according to the variable type of procedure.

DISCUSSION

The authors agree with the literature regarding the instability of orthognathic surgery in patients with cleft lip and palate. The cause of instability is attributed to some variables such as several previous surgeries, fibrous tissue resulted from previous procedures, changes in dentition and muscle balance. At the same time, for non-cleft patients, stability and predictability in orthognathic surgery usually vary depending on the direction and magnitude of the surgical procedures, generally in that order of importance.^{9,10}

The literature indicates a significant trend towards a higher number of postoperative relapses in cleft patients than in patients with non-cleft maxillary hypoplasia who underwent orthognathic surgery.^{9,14}

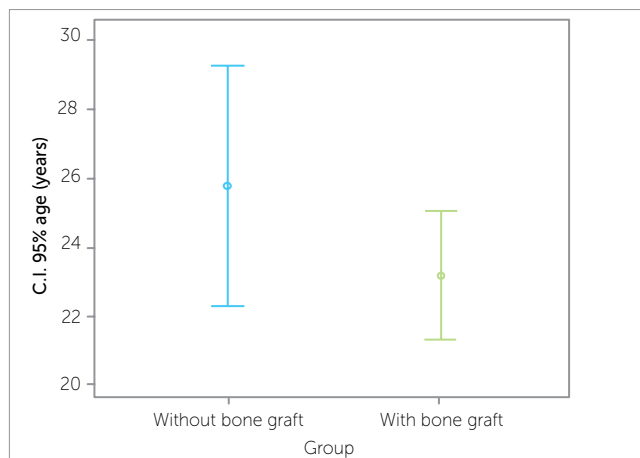


Figure 5 - Confidence interval with regard to age in each group.

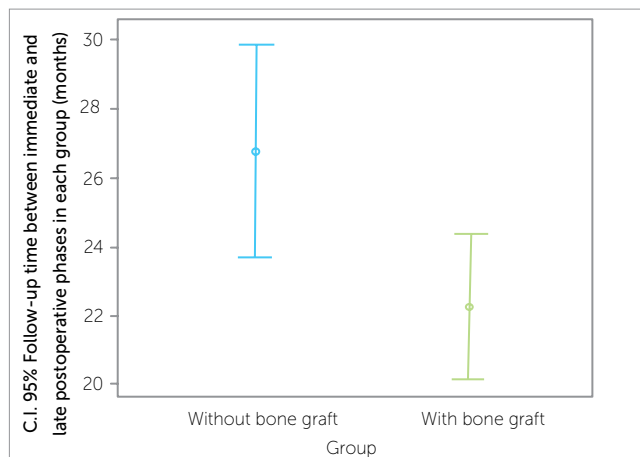


Figure 6 - Confidence interval with regard to postoperative follow-up period in each group.

Table 4 - Descriptive statistics of variables.

Variable	Group	n	Mean \pm SD	Median
Age (years)	Without bone graft	23	25.78 \pm 8.11	23.00
	With bone graft	25	23.16 \pm 4.66	23.00
Follow-up time between immediate and late postoperative phases	Without bone graft	23	24.87 \pm 11.37	23.00
	With bone graft	25	17.68 \pm 8.38	17.00

Some authors suggested that to improve stability, a better, more effective and rapid healing should be provided by means of performing bone grafts adapted in the gaps created by the correction of the maxilla.^{16,17} To evaluate the effectiveness of the grafting procedure, the authors proposed a study carried out by means of cephalometric analysis of patients undergoing orthognathic surgery.

Additionally, taking into account the benefits observed with the use of allogenic bone graft, the authors included in the study patients who had allogenic graft-type only, since it is known that allogenic bone grafting offers several advantages such as easy handling, great amount of available material, cost reduction and, especially, decrease in patient's postoperative morbidity. Nique et al² studied the use of allograft in patients with alveolar defects and cleft lip and palate, obtaining good results for bone integration. Other authors have also had good results concerning allograft bone grafting in orthognathic surgery for non-cleft patients.^{16,17}

As for the methods, the authors used those already described in the literature, for instance, radiographic evaluation by means of cephalometric analysis performed at three different stages (preoperative, immediate postoperative and late postoperative).^{7,19-22} As shown in the studies of Erbe et al²² and Iannetti et al,²¹ these methods demonstrated to be efficient, since they were manually performed by one single and trained examiner.

After applying the methodology, the results showed more horizontal relapse in the CG (without graft) than the observed in the TG (with grafting), i.e., more stability was obtained with the use of grafts. This fact was also observed by Hirano and Suzuki;⁷ however, in their study, relapses occurred both horizontally and vertically and the only different approach was the use of autogenous bone graft to fill the gaps created by osteotomies, which may suggest the formation of an autograft mechanical barrier that is less efficient to restrict the movements of relapse.

At last, the present results corroborate the studies of Heliovaara et al²⁰ and Iannetti et al,²¹ demonstrating the positive effects of performing bone grafting in order to minimize relapses in orthognathic surgery for cleft patients.

CONCLUSIONS

The use of allogenic grafts in cleft patients undergoing Le Fort I maxillary osteotomy contributes to increase postoperative stability when compared to surgeries without bone grafting.

REFERENCES

1. Ankola AV, Nagesh L, Hegde P, Karibasappa GN. Primary dentition status and treatment needs of children with cleft lip and/or palate. *J Indian Soc Pedod Prev Dent.* 2005;23(2):80-82.
2. Nique T, Fonseca RJ, Upton LG, Scott R. Particulate allogeneic bone grafts into maxillary alveolar clefts in humans: a preliminary report. *J Oral Maxillofac Surg.* 1987;45(5):386-92.
3. Spina Veia. Classificação das fissuras lábio-palatinas. Sugestão de modificação. *Rev Hosp Clin Fac Med São Paulo.* 1972;27(1):5-7.
4. Bill J, Proff P, Bayerlein T, Weingaertner J, Fanghanel J, Reuther J. Treatment of patients with cleft lip, alveolus and palate: a short outline of history and current interdisciplinary treatment approaches. *J Craniomaxillofac Surg.* 2006;34 Suppl 2:17-21.
5. Schultes G, Gaggli A, Karcher H. Comparison of periodontal disease in patients with clefts of palate and patients with unilateral clefts of lip, palate, and alveolus. *Cleft Palate Craniofac J.* 1999;36(4):322-7.
6. Dahllof G, Ussisoo-Joandi R, Ideberg M, Modeer T. Caries, gingivitis, and dental abnormalities in preschool children with cleft lip and/or palate. *Cleft Palate J.* 1989;26(3):233-7; discussion 37-8.
7. Hirano A, Suzuki H. Factors related to relapse after Le Fort I maxillary advancement osteotomy in patients with cleft lip and palate. *Cleft Palate Craniofac J.* 2001;38(1):1-10.
8. Bailey LJ, Cevitanes LH, Proffit WR. Stability and predictability of orthognathic surgery. *Am J Orthod Dentofacial Orthop.* 2004;126(3):273-7.
9. Kerawala CJ, Stassen LF, Shaw IA. Influence of routine bone grafting on the stability of the non-cleft Le Fort I osteotomy. *Br J Oral Maxillofac Surg.* 2001;39(6):434-8.
10. Ayliffe PR, Banks P, Martin IC. Stability of the Le Fort I osteotomy in patients with cleft lip and palate. *Int J Oral Maxillofac Surg.* 1995;24(3):201-7.
11. Bishara SE, Chu GW, Jakobsen JR. Stability of the LeFort I one-piece maxillary osteotomy. *Am J Orthod Dentofacial Orthop.* 1988;94(3):184-200.
12. Proffit WR, Phillips C, Turvey TA. Stability following superior repositioning of the maxilla by LeFort I osteotomy. *Am J Orthod Dentofacial Orthop.* 1987;92(2):151-61.
13. Steinberg B, Padwa BL, Boyne P, Kaban L. State of the art in oral and maxillofacial surgery: treatment of maxillary hypoplasia and anterior palatal and alveolar clefts. *Cleft Palate Craniofac J.* 1999;36(4):283-91.
14. De Riu G, Meloni SM, Raho MT, Gobbi R, Tullio A. Delayed iliac abscess as an unusual complication of an iliac bone graft in an orthognathic case. *Int J Oral Maxillofac Surg.* 2008;37(12):1156-8.
15. Bothur S, Blomqvist JE, Isaksson S. Stability of Le Fort I osteotomy with advancement: a comparison of single maxillary surgery and a two-jaw procedure. *J Oral Maxillofac Surg.* 1998;56(9):1029-33; discussion 33-4.
16. Christian JM, Peterson LJ. Frozen femoral head allogeneic bone grafts for orthognathic surgery. *J Oral Maxillofac Surg.* 1982;40(10):635-9.
17. Scheffer P, Blanchard P, Attar A, Assa A. Cryopreserved allografts in orthognathic surgery]. *Rev Stomatol Chir Maxillofac.* 1988;89(4):220-8.
18. Precious DS. Treatment of retruded maxilla in cleft lip and palate: orthognathic surgery versus distraction osteogenesis: the case for orthognathic surgery. *J Oral Maxillofac Surg.* 2007;65(4):758-61.
19. Garrison BT, Lapp TH, Bussard DA. The stability of Le Fort I maxillary osteotomies in patients with simultaneous alveolar cleft bone grafts. *J Oral Maxillofac Surg.* 1987;45(9):761-65.
20. Heliövaara A, Ranta R, Hukki J, Rintala A. Skeletal stability of Le Fort I osteotomy in patients with isolated cleft palate and bilateral cleft lip and palate. *Int J Oral Maxillofac Surg.* 2002;31(4):358-63.
21. Iannetti G, Cascone P, Saltarel A, Ettaro G. Le Fort I in cleft patients: 20 years' experience. *J Craniofac Surg.* 2004;15(4):662-9.
22. Erbe M, Stoelinga PJ, Leenen RJ. Long-term results of segmental repositioning of the maxilla in cleft palate patients without previously grafted alveolo-palatal clefts. *J Craniomaxillofac Surg.* 1996;24(2):109-17.
23. Louis PJ, Waite PD, Austin RB. Long-term skeletal stability after rigid fixation of Le Fort I osteotomies with advancements. *Int J Oral Maxillofac Surg.* 1993;22(2):82-6.