

Cephalometric analysis of the upper airways of Class III patients subjected to orthosurgical treatment

Camila Gornic*, Paula Paiva do Nascimento**, Camilo Aquino Melgaço***, Antonio Carlos de O. Ruellas****, Paulo José D'Albuquerque Medeiros*****, Eduardo Franzotti Sant'Anna*****

Abstract

Objective: The aim of this study was to evaluate the effects of orthognathic surgery for mandibular setback – with and without combined maxillary surgery – on the upper airways (UA). **Methods:** Immediate lateral preoperative and postoperative cephalometric radiographs of 17 Class III patients were evaluated. Measurements of airway space (AS) diameter were taken in the sagittal plane in the hypopharyngeal and oropharyngeal regions, and changes in hyoid bone position were also recorded. Paired t-test and Pearson's coefficient were applied seeking for potential associations between skeletal and AS changes. **Results:** Significant AS reduction was noted in the hypopharyngeal region (mean= 3.10 mm, $p= 0.024$). The hyoid bone was displaced inferiorly and posteriorly, thereby reducing its distance to the anterior mandibular region. No quantitative correlation could be established between anteroposterior AS reduction and mandibular setback. However, there was a strong correlation between initial AS diameter and the amount of reduction observed in the hypopharynx, but only moderate correlation with the oropharynx. **Conclusions:** Mandibular setback can cause significant UA narrowing, especially in the inferior-most portion (hypopharynx). Therefore, special attention should be given to UA evaluation when formulating an orthosurgical treatment plan since the potential deleterious effects of these changes on functions of the patients should not be overlooked.

Keywords: Orthognathic surgery. Mandibular setback. Airways. Oropharynx. Hypopharynx.

INTRODUCTION

The upper airway (UA) – whose major component is the pharynx – consists of a tube that extends from the nostrils to the larynx (glottis).

This structure can be didactically divided into: Nasopharynx (superior-most region, related to the choanae), velopharynx (posterior region of the uvula), oropharynx (base of tongue) and

How to cite this article: Gornic C, Nascimento PP, Melgaço CA, Ruellas ACO, Medeiros PJD, Sant'Anna EF. Cephalometric analysis of the upper airways of Class III patients subjected to orthosurgical treatment. *Dental Press J Orthod.* 2011 Sept-Oct;16(5):82-8.

» The authors report no commercial, proprietary, or financial interest in the products or companies described in this article.

* Graduate, School of Dentistry – Federal University of Rio de Janeiro (UFRJ).

** MSc student in Orthodontics, Department of Pediatric Dentistry and Orthodontics, School of Dentistry - UFRJ.

*** MSc in Orthodontics and PhD student, Department of Pediatric Dentistry and Orthodontics, School of Dentistry - UFRJ.

**** PhD in Orthodontics and Adjunct Professor, Department of Pediatric Dentistry and Orthodontics, School of Dentistry - UFRJ.

***** PhD in Dentistry, UFRJ. Head Professor of Surgery, School of Dentistry - UERJ.

***** PhD in Orthodontics, School of Dentistry - UFRJ. Adjunct Professor, Department of Pediatric Dentistry and Orthodontics, School of Dentistry - UFRJ.

hypopharynx (inferior-most region, posterior to the hyoid bone). The UA walls consist only of soft tissue and, therefore, is not supported by any rigid structure such as bone or cartilage. Thus, the mechanical support that ensures the continued opening of this structure in opposition to negative pressure during inhalation movements results from tension and contraction of the muscles that surround it.¹¹ This mechanism is due in large part to muscular insertions in the genial tubercles, which enable the mandible to be closely involved in the function and support of the tongue and related soft tissues. The genioglossus, geniohyoid and infrahyoid muscles are linked to the oropharynx and hypopharynx. The tongue muscles play an important role in maintaining airway opening, since they form the anterior wall of the pharynx in that segment.

Several procedures have been developed in the hope of increasing the pharyngeal airway space in patients with obstructive sleep apnea syndrome (OSAS). The goal would be to pull the tongue muscles anteriorly through mandibular advancement, thereby decreasing airway resistance to enhance air flow efficiency.¹⁴

On the other hand, one might question whether the opposite procedure, i.e., mandibular setback, could cause any reduction in pharyngeal airway space. This is a pertinent question since mandibular setback surgical technique is widely used in the treatment of Class III dentofacial deformities.

The effects of orthognathic surgery on the airways of healthy patients have not been fully explained in the literature, especially with regard to the risk of these patients developing OSAS in the postoperative period.

The purpose of this study was to assess and quantify, by means of cephalometric analysis, changes in the airways caused by orthognathic surgery involving mandibular setback, more specifically in regions directly related to the mandible, corresponding to the oropharynx and hypopharynx.

MATERIAL AND METHODS

Sample

Seventeen patients who had been subjected to orthodontic treatment in preparation for surgical correction of Class III dentoskeletal deformities were selected for this study. The surgeries were performed in the Department of Oromaxillofacial Surgery of the Pedro Ernesto State Hospital in 2006.

Six adult men and 11 adult women whose maxillofacial growth had already ceased were evaluated.

Surgical technique

Among the patients, 14 underwent combined orthognathic surgery for maxillary advancement and mandibular setback, whilst the remaining patients (3) were subjected to mandibular setback only. The surgical technique consisted of Le Fort I type maxillary osteotomy with rigid internal fixation. In performing mandibular setback, the technique of choice was bilateral vertical osteotomy with maxillomandibular fixation for a period of 2 to 3 weeks depending on the degree of occlusal stability.

Cephalometric analysis

Preoperative lateral cephalometric X-rays obtained up to 7 months prior to surgery as well as immediate postoperative radiographs taken up to one week after surgery were evaluated. Pre- and postoperative radiographs were obtained using the same device and in accordance with the standards of the lateral cephalometric technique.

All cephalograms were traced on acetate paper and all measurements were performed by the same examiner. Upper airway references were obtained according to the methodology advanced by Froberg et al,³ which can be seen in Figure 1.

Soft tissue measurements

1) Diameter of oropharyngeal airway (dark blue): Distance between the points determined by the intersection between the plane that extends from point B (the deepest point on the outer contour

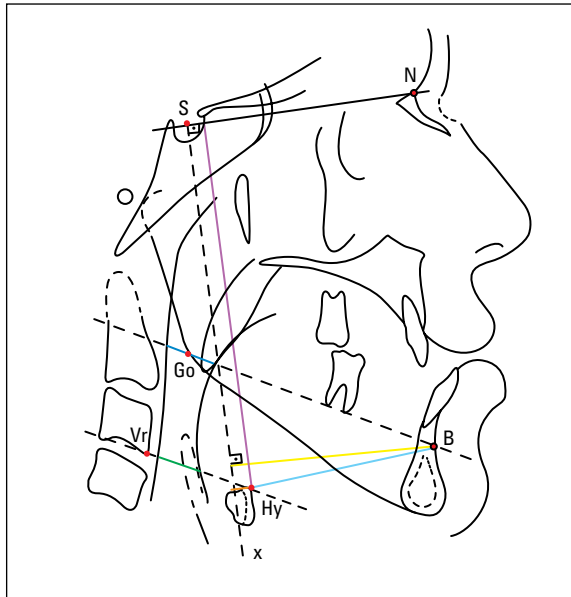


FIGURE 1 - Cephalometric landmarks.

of the mandibular alveolar process) to the gonion (Go - point determined by the intersection of the bisector of the angle formed by the lines tangent to the posterior and inferior borders of the mandible and the gonial angle), and the anterior and posterior walls of the pharynx. This measure intends to quantify the changes undergone by the oropharynx after surgery. Point B was selected as a reference as it constitutes the principal region of muscle insertion in the mandible, i.e., the genial tubercles.

2) Airway diameter in the hypopharynx region (green): Distance between the points defined by the intersection between the line extending from the most superoanterior point of the hyoid bone to the most anteroinferior point of the third cervical vertebra, and the anterior and posterior walls of the pharynx. This measure aims at quantifying the changes undergone by the hypopharynx after surgery.

Additional measures

3) Mandibular position (yellow): Measures the shortest distance between point B and a line perpendicular to SN (sella-nasion) passing through S (here called x). This measure discloses the amount of mandibular setback achieved through surgery.

4) SNA - Angle formed by the SN and NA lines (nasion-point A), where A is the deepest point on the contour of the premaxilla, which determines the degree of maxillary retrusion relative to the cranial base.

5) SNB - Angle formed between the SN and NB lines (nasion-point B), which expresses the degree of mandibular protrusion relative to the cranial base.

6) GoGn-SN - Angle determined by the intersection between the line joining the gonial (Go) and gnathion (Gn) points, and the SN line.

7) FMA - Angle determined by the intersection of the mandibular plane (line passing through the menton (Me) and tangent to the lower border of the mandible in the region of the gonial angle), with the Frankfort horizontal plane (junction of the Porium, Po, and orbitale, Or, points).

These last two angular measures (GoGn-SN and FMA) help to diagnose potential mandibular rotations in the vertical direction that can result from surgery, consequently inducing changes in the oropharyngeal reference plane.

8) Hy-SN (purple), the smallest distance between the most anterosuperior point on the body of the hyoid bone (Hy) and the SN line, revealing the vertical position of the hyoid bone relative to the cranial base.

9) Hy-x (orange), the smallest distance between Hy and line x, enabling the evaluation of the antero-posterior position of the hyoid bone.

10) Hy-B (light blue), distance between the Hy and point B, reflecting the relationship between the hyoid bone and the anterior region of the mandibular body.

RESULTS

Data were collected from the patients and all variables were used in the cephalometric analysis. Descriptive analysis including mean, standard deviation and minimum and maximum values measured on the preoperative and postoperative radiographs as well as the paired t-test are shown in Table 1. Some variables were compared with the purpose of establishing correlations between them, using Pearson's correlation coefficient (Table 2).

TABLE 1 - Descriptive statistics of cephalometric variables obtained from preoperative (T1) and postoperative (T2) radiographs.

Variable	X-ray	N	Mean	Standard Deviation	Minimum	Maximum				
SNA	T1	17	83.7647	3.56685	3.56685	89.50				
	T2	17	85.4412	3.96422	3.96422	91.00				
SNB	T1	17	86.2059	4.63026	4.63026	94.00				
	T2	17	82.1765	4.79890	4.79890	94.00				
ANB	T1	17	-2.4412	2.07577	2.07577	1.00				
	T2	17	3.2647	3.52277	3.52277	9.00				
GoGn-SN	T1	17	35.5882	5.70426	5.70426	46.00				
	T2	17	37.0882	6.17767	6.17767	55.00				
FMA	T1	17	26.6176	6.54916	6.54916	42.00				
	T2	17	28.8824	7.94223	7.94223	53.00				
Mandibular Position	T1	17	64.2647	7.47938	7.47938	76.00				
	T2	17	56.9412	7.70528	7.70528	71.00	X-ray 1	X-ray 2	t-test	p-value
Oropharyngeal Diameter	T1	17	16.8824	4.85583	4.85583	28.00	16.8824	15.9118	0.682	0.505
	T2	17	15.9118	5.29515	5.29515	25.00				
Hypopharyngeal Diameter	T1	17	13.0588	6.40772	6.40772	28.00	13.0588	9.6471	2.477	0.025*
	T2	17	9.6471	4.50959	4.50959	23.00				
Hy-SN	T1	17	113.0882	8.26747	8.26747	127.00	113.0882	117.3529	-3.707	0.002**
	T2	17	117.3529	8.69943	8.69943	132.50				
Hy-x line perp. SN	T1	17	9.1765	9.58505	9.58505	29.00	9.1765	7.0882	1.368	0.190
	T2	17	7.0882	9.87300	9.87300	26.00				
Hy-point B	T1	17	56.3235	7.16315	7.16315	67.50	56.3235	51.4412	2.805	0.013*
	T2	17	51.4412	6.49972	6.49972	65.00				

* Correlation at 0.05 significance level. ** Correlation at 0.01 significance level.

TABLE 2 - Pearson's correlation (r) between different variables.

		Change in oropharyngeal diameter	Change in hypopharyngeal diameter	Hy-SN	Hy-x	Hy-point B
Mandibular Setback	r	0.162	0.067	0.263	0.338	-0.261
	p	0.535	0.800	0.307	0.184	0.312
Initial airway space diameter	r	-0.526	-0.728			
	p	0.030*	0.001**			
Hy-SN	r	-0.389	-0.266			
	p	0.123	0.302			
Hy-x	r	0.224	0.102			
	p	0.388	0.697			
Hy-point B	r	-0.127	0.001			
	p	0.626	0.997			

* Correlation at 0.05 significance level. ** Correlation at 0.01 significance level.

DISCUSSION

In the cases analyzed in this study, the mandible experienced a mean setback of 7.32 mm after surgery. The impact on the airway space was evidenced by a mean reduction of 0.97 mm in the oropharynx and 3.41 mm in the hypopharynx. The initial mean diameters of these spaces were 16.88 mm and 13.05 mm, respectively.

This reduction was statistically significant only in the region of the hypopharynx ($P=0.025$), as shown by the paired t-test (Table 1). In a study⁸ where the smallest diameter in the posterior region of the tongue (which in most cases corresponds to the hypopharynx) was measured, the same result was found: Airway space reduction, in agreement with other authors.¹²

Despite this reduction in the hypopharynx, this study was unable to establish a significant quantitative correlation between this reduction and the mandibular setback, i.e., mandibular setback causes airway narrowing, but not proportionally. However, there was a strong correlation between the initial diameter and the amount of AS reduction in the hypopharynx ($r=-0.728$, $p<0.01$). In the oropharyngeal region there was moderate correlation ($r=-0.526$, $p<0.05$) between the initial diameter and the reduction observed in the airway after surgery. Thus, patients presenting extensive airway space in the preoperative period tend to experience greater AS reduction after mandibular setback surgery.

Because most patients underwent combined orthognathic surgery, one should take into account the influence of maxillary surgery on the final position of the mandible. This influence can be observed by a change in mandibular plane angulation, as assessed by measuring GoGn-SN. The correlation found between this measure and changes in the oropharynx ($r=0.511$, $p<0.05$) indicates a direct link between this space and mandibular rotation, i.e., when GoGn-SN increases (clockwise mandibular rotation) the diameter of the oropharynx is likely to increase as well.

This finding may explain the variability found in the behavior of oropharyngeal soft tissues, where it was found that 57% of patients who underwent mandibular setback associated with maxillary intervention showed an increase in oropharyngeal space. Otherwise, three patients who underwent mandibular setback alone experienced only a reduction in this space. Another explanation for this variation may be ascribed to a difficulty in standardizing tongue position during radiograph acquisition, since such position is very unstable and constantly changes in response to physiological movements.²

A study evaluating patients who underwent mandibular setback surgery alone found a reduction in airway space (in the mandibular plane) in all cases, establishing a correlation between these two variables ($r=0.52$).⁵

Another significant finding was that the hyoid bone was displaced inferiorly (mean=4.26 mm) in response to mandibular setback. Horizontally, bone movement varied with a slight prevalence of posterior displacement (2.08 mm), following the mandibular movement. Other authors^{4,7,12} also observed inferior and posterior displacement of the hyoid bone. In contrast, anterior displacement of this bone has also been reported.¹⁵

Reduction in the distance between the hyoid bone and the anterior mandible region (mean=4.88 mm) was also a significant finding, which raised the question of how the suprahyoid musculature might behave. Changes in this muscle's tone are likely to take place over time to compensate for the decrease in this distance. The largest reduction found for this distance was 18 mm, corresponding to 27% of the original distance exhibited by this particular individual.

In this study, cephalometric radiographs were used to evaluate the upper airways. Although these X-rays provide a two-dimensional view of a three-dimensional structure, studies in the literature have shown adequate correlation between measurements obtained from lateral radiographs and CT scans, validating the former's use for this purpose.^{6,9}

Magnetic resonance evaluation of airway behavior after orthognathic surgery has shown no signs of edema in patients' airways in the immediate postoperative period.¹⁰ It is therefore safe to assert that the airway changes observed in this study were not masked by tissue edema but result in fact from movements induced by bone surgery.

This study focused on assessing changes in the immediate postoperative period. Other authors, however, followed their patients for longer periods: 3 months, 6 months, 1 year and up to three years. After one year, no significant tendency was found showing that airway soft tissues tend to return to their initial dimensions.⁵ Another study,⁷ which used computed tomography, also demonstrated this same result. A two-year or longer follow-up actually suggests that changes occur in the airways over time after mandibular setback surgery.¹³ Moreover, some authors argue that the hyoid bone tends to return to its original position, probably because mandible position tends to relapse forward and upward even though the hyoid bone does not quite extend as far as the mandible.⁴

Although there are many studies on this subject in the literature, any comparison between them is complicated by the use of a wide range

of different methodologies, which are still rather limited due to the nature of airway tissues and their dynamic structure. Further studies are warranted to clinically evaluate the impact of changes observed in cephalometric radiographs. Are such changes sufficient to cause dysfunction or are they within the scope of physiological limits? The answer to this question requires that patients be interviewed for possible symptoms of discomfort, breathing or swallowing difficulties, snoring, apnea or other symptoms that might exert a genuine impact on the health of these individuals.

CONCLUSIONS

Mandibular setback orthognathic surgery for treatment of cases with Class III facial deformity can lead to significant upper airway narrowing, especially in the lower portion, which comprises the hypopharynx (3.41 mm). Careful attention should therefore be given to the evaluation of this area in lateral view cephalometric radiographs during the stage of orthosurgical treatment planning, as potential deleterious effects, not only as a result of this reduction but also due to other alterations in crucial patient functions, should not be overlooked.

REFERENCES

1. Chen F, Terada K, Hua Y, Saito I. Effects of bimaxillary surgery and mandibular setback surgery on pharyngeal airway measurements in patients with Class III skeletal deformities. *Am J Orthod Dentofacial Orthop.* 2007;131(3):372-7.
2. Eggensperger N, Smolka K, Johner A, Rahal A, Thüer U, Iizuka T. Long-term changes of hyoid bone and pharyngeal airway size following advancement of the mandible. *Oral Surg Oral Med Oral Pathol Oral Radiol Endod.* 2005;99(4):404-10.
3. Froberg U, Naples RJ, Jones DL. Cephalometric comparison of characteristics in chronically snoring patients with and without sleep apnea syndrome. *Oral Surg Oral Med Oral Pathol Oral Radiol Endod.* 1995;80(1):28-33.
4. Gu GM, Gu G, Nagata J, Suto M, Anraku Y, Nakamura K, et al. Hyoid position, pharyngeal airway and head posture in relation to relapse after the mandibular setback in skeletal Class III. *Clin Orthod Res.* 2000;3(3):67-77.
5. Hochban W, Schürmann R, Brandenburg U. Mandibular setback for surgical correction of mandibular hyperplasia - does it provoke sleep-related breathing disorders? *Int J Oral Maxillofac Surg.* 1996;25(5):333-8.
6. Jacobson A. Airway changes after orthognathic surgery as assessed by cone-beam computed tomography [abstract]. *Am J Orthod Dentofacial Orthop.* 2007;132(5):712.
7. Kawamata A, Fujishita M, Ariji Y, Ariji E. Three-dimensional computed tomographic evaluation of morphologic airway changes after mandibular setback osteotomy for prognathism. *Oral Surg Oral Med Oral Pathol Oral Radiol Endod.* 2000;89(3):278-87.
8. Liukkonen M, Vähätalo K, Peltomäki T, Tiekso J, Happonen RP. Effect of mandibular setback surgery on the posterior airway size. *Int J Adult Orthodon Orthognath Surg.* 2002;17(1):41-6.
9. Lowe AA, Fleetham JA, Adachi S, Ryan CF. Cephalometric and computed tomographic predictors of obstructive sleep apnea severity. *Am J Orthod Dentofacial Orthop.* 1995;107(6):589-95.
10. Meisami T, Musa M, Keller MA, Cooper R, Clokie CM, Sándor GK. Magnetic resonance imaging assessment of airway status after orthognathic surgery. *Oral Surg Oral Med Oral Pathol Oral Radiol Endod.* 2007;103(4):458-63. Epub 2006 Oct 27.
11. Rajagopal MR, Jerry P. Applied anatomy and physiology of the airway and breathing. *Indian J Anaesth.* 2005;49(4):251-6.
12. Samman N, Tang SS, Xia J. Cephalometric study of the upper airway in surgically corrected Class III skeletal deformity. *Int J Adult Orthodon Orthognath Surg.* 2002;17(3):180-90.
13. Saitoh K. Long-term changes in pharyngeal airway morphology after mandibular setback surgery. *Am J Orthod Dentofacial Orthop.* 2004;125(5):556-61.
14. Silverstein K, Costello BJ, Giannakopoulos H, Hendler B. Genioglossus muscle attachments: an anatomic analysis and the implications for genioglossus advancement. *Oral Surg Oral Med Oral Pathol Oral Radiol Endod.* 2000;90(6):686-8.
15. Tselnik M, Pogrel A. Assessment of the pharyngeal airway space after mandibular setback surgery. *J Oral Maxillofac Surg.* 2000;58(3):282-5.

Submitted: August 20, 2008
Revised and accepted: March 2, 2009

Contact address

Eduardo Franzotti Sant'Anna
Av. Brigadeiro Trompowsky, s/n
CEP: 21.949-900 - Ilha do Fundão - Rio de Janeiro/RJ, Brazil
E-mail: eduardo.franzotti@gmail.com