

# Change in the gingival fluid volume during maxillary canine retraction

Jonas Capelli Jr.\*, Rivail Fidel Junior\*\*, Carlos Marcelo Figueredo\*\*\*, Ricardo Palmier Teles\*\*\*\*

## Abstract

**Introduction:** In the analysis of the pressure-tension theory of tooth movement, the application of an orthodontic force causes gradual displacement of fluids of the periodontal ligament, followed by distortion of the cells and extracellular matrix. **Objectives:** This study evaluated the gingival fluid volume on the mesial and distal aspects of the maxillary canines of 14 patients (3 males and 11 females) submitted to orthodontic movement. **Methods:** The fluid was collected using standard absorbent paper strips (Periopaper™) and the fluid volume was determined using the instrument Periotron™ at seven different periods (day -7, day 0, 1 hour, 24 hours, 14 days, 21 days, 80 days). The Friedman test was applied to compare the data achieved ( $p < 0.01$  and  $p < 0.05$ ). **Results:** The results revealed a significant change in the gingival fluid volume with time on both the pressure side ( $p < 0.001$ ) and the tension side ( $p < 0.01$ ). On the pressure side, the gingival fluid volume was significantly lower at the periods 0 ( $p < 0.01$ ) and 24hs ( $p < 0.001$ ) compared to the period 80 days.

**Keywords:** Gingival sulcus. Orthodontic movement. Inflammation.

## INTRODUCTION

The initial stage of orthodontic tooth movement involves an acute inflammatory response in the periodontium, characterized by vasodilation and leukocyte migration outside the capillaries. These migrating cells produce several cytokines, the local biochemical molecular signals, which interact directly or indirectly with the paradental cells.<sup>5</sup> The cytokines trigger the synthesis and secretion of several substances by the target cells, including prostaglandins, growth factors and other

cytokines. Ultimately, these cells form functional units that promote remodeling of the paradental tissues and facilitate the tooth movement.<sup>7</sup>

The acute inflammatory process that characterizes the initial stage of orthodontic tooth movement is predominantly exudative, in which plasma and leukocytes migrate outside the capillaries in areas of paradental stress. After one or two days, the acute stage of inflammation is decreased and replaced by a chronic process involving fibroblasts, endothelial cells and osteoblasts.

\* Associate professor of Orthodontics at FO-UERJ.

\*\* Collaborator professor of Periodontics at UERJ. Collaborator professor of the Specialization Course in Periodontics at PUC-RJ. Associate professor of the Specialization Course in Periodontics at ABO-DC.

\*\*\* Associate professor of Periodontics at UERJ. Associate professor of the Specialization Course in Periodontics at PUC-RJ.

\*\*\*\* Researcher at the Department of Periodontics at Forsyth Institute, Boston, USA.

During this period, the leukocytes continue to migrate in the stressed paradental tissues and modulate a remodeling process. The chronic inflammation prevails until the following session, when the orthodontist activates the force-inducing component and triggers another period of acute inflammatory process, which is superimposed to the chronic inflammation.<sup>8</sup>

For the patient, the periods of acute inflammation are associated with pain and impaired function (mastication). The reflex of this phenomenon may be observed in the gingival fluid of teeth submitted to orthodontic movement, which presents temporary significant increases in the concentrations of inflammation mediators such as cytokines and prostaglandins.<sup>8</sup>

The observation that orthodontic tooth movement involves several reactions with inflammatory characteristics was important because it allowed a better understanding that the factors involved in inflammation may be part of the reactions of tooth supporting tissues to orthodontic forces. However, the orthodontist should not feel embarrassed to induce focal areas of inflammation of the periodontal ligament during tooth movement for therapeutic purposes.<sup>15</sup> The occurrence of inflammatory events in the tissues does not necessarily imply clinically noticeable local changes or symptoms, because the inflammation may be subclinical.<sup>3</sup>

The expression of these biologically active substances concerning the changes in the gingival fluid during orthodontic tooth movement has been analyzed by non-invasive investigations in humans. These substances are produced by the periodontal ligament cells in sufficient quantity to be present and diffuse in the gingival fluid.<sup>4</sup>

## PURPOSE

Based on these considerations, this study quantified the gingival fluid volume on the mesial and distal aspects, respectively areas of tension and pressure, of maxillary canines submitted to orthodontic movement.

## MATERIAL AND METHODS

### Patient selection

This study was conducted on 14 patients attending the clinic of the Specialization Course in Orthodontics at the Dental School of the State University of Rio de Janeiro. The selection of patients did not follow criteria related to gender, ethnicity or malocclusion, except for the fact that all patients were indicated for extraction of maxillary first molars as part of the orthodontic treatment planning. The patients were informed on the characteristics and objectives of the study and signed an informed consent form. The group of patients was composed of 3 males and 11 females ( $18.8 \pm 4.8$  years; range 12 to 28 years).

The exclusion criteria comprised the presence of autoimmune diseases, pregnancy, breastfeeding, prolonged use of drugs during the six months before study onset (antibiotics, anti-histaminic drugs, cortisone, hormones), and others that might interfere with the inflammatory process or cause any direct adverse effect on the periodontium.

### Orthodontic device

Brackets with 0.022 x 0.028-in slots (Morelli, Sorocaba, SP, Brazil) were bonded on the canines and second premolars and bands were fitted and cemented on the first molars with 0.055 x 0.022 x 0.028-in triple tubes (Morelli) welded on the buccal aspect and 2 x 0.036-in tubes (Morelli) welded on the palatal aspect. The premolars had been extracted at least 20 days earlier, before onset of canine retraction. The canines were retracted using a 0.017 x 0.025-in segmented archwire fabricated with TMA (Morelli) with a vertical loop activated by a NiTi coil (Morelli), which delivered a 150 g force measured with a strain gauge (Dentaureum, Ispringen, Germany). A passive auxiliary archwire was tied to the tube on the first molars and brackets on the maxillary second premolars<sup>6,7</sup> (Figs 1 and 2). Auxiliary anchorage was achieved with a transpalatal bar connecting the maxillary first molars, fabricated with 0.032-in wire (Morelli).

### Clinical follow-up

The clinical examinations comprised analysis of: (1) Plaque index (PI) and (2) Gingival index (GI). Periodontal examination was conducted by a single calibrated examiner. The PI and GI measurements were determined with the aid of a Goldman-Fox/Williams periodontal probe (Hu-Friedy, Chicago - IL, USA). The absence/presence of plaque/bleeding was evaluated on all teeth on the buccal, lingual, mesial and distal aspects. Seven days before the initial application of orthodontic force the patients received oral hygiene instructions and were asked to brush their teeth using an orthodontic toothbrush (Oral-B, São Paulo-SP, Brazil), using the dentifrice Colgate Total 12 (Colgate/Palmolive, São Bernardo do Campo-SP, Brazil) and perform mouthrinsing with 0.12% chlorhexidine gluconate<sup>2</sup> (Noplak, Lab. Daudt, Rio de Janeiro-RJ, Brazil) twice a day until completion of the study.

### Collection of gingival fluid (GF) samples

The samples were collected from the mesial and distal aspects of the maxillary canines of each patient at six different periods. The first collection was performed 7 days before onset of application of orthodontic force, called period -7d. The second collection was obtained on the first day of force application, called period 0. The third was collected one hour after force application, called period 1h. The fourth was obtained 24 hours after force application, called period 24hs. The fifth was collected two weeks after force application, called period 14d. The sixth was achieved three weeks after force application, called period 21d. Finally, the seventh collection was performed 80 days after the initial force application, called period 80d.

The collection sites were isolated using cotton rolls and air-dried. A standard absorbent paper strip (Periopaper, IDE Interstate, Amityville-NY, USA) was placed in the gingival sulcus until

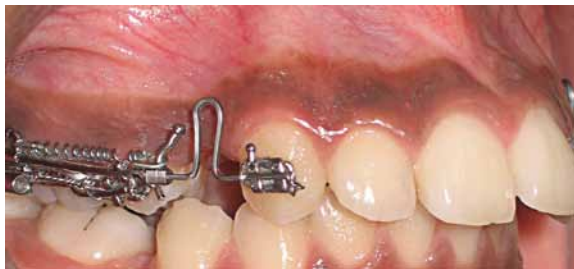

FIGURE 1 - Orthodontic device employed for maxillary canine retraction in period 0.

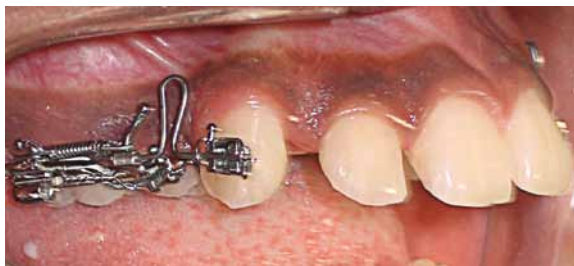

FIGURE 2 - Aspect 80 days after onset of maxillary canine retraction.

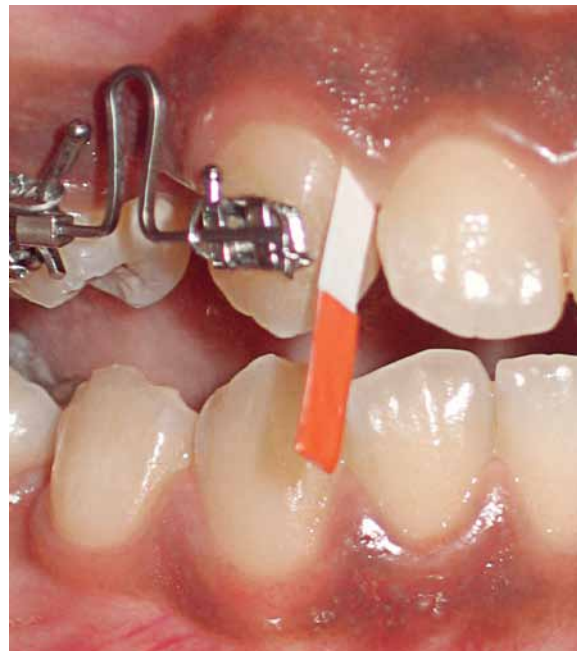

FIGURE 3 - Absorbent paper strip used for collection of gingival fluid.

resistance was felt and left in this position for 30 seconds (Fig 3). The GF volume was immediately determined using a calibrated GF measurement instrument (Periotron 8000, IDE Interstate, Amityville, NY, USA). The electrode tweezers were cleaned and dried and the digital monitor was zeroed after each measurement.

## RESULTS

The device employed for canine distalization was effective, achieving considerable magnitude of movement in a period of 80 days.

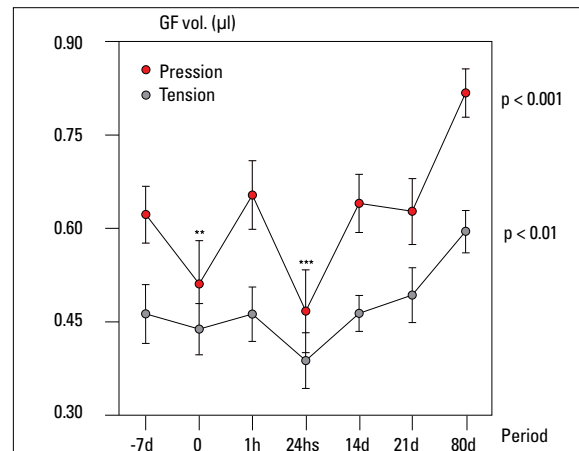
Graph 1 presents the mean gingival fluid volumes (GF) in  $\mu\text{l}$  on the Pressure side ( $n = 14$ ) and Tension side ( $n = 14$ ) with time. The non-parametric Friedman test was applied to analyze the significance of difference with time. The results revealed significant change in the GF volume with time on both the pressure side ( $p < 0.001$ ) and the tension side ( $p < 0.01$ ). On the pressure side, the GF volume was significantly lower in periods 0 ( $p < 0.01$ ) and 24hs ( $p < 0.001$ ) compared to the period 80d, according to the Dunn's multiple comparisons test.

## DISCUSSION

Even though the force application was carefully controlled, achieving optimal values, there was a tendency of crown tipping instead of a translation movement.<sup>7,8,15</sup> This inclination may be corrected in the subsequent stages of orthodontic treatment and was observed in most cases in this study.

During canine retraction, the pressure-tension theory of tooth movement and accompanying phenomena were expected. Application of an orthodontic force on a tooth causes gradual displacement of fluids of the periodontal ligament, followed by distortion of the cells and extracellular matrix.<sup>5</sup>

In this study, the change in the gingival fluid volume demonstrated variations in the different periods. In the period -7d, when the patients presented their own oral hygiene habits, the readings



GRAPH 1 - Graph of mean changes in the GF volume on the pressure and tension areas with time (\*\*  $p < 0.01$  and \*\*\*  $p < 0.001$ ).

of the Periotron™ revealed values indicating presence of mild inflammation in the gingival tissue, with higher values on the pressure site, probably due to the greater difficulty to perform oral hygiene on the distal aspect of canines. These values were similar to those observed in a previous study that analyzed the gingival fluid volume in patients with gingivitis.<sup>4</sup> In period 0, when the patients had received oral hygiene instructions and had initiated daily mouthrinsing with chlorhexidine gluconate, the gingival fluid volume was reduced and the readings of the Periotron™ exhibited lower values, without differences between the pressure and tension sides. One hour after orthodontic force application the values were increased, especially on the pressure side, despite the effective dental plaque control. In the period 24hs there was a reduction in the gingival fluid volume on both sides. This agrees with the report of Tuncer et al<sup>18</sup> on the tension side, who considered that this finding represented an initial stage of inflammatory response to a mechanical trauma.

In the period 14d the values were similar to the period -7d, indicating that, with the induction of a mechanical stimulus, the gingival fluid volume was changed as observed in the presence of a bacterial stimulus. In the period 21d to 80d,

the use of chlorhexidine was interrupted and the patients did not receive any specific toothbrushing instructions. A considerable increase in the gingival fluid volume was then observed, especially on the pressure side; in this period, probably there was a combination of mechanical stimulus due to canine retraction and the presence of dental plaque.

Previous studies demonstrated that the gingival fluid flow reflects the changes in deeper regions of the periodontal tissues, such as the alveolar bone and periodontal ligament, in teeth submitted to orthodontic treatment.<sup>4,6,8,9,12</sup> The increase in the gingival fluid flow may be observed in teeth submitted to orthodontic movement, being reduced in the retention period, when tooth movement is interrupted.<sup>13</sup> This variation in the gingival fluid volume in teeth under mechanical stress might be associated to the onset of a subsequent inflammatory process, which is involved in the cascade of events necessary for orthodontic tooth movement.<sup>3,6,8,9,12</sup> The direction of gingival fluid flow in teeth under mechanical stress would be from the pressure side to the tension side, both apically and coronally toward the gingival sulcus. Compression of the periodontal ligament would be asso-

ciated to the appearance of biochemical markers released by the cells, which would be detected in the gingival sulcus. Moreover, the effect of orthodontic forces on the periodontal ligament is fast, with changes occurring in minutes after their application.<sup>16</sup>

It should be considered that the utilization of orthodontic braces may contribute to the increase in dental plaque and gingival inflammation, which might be related to the increased enzymatic activity of in all sites.<sup>13</sup> The hygiene of teeth with orthodontic appliances is difficult and toothbrushing may be complemented by chemical dental plaque control in special situations, such as in patients submitted to orthognathic surgery. Chlorhexidine is the best product for gingivitis control in orthodontic patients. The 0.12% chlorhexidine gluconate is an important therapeutic agent for the control of inflammation, gingival bleeding and plaque accumulation in orthodontic patients.<sup>1,2</sup>

Therefore, it may be concluded that there is a significant change in the gingival fluid volume with time in maxillary canines submitted to retraction, both on the pressure and tension sides. On the pressure side, the gingival fluid volume was significantly lower in the periods 0 and 24hs compared to the period 80d.

## REFERENCES

1. Boyd R. Considerações periodontais durante o tratamento ortodôntico. In: Bishara S. Ortodontia. 1ª ed. São Paulo: Ed. Santos; 2004. p. 442-53.
2. Brightman LJ, Terezhalmay GT, Greenwell H, Jacobs M, Enlow DH. The effects of a 0.12% chlorhexidine gluconate mouth rinse on orthodontic patients aged 11 through 17 with established gingivitis. *Am J Orthod Dentofacial Orthop.* 1991 Oct;100(4):324-9.
3. Consolaro A. Reabsorções dentárias nas especialidades odontológicas. 2ª ed. Maringá: Dental Press; 2005.
4. Goodson JM. Gingival crevice fluid flow. *Periodontology* 2000. 2003; 31(1):55-76.
5. Grieve W, Johnson G, Moore R, Reinhardt R, Dubois L. Prostaglandin E (PGE) and interleukin-1 $\beta$  (IL-1 $\beta$ ) levels in gingival crevicular fluid during human orthodontic tooth movement. *Am J Orthod Dentofacial Orthop.* 1994; 105(4):369-74.
6. Heasman P, Millet D, Chapple I. The periodontium and orthodontics in health and disease. Toronto: Oxford University Press; 1996.
7. Iwasaki LR, Crouch LD, Tutor A, Gibson S, Hukmani N, Marx DB, et al. Tooth movement and cytokines in gingival crevicular fluid and whole blood in growing and adult subjects. *Am J Orthod Dentofacial Orthop.* 2005 Oct;128(4):483-91.
8. Iwasaki L, Haack J, Nickel J, Morton J. Human tooth movement in response to continuous stress of low magnitude. *Am J Orthod Dentofacial Orthop.* 2000 Feb;117(2):175-83.
9. Krishnan V, Davidovitch Z. Cellular, molecular, and tissue-level reactions to orthodontic force. *Am J Orthod Dentofacial Orthop.* 2006 Apr;129(4):469.e1-32.
10. Lamster IB. Evaluation of components of gingival crevicular fluid as diagnostic tests. *Ann Periodontol.* 1997 Mar;2(1):123-37.
11. Lindhe J. Tratado de periodontia clínica e implantologia oral. 3a ed. Rio de Janeiro: Guanabara Koogan; 1999.
12. Masella RS, Meister M. Current concepts in the biology of orthodontic tooth movement. *Am J Orthod Dentofacial Orthop.* 2006 Apr;129(4):458-68.
13. Pender N, Samuels RH, Last KS. The monitoring of orthodontic tooth movement over 2-year period by analysis of gingival crevicular fluid. *Eur J Orthod.* 1994 Dec;16(6):511-20.
14. Sandy JR, Farndale RW, Meikle MC. Recent advances in understanding mechanically induced bone remodeling and their relevance to orthodontic theory and practice. *Am J Orthod Dentofacial Orthop.* 1993 Mar;103(3):212-22.
15. Smith R, Storey E. The importance of force in orthodontics. *Austr J Dent.* 1952 Dec; 56(6):291-304.
16. Sugiyama Y, Yamaguchi M, Kanekawa M, Yoshii M, Nozoe T, Nogimura A, et al. The level of cathepsin B in gingival crevicular fluid during human orthodontic tooth movement. *Eur J Orthod.* 2003 Feb;25(1):71-6.
17. Thilander B, Rygh P, Reitan K. Reações teciduais em Ortodontia. In: Graber T, Vanarsdall R. Ortodontia princípios e técnicas atuais. 3ª ed. Rio de Janeiro: Guanabara Koogan; 2002. p. 101-68.
18. Tuncer BB, Ozmeriç N, Tuncer C, Teoman I, Cakilci B, Yücel A, et al. Levels of interleukin-8 during tooth movement. *Angle Orthod.* 2005 May;75(3):497.

Submitted: April 2007

Revised and accepted: November 2007

**Contact address**

Jonas Capelli Junior  
 Rua Visconde de Pirajá, 407 / 203  
 Rio de Janeiro/RJ, Brazil  
 CEP: 22.410-003  
 E-mail: capellijr@uol.com.br