

# Electromyographic analysis of the orbicularis oris muscle in youngsters with Class II, Division 1 and normal occlusion

Vania Célia Vieira de Siqueira\*, Meire Alves de Sousa\*\*, Fausto Bérzin\*\*\*, César Augusto Souza Casarini\*\*\*\*

## Abstract

**Aim:** The purpose of this study was to make an electromyographic comparison of the action potentials of the upper and lower segments of the orbicularis oris muscle, bilaterally, in youngsters with Class II, Division 1 malocclusion and youngsters with normal occlusion in order to verify whether or not there is a difference between the two groups with regard to the electromyographic activity that occurs. **Methods:** The sample consisted of 50 girls, in the age-range from 8 to 10 years, with no previous orthodontic treatment, divided into two groups: 25 with Class II, Division 1 malocclusion and 25 with normal occlusion. Electromyographic signals of the orbicularis oris muscle were acquired using Ag/AgCl surface electrodes. Muscle activity was recorded in the resting position, in the isometric contraction and in the isotonic contraction and the Root Mean Square (RMS) values of each movement were determined. The data collected were submitted to statistical analyses of variance and Tukey test ( $\alpha=0.05$ ). **Results:** The results showed that there was a difference in electromyographic activity between the young girls with Class II, Division 1 malocclusion and those with normal occlusion. Muscle activity was higher in the girls with malocclusion than in those with normal occlusion. **Conclusion:** This suggests lower competence of the orbicularis oris muscle in the girls with Class II, Division 1 malocclusion.

**Keywords:** Electromyography. Orthodontics. Class II Division 1. Normal occlusion. Orbicularis oris muscle.

**How to cite this article:** Siqueira VCV, Sousa MA, Bérzin F, Casarini CAS. Electromyographic analysis of the orbicularis oris muscle in youngsters with Class II, Division 1 and normal occlusion. *Dental Press J Orthod.* 2011 Sept-Oct;16(5):54-61.

» The authors report no commercial, proprietary, or financial interest in the products or companies described in this article.

\* PhD and Professor, Orthodontics Course at the Piracicaba School of Dentistry - UNICAMP, Brazil.

\*\* PhD in Orthodontics, Piracicaba School of Dentistry - UNICAMP - Brazil;

\*\*\* Head Professor of the Anatomy Course, Department of Physiology, Piracicaba School of Dentistry - UNICAMP, Brazil.

\*\*\*\* PhD in Anatomy, Department of Physiology, Piracicaba School of Dentistry - UNICAMP, Brazil.

## INTRODUCTION

Electromyographic analysis of the masticatory muscles constitutes an important complementary instrument in orthodontic diagnosis, as a careful evaluation of muscle activity before and during treatment guides the professional in selecting suitable therapy, as well as in the choice of more individualized retainers, minimizing relapses.<sup>22</sup>

Perioral musculature and lip position are determinant factors in the position of the teeth and shape of the dental arch because of their moderate yet continuous activities. The forces resulting from the resting position of the lips help to define and maintain the occlusion. Patients with lip incompetence are unable to achieve habitual lip sealing without effort, a condition that favors dental protrusion by the reduction of lip pressure that acts on them, generating facial imbalance. The absence of contact between the lips causes a muscle imbalance that may affect various functions, such as breathing, swallowing and speech, besides the growth and harmonious development of the face.<sup>4,6,7,9,10,11,29</sup>

There are three swallowing patterns: Normal, with accentuated contraction of the masseter muscle and limited activity of the labial and chin musculature; the visceral type, with little or no activity of the masseter, considerable contraction of the chin muscle and smooth activity of the lower segment of the orbicular muscle of the mouth; and the third, with marked activity of the lower segment of the orbicular and chin muscles, considerable contraction of the upper segment of the orbicular muscle of the mouth and minimum activity of the masseter. Both segments of the orbicular muscle of the mouth function as separate and independent entities.<sup>14</sup>

The behavioral pattern of the upper and lower segments of the orbicular muscle of the mouth evaluated in youngsters presenting normal occlusion shows the absence of significant electromyographic activity in this muscle during mastication and deglutition, as well as in the resting state. The lateral and medial regions, upper and lower segments may

function as independent organs between them, in spite of constituting one and the same muscle.<sup>5,18,30</sup>

The synergic patterns of muscle behavior differ with regard to the anomalies of occlusion and are correlated to the existence or lack of efficiency of the masticatory mechanism.<sup>12,16,17</sup>

Electromyographic studies of the masseter, orbicularis oris, mentalis and anterior portion of the temporal muscles, evaluated during normal deglutition and in atypical deglutition, have revealed that patients with normal deglutition presented accentuated contraction of the masseter muscle, little activity of the perioral muscles and absence of temporal muscle activity, whereas patients with atypical deglutition presented greater activity of the perioral muscles.<sup>22,26</sup>

Electromyographic analysis of the orbicularis oris, temporal, masseter, pterygoid, mentalis and supra-hyoid muscles, during the movements of mastication, deglutition, rest, lip sealing, elevation, lowering and lateral movement of the mandible in youngsters with Class II, Division 1, when compared with a similar group of youngsters with normal occlusion, showed that all the youngsters with Class II, Division 1 presented alterations in the musculature intimately connected to the temporomandibular joint, and that orthodontic treatment could alter the action potential of some of these muscles.<sup>13,18</sup> In mastication and deglutition, youngsters with malocclusion presented a tendency towards less electromyographic activity in all the muscles.<sup>1</sup> Lips considered incompetent before treatment became competent in approximately 25% of the evaluated cases.<sup>19</sup> Youngsters with clinically normal occlusion presented more competent lips than those with Class II, Division 1.<sup>24,25,27</sup>

The relationship between electromyographic activity of the upper and lower segments of the orbicularis oris muscle and predominantly nasal or mouth breathing indicated that greater activity of the muscle occurred in youngsters with predominantly mouth breathing than in those with predominantly nasal breathing.<sup>23</sup>

Electromyographic activity of the buccinator, mentalis, orbicularis oris, temporal, masseter and mandibular depressor muscles during the movements of deglutition, light contact of the teeth, forced occlusion, suction, rest and various mandibular movements did not differ among children with deciduous dentition and adults with normal occlusion.<sup>28</sup> In patients presenting finger sucking habits, a predominance of activity of the orbicularis oris or mentalis muscle occurs, and during suction minimal contraction of the temporal muscle. In the presence of sucking habits, the abnormal muscular activity patterns become established and it is not enough to correct the habit if the muscular pattern persists.<sup>2</sup>

Since the shape of the dental arches and orofacial musculature activity interact reciprocally, the present study made an electromyographic evaluation of the action potentials of the orbicularis oris muscle in its upper and lower segments, in youngsters with Class II, Division 1 and in youngsters with clinically normal occlusion to verify whether or not there were differences in the electrical activity of this muscle between these groups.

## MATERIAL AND METHODS

This research study was previously submitted to the Research Ethics Committee for evaluation and approval under number 147/2002 and was found to be in accordance with the Guidelines and Regulatory Rules of the National Council of Health, Resolution No. 196-1996.

The sample consisted of 50 young white girls, age-range between 8 and 10 years, who had never been submitted to orthodontic treatment before and were distributed into two groups: 25 with dental Class II, Division 1 and 25 with normal occlusion. The youngsters underwent clinical exam in which the relationship of the two permanent maxillary and mandibular first molars, incisal relationship in the vertical and horizontal

planes (overjet and overbite) and the relationship of the permanent and/or deciduous canines were observed. Each youngster was also asked to have complementary exams performed, which consisted of lateral cephalometric radiographs, panoramic radiographs, plaster casts as well as intra and extraoral photographs.

A chart especially designed for this research was used to note the personal data and occlusal characteristics of each selected youngster. During the clinical exam the following characteristics were observed in youngsters with Class II, Division 1:

1) Maxillary permanent first molars and deciduous canines mesially positioned in relation to the mandibular permanent first molars and deciduous canines, respectively.

2) Overjet larger than 3 mm.

Cephalometrically, the youngsters presented a vertical facial growth pattern with mean values of SN.GoGn angle of 35° and FMA angle of 27°, mean SNA angle of 80°, mean SNB angle of 75°, and mean ANB angle of 5°.

The following characteristics were considered to classify the youngsters with normal occlusion:

1) First permanent molars in key occlusion, that is, the mesio-buccal cusp of the maxillary permanent first molar occluding in the buccal sulcus of the mandibular permanent first molar; permanent and/or primary canines in Class I, that is to say, the tip of the buccal cusp of the maxillary canine occluding in the buccal embrasure between the mandibular canine and the mandibular deciduous first molar and/or mandibular first premolar.

2) Overjet and overbite of approximately 2.5 mm; absence of malpositioned teeth and absence of tooth crowding.

Cephalometrically, the subjects presented a vertical facial growth pattern with mean values of SN.GoGn angle of 35° and FMA angle of 27°, mean SNA angle of 81°, mean SNB angle of 79°, and mean ANB angle of 3°.

### Electromyographic analysis

Electromyography is defined as the collection of information about muscle electrical activity by means of electrodes connected to equipment for signal amplification and recording.<sup>8,15,20,21</sup> One of the forms of manipulating the signal occurs by determining the root mean square (Root Mean Square, RMS), representing the best method, since it considers the physiological alterations in the electromyographic signal, reflecting the number, frequency and the manners of action potentials of the active motor units, allowing an analysis of the electromyographic signal amplitude.<sup>3</sup>

For the electromyographic recording, the Signal Conditioner Myosystem-I<sup>®</sup> (Data Hominis Tecnologia Ltda, Brazil) was used, consisting of 12 channels with 12 bit dynamic range resolution, Butterworth type filter, low pass 500 Hz and high pass 20 Hz; 100 times gain, analog-to-digital converter board (A/D) with a capacity of 2000 Hz to 4000 Hz, 12 bits, Myosystem-I<sup>®</sup>, version 2.12 software, for simultaneous presentation of the signals from 12 channels and signal treatment (value of RMS, mean, minimum, maximum and standard deviation), with sampling frequency of 2000 Hz.

To capture the action potentials of the orbicularis oris muscle, passive surface Ag/AgCl electrodes from Data Hominis Tecnologia Ltda. were used. A reference electrode (ground) consisting of a stainless steel metal plate was also used with the purpose of reducing noise during electromyographic signal acquisition.

The volunteers remained seated on chairs, in the most comfortable manner possible with the back supported by the chair-back and the head positioned with the Frankfurt plane parallel to the ground, eyes open, feet supported on the ground and arms supported on the lower limbs. A pair of surface electrodes, previously coated with electric conductor gel, was fixed to the mid portion of the upper lip with plaster tape, 2 mm above its free edge, 1 cm distant

from one another and the same procedure was adopted for the lower lip with the electrodes fixed 2 mm below its margin. The reference electrode (ground), connected to the surface electrode and previously coated with electric conductor gel was also fixed to the right wrist of each of the volunteers, with the aid of velcro tape. Before beginning with electromyographic signal collection, all the volunteers were informed about the characteristics of the equipment and given instructions about the movements they should make, in addition to previous training.

The electromyographic recordings began with evaluation of the resting position and, after this, during isometric contraction and isotonic contraction. For each of the above-mentioned situations, a collection time of 10 seconds was performed. When recording the resting position, each volunteer kept the facial and masticatory musculature relaxed and lips in their habitual posture, with the examiner using the following command: Relax, relax, relax...

After this, to record isometric contraction, which was performed in maximum intercuspation, the volunteer placed parafilm material between the maxillary and mandibular teeth, bilaterally. The following verbal command was established: Force, force, force... Maintained for 10 seconds. To record isotonic contraction, non habitual masticatory activity, parafilm was used in the same way as in the previous movement and the masticatory cycle was determined by means of a metronome with a beat frequency of 60 bpm. The volunteer was instructed to bite the parafilm for 10 seconds whenever the sound of the metronome was heard.

After data collection, the electromyographic tracings were evaluated, and intervals were selected for analysis with each interval corresponding to 1 second. In the resting position and in isometric activity, 3 central intervals from the electromyographic tracing were selected, avoiding the initial and final intervals, as these may be influenced by the volunteer's initial hesitation,

TABLE 1 - Mean RMS ( $\mu\text{V}$ ) and standard deviation values with reference to the orbicularis oris muscle, upper segment (UO), of the groups with Class II, Division 1 and normal occlusion, in the resting, isometric and isotonic positions.

	Group			
	Class II, Division 1		Normal Occlusion	
	Mean	SD	Mean	SD
Rest	8.84 Ac	4.79	5.27 Bc	2.37
Isometry	27.66 Aa	23.64	17.83 Ba	8.41
Isotony	21.39 Ab	16.19	14.32 Bb	8.55

Means followed by different letters (capitals in the horizontal and lower case in the vertical) differ among them by ANOVA and the Tukey test ( $p < 0.05$ ).

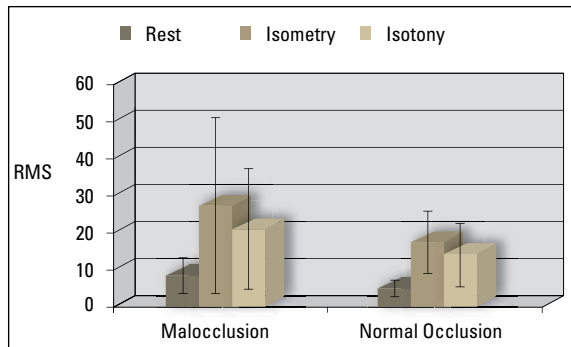


FIGURE 1 - Mean RMS ( $\mu\text{V}$ ) and standard deviation values with reference to the orbicularis oris muscle, upper segment (UO), of the groups with Class II, Division 1 and normal occlusion, in the resting, isometric and isotonic positions.

TABLE 2 - Mean RMS ( $\mu\text{V}$ ) and standard deviation values with reference to the orbicularis oris muscle, lower segment (LO), of the groups with Class II, Division 1 and normal occlusion, in the resting, isometric and isotonic positions.

	Group			
	Class II, Division 1		Normal Occlusion	
	Mean	SD	Mean	SD
Rest	14.24 Ab	10.63	6.96 Bb	3.50
Isometry	30.63 Aa	13.24	19.90 Ba	9.43
Isotony	25.85 Aa	14.19	20.61 Ba	16.62

Means followed by different letters (capitals in the horizontal and lower case in the vertical) differ among them by ANOVA and the Tukey test ( $p < 0.05$ ).

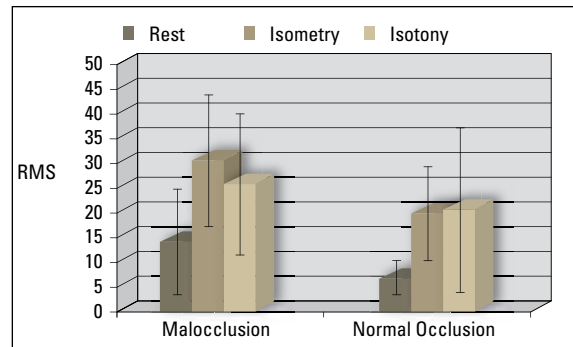


FIGURE 2 - Mean RMS ( $\mu\text{V}$ ) and standard deviation values with reference to the orbicularis oris muscle, lower segment (LO), of the groups with Class II, Division 1 and normal occlusion, in the resting, isometric and isotonic positions.

or diminished muscle activity at the end of the movement. In isotonic activity, one interval of the collected electromyographic tracing was selected, also avoiding the initial and final intervals.

The collected data were processed by the RMS (Root Mean Square) using Myosystem-I software, and submitted to statistical analysis by the analysis of variance (ANOVA) for repeated measures and the Tukey test ( $\alpha = 0.05$ ).

## RESULTS

The data with reference to electromyographic analysis are shown in Tables 1 and 2 and Figures 1 and 2.

The results revealed that there was statistical significant difference between the two studied groups, so that youngsters with Class II, Division 1 presented a higher mean value of electrical activity of the orbicularis oris muscle than youngsters with normal occlusion, in all the evaluated positions. Greater electrical activity occurred during isometric contraction than in isotonic contraction, however, this difference was not shown to be statistically significant for the lower segment of the orbicularis oris muscle. Discrete muscular activity was observed both in the group with Class II, Division 1 and in the group with normal occlusion during the resting position.

## DISCUSSION

In this study, it was chosen to evaluate a group of youngsters in the age-range from 8 to 10 years, of the female gender, with dental Class II, Division 1, comparing them with a similar group with normal occlusion, as a great demand for treatment for this type of malocclusion has been observed in daily clinical practice. It is believed that orthodontic intervention in this age-range is more efficient because of greater tissue viscoelasticity, thus contributing to post-treatment stability. The choice of girls was made with the intention of avoiding variables that could interfere in the results due to inherent differences in development between the genders.

Electromyography is an extremely useful tool in the study of neuromuscular aspect of the masticatory system. Nevertheless, to obtain a faithfully electromyographic recording it is imperative to use an adequate technique in order to minimize the interferences from the environment.

In electromyographic signal acquisition surface electrodes were used. The choice of electrodes depends on the information one wishes to collect and the location of the muscles to be studied. Surface electrodes are used in the study of muscles located immediately under the skin, as they allow the integrated electrical activity of these muscles to be estimated, whereas needle electrodes enable access to deeper muscles, making them important in the study of motor units.<sup>15,16,20,21</sup> In addition, surface electrodes have been shown to be easy to use and cause no discomfort to the patient.<sup>3,20</sup>

In processing the collected signal, it was chosen to determine the RMS. This form of analysis presents outstanding advantages, since muscle electrical activity is expressed quantitatively, with this calculation made in a simplified manner by means of specific types of software.<sup>3,21</sup>

In the present study there was evidence of a difference in electromyographic activity between youngsters with Class II, Division 1 and normal occlusion, with greater electrical activity of the

muscles in the group with malocclusion. This fact is probably related to the characterization of this malocclusion; that is, projected maxillary incisors and anteroposterior discrepancy, which makes it difficult for this musculature to perform its basic functions, generating the need for adaptations. The results obtained are in agreement with those of previous studies, in which the authors observed that patients with Class II, Division 1 expend greater perioral musculature effort to make various movements,<sup>11,19,24,25,27</sup> in addition to presenting lower action potentials of the orbicularis oris muscle than those patients with normal occlusion; and that reduction in adequate dental contacts in the anterior region caused hypotonicity of the upper lip.<sup>1,12</sup>

Some studies have also verified adaptations of the perioral muscles, with an increase in their activity in the presence of alterations such as sucking habits, predominantly mouth breathing and abnormal swallowing.<sup>2,6,14,22,23,26,29</sup>

There are many reports in the literature about the importance of the perioral musculature as an etiologic factor of malocclusions.<sup>9,13,18,29,30</sup> However, it was observed that there is great difficulty in evaluating the real participation of this musculature in determining the positions of teeth. The lip length presents no correlation with the degree of maxillary incisor protrusion.<sup>14</sup> There is no direct correlation between the shape of the maxillary dental arch and perioral muscle activity<sup>19</sup> but there is a possible impact of activity of the orbicularis oris muscle on the final position of teeth in the dental arches, especially in Class II, Division 1 and Division 2.<sup>10</sup> Larger lip thickness could possibly cause greater muscular activity, but not necessarily influencing the position of teeth or inclination of incisors.<sup>17</sup> Persistence of the pattern of perioral muscle dysfunction after orthodontic treatment may cause relapse.<sup>22</sup> Imbalance of the perioral musculature represents a powerful factor in deformation of the arches and position of teeth.<sup>4</sup> The orbicularis oris muscle influences the angulation of the maxillary incisors, however, it is not influenced by the degree



of maxillary protrusion.<sup>7</sup> However, there appears to be no doubt that the upper and lower segments of the orbicularis oris muscle function in an independent manner.<sup>5,14,18,30</sup>

In view of the results obtained in this study, it is believed that patients with Class II, Division 1 present a pattern of perioral muscle activity that differs from those with normal occlusion, with the need for greater muscle fiber participation to perform various functions.

## CONCLUSIONS

Based on the literature, sample characteristics, methodology used and results obtained, it was concluded that:

1) Different electromyographic activity occurred between youngsters with Class II, Division 1 and those with normal occlusion.

2) This activity was shown to be greater in youngsters with Class II, Division 1, thus, suggesting decreased lip competence in this group.

## REFERENCES

- Ahlgren JGA, Ingervall BF, Thilander BL. Muscle activity in normal and postnormal occlusion. *Am J Orthod.* 1973;64(5):445-56.
- Baril C, Moyers RE. An electromyographic analysis of the temporalis muscles and certain facial muscles in thumb and finger sucking patients. *J Dent Res.* 1960;39(3):536-53.
- Basmajian JV, De Luca CJ. *Muscles alive: their function revealed by electromyography.* 5<sup>th</sup> ed. Baltimore: Williams & Wilkins; 1985.
- Camargo MCF, Azevedo Jr O, Briso MLG. Dispositivo indutor de vedamento labial – DIVEL. *J Bras Ortodon Ortop Facial.* 2001;6(33):256-61.
- Essenfelder LRC, Vitti M. Análise eletromiográfica dos músculos orbicularis oris em jovens portadores de oclusão normal. *Ortodontia.* 1977;10(3):180-91.
- Gustafsson M, Ahlgren J. Mentalis and orbicularis oris activity in children with incompetent lips. *Acta Odontol Scand.* 1975;33(6):355-63.
- Jung MH, Yang WS, Nahm DS. Effects of upper lip closing force on craniofacial structures. *Am J Orthod Dentofacial Orthop.* 2003;123(1):58-63.
- Lehmkuhl DL, Smith KL. *Cinesiologia clínica de Brunstrom.* 4<sup>a</sup> ed. São Paulo: Manole; 1989.
- Lowe AA, Johnston WD. Tongue and jaw muscle activity in response to mandibular rotations in a sample of normal and anterior open-bite subjects. *Am J Orthod.* 1979;76(5):565-76.
- Lowe AA, Takada K. Associations between anterior temporal, masseter, and orbicularis oris muscle activity and craniofacial morphology in children. *Am J Orthod.* 1984;86(4):319-30.
- Lowe AA, Takada K, Taylor LM. Muscle activity during function and its correlation with craniofacial morphology in a sample of subjects with class II, division 1 malocclusions. *Am J Orthod.* 1983;84(3):204-11.
- Marchiori SC, Vitti M. Estudo eletromiográfico do músculo orbicular da boca em indivíduos com oclusão normal e maloclusões. *RGO: Rev Gaúcha Odontol.* 1996;44(6):331-4.
- Moyers RE. Temporomandibular muscle contraction patterns in Angle Class II, division I malocclusions: an electromyographic analysis. *Am J Orthod.* 1949;35(11):837-57.
- Nieberg LG. An electromyographic and cephalometric radiographic investigation of the orofacial muscular complex. *Am J Orthod.* 1960;46(8):627-8.
- Portney L. Eletromiografia e testes de velocidade de condução nervosa. In: Sullivan OS, Schmitz JT. *Fisioterapia: avaliação e tratamento.* São Paulo: Manole; 1993. p. 183-223.
- Pruzansky S. The application of electromyography to dental research. *J Am Dent Assoc.* 1952;44(1):49-68.
- Rasheed SA, Munshi AK. Electromyographic and ultrasonographic evaluation of the circum-oral musculature in children. *J Clin Pediatr Dent.* 1996;20(4):305-11.
- Sales RD, Vitti M. Análise eletromiográfica dos músculos orbiculares oris em indivíduos portadores de maloclusão Classe I, antes e após submetidos a tratamento ortodôntico. *Rev Assoc Paul Cir Dent.* 1979;33(5):399-411.
- Simpson M. An electromyographic investigation of the perioral musculature in Class II division 1 malocclusion. *Br J Orthod.* 1977;4(1):17-22.
- Sodeberg GL, Cook TM. Electromyography in biomechanics. *Phys Ther.* 1984;64(12):1813-20.
- Sodeberg GL, Knutson LM. A guide for use and interpretation of kinesiological electromyographic data. *Phys Ther.* 2000;80(5):485-98.
- Störmer K, Pancherz H. Electromyography of the perioral and masticatory muscles in orthodontic patients with atypical swallowing. *J Orofac Orthop.* 1999;60(1):13-23.

23. Tomé MC, Marchiori SC. Estudo eletromiográfico dos músculos orbiculares superior e inferior da boca em crianças respiradoras nasais e bucais durante o repouso com e sem contato labial. *J Bras Ortodon Ortop Facial*. 1998;3(15):59-66.
24. Tosello DO, Vitti M, Bérzin F. EMG activity of the orbicularis oris and mentalis muscles in children with malocclusion, incompetent lips and atypical swallowing – part I. *J Oral Rehabil*. 1998;25(11):838-46.
25. Tosello DO, Vitti M, Bérzin F. EMG activity of the orbicularis oris and mentalis muscles in children with malocclusion, incompetent lips and atypical swallowing – part II. *J Oral Rehabil*. 1999;26(8):644-9.
26. Tulley WJ. Methods of recording patterns of behavior of the oro-facial muscles using the electromyograph. *Dent Rec*. 1953;73:741-8.
27. Vianna MS. Análise eletromiográfica do músculo orbicular da boca em indivíduos com maloclusão Classe II, divisão 1 de Angle e modo respiratório predominantemente bucal ou nasal [dissertação]. Curitiba (PR): Pontifícia Universidade Católica do Paraná; 2002.
28. Vitti M, Basmajian JV. Muscles of mastication in small children: an electromyographic analysis. *Am J Orthod*. 1975;68(4):412-9.
29. Vitti M, Basmajian JV, Ouellette PL, Mitchell DL, Eastman WP, Seaborn RD. Electromyographic investigations of the tongue and circumoral muscular sling with fine-wire electrodes. *J Dent Res*. 1975;54(4):844-9.
30. Zilli AS. Estudo eletromiográfico dos músculos orbiculares da boca, segmentos superior e inferior (região medial), em jovens com maloclusão Classe I de Angle [dissertação]. Piracicaba (SP): Universidade Estadual de Campinas; 1994.

Submitted: August 16, 2007

Revised and accepted: August 6, 2009

---

**Contact address**

Vania C. V. Siqueira

Rua José Corder 87 - Jardim Modelo

CEP: 13.419-325 - Piracicaba / SP, Brazil

E-mail: [siqueira@fop.unicamp.br](mailto:siqueira@fop.unicamp.br)