



# Angle Class II malocclusion treated without extractions and with growth control

Maria Tereza Scardua\*\*

## Abstract

Angle Class II malocclusion is defined according to the anteroposterior molar relationship with or without a discrepancy between basal bones. Maxillary protrusion and mandibular retrusion are included in this pattern. When orthodontic treatment starts at an early age, it is possible to affect growth of both basal bones and the dentoalveolar region, which helps to correct tooth positioning in the corrective phase. This report describes the treatment of a case of Angle Class II, division 1 malocclusion that was presented to the Committee of the Brazilian Board of Orthodontics and Facial Orthopedics (BBO) as partial fulfillment of the requirements to obtain the BBO Diploma. The case was representative of category 1, that is, Angle Class II malocclusion treated without extractions and with growth control.

**Keywords:** Angle Class II malocclusion. Interceptive orthodontics. Corrective orthodontics.

## HISTORY AND ETIOLOGY

A white, 11-year-old girl presented for orthodontic treatment. She was in good general health and did not report any important disease or trauma. She had no oral sucking habits, and posture, swallowing and speech were normal.

She was in the mixed dentition and had a conoid lateral incisor (Figs 1 and 2). Her main complaints were the diastemas and the shape of maxillary incisors. She had not undergone any previous orthodontic treatment.

## DIAGNOSIS

The evaluation of facial features revealed a pleasing middle third, a short lower third height and a symmetrical face. She also had a very convex profile, mandibular retrusion and maxillary protrusion. The acute nasolabial angle and the oblique nasion perpendicular line reflected the maxillary involvement in malocclusion. At the same time, the everted lower lip, the deep mentolabial fold, the short mandibular line forming an open angle with the neck also indicated mandibular compromise (Fig 1).

\* Clinical case report, category 1, approved by the Brazilian Board of Orthodontics and Facial Orthopedics (BBO).

\*\* MSc, Temporomandibular Joint Disorders, Federal University of São Paulo. Specialist in Orthodontics, Bauru School of Dentistry, University of São Paulo. Diplomate, Brazilian Board of Orthodontics and Facial Orthopedics.

Lateral radiograph findings, morphological analysis and cephalometric measures confirmed the Class II skeletal pattern (ANB= 7°, SNA= 89°, and SNB= 82°). The horizontal planes and the morphological characteristics defined the patient's profile as brachyfacial. The vertical maxillary incisors (I-NA = 20°) and the mandibular incisors tipped buccally (I-NB= 32° and IMPA= 105.5°) confirmed the skeletal deficiency (Fig 4 and Table 1).

The patient had a Class II molar relationship, exaggerated 100% overbite and 6 mm overjet. She had diastemas in the maxillary and mandibular arches, a 1 mm deviation to the right from the maxillary midline, tooth # 26 was crossed and tooth # 12 had a conoid shape (Fig 2).

No third molars were seen on the panoramic radiograph (Fig 3).

## TREATMENT OBJECTIVES

The treatment should reduce the anteroposterior skeletal discrepancy and redirect mandibular growth, to restrict maxillary growth anteriorly, to retract maxillary molars and to increase vertical dentoalveolar growth to correct overbite. The extraoral appliance should also contribute to reposition tooth # 26.

These skeletal changes should decrease facial profile convexity, increase lower facial height and decrease the depth of the mentolabial fold.

The dentoalveolar objective was to obtain a molar relationship as the key to occlusion and to correct overbite, overjet and tight interproximal contacts. Maximal intercuspation (MI) with simultaneous bilateral contacts, small difference between centric relation (CR) and MI, and effective, mutually protected guidance and occlusion were also part of the treatment objectives.

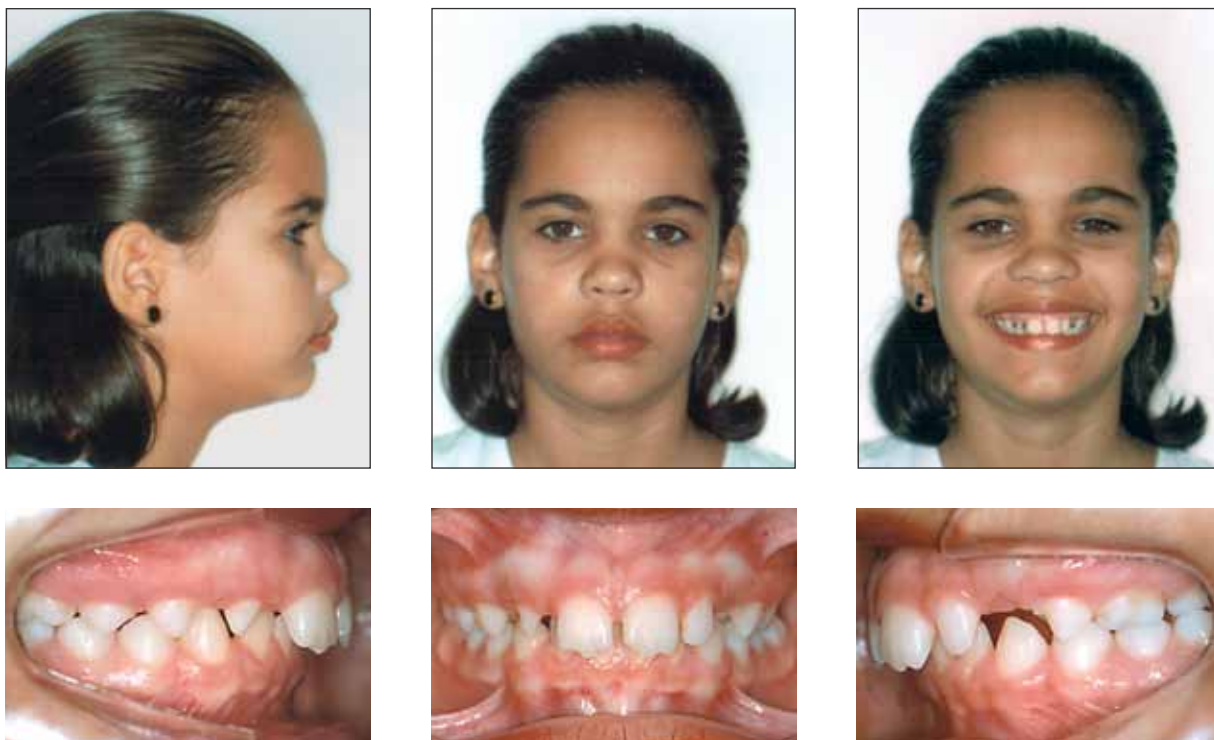


FIGURE 1 - Initial facial and intraoral photographs.

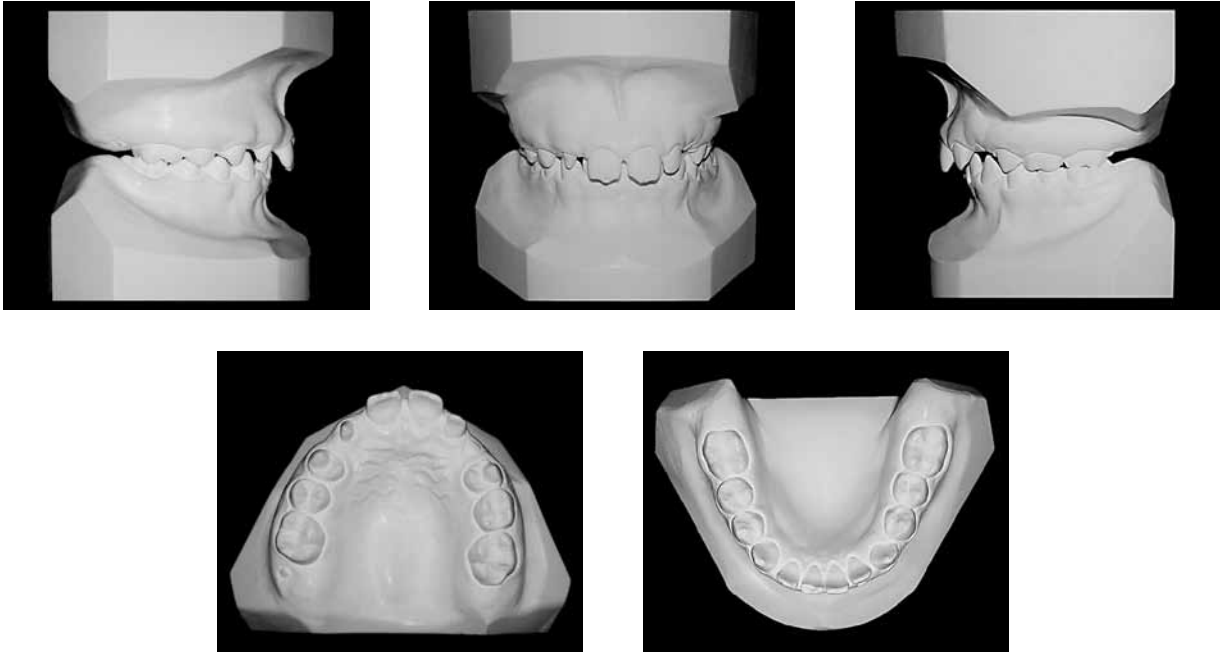


FIGURE 2 - Initial dental casts.

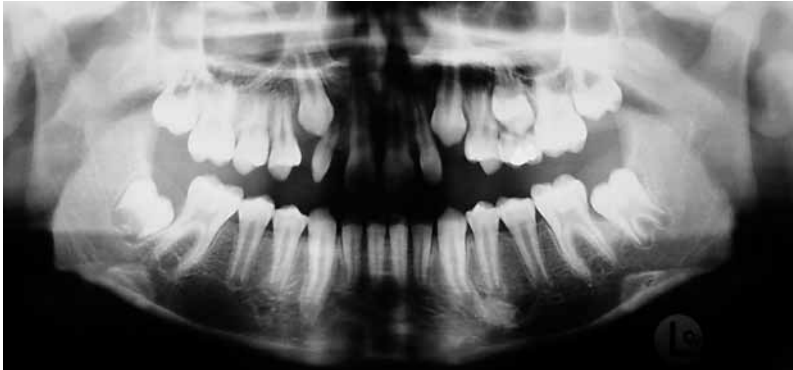

FIGURE 3 - Initial panoramic radiograph.

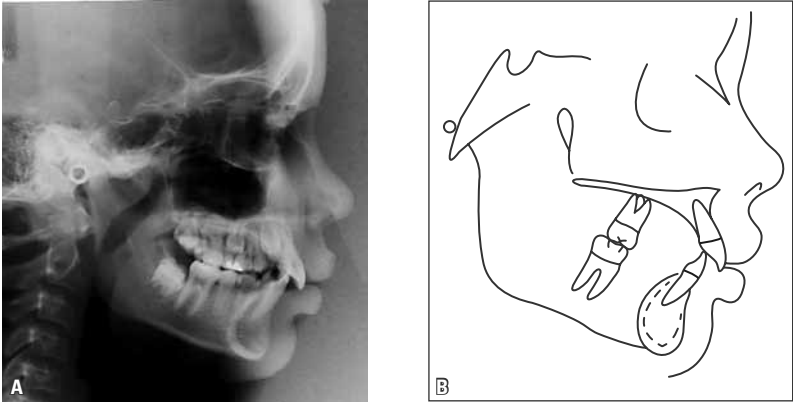


FIGURE 4 - Initial cephalometric profile radiograph (A) and cephalometric tracing (B).

## TREATMENT PLAN

Treatment should initiate with the placement of a Bionator and a Kloehn headgear. After correcting the skeletal discrepancy, the fixed maxillary and mandibular appliance should be placed together with 0.014-in to 0.020-in stainless steel archwires for alignment and leveling. After that, rectangular 0.019 X 0.025-in stainless steel archwires should be used to close residual spaces. Finally, individualized maxillary and mandibular rectangular 0.019 X 0.025-in stainless steel archwires should be used according to need.

Planned retention consisted of a maxillary wraparound clasp plate and, in the mandibular arch, a fixed retainer between teeth #33 and #43 fabricated with 0.032-in stainless steel wire.

After removal of the fixed appliance, the patient should be referred to a specialist for contouring of teeth # 12 and # 22.

### Treatment progression

As planned, the Bionator was placed. The acrylic plate was drilled in the region of the mandibular premolars to improve the curve of Spee and in the region of the maxillary molar for retraction due to the effect of the extraoral appliance. After some months, the occlusal acrylic plate was removed to increase posterior dentoalveolar growth and promote overbite correction. Treatment time was 14 months in this phase. However, for 18 months the Bionator was kept in the mouth so that the premolars reached full eruption and the alveolar process increased vertically, and perfect relationships as the key to occlusion. After full eruption of the second molars, the corrective phase began.

Metal brackets with 0.22 X 0.028-in slots were bonded using torque and angulations as prescribed by Andrews. Sequentially, round NiTi and stainless steel 0.014-in to 0.020-in archwires were placed for alignment and leveling. After that, upper and lower 0.019 X 0.025-in stainless steel archwires were placed. In the

maxilla, residual spaces were reduced and managed to correct the midline.

After the achievement of planned objectives, the fixed orthodontic appliance was removed for the placement of retainers. A removable plate with wraparound clasps was used for the maxilla. In the mandible, a fixed 0.032-in stainless steel intercanine bar was bonded to teeth # 33 and 43. The use of an upper retention plate for 24 hours a day for 6 months was recommended, followed by six more months of overnight use, at a total of 12 months. The use of the maxillary intercanine bonded retainer was recommended for an undetermined length of time.

## RESULTS

At the end of the treatment, the patient underwent diagnostic tests again. The results revealed that the orthopedic treatment changed the maxilla and the mandible. The objectives set for the treatment were achieved. The patient cooperated in wearing the appliances; maxillary growth was restricted with the use of extraoral anchorage, and the increase of mandibular growth was controlled, which resulted in a reduction of 5° in the ANB angle. The SNB angle increased 2.5° in consequence of the increase in mandibular length, whereas the vertical increase resulted in a decrease of the mandibular plane, with an increase in anterior and posterior face heights (Table 1, Figs 5, 6 and 8).

The superimposition of cephalometric tracings according to lateral radiographs of the face clearly showed that there was greater vertical than anteroposterior growth of the mandible (Fig 9). The use of a Bionator for a long time and the patient cooperation may have favored a more marked condylar growth, that is, forward and upward, which resulted in bone apposition on the lower border of the mandible and mesial movement of teeth in relation to the mandibular body.

The decrease of the mandibular plane resulted from the anticlockwise mandibular rotation, as well

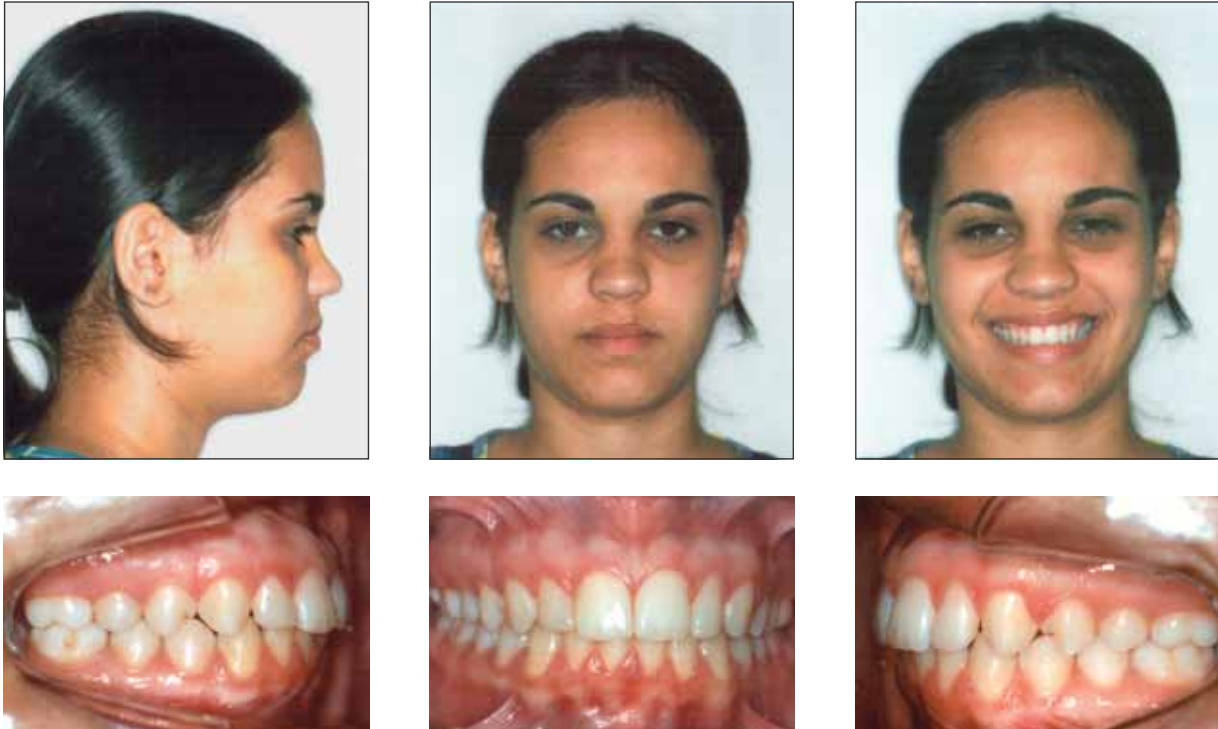

FIGURE 5 - Final facial and intraoral photographs.

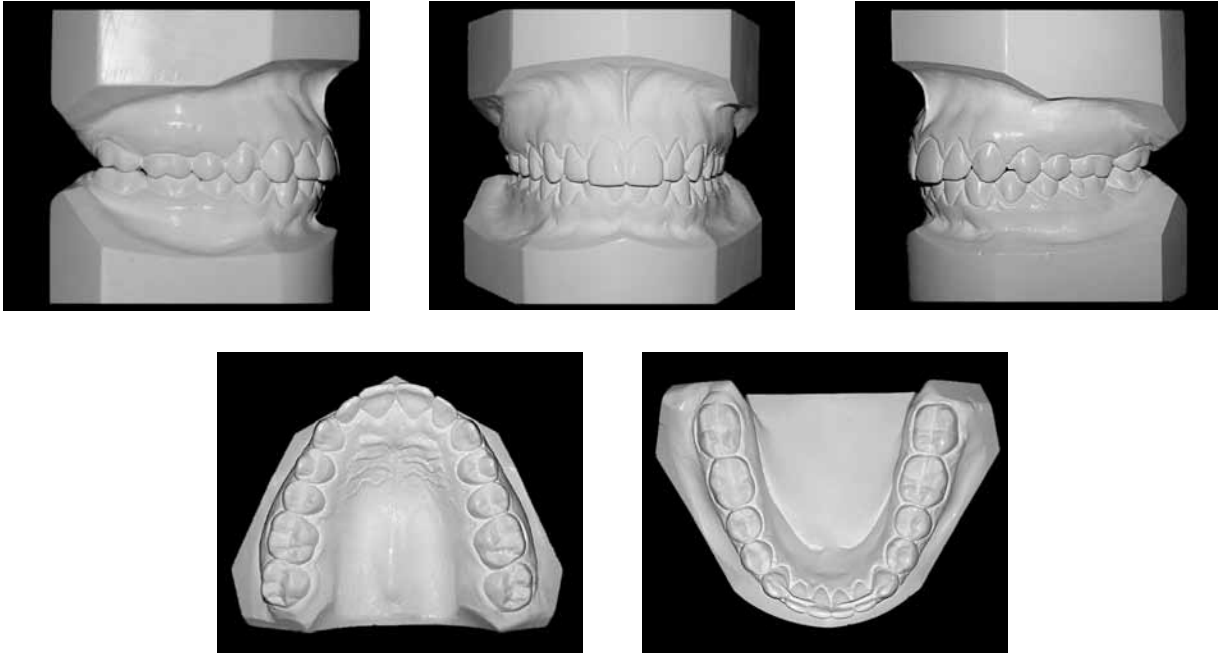


FIGURE 6 - Final dental casts.

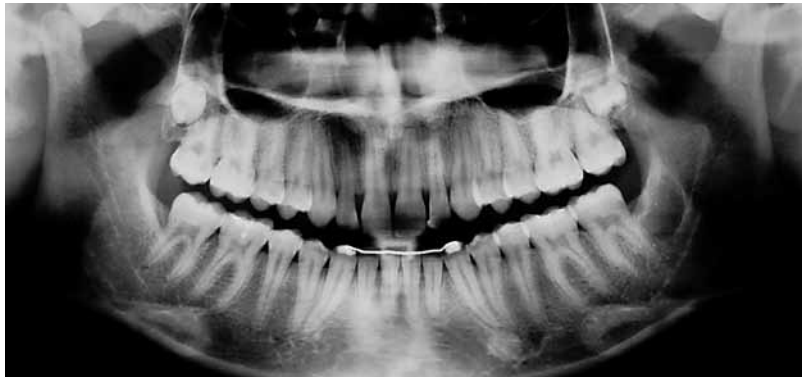

FIGURE 7 - Final panoramic radiograph.

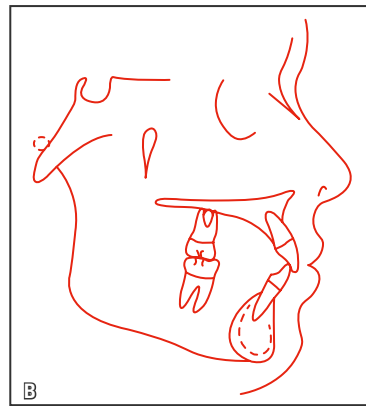
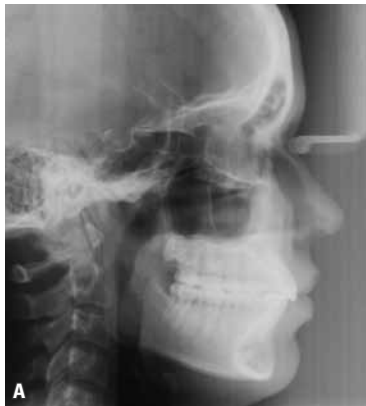

FIGURE 8 - Final cephalometric profile radiograph (A) and cephalometric tracing (B).

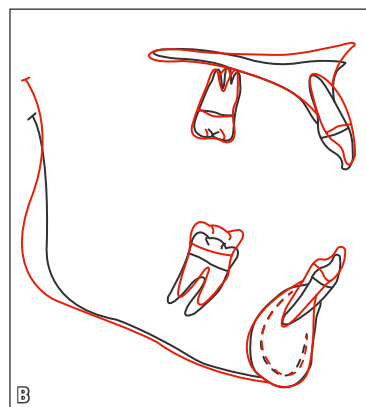
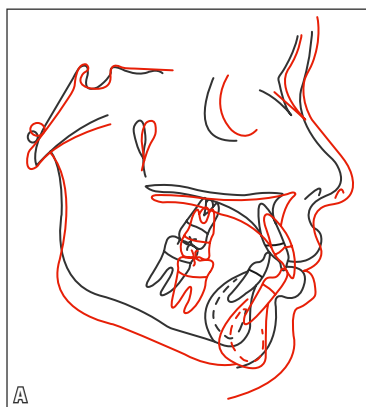


FIGURE 9 - Total (A) and partial (B) superimpositions of initial (black) and final (red) cephalometric tracings.

as from the direction of condylar growth. The superimposition of baseline and final tracings showed that there was substantial growth for the long time interval between baseline and final records.

The analysis of teeth revealed that maxillary incisors moved 7° buccally due to the tipping of canines according to Andrews' prescriptions (11°). Mandibular incisors kept their buccal tipping, which is common in patients with a mandibular deficiency. At the end of the treatment, there were well established molar, premolar and canine relationships as the keys to occlusion.

The analysis of facial features revealed a decrease in profile convexity and a greater height in the lower third of the face, which resulted in improvement of the mentolabial fold.

The clinical evaluation showed that the periodontium was healthy and had no occlusal pathologies; occlusion occurred with simultaneous bilateral contacts in MI and a very small difference between CR and MI, and satisfactory guidance was achieved.

The panoramic radiograph did not show any root resorption or periodontal lesions. The patient was referred to a specialist for the extraction of maxillary third molars (Fig 7).

The evaluation of results two years after treatment completion confirmed stability of results (Figs 10 – 14). Despite the frequent recommendations, the patient had not had the third molars extracted yet at the time when this report was prepared (Fig 12).

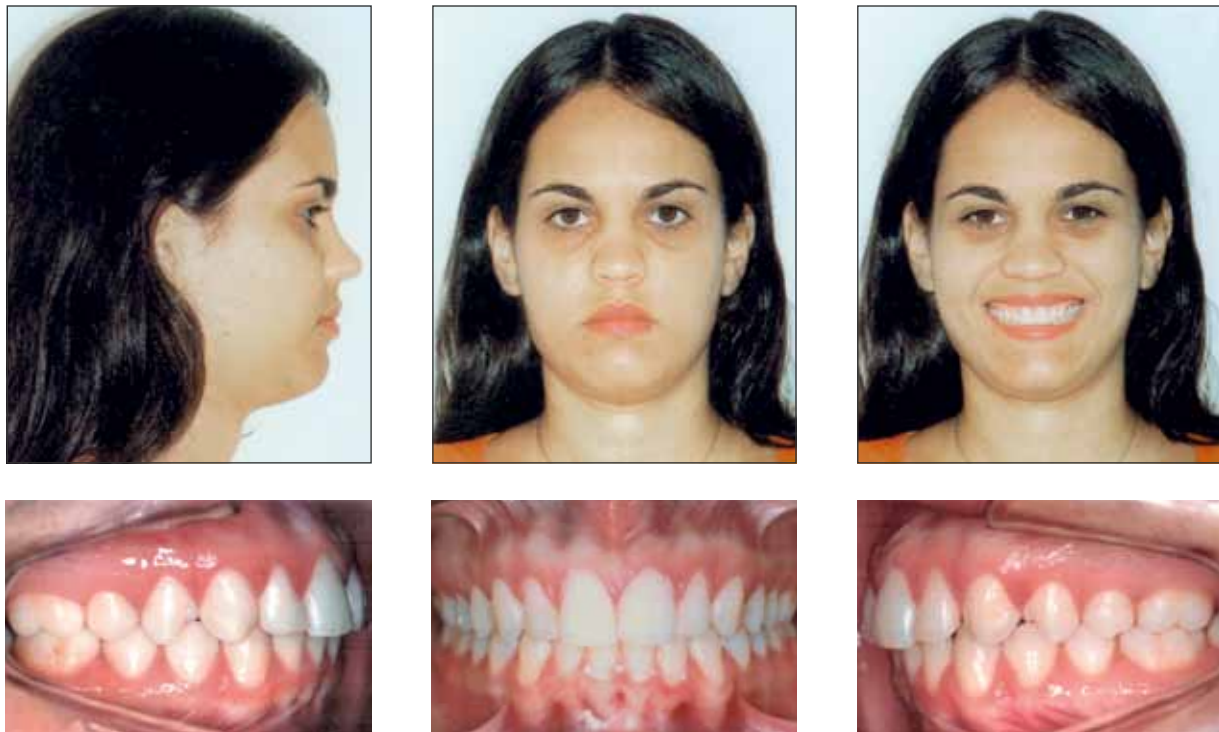

FIGURE 10 - Facial and intraoral photographs two years after treatment completion.

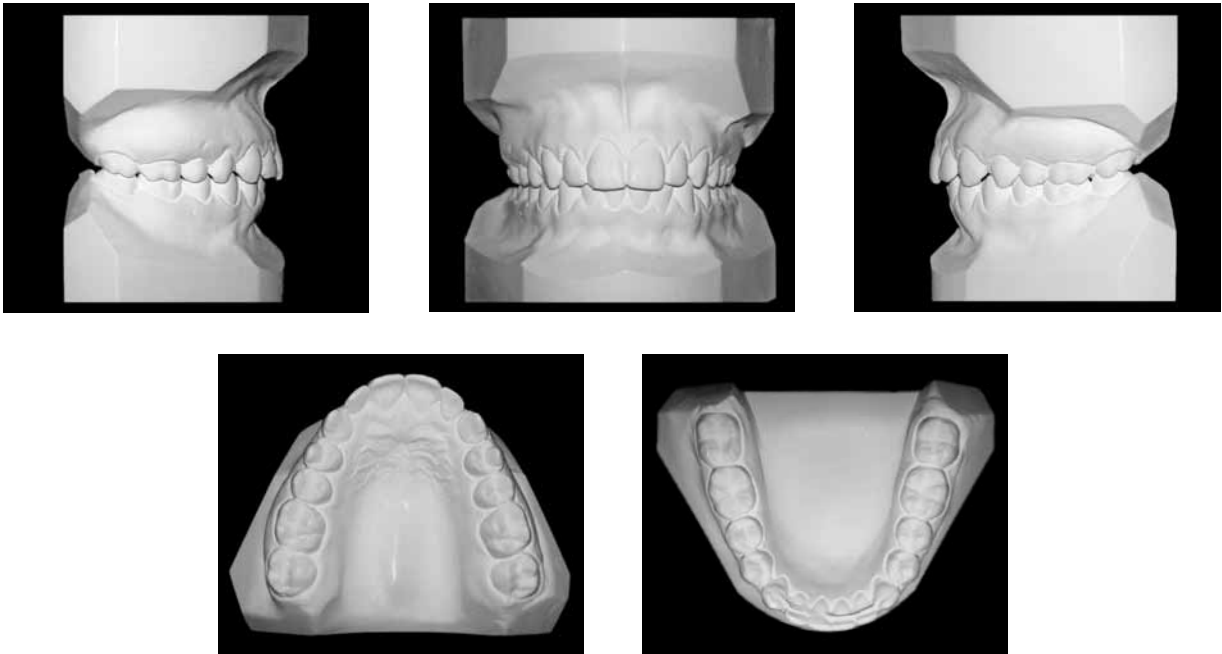


FIGURE 11 - Control dental casts two years after treatment completion.

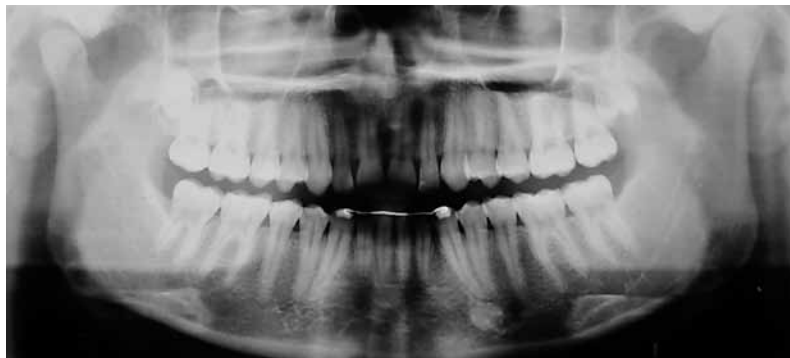

FIGURE 12 - Control panoramic radiograph two years after treatment completion.

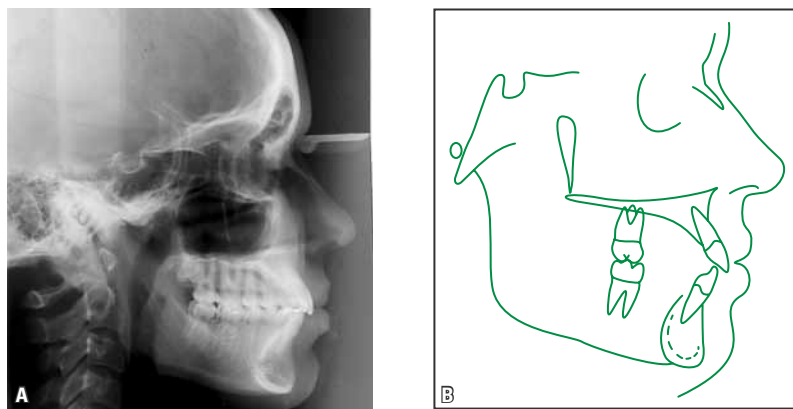


FIGURE 13 - Cephalometric profile radiograph (A) and cephalometric tracing (B) two years after treatment completion.



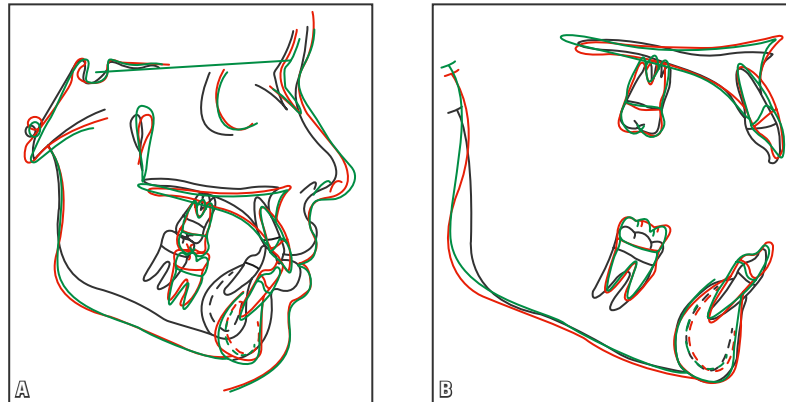


FIGURE 14 - Total (A) and partial (B) superimposition of cephalometric tracings at initial (black), at treatment completion (red) and two years after treatment (green).

TABLE 1 - Summary of cephalometric measurements.

		MEASUREMENTS	Normal	A	B	Difference A/B	C
Skeletal Pattern	SNA (Steiner)	82°	89°	86.5°	2.5	86.5°	
	SNB (Steiner)	80°	82°	84.5°	2.5	84.5°	
	ANB (Steiner)	2°	7°	2.5°	4.5	2.5°	
	Convexity Angle (Downs)	0°	13°	5.5°	7.5	5°	
	Y-Axis (Downs)	59°	62°	64°	2	63°	
	Facial Angle (Downs)	87°	83.5°	86.5°	3	86°	
	SN – GoGn (Steiner)	32°	23°	21°	2	19°	
	FMA (Tweed)	25°	22°	19°	3	18°	
Dental Pattern	IMPA (Tweed)	90°	105.5°	106°	2	105°	
	$\underline{1}$ – NA (°) (Steiner)	22°	20°	27°	7	26°	
	$\underline{1}$ – NA (mm) (Steiner)	4 mm	4 mm	5 mm	1	5 mm	
	$\bar{1}$ – NB (°) (Steiner)	25°	32°	32°	0	30°	
	$\bar{1}$ – NB (mm) (Steiner)	4 mm	5.5 mm	6 mm	0.5	5.5 mm	
	$\frac{1}{\bar{1}}$ – Interincisal Angle (Downs)	130°	121°	126°	5	127°	
	$\bar{1}$ – APo (mm) (Ricketts)	1 mm	0.5 mm	2 mm	1.5	2 mm	
Profile	Upper Lip – S Line S (Steiner)	0 mm	5 mm	0 mm	5	0.5 mm	
	Lower Lip – S Line (Steiner)	0 mm	4 mm	2 mm	2	2.5 mm	

## FINAL CONSIDERATIONS

Angle Class II malocclusions are defined according to the sagittal molar relationships, although basal bones are not always compromised. When they are, there may be abnormal sagittal positioning of the maxilla, mandible, or both. Sagittal abnormalities may also be found in basal bones regardless of the relationship between dental arches as a result of tooth compensation to the skeletal problem.<sup>1</sup>

Orthopedic interventions, both in the maxilla and in the mandible, are possible. In the maxilla, extraoral anchorage had its potential confirmed in a study with implants.<sup>3</sup> In the mandible, however, the effect of orthopedic treatment on growth is discrete, and clinical responses are dental rather than skeletal. In this sense, reports in the literature are greatly variable. Patients with a good facial pattern may positively contaminate samples and generate optimistic results. A study conducted by Tulloch et al<sup>4</sup> in 1997 brought important contributions to clarify this issue. Two groups were treated with orthopedic appliances, and a third was used as control. Both the treated groups and the controls had a similar variation in extension of growth, which led to the conclusion that the individual with the worst increase in the control group, even if treatment was provided, would probably not reach its group mean and would have less growth than the mean growth for the untreated group.

Another interesting study that made us think about orthopedic responses was the theory of facial growth mortgage. This theory suggests that facial growth obtained during treatment is an advancement of the total growth available to each patient. After treatment, patients do not keep the growth rate seen during the treatment and grow less than would be expected for them.<sup>5</sup>

The fact that we currently know the effects of

orthopedic appliances better and know that they are less significant for growth than previously imagined, does not reduce our interest in their use, but suggests a more realistic prognosis based on high quality scientific data.<sup>6</sup> Maybe it is possible to use patient growth not only to produce results, but also to correct malocclusion using the growth achieved during treatment.<sup>2</sup>

In this case, we chose to treat the Class II malocclusion using an extraoral KloeHN headgear and a Bionator. Our purpose was to obtain retraction of maxillary molars and anterior maxillary growth restriction, as well as the mandibular advancement and vertical dentoalveolar increases. Growth was an ally in the correction of malocclusion. Therefore, the maintenance of the existing dentoalveolar compensations and the treatment results were expected and contributed to malocclusion correction. The marked tipping and the already great mandibular incisors protrusion had an additional slight increase. This, however, was not a matter of concern, because the radiographs showed a good amount of bone on the buccal and lingual surfaces of the mandibular symphysis. Although different from mean values, incisors and facial structures are balanced in terms of shape and function.

The comparison of baseline and final tracings showed that there was substantial growth for the long time interval between baseline and final records. The use of a Bionator for a long time and patient cooperation may have favored a more marked condylar growth, as well as mesial movement of the teeth in relation to the mandibular body and protrusion of the incisors. These growth characteristics have been brilliantly described by Björk<sup>7</sup> in longitudinal studies.

The analysis of control records two years after treatment completion revealed that occlusion remained stable and that the facial appearance was very pleasing (Figs 10 – 14).

## REFERENCES

1. Capelozza Filho L. Individualização de braquetes na técnica de straight wire: revisão e sugestões de indicações para uso. *Rev Clín Ortod Dental Press*. 1999 jul-ago;4(4):87-106.
2. Capelozza Filho L. *Diagnóstico em Ortodontia*. 1ª ed. Maringá: Dental Press; 2004.
3. Melsen B. Effects of cervical anchorage during and after treatment: an implant study. *Am J Orthod*. 1978 May;73(5):526-40.
4. Tulloch JF, Phillips C, Koch G, Proffit WR. The effect of early intervention on skeletal pattern in Class II malocclusion: a randomized clinical trial. *Am J Orthod Dentofacial Orthop*. 1997 Apr;111(4):391-400.
5. Johnston LE Jr. Functional appliances: a mortgage on mandibular position. *Aust Orthod J*. 1996 Oct;14(3):154-7.
6. Scardua MT, Januzzi E, Grossmann E. Ortodontia baseada em evidência científica: incorporando ciência na prática clínica. *Rev Dental Press Ortod Orthop Facial*. 2009 maio-jun;14(3):107-13.
7. Björk A. Variations in the growth pattern of the human mandible: longitudinal radiographic study by the implant method. *J Dent Res*. 1963 Jan-Feb;42(1)Pt 2:400-11.
8. Björk A, Skieller V. Facial development and tooth eruption: an implant study at the age of puberty. *Am J Orthod*. 1972 Oct;62(4):339-83.

Submitted: December 2010  
Revised and accepted: March 2011

---

### Contact address

Maria Tereza Scardua  
Rua Chapot Presvot, 100/801 Praia do Canto  
CEP: 29.055-410 – Vitória / ES, Brazil  
E-mail: maria@terezascardua.com.br