

Assessment of the accuracy of cephalometric prediction tracings in patients subjected to orthognathic surgery in the mandible

Thallita Pereira Queiroz*, Jéssica Lemos Gulinelli**, Francisley Ávila Souza***, Liliane Scheidegger da Silva Zanetti****, Osvaldo Magro Filho*****, Idelmo Rangel Garcia Júnior*****, Eduardo Hochuli Vieira*****

Abstract

Objective: The purpose of this study was to assess the accuracy of cephalometric prediction tracings—performed for orthognathic surgery—by means of the cephalometric analysis of preoperative and seven-day postoperative tracings, in patients subjected to correction of mandibular deformities. **Methods:** The lateral cephalograms of 17 patients who had been submitted to mandibular orthognathic surgery, three years earlier, were used. Cephalometric tracings were performed in the preoperative and seven-day postoperative periods and the following landmarks were traced: condyle (Co), pogonion (Pog), gonial (Go), menton (Me), B (B) and incisor (I). The analysis was based on the difference obtained by superimposing preoperative, prediction and postoperative tracings. The landmarks were projected onto a Cartesian plane for measuring distances between points in millimeters. The data were statistically analyzed using the paired Student t test ($\alpha = 0.05$). **Results:** A statistically significant mean difference was observed between the planned change and the change effectively achieved in the postoperative cephalometric tracings for points Pog ($p = 0.014$) and I ($p = 0.008$) on the horizontal axis. No statistically significant difference was found for the aforementioned cephalometric points on the vertical axis ($p > 0.05$). **Conclusions:** Cephalometric prediction tracings contributed to the preoperative evaluation of the patients and consequently to treatment optimization. However, they was not entirely reliable in these cases due to a slight underestimation of horizontal skeletal changes. These changes should be considered in planning and postoperative follow-up of patients subjected to orthognathic surgery in the mandible.

Keywords: Surgery. Cephalometry. Mandible.

* MSc and PhD in Oral and Maxillofacial Surgery and Traumatology, School of Dentistry, Araçatuba - UNESP. Professor of the disciplines of Oral and Maxillofacial Surgery and Traumatology I and II, University Center of Araraquara - UNIARA.

** MSc and PhD in Oral and Maxillofacial Surgery and Traumatology, School of Dentistry, Araçatuba - UNESP.

*** MSc and PhD candidate in Oral and Maxillofacial Surgery and Traumatology, School of Dentistry, Araçatuba - UNESP.

**** MSc in Oral and Maxillofacial Surgery and Traumatology, School of Dentistry, Piracicaba - UNICAMP. PhD in Oral and Maxillofacial Surgery and Traumatology, School of Dentistry, Araçatuba - UNESP.

***** Adjunct Professor, Department of Surgery and Integrated Clinic, Discipline of Oral and Maxillofacial Surgery and Traumatology, School of Dentistry, Araçatuba, UNESP.

***** Adjunct Professor, Department of Diagnosis and Surgery, Discipline of Oral and Maxillofacial Surgery and Traumatology, School of Dentistry, Araraquara, UNESP.

INTRODUCTION

Correction of dentofacial deformities often requires a combination of orthodontic and surgical treatment to produce functional benefits, proper occlusion and masticatory function, in addition to positive psychosocial and aesthetic changes.^{3,13} The desire to improve facial appearance is a strong motivating factor in seeking treatment. Therefore, the ability to predict treatment outcome is essential.⁵

To establish a correct diagnosis and treatment plan for orthognathic surgery it is of paramount importance to combine a patient's clinical evaluation, model analysis, facial analysis, cephalometric study and model surgery.^{12,19,23} Although cephalometric analysis is a fundamental tool for diagnosis confirmation, it is not the only source of information worthy of evaluation. Facial aesthetics and occlusion must be analyzed together with cephalometry if a correct diagnosis and appropriate treatment plan are to be reached.²⁰

One crucial factor in the clinical protocol consists in the prediction of surgical procedures to assess their suitability for treatment and conduct optimization in each case. Cephalometric prediction tracings (CPTs) enable the study of profile changes, extraction planning and the necessary orthodontic changes. CPTs can also be used to assess treatment progress and stability of the surgical procedures in the postoperative follow-up period, allowing patients to become aware of the proposed treatment and expected outcome, thereby empowering them to provide enhanced compliance.^{7,15}

Friede et al⁹ found that the most complex surgical procedures were also the most difficult to predict and concluded that the usefulness of CPTs depends on the clinical ability to follow detailed planning.

Gjorup and Athanasiou¹⁰ asserted that CPTs allow prior consideration of the various treatment options, access to information on planned chang-

es and the psychological preparation of patients. Cephalometric analysis provides both examination and clinical implementation for the study of skeletal disproportion and malocclusions.¹⁶ In soft tissues, the quantification of movement is associated with decreased accuracy.²

By using a cephalometric study it is possible to compare CPTs with cephalometric tracings obtained in the immediate postoperative period, which allows consistency to be verified between planned outcome and achieved outcome in the immediate surgical treatment.

OBJECTIVE

The purpose of this study was to assess the reliability of cephalometric prediction tracings performed for orthognathic surgery by means of cephalometric analysis of preoperative and seven-day postoperative periods, in patients subjected to correction of mandibular deformities.

MATERIAL AND METHODS

The sample consisted of 17 adult patients, aged between 22 and 45 years, who had undergone orthognathic surgery in the mandible 3 years earlier, i.e., 12 mandibular advancement cases (ranging from 3 mm to 7 mm, with a mean advancement of 5.4 mm) and 5 mandibular setback cases (ranging from 3 mm to 10 mm, with a mean setback of 5.2 mm). These patients were treated at the Center for Research and Treatment of Orofacial Deformities (CEDEFACE, Araraquara, São Paulo, Brazil). The study included CPTs and lateral cephalograms of preoperative and seven-day postoperative periods. All radiographs were taken with the same radiographic unit (Funk Orbital X-15). The treatment of these patients involved prior orthodontic preparation and the surgical technique consisted of bilateral sagittal split osteotomy of the mandibular ramus associated with rigid internal fixation for

mandibular advancement or setback.

A single surgeon drew each cephalogram manually in random sequence on the acetate sheet over each of the 34 lateral cephalograms as well as the CPTs. Light intensity was controlled by means of black cardboard placed as a mask over the radiographs so that low-contrast structures could be conveniently viewed. A light box—under adequate light conditions—was used during cephalometric tracing.

A standardized cephalometric tracing method was used with two reference lines, one horizontal (HL) and one vertical (VL), illustrated in Figure 1, based on studies by Phillips et al.¹⁷ and Watzke et al.²⁴ Thus, the horizontal line was defined as a line traced six degrees below the sella-nasion line (SN), which corresponded to the X coordinate and the vertical reference line was defined as a line perpendicular to the horizontal line passing through sella, which corresponded to the Y coordinate.

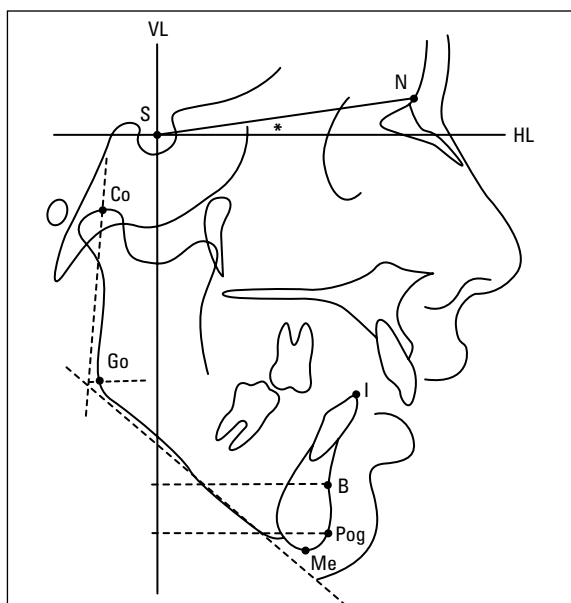


FIGURE 1 - Schematic illustration of cephalometric tracing showing the cephalometric landmarks analyzed in this study and the horizontal and vertical reference lines that correspond to the X and Y coordinates, respectively (* = 6 degrees).

The following cephalometric landmarks were traced (Fig 1): Condyle = Co (posterior superior-most point of the condylar head); Pogonion = Pog (anterior-most point of the contour of the chin in the sagittal plane); Gonial = Go (point where the bisector of the angle between the tangent to the posterior edge of the ramus and the tangent to the lower limit of the body of the mandible intercepts the mandibular contour); Sella = S (geometric center of the sella turcica); Nasion = N (meeting point between the suture of the frontal bone with the nasal bones); Menton = Me (inferior-point of the contour of the mandibular symphysis); Point B = B (deepest point of the anterior concavity of the mandibular symphysis); Incisive = I (point on the incisal edge of the lower central incisor).

For assessment, these cephalometric points were projected for the preoperative, prediction and seven-day postoperative tracings with the aid of a try square, for both the X and Y coordinates (HL and VL, respectively), enabling the evaluation of changes in each stage. The distance from the landmarks to the coordinates was measured with the aid of a pair of compasses and a millimeter ruler so that linear, perpendicular measurements were obtained for each operative time. Changes were calculated based on the differences between the values obtained in the preoperative tracing and the CPT, in the CPT and the postoperative tracing, and pre- and postoperative tracings, for all landmarks.

CPTs were compared with the corresponding change analyses resulting from treatment and the results were tabulated and analyzed using the Kolmogorov-Smirnov test. As it was found that the values were normally distributed, they were compared using the paired t test ($p < 0.05$). Thus, CPT accuracy was assessed by eliminating the potential interference of angular measurements.

TABLE 1 - Results of the difference between the horizontal position of cephalometric points evaluated in the preoperative stage, and the postoperative and cephalometric prediction tracings (results in mm, SD = standard deviation, CPT = cephalometric prediction tracing).

	B		I		Pog		Me	
	Postop.	CPT	Postop.	CPT	Postop.	CPT	Postop.	CPT
Mean	0.6	1.6	-0.4	1.5	0.4	0.8	-0.2	1.1
SD	3.4	4.0	3.9	3.9	3.6	4.8	3.4	4.1
Minimum	-5	-5	-7	-5	-8	-7	-6	-5
Maximum	8	7	6	7	6	9	6	7

TABLE 2 - Results of the difference between the vertical position of cephalometric points evaluated in the preoperative stage and the postoperative and cephalometric prediction tracings (results in mm, SD = standard deviation, CPT = cephalometric prediction tracing).

	B		I		Pog		Me	
	Postop.	CPT	Postop.	CPT	Postop.	CPT	Postop.	CPT
Mean	-0.6	-0.1	0.6	0.2	0.7	1.1	1.0	0.6
SD	3.9	4.4	4.2	5.2	3.2	4.8	3.8	5.1
Minimum	-7	-9	-7	-12	-6	-11	-8	-13
Maximum	6	6	6	8	6	9	6	10

TABLE 3 - Means and standard deviations (in mm) obtained from the difference between the cephalometric points assessed in cephalometric prediction tracings and postoperative tracings on the horizontal and vertical axes (CPT = cephalometric prediction tracing).

Axes (planes)	Cephalometric points CPT/Postoperative	Mean	SD	95% confidence interval		Significance
Horizontal	Point I	-1.82	2.48	-3.09	-0.54	0.008*
	Point B	-1.00	2.57	-2.32	0.32	0.129
	Point Pog	-1.29	1.92	-2.28	-0.30	0.014*
	Point Me	-0.47	3.12	-2.07	1.13	0.543
Vertical	Point I	0.47	2.34	-0.73	1.67	0.421
	Point B	-0.58	2.87	-2.06	0.88	0.411
	Point Pog	0.41	2.93	-1.09	1.92	0.571
	Point Me	-0.41	2.80	-1.85	1.03	0.554

*Statistical significance.

RESULTS

Changes were calculated for the differences between the values obtained in the preoperative tracing and the CPT, in the CPT and the postoperative tracing, and in the pre- and post-operative tracings, for all landmarks, marked on the horizontal and vertical planes (Tables 1 and 2) and no statistical difference was found

in mean values between the planned change (CPT) and the change effectively achieved in the postoperative cephalometric tracings for points Pog and I on the horizontal axis ($p = 0.014$ and $p = 0.008$, respectively). Table 3 represents the mean, standard deviation, confidence interval (95%) and statistical significance ($\alpha = 5\%$) after comparing the CPTs and

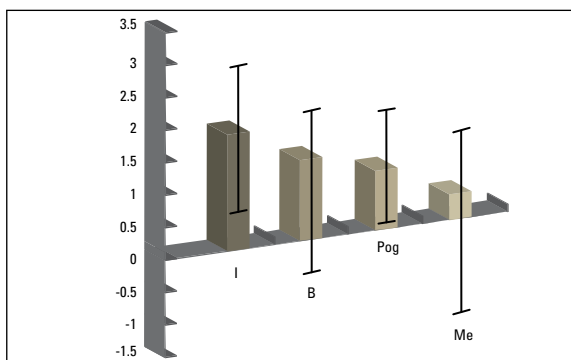


FIGURE 2 - Mean difference (in mm) between planned changes and changes effectively achieved in the cephalometric tracings on the horizontal axis. Error bars represent confidence intervals at 95%.

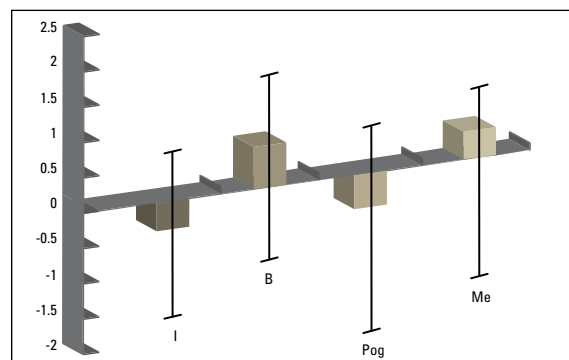


FIGURE 3 - Mean difference (in mm) between planned changes and changes effectively achieved in cephalometric tracings on the vertical axis. Error bars represent confidence intervals at 95%.

postoperative tracings for points I, B, Pog and Me on the horizontal and vertical axes, considering the changes observed in all 17 patients.

Figures 2 and 3 show the mean difference (in mm) between the planned changes and the changes effectively achieved in the cephalometric tracings on the horizontal and vertical axes.

DISCUSSION

Sample selection, in studies that involve humans, is crucial for increasing CPT uniformity and accuracy.^{5,22} In the present study the sample consisted of patients who had undergone surgical-orthodontic treatment, including correction of retrognathia or mandibular prognathism using bilateral sagittal osteotomy of the mandibular ramus. This technique was described by Trauner and Obwegeser²¹ and was later improved, modified^{4,6} and with the use of rigid internal fixation became a technique that provides adequate stability and outcome.¹⁸

A seven-day postoperative analysis was performed as considerable postoperative complications may occur after satisfactory accommodation of soft tissues and regression of the edema.^{1,8} The need was therefore felt

to evaluate the recent postoperative period. Hack et al¹¹ evaluated the stability of postsurgical patients who had undergone orthognathic surgery and found that the most significant changes in soft tissue took place in the first year after surgery.

Among the steps in planning for orthognathic surgery, preoperative cephalometric tracings and CPTs are noteworthy and should be performed with accuracy since, when associated with facial analysis and model surgery, both contribute greatly to the information necessary for planning surgery.

Cephalometric analysis, among other purposes, allows us to assess whether tooth inclination is correct with respect to bony bases, or whether facial height requires correction. In addition, by providing the thickness of the bone plate it helps in determining the most appropriate osteotomy to be performed. Nevertheless, cephalometry should be seen as a complementary diagnostic method which, in conjunction with facial analysis, CPT and model surgery, help to determine planning.²³

This study revealed, among other findings, that CPTs contributed to patient evaluation

and treatment optimization. In performing CPTs, surgeons can determine the direction and amount of the surgical procedures to be carried out, based on the patients' facial features and chief complaint. Kiyak et al¹⁴ claimed that if a surgeon achieves in surgery the same results predicted in the CPT, the patient's chief complaint will be resolved.

In this study, CPT accuracy was not absolute as it showed a slight tendency towards underestimating horizontal skeletal changes. The reason may lie in the fact that tracings were performed manually and were therefore error-prone. Eckhardt and Cunningham,⁵ after comparing computerized with manually performed tracings of patients who had undergone surgical correction of mandibular deformities, concluded that there were significant differences in the accuracy of both tests. This finding confirms the high predictability of manual tracings when we are confronted with lower third of the face correction. Horizontal skeletal changes should be taken into account in planning and postoperative follow-up of patients subjected

to orthognathic surgery in the mandible, especially in the long term, since a lack of stability may compromise future results.

Planning for the correction of dentofacial deformities is a challenge in the field of orthognathic surgery. The aesthetic demands of patients further increases dental surgeons' responsibility. When planning these surgeries surgeons should therefore ensure that each procedure is performed carefully so that the desired results are achieved. Further research is needed to increase CPT accuracy and provide a deeper understanding of the changes most often associated with these tracings.

CONCLUSIONS

CPTs contributed to the preoperative evaluation of the patients and consequently to treatment optimization. However, they were not entirely reliable in these cases due to a slight underestimation of horizontal skeletal changes. These changes should be considered in planning and postoperative follow-up of patients subjected to orthognathic surgery in the mandible.

REFERENCES

- Bell WH. Modern practice in orthognathic and reconstructive surgery. Philadelphia: W. B. Saunders; 1992.
- Burstone CJ, James RB, Legan H, Murphy GA, Norton LA. Cephalometrics for orthognathic surgery. *J Oral Surg.* 1978 Apr;36(4):269-77.
- Cousley RR, Grant E. The accuracy of preoperative orthognathic predictions. *Br J Oral Maxillofac Surg.* 2004 Apr;42(2):96-104.
- Dal Pont G. Retromolar osteotomy for the correction of prognathism. *J Oral Surg Anesth Hosp Dent Serv.* 1961 Jan;19:42-7.
- Eckhardt CE, Cunningham SJ. How predictable is orthognathic surgery? *Eur J Orthod.* 2004;26(3):303-9.
- Epker BN. Modifications in the sagittal osteotomy of the mandible. *J Oral Surg.* 1977 Feb;35(2):157-9.
- Fish LC, Epker BN. Surgical-orthodontic cephalometric prediction tracing. *J Clin Orthod.* 1980 Jan;14(1):36-52.
- Fonseca RJ. Oral and maxillofacial surgery: orthognathic surgery. Philadelphia: W.B. Saunders; 2000. v. 2.
- Friede H, Kahnberg KE, Adell R, Ridell A. Accuracy of cephalometric prediction in orthognathic surgery. *J Oral Maxillofac Surg.* 1987 Sep;45(9):754-60.
- Gjorup H, Athanasiou AE. Soft tissue and dentoskeletal profile changes associated with mandibular setback osteotomy. *Am J Orthod Dentofacial Orthop.* 1991 Oct;100(4):312-23.
- Hack GA, Mol van Otterloo JJ, Nanda R. Long term stability and prediction of soft tissue changes after Le Fort I surgery. *Am J Orthod Dentofacial Orthop.* 1993 Dec;104(6):544-55.
- Hindi EC, Kent JN. Tratamiento quirúrgico de las anomalías de desarrollo de los maxilares. Barcelona: Editorial Labor; 1974.
- Hoffman GR, Staples G, Moloney FB. Cephalometric alterations following facial advancement surgery 2. Clinical and computadorised evaluation. *J Craniomaxillofac Surg.* 1994 Dec;22(6):371-5.
- Kiyak HA, Vitaliano PP, Crinean J. Patient's expectations as predictors of orthognathic surgery outcomes. *Health Psychol.* 1988;7(3):251-68.
- Loh S, Heng IK, Ward-Booth P, Winchester L, McDonald F. A radiographic analysis of computer prediction in conjunction with orthognathic surgery. *Int J Oral Maxillofac Surg.* 2001 Aug;30(4):259-63.
- Matheus NCP, Gerhardt OM, Costa NP, Caminha JAN, Lorandi CS, Rizzato RD. Correlações matemáticas entre dimensões esqueléticas lineares transversais obtidas de análise cefalométrica computadorizada a partir de telerradiografias em norma frontal. *Rev Odonto Ciência.* 1994;9(18):67-79.
- Phillips C, Turvey TA, McMillian A. Surgical orthodontic correction of mandibular deficiency by sagittal osteotomy: clinical and cephalometric analysis of 1-year data. *Am J Orthod Dentofacial Orthop.* 1989 Dec;96(6):501-6.
- Proffit WR, Turvey TA, Phillips C. Orthognathic surgery: a hierarchy of stability. *Int J Adult Orthodon Orthognath Surg.* 1996;11(3):191-204.
- Satrom KD, Sinclair PM, Wolford LM. The stability of double jaw surgery: a comparison of rigid versus wire fixation. *Am J Orthod Dentofacial Orthop.* 1991 Jun;99(6):550-63.
- Suguino R, Ramos AL, Terada HH, Furquim LZ, Maeda L, Silva OG Filho. Análise facial. *Rev Dental Press Ortod Ortop Maxilar.* 1996 set-out;1(1):86-107.
- Trauner R, Obwegeser H. The surgical correction of mandibular prognathism and retrognathia with consideration of genioplasty. I. Surgical procedures to correct mandibular prognathism and reshaping of the chin. *Oral Surg Oral Med Oral Pathol.* 1957 Jul;10(7):677-89.
- Veltkamp T, Buschang PH, English JD, Bates J, Schow SR. Predicting lower lip and chin response to mandibular advancement and genioplasty. *Am J Orthod Dentofacial Orthop.* 2002 Dec;122(6):627-34.
- Vig KD, Ellis E 3rd. Diagnosis and treatment planning for the surgical-orthodontic patient. *Dent Clin North Am.* 1990 Apr;34(2):361-84.
- Watzke IM, Turvey TA, Phillips C, Proffit WR. Stability of mandibular advancement after sagittal osteotomy with screw or wire fixation: a comparative study. *J Oral Maxillofac Surg.* 1990 Feb;48(2):108-21.

Submitted: November 2007
Revised and accepted: February 2010

Contact address

Thallita Pereira Queiroz
Rua: Voluntários da Pátria, número 1401, apto 91,
CEP: 14.801-320 – Centro, Araraquara / SP, Brazil
E-mail: thaqueiroz@hotmail.com