

Transverse effects of rapid maxillary expansion in Class II malocclusion patients: A Cone-Beam Computed Tomography study

Carolina Baratieri*, Lincoln Issamu Nojima**, Matheus Alves Jr.***, Margareth Maria Gomes de Souza****, Matilde Gonçalves Nojima*****

Abstract

Objective: The aim of this study was to evaluate by Cone-Beam Computed Tomography (CBCT) transversal responses, immediately and after the retention period, to rapid maxillary expansion (RME), in Class II malocclusion patients. **Methods:** Seventeen children (mean initial age of 10.36 years), with Class II malocclusion and skeletal constricted maxilla, underwent Haas' protocol for RME. CBCT scans were taken before treatment (T1), at the end of the active expansion phase (T2) and after the retention period of six months (T3). The scans were managed in Dolphin software, where landmarks were marked and measured, on a coronal slice passing through the upper first molar. The paired Student's t-test was used to identify significant differences ($p < 0.05$) between T2 and T1, T3 and T2, and T3 and T1. **Results:** Immediately after RME, the mean increase in maxillary basal, alveolar and dental width was 1.95 mm, 4.30 mm and 6.89 mm, respectively. This was accompanied by buccal inclination of the right (7.31°) and left (6.46°) first molars. At the end of the retention period, the entire transverse dimension increased was maintained and the dentoalveolar inclination resumed. **Conclusions:** The RME therapy was an effective procedure to increase transverse maxillary dimensions, at both skeletal and dentoalveolar levels, without causing inclination on anchorage molars in Class II malocclusion patients with skeletal constricted maxilla.

Keywords: Rapid maxillary expansion. Transverse effects. Cone-Beam Computed Tomography. Class II malocclusion.

* DDS; MS; PhD Student, Department of Orthodontics, School of Dentistry, Federal University of Rio de Janeiro, Brazil.

** DDS; MS; PhD Associate Professor, Department of Orthodontics, School of Dentistry, Federal University of Rio de Janeiro, Brazil.

*** DDS; MS; PhD Student, Department of Orthodontics, School of Dentistry, Federal University of Rio de Janeiro, Brazil.

**** DDS; MS; PhD Associate Professor, Department of Orthodontics, School of Dentistry, Federal University of Rio de Janeiro, Brazil.

***** DDS; MS; PhD Associate Professor, Department of Orthodontics, School of Dentistry, Federal University of Rio de Janeiro, Brazil.

INTRODUCTION

Class II Division 1 malocclusions are strongly related to transverse problems, presenting a significantly reduced maxillary width when compared to normal occlusion.^{2,22,25,26} However, its diagnosis is often passed unnoticed at clinical examination as transverse deficiency is camouflaged by the Class II skeletal pattern itself. The upper teeth occlude in a more anterior region of the mandible, showing an apparent normal transverse development, even in the presence of maxillary transverse deficiency.²⁸ Upper molars tend to incline buccally to compensate the insufficient skeletal and alveolar base. For this reason, rapid maxillary expansion (RME) may be considered before treating Class II Division 1 malocclusion patients.²⁶

RME has been the treatment chosen by many orthodontists for correction of skeletal maxillary constriction in growing patients.^{10,11} The key feature of RME is that the force applied to the teeth and alveolar processes by activating the expander screw promotes the opening of the midpalatal suture. The stability of the new transverse dimension is also a fundamental part of the treatment, which turns the retention phase as important as the active phase,¹⁵ with the expander appliance having to remain in place for at least three months.¹³ The Haas expander appliance is widely used in orthodontics because its screw is covered by an acrylic block that enhances the contact with the lateral walls of palate, thus increasing the anchorage, improving the orthopedic effect, and decreasing tooth movement.¹¹

Until recently, frontal cephalometric radiographs were the most precise methods for evaluating the transverse effects of RME. However, the difficulties inherent to the technique not always allowed the precise location and identification of craniofacial structures. With the use of the Cone-Beam Computed Tomography (CBCT) images, not only a three-dimensional visualization of the whole craniofacial complex is possible, but also precise and reliable

measurements of the changes caused by RME, since there is neither image superposition nor size distortion.⁸

Despite the numberless articles on rapid maxillary expansion effects,^{12,15,24} the literature is still scarce in studies evaluating only the results from the expander appliance in Class II malocclusion patients. The objective of the present study was to evaluate, using CBCT, the dental and skeletal transverse effects of rapid maxillary expansion immediately and after a retention period, with Haas expander appliance in Class II malocclusion patients.

MATERIAL AND METHODS

This prospective clinical study was performed at the Department of Orthodontics of the Federal University of Rio de Janeiro after being approved by the research ethics committee of the Institute of Collective Health Studies (0052.0.239.000-09). Seventeen children (8 boys and 9 girls with mean ages of 10.67 and 10.05 years, respectively) presenting Class II, Division 1 malocclusion and skeletal transverse deficiency were selected for the study.

The inclusion criteria were: ages between 7-12 years; Class II molar (unilateral or bilateral) and skeletal ($ANB \geq 4^\circ$)²¹ relationship; maxillary skeletal transverse deficiency (distance from J point to facial frontal line > 12 mm);²⁰ and stage before pubertal growth spurt.⁶

Even not being an exclusion criterion, none of the patients had visible posterior crossbite. The transverse problem was first evaluated clinically and diagnosed as atresia, when the patient projected the mandible until a Class I relationship, and the posterior relationship was edge to edge or in crossbite.¹⁶

All patients were submitted to RME protocol established by Haas for patients younger than 14 years of age.^{11,13} The appliances were standardized by 0.047-in stainless steel wire (Rocky Mountain Orthodontics) and 11 mm expander screw

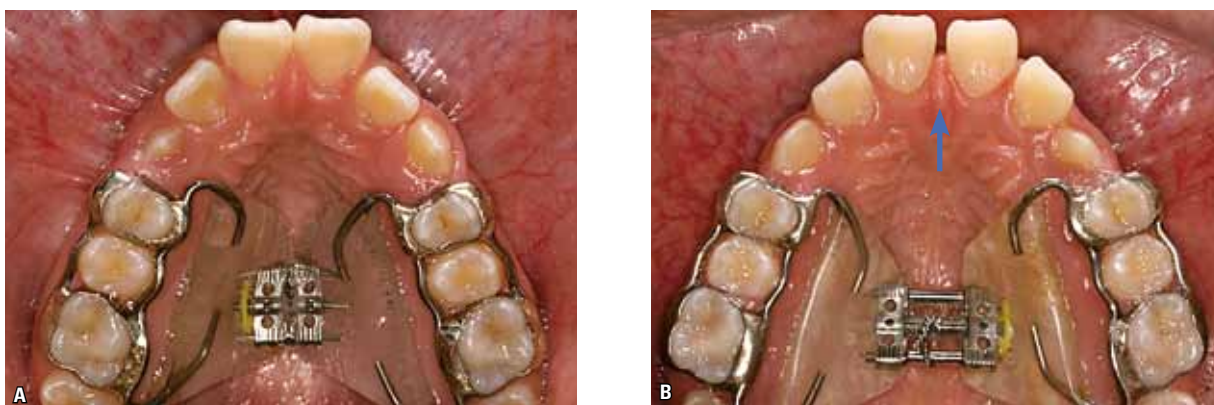


FIGURE 1 - Occlusal oral pictures with the Haas expander appliance: **A**) Before the beginning of screw activation, **B**) Immediately after screw stabilization (blue arrow shows the opening of the inter-incisors diastema).

(Dentaurum, Magnum model, 600.303.30) (Fig 1, A). The first screw activation was of one complete turn (0.8 mm), in the same day of appliance installation, and the following activations were of two 1/4 turn per day (0.2 mm per turn, 0.4 mm daily) until the palatine surface of the upper molar contacted the buccal surface of the lower molar, when the patient projected the mandible to a Class I relationship. This active expansion treatment varied from 2-3 weeks. After this, the screw was stabilized with a 0.012-in double thread ligature (Fig 1, B) and kept in place passively for the following six months when the appliance was then removed.

CBCTs were performed before treatment (T1), immediately after screw expander stabilization (T2), and 1-2 days after appliance removal (T3). All scans were taken with the same Cone-Beam machine (i-CAT, Imaging Sciences International, Hatfield, Pennsylvania, USA), according to a standard protocol (120 KVp, 3-8 mA, FOV = 13x17 cm, voxel = 0.4 mm, and scan time = 20s). The scans performed in T1 and T2 were saved in DICOM (digital imaging and communication in medicine) format, and with Dolphin Imaging software® version 11.0 (Dolphin Imaging, Charsworth, California, USA), it was possible to reconstruct 3D images for analysis.

Using specific software functions, before the measurements, it was possible to standardize

head image positions according to the axial, coronal, and sagittal planes⁴ at all studied times: The axial plane, passing through right and left orbital points as well as right porion; coronal plane, passing through left and right porion, perpendicular to the chosen axial plane; and sagittal plane, passing through nasion point, perpendicular to the chosen axial and coronal planes (Fig 2).

After standardization, the coronal plane and the 3D reconstructions of the images were used for determining the coronal slice and position of the landmarks (Fig 3). The most anterior coronal slice showing the entire palatal root of the first upper molar was chosen. All the landmarks were identified on the selected coronal slice. Landmarks and measurements were previously described by Podesser et al,¹⁸ as follows (Fig 4):

- Right and Left Maxillary (rMx and lMx): Right and left points in which the axial plane, by passing tangentially at the more inferior contour of nasal cavity, meets the buccal-alveolar contour of the maxilla.

- Right and Left Maxillary Alveolar (rMa and lMa): The most inferior and medial point of the buccal-alveolar process in relation to the upper first permanent molar.

- Right and Left Molars Cusp (rMc and lMc): The most inferior and medial point of the mesial-buccal cusp of the upper first permanent molar.

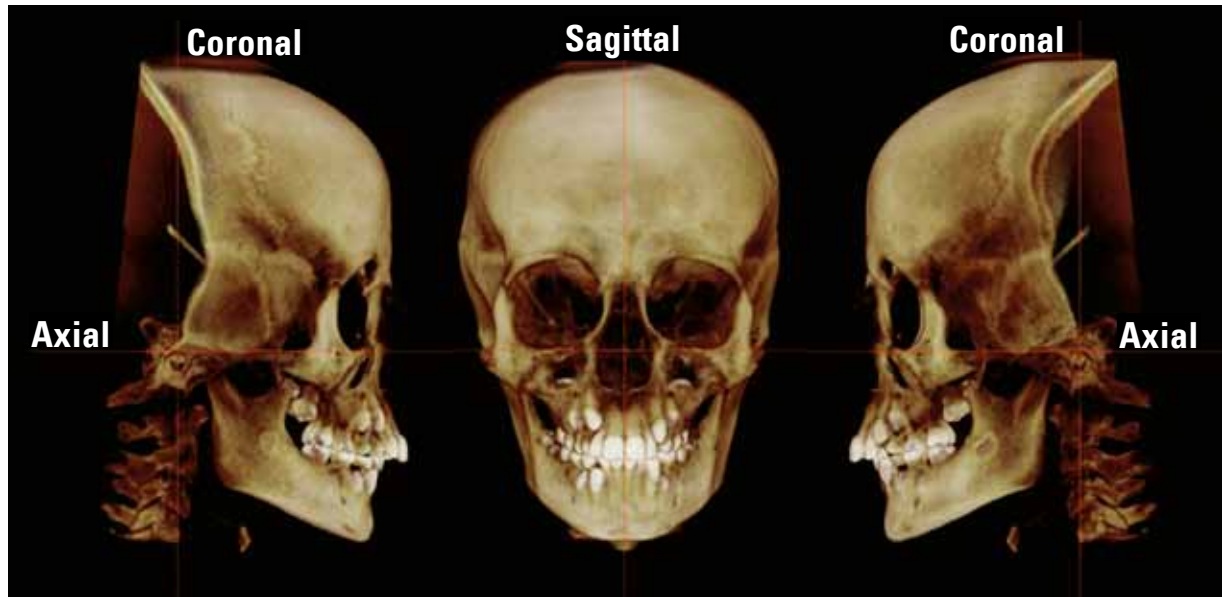


FIGURE 2 - Three-dimensional image of the head position after standardization by the axial, coronal and sagittal reference planes. Dolphin Imaging® 11.0, orientation tool.

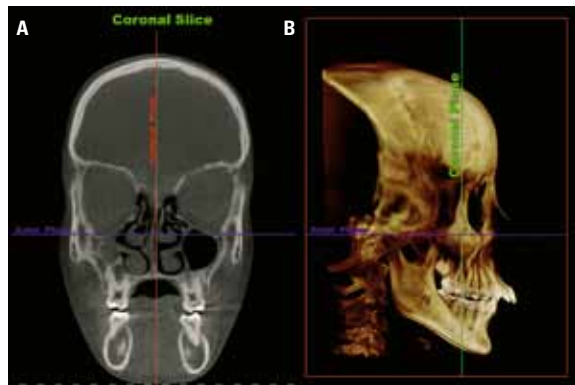


FIGURE 3 - **A)** Coronal slice used to identify the landmarks and measurements; **B)** 3D right lateral image, with the coronal plane passing through the right upper first molar. Dolphin Imaging® 11.0.

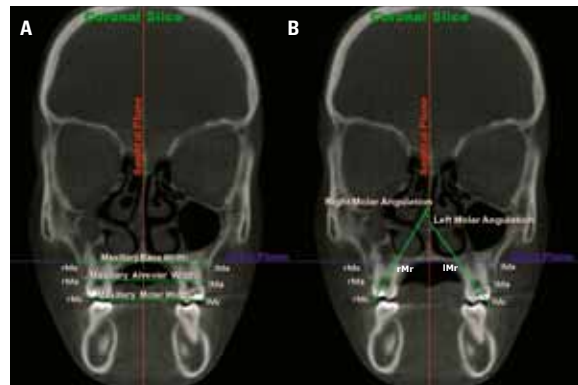


FIGURE 4 - Coronal slice images with the landmarks identified (rMx, lMx, rMa, lMa, rMc, lMc, rMr e lMr) and measurements: **A)** linear measurements (Maxillary base width, Maxillary alveolar width, Maxillary dental width); **B)** angular measurements (Right and Left molar angulation). Dolphin Imaging® 11.0, Digitize/Measurement tool.

- Right and Left Root Molars (rMr and lMr): The most superior and medial point of the palatine root of the upper first permanent molar.

The Linear measurements (mm) were maxillary basal width (rMx-lMx), maxillary alveolar width (rMa-lMa), and maxillary dental width (rMc-lMc), whereas angular measurements were right (rMc.rMr.sagittal plane) and left (lMc.lMr.sagittal plane) dentoalveolar angulation.

In order to avoid possible measurement errors, two similar monitors were used, including the software. This allowed CBCT images to be simultaneously handled for locating planes and landmarks in all three study period of times (T1, T2, T3) for each patient, where T1 was always the reference. Measurements, regarding each period of time, were taken separately by the same examiner within a 1-week interval.

Error of the method

Prior to the measurements, 15 scans were randomly selected in order to determine the reproducibility of the measurement performed in the present study. The 3D position of the head image was standardized, landmarks identified and measurements were obtained in two different periods within a 2-week interval under the same conditions. Intra-class correlation test was applied to verify the intra-observer agreement (95% interval confidence) for all variables. Agreement index was greater than 0.95 for all variables studied.

Statistical analysis

Means, standard deviations, minimum and maximum values were calculated for each variable at T1, T2, and T3, as well as changes occurring between T1 and T2, T2 and T3, and T1 and T3 were recorded. After normal data distribution was confirmed by the Kolmogorov-Smirnov non-parametric test, statistically significant differences between T2 and T1, T3 and T2, and T3 and T1 were identified using paired Student's t test ($p < 0.05$). All statistical analyses were carried out using SPSS software version 16.0 (SPSS Inc., Chicago, IL, USA).

TABLE 1 - Descriptive analysis of measurements obtained in pre-treatment (T1), immediately after expansion (T2) and after 6 months retention (T3).

	T1 (n=17)				T2 (n=17)				T3 (n=16)			
	Mean	Min.	Max.	SD	Mean	Min.	Max.	SD	Mean	Min.	Max.	SD
Maxillary Base Width	60.13	54.96	66.28	3.24	62.08	56.55	67.45	3.43	61.78	56.30	65.92	3.29
Maxillary Alveolar Width	53.53	46.98	57.70	3.17	57.83	51.41	61.68	2.88	58.22	51.87	61.88	3.27
Maxillary Dental Width	51.39	47.79	55.25	2.34	58.19	53.22	61.47	2.38	57.28	52.23	61.13	2.62
Right Molar Angulation	36.23	30.96	43.81	3.80	43.54	35.07	51.74	5.44	37.82	27.51	49.40	5.53
Left Molar Angulation	36.88	30.31	44.19	4.17	43.34	37.16	54.12	5.10	38.15	30.29	45.69	4.58

n = sample number; Min = minimum; Max = maximum; SD = standard deviation.

TABLE 2 - Results regarding transverse changes between pre-treatment and post-expansion (T2 – T1), post-expansion and retention (T3 – T2), and initial and retention (T3 – T1).

	T2-T1 (n=17)				T3-T2 (n=16)			T3-T1 (n=16)			
	Mean	SE	SD	%screw activation	Mean	SE	SD	Mean	SE	SD	%screw activation
Maxillary Base Width	1.95***	0.18	0.74	29.10	-0.29	0.16	0.64	1.66***	.23	.92	24.97
Maxillary Alveolar Width	4.30***	0.30	1.20	65.38	0.39	.22	0.89	4.69***	0.33	1.32	72.32
Maxillary Dental Width	6.89***	0.33	1.31	102.84	-0.91**	0.24	0.95	5.89***	0.34	1.38	91.08
Right Molar Angulation	7.31***	0.85	3.40	---	-5.71***	0.81	3.26	1.74	0.92	3.66	---
Left Molar Angulation	6.46***	0.95	3.79	---	-5.19***	0.76	3.05	1.27	0.56	2.22	---

n = sample number; SE = standard error; SD = standard deviation; Level of significance = * $p < 0.05$; ** $p < 0.01$; *** $p < 0.001$.

RESULTS

The midpalatal suture opened in all patients. This could be clinically visualized within 3-5 days after the beginning of the expander activation by the increase of inter-incisor diastema (Fig 1, B) and then confirmed in the CBCT image at T2 (Fig 5).

The mean screw activation was 7 mm (min. = 5.6 mm and max. = 9 mm).

During the retention period, one of the patients returned without the appliance, which was replaced by a removable retention appliance, but data at T3 were not computed.

The results regarding to the descriptive analysis and Student's t test are presented in Tables 1 and 2.

DISCUSSION

Rapid maxillary expansion has been widely used since the mid 60's.^{9,10} Numberless protocols and appliances have been proposed for correction of transverse skeletal discrepancies. In 1961, Haas⁹ described a technique for construction of

a dental-mucous-bone-supported expansion appliance and its effects have been evaluated since then.^{11,12} The objective of the present study was to evaluate, immediately after RME, as well as

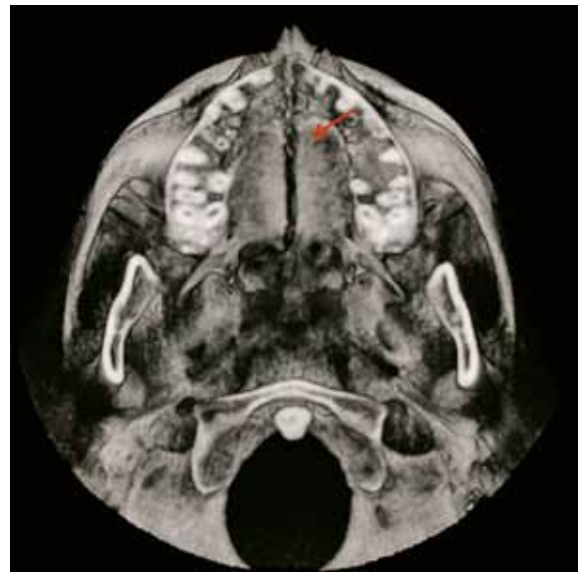

FIGURE 5 - Three-dimensional reconstruction showing the opening of the midpalatal suture in T2 (Dolphin Imaging®).

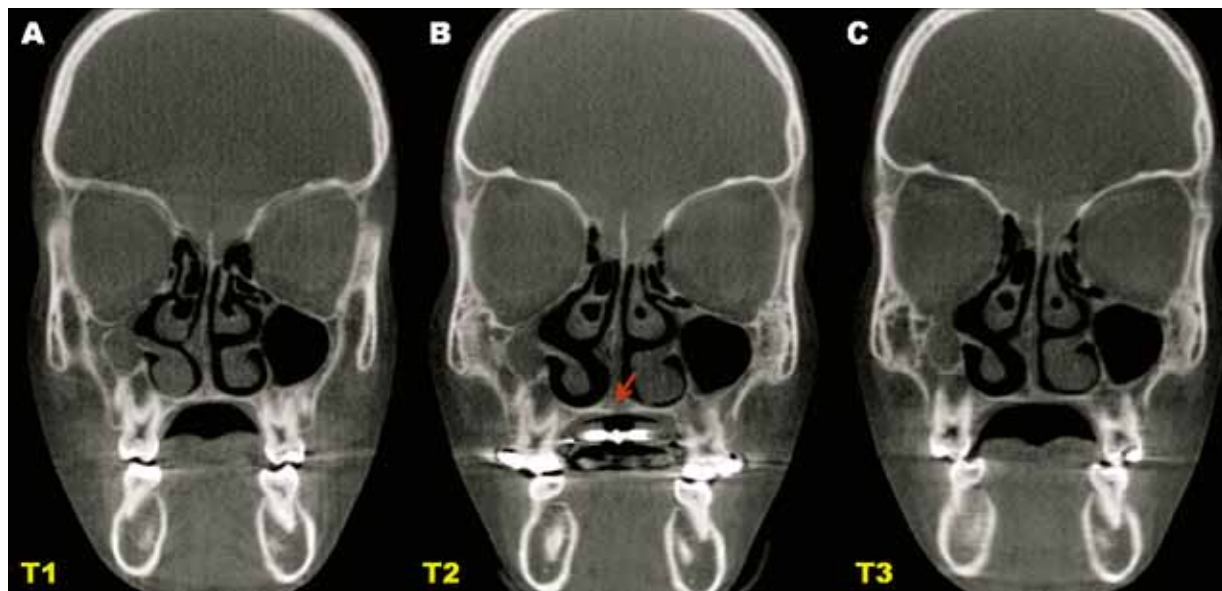


FIGURE 6 - Coronal slice used to measurements at T1, T2 and T3. **A)** Pre-treatment, crossbite not present in centric relation occlusion; **B)** Immediately after the transverse discrepancy correction, showing the palatal suture opened with slight inferior displacement (arrow) and an increase of the dentoalveolar angulation; **C)** After 6-months of retention, the transverse dimension increased, showing the buccal posterior crossbite tendency and the palatal dentoalveolar angulation. Dolphin Imaging® 11.0.

during and after the retention period, the transverse effects of the Haas expander in Class II malocclusion patient, since this treatment is so requested in this malocclusion.

The expansion protocol applied in this study was efficient for all patients. The opening of the midpalatal suture was easily confirmed on CBCT images realized at T2 (Fig 5), and none of the patients reported pain during the active or the retention period, just a light discomfort at the moment of the screw activation during the first 3 days. Treatment timing was an important issue to be considered, since it has been demonstrated that patients who underwent to RME before pubertal growth spurt exhibited greater skeletal effects, as well as greater bone stability when compared to later treatment.¹⁴ The successful results observed in our study can be attributed to the choice of the appliance, which provided maximum anchorage when used in the appropriate skeletal maturation period.¹³

Standardization of the amount of screw expander activation seems to be ideal to evaluate the transverse effects. However, we thought this is ethically wrong as the patients had different orthodontic needs, i.e., some might need more expansion while for others the amount of activation might not be enough. In order to make it possible to evaluate and to compare the results with previous studies, the transverse effects were proportionally analyzed according to the amount of screw activation in each patient.

Immediately after screw expander stabilization, all measurements were found to be highly significant (Table 2). Maxillary basal width increased, on average, 1.95 mm (29.10% of the screw activation), which was similar to what was found by Podesser et al.¹⁹ Alveolar and dental widths showed significantly greater results in our study, 4.3 and 6.9 mm, respectively, compared to 2.6 and 3.6 mm found elsewhere.¹⁹ Such difference may be related to the fact that the expander was removed at the end of

the active period for CBCT performing, which might have allowed some relapse, unlike our study, in which the expander was only removed at the end of the retention period.

Several studies reported a downward movement of the maxilla during the midpalatal suture opening following RME.^{1,5,9,23} This can happen because the center of resistance of the maxilla is located above the force application point, causing a buccal inclination of the dentoalveolar structures of the maxilla, with a downward displacement of the central region of the maxilla.^{17,27,29} This effect could also be observed in our study, visually, on CBCT images at T2 (Fig 6) and through the significant increase of the buccal inclination of the first upper molars (7.31°/6.46°) and the greater increase of the dental width than the total amount of screw activation (102.84%).

During the retention period (T3-T2), basal and alveolar maxillary widths did not change significantly ($p > 0.05$). The 6-months of retention with Haas expander not only kept the new transverse dimension, but also allowed a significant decrease in dentoalveolar angulation (-5.71° / -5.19°), decreasing the maxillary dental width (-0.91 mm). As reported by previous studies,^{5,11,24} the increase in transverse dimension, on the frontal view, in this study also occurred as a triangular form with the apex located superiorly. At the end of the retention period, it was observed that basal, alveolar, and dental maxillary widths were highly significantly ($p < 0.001$) greater than those measured at T1 (1.66 mm, 4.69 mm and 5.89 mm, respectively), corresponding to 24.97%, 72.32%, and 91.08% of the total of the screw activation. Similar results were found by Ballanti et al.³, who used computed tomography to evaluate the RME effects after 6-months retention with Hyrax-type expander. The molar widths at the apex and crown increased, respectively, 5.1 mm and 6.1 mm for a total

activation of 7 mm. Meanwhile, Garib et al⁷ found greater results at the basal and dental (crown) levels with the Hass appliance, respectively, 5.5 mm and 8.1 mm. Nevertheless, the retention period (3-months) was shorter and some relapse might be still expected.

The strong association between skeletal transverse deficiency and Class II, Division 1 malocclusions, even in the absence of posterior cross-bite, shows the importance of this discrepancy correction avoiding dental compensations.^{2,22,25,26} Our results showed that the RME with the Haas expander in Class II malocclusion patients did not change significantly the upper molar angulation. At the end of the retention period, dentoalveolar angulation was not found to be statistically different from that recorded at T1 despite the changes observed during the evaluation period. This demonstrates that the increase in dental width caused by RME had indeed promoted an effective

translation movement in the anchorage teeth. Ballanti et al³ also obtained the same results using Hyrax-type appliance, whereas Garib et al⁷ found significantly increased inclination of the molars at the end of their study. The 3-months of retention may not have been enough for molars to resume to their initial inclination.

CONCLUSIONS

All the Class II malocclusion patients evaluated had a significant increase in the skeletal and dental transverse dimension, without causing significant changes in the anchorage molars. The 6-months retention period allowed the transverse skeletal increase to be maintained and to return to the initial dentoalveolar inclination.

ACKNOWLEDGMENTS

The authors acknowledge the financial support given by CAPES and FAPERJ.

REFERENCES

1. Akkaya S, Lorenzon S, Uçem TT. A comparison of sagittal and vertical effects between bonded rapid and slow maxillary expansion procedures. *Eur J Orthod*. 1999 Apr;21(2):175-80.
2. Alarashi M, Franchi L, Marinelli A, Defraia E. Morphometric analysis of the transverse dentoskeletal features of Class II malocclusion in the mixed dentition. *Angle Orthod*. 2003 Feb;73(1):21-5.
3. Ballanti F, Lione R, Fanucci E, Franchi L, Baccetti T, Cozza P. Immediate and post-retention effects of rapid maxillary expansion investigated by computed tomography in growing patients. *Angle Orthod*. 2009 Jan;79(1):24-9.
4. Cevidanes L, Oliveira AE, Motta A, Phillips C, Burke B, Tyndall D. Head orientation in CBCT-generated cephalograms. *Angle Orthod*. 2009 Sep;79(5):971-7.
5. Chung CH, Font B. Skeletal and dental changes in the sagittal, vertical, and transverse dimensions after rapid palatal expansion. *Am J Orthod Dentofacial Orthop*. 2004 Nov;126(5):569-75.
6. Fishman LS. Radiographic evaluation of skeletal maturation: a clinically oriented method based on hand-wrist films. *Angle Orthod*. 1982 Apr;52(2):88-112.
7. Garib DG, Henriques JF, Janson G, Freitas MR, Coelho RA. Rapid maxillary expansion-tooth tissue-borne versus tooth-borne expanders: a computed tomography evaluation of dentoskeletal effects. *Angle Orthod*. 2005 Jul;75(4):548-57.
8. Grauer D, Cevidanes LS, Styner MA, Heulfe I, Harmon ET, Zhu H. Accuracy and landmark error calculation using cone-beam computed tomography generated cephalograms. *Angle Orthod*. 2010 Mar;80(2):286-94.

9. Haas AJ. Rapid expansion of the maxillary dental arch and nasal cavity by opening the midpalatal suture. *Angle Orthod.* 1961 Apr;31(2):73-90.
10. Haas AJ. The treatment of maxillary deficiency by opening the midpalatal suture. *Angle Orthod.* 1965 Jul;35(3):200-17.
11. Haas AJ. Palatal expansion: just the beginning of dentofacial orthopedics. *Am J Orthod.* 1970 Mar;57(3):219-55.
12. Haas AJ. Long-term posttreatment evaluation of rapid palatal expansion. *Angle Orthod.* 1980 Jul;50(3):189-217.
13. Haas AJ. Entrevista. *Rev Dental Press Ortop Ortop Facial.* 2001;6(1):1-10.
14. Lagravere MO, Major PW, Flores-Mir C. Long-term dental arch changes after rapid maxillary expansion treatment: a systematic review. *Angle Orthod.* 2005 Mar;75(2):155-61.
15. Lima RM Filho, Ruellas ACO. Long-term maxillary changes in patients with skeletal Class II malocclusion treated with slow and rapid palatal expansion. *Am J Orthod Dentofacial Orthop.* 2008 Sep;134(3):383-8.
16. Lima R, Bolognese AM, editores. *Ortodontia: arte e ciência.* 1ª ed. Maringá: Dental Press; 2007.
17. Majourau A, Nanda R. Biomechanical basis of vertical dimension control during rapid palatal expansion therapy. *Am J Orthod Dentofacial Orthop.* 1994 Sep;106(3):322-8.
18. Podesser B, Williams S, Bantleon HP, Imhof H. Quantitation of transverse maxillary dimensions using computed tomography: a methodological and reproducibility study. *Eur J Orthod.* 2004 Apr;26(2):209-15.
19. Podesser B, Williams S, Crismani AG, Bantleon HP. Evaluation of the effects of rapid maxillary expansion in growing children using computer tomography scanning: a pilot study. *Eur J Orthod.* 2007 Feb;29(1):37-44.
20. Ricketts RM. Perspectives in the clinical application of cephalometrics. *Angle Orthod.* 1981 Apr;51(2):115-50.
21. Riedel RA. The relation of maxillary structures to cranium in malocclusion and in normal occlusion. *Angle Orthod.* 1952;22(3):142-5.
22. Sayin MO, Turkkahraman H. Comparison of dental arch and alveolar widths of patients with Class II, division 1 malocclusion and subjects with Class I ideal occlusion. *Angle Orthod.* 2004 Jun;74(3):356-60.
23. Silva OG Filho, Boas MC, Capelozza L Filho. Rapid maxillary expansion in the primary and mixed dentitions: a cephalometric evaluation. *Am J Orthod Dentofacial Orthop.* 1991 Aug;100(2):171-9.
24. Silva OG Filho, Montes LA, Torelly LF. Rapid maxillary expansion in the deciduous and mixed dentition evaluated through posteroanterior cephalometric analysis. *Am J Orthod Dentofacial Orthop.* 1995 Mar;107(3):268-75.
25. Tollaro I, Baccetti T, Franchi L, Tanasescu CD. Role of posterior transverse interarch discrepancy in Class II, division 1 malocclusion during the mixed dentition phase. *Am J Orthod Dentofacial Orthop.* 1996 Oct;110(4):417-22.
26. Uysal T, Memili B, Usumez S, Sari Z. Dental and alveolar arch widths in normal occlusion, Class II division 1 and Class II division 2. *Angle Orthod.* 2005 Nov;75(6):941-7.
27. Wertz RA. Skeletal and dental changes accompanying rapid midpalatal suture opening. *Am J Orthod.* 1970 Jul;58(1):41-66.
28. Will L. Transverse maxillary deformities: diagnosis and treatment. *Oral Maxillofac Surg.* 1996;5:1-28.
29. Zimring JF, Isaacson RJ. Forces produced by rapid maxillary expansion. *Angle Orthod.* 1965 Jul;35:178-86.

Submitted: June 2010
Revised and accepted: July 2010

Contact address

Carolina Baratieri
Rua Anibal de Mendonça 16, ap. 109
CEP: 22.410-050 – Rio de Janeiro / RJ, Brazil
E-mail: carolinabaratieri@hotmail.com