

# Premaxilla: an independent bone that can base therapeutics for middle third growth!

Mariana Trevizan<sup>1</sup>, Alberto Consolaro<sup>2</sup>

DOI: <http://dx.doi.org/10.1590/2177-6709.22.2.021-026.oin>

Premaxilla, in its early descriptions, had the participation of Goethe. In our face, in a certain period of growth and development processes, premaxilla is an independent and, then, a semi-independent bone to finally be totally integrated to the maxilla. Formation of the premaxilla acts as a stabilization element inside the facial skeleton comparable to the cornerstone of a Roman arch and is closely related to the development of human face and its abnormal growth with characteristic malformations. Until when the premaxillary-maxillary suture remains open and offers opportunities to orthopedically influence facial growth to exert influence over facial esthetics and function? Contact with preliminary results in 1183 skulls from anatomic museums at USP, Unicamp and Unifesp led us to question therapeutic perspectives and its clinical applicability.

**Keywords:** Premaxilla. Facial growth. Incisive suture. Goethe.

A descrição inicial da pré-maxila teve a participação de Goethe. Na face, em determinado período do crescimento e desenvolvimento, têm-se a pré-maxila como um osso independente e, depois, semi-independente para, finalmente, se integrar totalmente à maxila. A formação da pré-maxila atua como um elemento estabilizador dentro do esqueleto facial, comparável com a pedra angular de um arco romano, e está intimamente relacionada com o desenvolvimento da face humana e seu crescimento anormal, com malformações características. Até quando a sutura pré-maxilar-maxilar continua aberta e oferece oportunidades para se influenciar ortopedicamente o crescimento facial e modificar a estética e função da face? O contato com estudos preliminares em 1.183 crânios de museus anatômicos da USP, Unicamp e Unifesp nos induziu a questionar sobre as perspectivas terapêuticas e aplicabilidades clínicas.

**Palavras-chave:** Pré-maxila. Crescimento facial. Sutura incisiva.

<sup>1</sup> Post-graduation program in Pediatric Dentistry, Dental School of Ribeirão Preto, Universidade de São Paulo (FORP-USP).

<sup>2</sup> Full professor, Dental School of Bauru, Universidade de São Paulo (FOB-USP) and Post-graduation program at the Dental School of Ribeirão Preto, Universidade de São Paulo (FORP-USP).

**Contact address:** Alberto Consolaro  
E-mail: [consolaro@uol.com.br](mailto:consolaro@uol.com.br)

**How to cite this article:** Trevizan M, Consolaro A. Premaxilla: an independent bone that can base therapeutics for middle third growth! Dental Press J Orthod. 2017 Mar-Apr;22(2):21-6.

DOI: <http://dx.doi.org/10.1590/2177-6709.22.2.021-026.oin>

**Submitted:** February 06, 2017 - **Revised and accepted:** February 13, 2017

» The authors report no commercial, proprietary or financial interest in the products or companies described in this article.

The face is divided into upper third, middle third (midface) and lower third. Maxilla is the main bone of midface and shows prevailing vertical growth associated to the skull base. In the first years of postnatal life, skull growth predominates over facial growth.<sup>6,7</sup> At the same time, mandibular growth is exuberant and maxillary growth is reduced.

In the first ten years of life, there is predominantly horizontal maxillary growth towards the anterior and posterior region<sup>8</sup>. In the second decade of life, vertical growth prevails. The present study represents a second phase of author's reflections on the premaxilla; and conclusions are similar to those previously published.<sup>38</sup> Some other information was added to the present study, besides the arguments presented at that time, thus enhancing the first study aforementioned.

When explaining facial growth and development in childhood, Enlow and Dale<sup>14</sup> described that there is a displacement of the nasomaxillary complex as a result of the increase in soft tissues in the face. The bones of the nasomaxillary complex get dislocated to positions far from their several suture joints. A new bone is simultaneously added to the suture margins of each bone, broadening the perimeter of each bone by means of quantities that amount to extensions of the regional dislocation.

Premaxilla is also known as incisive bone, intermaxillary bone and premaxillary bone, or even Goethe's bone. Its discovery in humans can be romantically attributed to Goethe<sup>18</sup> (1784) for he was, perhaps, the greatest genius of German culture, even though there are reports that precede his mention.<sup>9</sup>

The first illustration of the incisive suture in humans was presented in 1573 by Coiter.<sup>11</sup> In 1779, Broussonet (cited by Brauning-Oktavio,<sup>9</sup> 1956) and, right after that, in 1780, Vicq d'Azyr (cited by Brauning-Oktavio,<sup>9</sup> 1956), pioneered to describe it as anatomists reporting it as a medial part of the maxilla that represented a bone separate from the skull in vertebrates.

Premaxilla growth is closely related to the development of human face,<sup>3</sup> yet, with respect to premaxillary growth and development, it has not been defined yet the period in which the premaxilla/maxilla suture closure occurs, so that they can constitute a single bone.

Abnormal growth of the premaxilla in relation to the maxilla may be correlated to malformation, such as prognathism, deep bite and protrusion.<sup>3</sup> Formation of the premaxilla acts as a stabilization element inside the facial skeleton, comparable to the cornerstone of a Roman arch. In other words, premaxilla is closely related to the development of human face and its abnormal growth may be related to characteristic malformations.

Thoroughly and sequentially understanding the development of the premaxilla and its integration to the maxilla can:

**1) Base and stimulate the formulation of new ways for the treatment of growth and development alterations in the maxilla and the midface with the use of anteroposterior expansion of the maxilla.**

Orthodontic appliances could conduct the premaxilla to a more beneficial anterior position<sup>20,32,34</sup> by the premaxillary-maxillary suture opening, stimulating the development of that region<sup>34</sup> and be a contribution factor in non-surgical maxillary protraction through stimulation of maxillary sutures.<sup>20</sup>

For instance, the suture that exists between premaxilla and maxilla can be the adequate point for intervention in Class III cases in which the diagnosis indicates lack of maxillary development. Considering the existence of premaxilla as an independent bone would enable its movement via suture and/or periosteal bone growth, in order to correct certain malocclusions, reducing risk and seriousness, or even avoiding some surgical procedures.

**2) Help with understanding the etiopathogeny of cleft lip and cleft palate and their outcomes in craniofacial growth, allowing the planning of more refined and pertinent treatments of such development disorders.**

The position of the clefts is not always identical to the premaxillary-maxillary suture<sup>3,21</sup>, since bone development does not match to primary facial development.<sup>21</sup> Face formation lines are not identical to the gathering of bone growth centers in all the sutures, including those of the premaxillary-maxillary suture.

Bilateral cleft lip and cleft palate cause premaxillary protrusion, including infra-nasal and teeth soft tissues.<sup>4</sup> Its treatment goes through several stages, among them alveolar bone grafting,<sup>23</sup> which can be

autogenous or synthetically produced grafts,<sup>19</sup> extinguishing failure.

The existence of premaxilla as an independent bone would enable its movement after relocation, which occurs precociously, in a way that the defect is reduced before grafting execution, leading it to a more favorable position.

### 3) Base and stimulate current and new therapeutics for nasal obstruction cases in newborn children for congenital nasal pyriform aperture stenosis.

Nasal obstruction is a potentially serious condition to infants,<sup>15</sup> once it may lead to respiratory failure of newborn children.<sup>10</sup> Among the etiologies, there is congenital nasal pyriform aperture stenosis, which narrows the anterior third of the nasal cavity, caused by excessive growth of maxillary medial nasal process.<sup>29</sup>

The intermaxillary bone, or premaxilla, constitutes the main limit of the pyriform apertures, and parts of such bone can be occasionally seen on the laterals to the pyriform apertures up to five years of life approximately, together with the nasal bone, which closes the pyriform aperture and is in contact with the frontal bone.<sup>3</sup>

## WHAT IS THE IMPORTANCE OF THE PREMAXILLA AND ITS PROSPECTIVE CLINICAL IMPLICATIONS?

The prefix 'pre' implies anteriority, antecedence or precedence. The nominal definition of the premaxillary bone indicates the one that precedes or is ahead of the maxilla and skull.

The premaxilla is the intermaxillary segment of the maxilla where the four upper incisors are placed.<sup>3</sup> It develops embryonically from the primary palate.<sup>25,28</sup>

The limits of the premaxilla are signaled by a lateral structure that starts in the incisive foramen towards the region between lateral incisors and canines, forming what was once called incisive bone.<sup>28</sup> The route of the suture descends from the junction of maxilla and premaxilla, near the pyriform aperture in its lower portion, until the alveolar margin in the region of the canine, transposing the palate until the incisive foramen<sup>22</sup> (Figs 1 and 2).

We can distinguish three parts in the premaxilla:

» the alveolar part with facial process,

» the palatine process,

» and the Stenonianus process, which goes along with the cartilage of the nasal septum and the vomer.<sup>3,27</sup>

Embryonically, the face derives from prominences that surround a central depression called *stomodeum*, which will turn out to be the oral cavity. At the embryonic stage, there are six pharyngeal arches, and the first one originates from the maxilla and the mandible. Later, leveling of the medial nasal and frontonasal processes will originate the nose, maxilla and primary palate. The lateral nasal process also participates in the formation of the maxilla and the nose.

The premaxilla starts ossification in the 7th month of pregnancy.<sup>28</sup> In such period, there is a change in blood supplementation of the face that occurs concurrently with a critical period of intermediate development of the face and the palate.

As incredible as it may seem, existence of the premaxilla as an independent or semi-independent bone has already been questioned,<sup>5,26,35,36</sup> for it is difficult to embryonically identify its ossification center.

Clarifying up to when the premaxilla, in terms of time, can be considered independent or semi-independent — since even adults have it partially or totally persistent<sup>20</sup> — can create new opportunities in orthopedics, orthodontics and surgeries involving the region to correct disorders in craniomandibular growth and development.

In order to topographically determine and identify the approximate closure time of the suture between the maxilla and the premaxilla, exploring their morphology, function and relevance in the human skeleton, Trevizan<sup>37</sup> has been doing research with over 1183 skulls at varying gestational and postnatal ages from the anatomic museums of USP, Unicamp and Unifesp universities. Preliminary results show that the premaxilla must be considered independent on the maxilla up to a certain precocious stage of postnatal life, but it can be extended throughout life, being semi-independent on the maxilla.

The premaxillary-maxillary suture, also known as incisive suture, can be identified in the palate of the skulls even in adults, but it has been reported that its closure occurs in the third semester of prenatal life.<sup>1,2,22,24</sup> Its closure on the buccal surface of the alveolar process may happen very precociously, but what about the

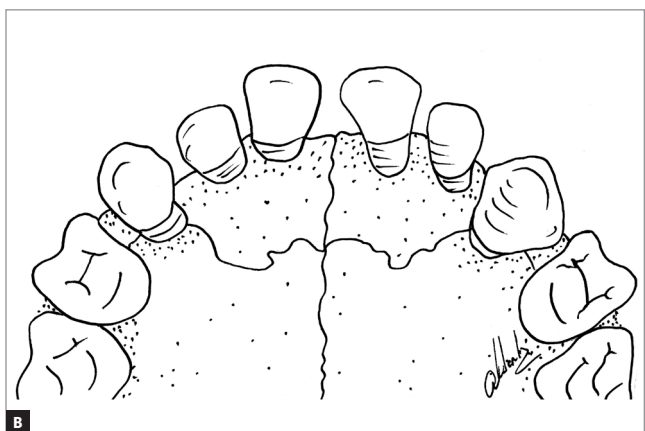
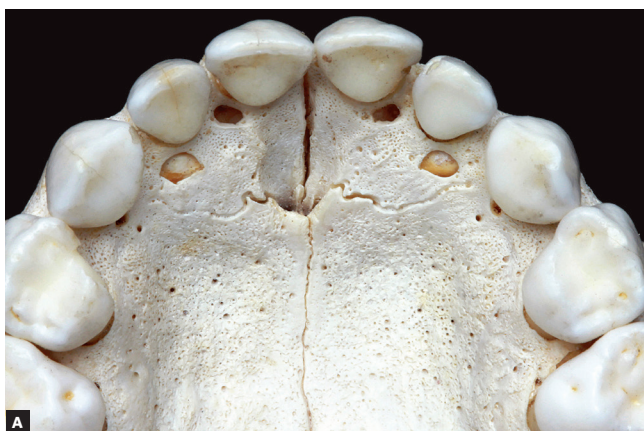

Figure 1 - Premaxillary-maxillary suture in a child's skull.

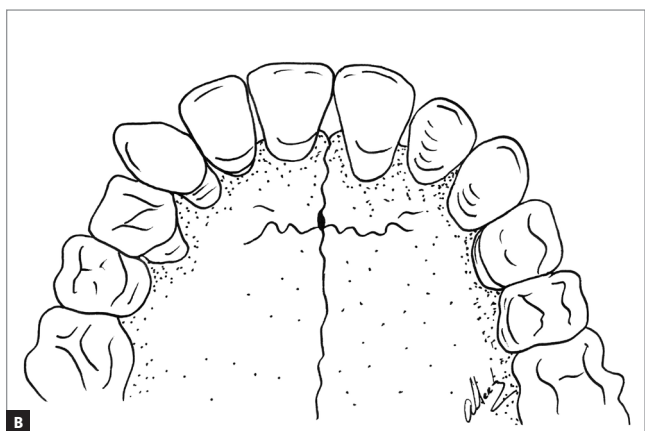
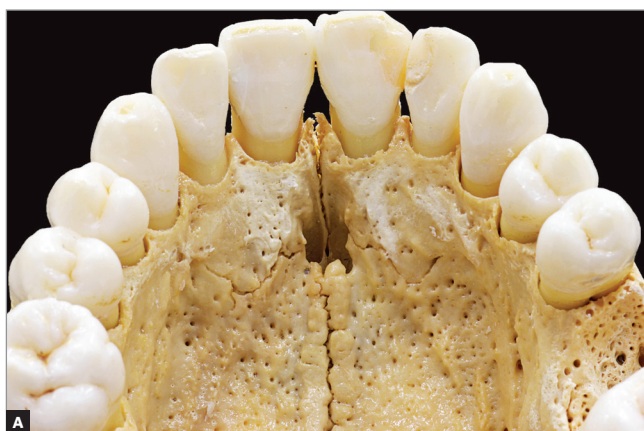

Figure 2 - Premaxillary-maxillary suture in an adult's skull.

other areas? What would be the course or sequence of the closure of such suture in all its anatomic interfaces? In parallel, questioning and controversy remain:

*“Up to where these results on the premaxilla and the premaxillary-maxillary suture will be able to withstand treatment protocols of craniomandibular growth disorders as it happens with the midpalatal suture, especially regarding procedures for maxillary expansion/position and volume increase?”*

The particularities of the premaxillary-maxillary suture are probably associated to the way and mechanisms of maxillary growth whose remodeling happens from upper to lower<sup>13</sup>, offering a more precocious closure than the midpalatal suture, which must be a concentration point of forces related to craniomandibular growth, since it is directly linked to the skull base! Yet, in adults, this suture can be observed<sup>5</sup>.

## HISTORICAL ASPECTS AND EVOLUTION OF KNOWLEDGE ON THE PREMAXILLA IN HUMANS

Discussion on the existence of a separate intermaxillary bone in humans seems to be as old as the history of comparative anatomy. Since then, the premaxilla or intermaxillary bone has a central place in the discussion on dissimilarity or homology between men and other vertebrates.

In Camper's concept in 1778 (cited by Brauning-Oktavio,<sup>9</sup> 1956), the division of maxilla "between the incisive and the canine teeth" is considered one of the main differences between humans and monkeys. According to Goethe, accident and reflection guided him in his research with various skulls of animals and humans. It is not only the anatomic discovery that made Goethe's work so famous and important, but the idea according to which there was natural harmony among vertebrates, including men, for which a especial position was intended.<sup>17</sup>

Goethe started his morphological studies in 1781 as a student of his friend Loder, professor of Anatomy in Jena (cited by Franz,<sup>16</sup> 1933). His first booklets on the intermaxillary bone were published in 1784/1786 and a new edition was republished in 1981. In Goethe's letters, we see: "I have found neither gold, nor silver, but what makes me one of us, that is, the presence of the intermaxillary bone in humans!" (cited by Voss,<sup>33</sup> 1979).

Nevertheless, it was also Vicq d'Azyr (cited by Brauning-Oktavio,<sup>9</sup> 1956) who discovered the intermaxillary bone, which he called anterior maxilla, in unborn children, and presented it in his "Memories"

at the Science Academy, in Paris, 1780. According to Barteczko and Jacob<sup>3</sup> (2004), the merits of such discovery are owed to Vicq d'zur, even though both Goethe and Vicq d'Azyr described it independently and with different methods. Perhaps, Volcher Coiter<sup>11,12</sup> (1573 and 1573/1955) was the first one to do that, when, in an illustration of the incisive suture, he wrote only "upper maxillary bone in an adult, with number and position of the interviewee". Although Goethe was not the first one to discover the premaxillary, his involvement brought great philosophical and ideological importance to the subject. It may be scary, but we still find authors who deny a separate premaxilla.<sup>30,31,36</sup>

## FINAL CONSIDERATIONS

1. We are still in search of several explanations for the results of the analysis of 1183 human skulls from anatomic museums of USP, Unicamp and Unifesp universities, to be presented soon.

2. How can we use them in therapeutic diagnoses and planning of the patients with altered development of the midface if we still do not even know how and when the premaxillary-maxillary suture disappears?

3. Stimulating critical thinking by presenting preliminary questions and results represents a way of collecting subsidies and increase the amplitude of their explanations in clinical practicing.

The premaxilla having a period as an independent bone seems unequivocal as well as the fact that we will be able to use it in therapeutics. We are now exploring the perspectives on using the premaxillary-maxillary suture in order to influence the growth of the middle third of the face!



## REFERENCES

1. Ashley-Montagu MF. The premaxilla in primates. *Q Rev Biol.* 1935;10(1):32-59.
2. Ashley-Montagu MF. The premaxilla in primates. *Q Rev Biol.* 1935;10(2):181-208.
3. Barteczko K, Jacob M. A re-evaluation of the premaxillary bone in humans. *Anat Embryol (Berl).* 2004 Mar;207(6):417-37.
4. Baxter DJ, Shroff MM. Developmental maxillofacial anomalies. *Semin Ultrasound CT MR.* 2011 Dec;32(6):555-68.
5. Behrents RG, Harris EF. The premaxillary-maxillary suture and orthodontic mechanotherapy. *Am J Orthod Dentofacial Orthop.* 1991 Jan;99(1):1-6.
6. Bishara SE. *Orthodontia.* São Paulo: Ed. Santos; 2004.
7. Bishara SE. *Textbook of Orthodontics.* St. Louis: WB Saunders; 2000.
8. Björk A, Skieller V. [Growth and development of the maxillary complex]. *Inf Orthod Kieferorthop.* 1984;16(1):9-52.
9. Bräuning-Oktavio H. Vom Zwischenkieferknochen zur Idee des Typus. Goethe als Naturforscher in den Jahren 1780–1786. Barth: Leipzig; 1956. *Nouv Acta Leopoldina n.* 126, Bd.18.
10. Brown OE, Myer CM, Manning SC. Congenital nasal pyriform aperture stenosis. *Laryngoscope* 1989;99:86-91.
11. Coiter V. *Externarum et internarum principalium humani corporis partium tabulae, atque anatomicae exercitationes observationesque variae.* Noribergae: Gerlatz; 1573.
12. Coiter V. *Externarum et internarum principalium humani corporis partium tabulae atque anatomicae.* *Opuscula selecta Neerlandicorum de arte medica.* Bohn: Harlem; 1573-1955.
13. Delaire J. [Lateral limits of the os incisivum. (Studies of some congenital malformations)]. *Fortschr Kieferorthop.* 1965;26(4):391-5. German.
14. Enlow DH, Dale JG. Crescimento e desenvolvimento facial na infância. In: Ten Cate R. *Histologia Bucal.* 5a ed. Rio de Janeiro: Guanabara Koogan; 2001. p. 393-432.
15. Faust RA, Phillips CD. Assessment of congenital bony nasal obstruction by 3-dimensional CT volume rendering. *Int J Pediatr Otorhinolaryngol.* 2001 Oct 19;61(1):71-5.
16. Franz V. Goethes Zwischenkieferpublikation nach Anlaß, Inhalt und Wirkung. *Z Anat Entw.-Gesch.* 1933;30:469-543.
17. Goerttler K. Hrsg *Entwicklungsgeschichte des Menschen.* Berlin: Springer; Göttingen Heidelberg; 1950.
18. Goethe VW. Über den Zwischenkiefer des Menschen und der Tiere. Handschriftlich: mit Tafeln, März; 1784; ohne Tafeln 1820 zur Morphologie, Band I Heft 2: "Dem Menschen wie den Tieren ist ein Zwischenknochen der obern Kinnlade zuzuschreiben"; 1831 mit Tafeln in den "Verhandlungen der Kaiserlich Leopoldinisch-Carolinischen Akademie der Natur- forschers".
19. Hallman M, Thor A. Bone substitutes and growth factors as an alternative/complement to autogenous bone for grafting in implant dentistry. *Periodontol* 2000. 2008;47:172-92.
20. Haskell BS, Farman AG. Exploitation of the residual premaxillary-maxillary suture site in maxillary protraction. An hypothesis. *Angle Orthod.* 1985 Apr;55(2):108-19.
21. Lisson JA, Kjaer I. Location of alveolar clefts relative to the incisive fissure. *Cleft Palate Craniofac J.* 1997 July;34(4):292-6.
22. Noback CR, Moss ML. The topology of the human premaxillary bone. *Am J Phys Anthropol.* 1953 June;11(2):181-8.
23. Precious DS. A new reliable method for alveolar bone grafting at about 6 years of age. *J Oral Maxillofac Surg.* 2009 Oct;67(10):2045-53.
24. R Emmelink ILL. The postnatal development of the human maxillary sutural surfaces [thesis]. Groningen, The Netherlands: The University of Groningen; 1985.
25. Revelo B, Fishman LS. Maturational evaluation of ossification of the midpalatal suture. *Am J Orthod Dentofacial Orthop.* 1994 Mar;105(3):288-92.
26. Rygh P, Tindlund R. Orthopedic expansion and protraction of the maxilla in cleft palate patients--a new treatment rationale. *Cleft Palate J.* 1982 Apr;19(2):104-12.
27. Shepherd WM, McCarthy MD. Observations on the appearance and ossification of the premaxilla and maxilla in the human embryo. *Anat Rec.* 1955 Jan;121(1):13-28.
28. Sperber GH, Sperber SS, Guttmann GD. *Craniofacial embryogenetics and development.* 2nd ed. Shelton: People's Medical; 2010.
29. Tagliarini JV, Nakajima V, Castilho EC. Congenital nasal pyriform aperture stenosis. *Braz J Otorhinolaryngol.* 2005 Mar-Apr;71(2):246-9.
30. Vacher C, Onolfo JP, Lézy JP, Copin H. [The growth of the maxilla in humans. What place for the premaxilla?]. *Rev Stomatol Chir Maxillofac.* 2001 June;102(3-4):153-8.
31. Vacher C, Sakka M, Dauge MC. Incisive suture (fissure) in the human fetus: radiographic and histologic study. *Cleft Palate Craniofac J.* 2001 July;38(4):330-6.
32. Vardimon AD, Graber TM, Voss LR, Verrusio E. Magnetic versus mechanical expansion with different force thresholds and points of force application. *Am J Orthod Dentofacial Orthop.* 1987 Dec;92(6):455-66.
33. Voss H. Goethes Selbstzeugnisse über seine Beschäftigung mit "organischen Naturen". II. Briefe (1776 bis 1817). *Gegen-Baurs Morphol Jb.* 1979;125:466-518.
34. Witzig JW, Spahl TJ. The clinical management of basic maxillofacial orthopedic appliances. *Mechanics.* Littleton: PSG; 1987. p. 226-8, 236-7, 240.
35. Wood NK. Osteogenesis of the human upper jaw: proof of the non-existence of a separate premaxillary centre. *Arch Oral Biol.* 1969 Nov;14(11):1331-9.
36. Wood NK, Wragg LE, Stuteville OH. The premaxilla: embryological evidence that it does not exist in man. *Anat Rec.* 1967 Aug;158(4):485-9.
37. Trevizan M. *Sutura pré-maxilar-maxilar: aspectos topográficos e temporais de sua presença [mestrado].* Ribeirão Preto (SP): Universidade de São Paulo; 2017. No prelo.
38. Trevisan M, Consolaro A. A pré-maxila é um osso independente até quando? A sutura pré-maxilar-maxilar pode fundamentar terapêuticas para o crescimento do terço médio da face! *Rev Clin Ortod Dental Press.* 2017 Fev-Mar;16(1):122-6.