



Agensis of mandibular second premolar in patient with dental bimaxillary protrusion

Carlos Alberto Estevanell Tavares¹

DOI: <http://dx.doi.org/10.1590/2177-6709.22.2.106-117.bbo>

The present study reports the treatment carried out in a patient with mandibular second premolar agensis associated with early loss of a deciduous second molar, deep overbite, severe overjet and dentoalveolar bimaxillary protrusion, which led to lip incompetence and a convex facial profile. The main objectives of this treatment were: to eliminate the spaces in mandibular arch, correct overbite, as well as eliminate bimaxillary protrusion and lip incompetence, thus leading to a balanced profile. The case was presented to the Brazilian Board of Orthodontics and Dentofacial Orthopedics (BBO) as part of the requirements to obtain the title of BBO diplomate.

Keywords: Tooth agensis. Corrective Orthodontics. Tooth extraction.

O presente caso clínico relata o tratamento de uma paciente com agensia de segundo pré-molar inferior associada à perda precoce do segundo molar decíduo, sobremordida profunda, sobressaliência exagerada e biprotrusão dentoalveolar, que causavam incompetência labial e perfil facial convexo. Os objetivos do tratamento foram eliminar os espaços presentes na arcada inferior, corrigir a sobremordida, eliminar a biprotrusão e a incompetência labial, harmonizando o perfil. Esse caso foi apresentado ao Board Brasileiro de Ortodontia e Ortopedia Facial (BBO) como parte dos requisitos para obtenção do título de Diplomado pelo BBO.

Palavras-chave: Agensia dentária. Ortodontia corretiva. Extração dentária.

INTRODUCTION

Tooth agensis is part of orthodontic routine, being found among 4-5% of the overall population, without including third molars. Such an incidence increases to 9% when patients seeking orthodontic treatment are taken into consideration.¹

With a prevalence of 2.5-4%, mandibular second premolars are the most commonly affected teeth, followed by third molars.^{2,3} In most patients, agensis affects both sides of the dental arch (nearly 60% of cases), whereas it affects a single tooth only on a smaller scale.³

With advances in Orthodontics, a number of therapeutic options became available for agensis treatment, namely: spontaneous space closure, autotransplantation, implants, mini-implants, anchorage for space closure.⁴ The orthodontic mechanics of choice must consider whether agensis affects both sides or not. Arguments in favor of contralateral tooth extraction are more common than unilateral space closure, due to potential difficulties involved not only in mesially displacing molars to an edentulous area, but also in achieving a satisfactory occlusion in the posterior region.⁵

» Patients displayed in this article previously approved the use of their facial and intraoral photographs.

Submitted: January 18, 2017 - **Revised and accepted:** March 03, 2017

How to cite this article: Tavares CAE. Agensis of mandibular second premolar in patient with dental bimaxillary protrusion. *Dental Press J Orthod.* 2017 Mar-Apr;22(2):106-17. DOI: <http://dx.doi.org/10.1590/2177-6709.22.2.106-117.bbo>

» The author reports no commercial, proprietary or financial interest in the products or companies described in this article.

¹Professor, Specialization course in Orthodontics, *Associação Brasileira de Odontologia-RS* (Rio Grande do Sul, Brazil).

Contact address: Carlos Alberto Estevanell Tavares
Rua Furriel Luiz Antonio Vargas, 250, conj. 1404, Porto Alegre/RS – CEP: 90.470-130 - E-mail: carlos.a.e.tavares@gmail.com

CASE REPORT

A 11-year and 6-month-old female patient sought orthodontic treatment with chief complaint of dental protrusion and lip incompetence. Her family medical history presented with no major occurrences nor reported any trauma affecting her teeth or face.

DIAGNOSIS

Facial examination revealed a rather decreased nasolabial angle and an everted lower lip, in addition to lip incompetence. Smile line was considered adequate (Fig 1).

Intraoral examination revealed 6-mm overjet and 60% of overbite, in addition to the presence of 5-mm space in the mandibular arch and minimal crowding in the maxillary arch. The #45 tooth was missing and #47 tooth was found to be impacted, whereas

#46 tooth was 3.0mm mesially displaced, in relation to #36 and #43 teeth, and distally displaced in relation to #33 tooth. Occlusal relationship was of Class I for molars and Class II for canines on the right side, and Class I for molars and edge-to-edge for canines on the left side (Figs 1 and 2).

Radiographic analysis revealed #45 tooth congenitally missing, in addition to four developing third molars and absence of caries or other pathologies. Cephalometric analysis suggested Class II skeletal pattern ($ANB = 5^\circ$), predisposition to vertical facial growth ($FMA = 29^\circ$, $Y\text{-axis} = 64^\circ$) and bimaxillary protrusion, with lower and upper lips 2 and 3 mm forward in relation to the S-line, respectively ($1.NA = 31^\circ$, $1.NB = 32.5^\circ$, and $IMPA = 98^\circ$) (Figs 3 and 4).

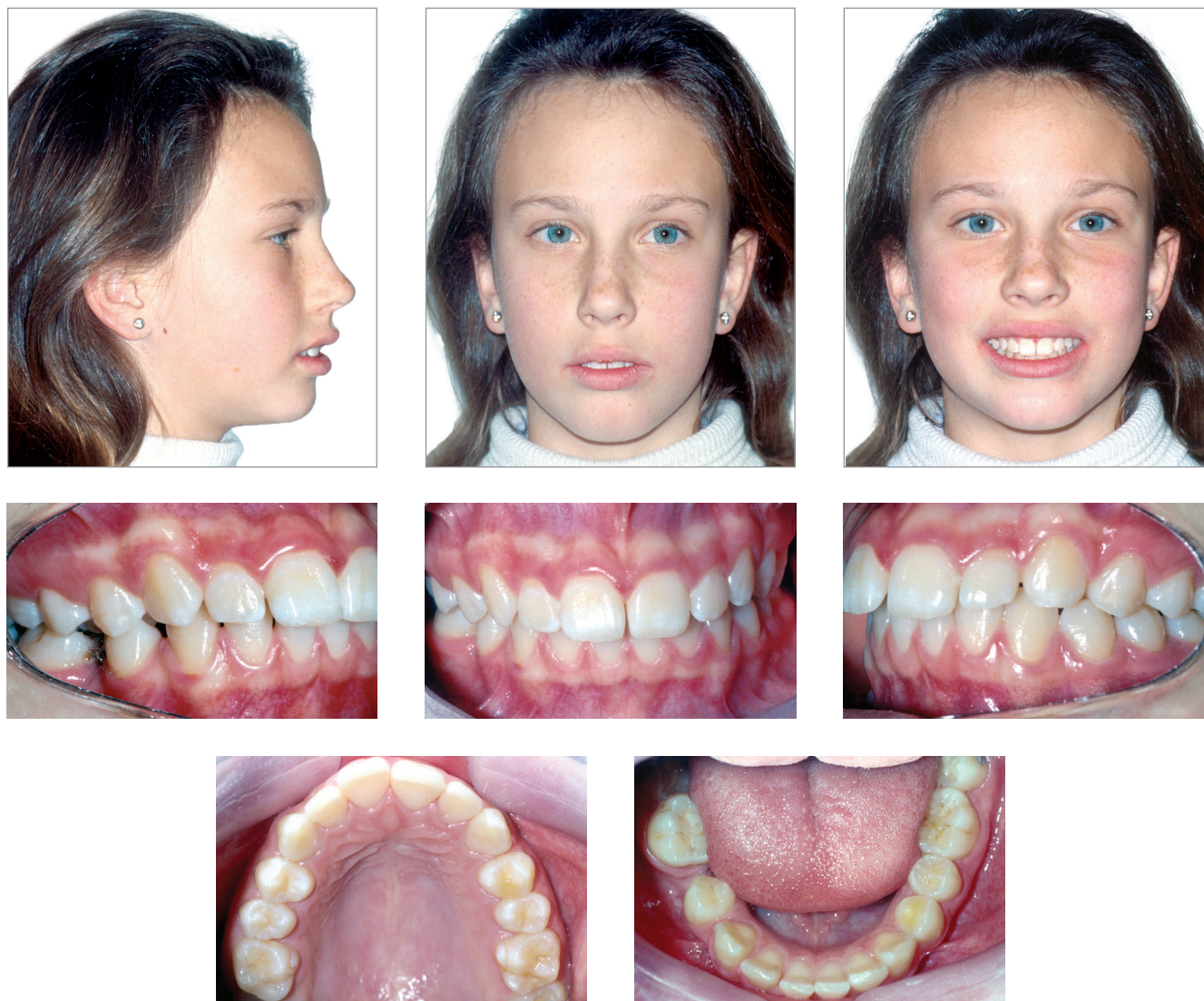

Figure 1 - Initial facial and intraoral photographs.

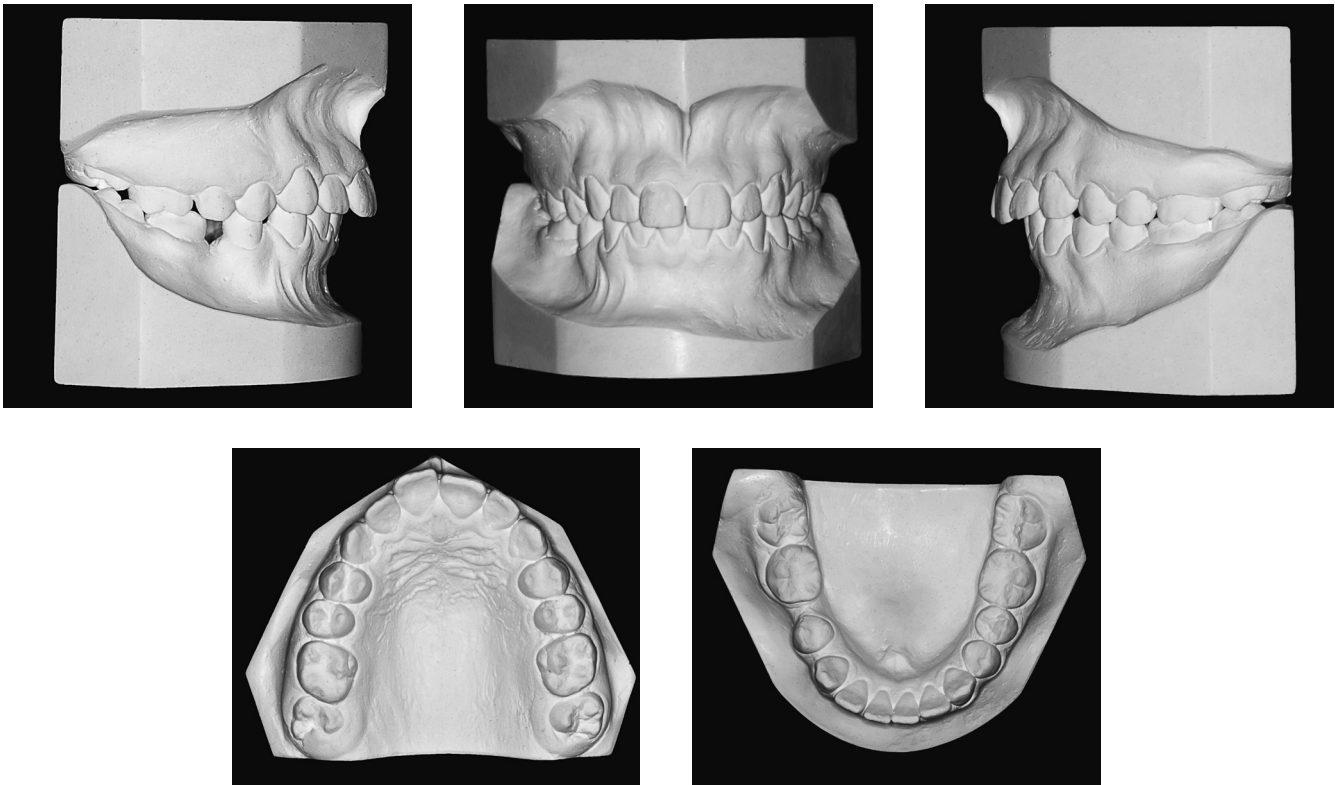


Figure 2 - Initial casts.

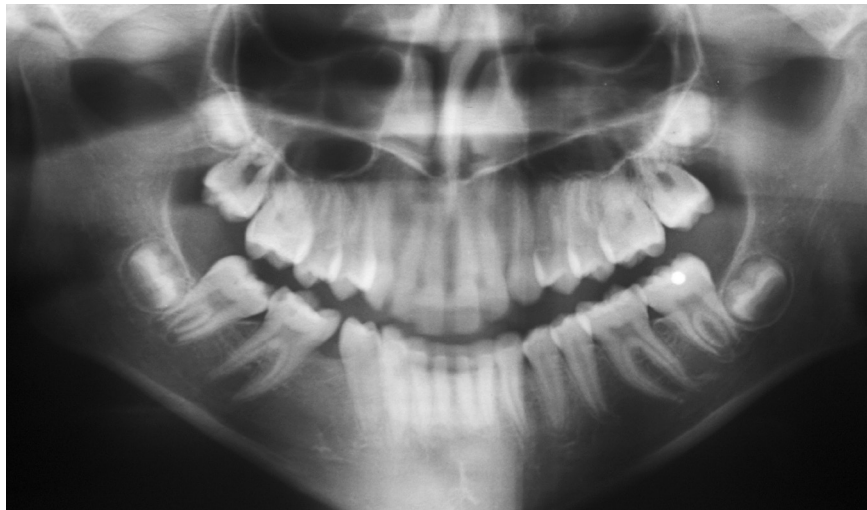


Figure 3 - Initial panoramic radiograph.

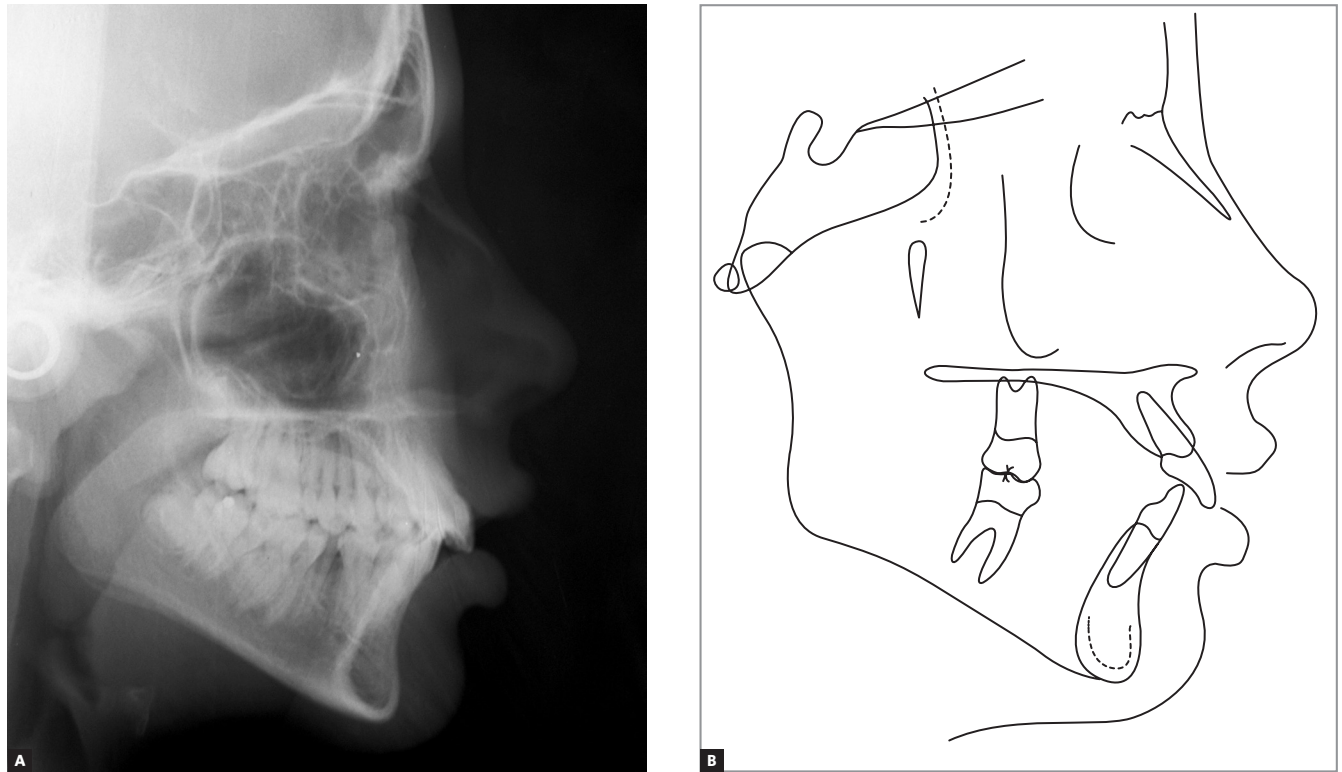


Figure 4 - Initial lateral cephalogram (A) and cephalometric tracing (B).

TREATMENT PLAN

Treatment objectives were as follows: to reduce overjet and overbite, achieve a Class I canine relationship, upright incisors, correct #47 tooth impaction, carry out space closure and achieve a symmetrical mandibular arch. As regards facial aesthetics, treatment objectives were: to decrease lip protrusion and increase lip seal.

Treatment plan included extraction of #14, #24 and #35 teeth, orthodontic appliance placement with 0.022x0.028-in slot metal brackets, and a sequence of 0.014-in, 0.016-in and 0.017x0.022-in NiTi archwires, followed by 0.018x0.025-in and 0.019x0.025-in SS archwires, in addition to retraction of #13, #23, #34, #44, #33 and #43 teeth with elastomeric chain. Subsequently, after tooth retraction, 0.019 x 0.025-in archwires with teardrop loops were used for incisors retraction and closure of remaining spaces. For finishing and torque control, maxillary and mandibular 0.019x0.025-in SS archwires were manufactured to be used in coordination. After fixed appliance debonding, a fixed canine-to-canine lingual bar retainer was placed in the man-

dibular arch, whereas a wraparound removable retention was placed in the maxillary arch.

Alternative treatment included distalization mechanics, such as extraoral appliance and intermaxillary elastics, in addition to keeping agenesis space unchanged for future prosthetic rehabilitation. Nowadays, the first choice for prosthetic rehabilitation of a congenitally missing premolar is implant treatment.⁶ However, implants are not stable before facial growth completion. Ostler and Kokich⁷ assessed long-term changes in the bone crest after deciduous second molar extraction, and showed that the bone crest decreased in 25% during the first four years after extraction and 5% during the following three years, thus totaling 30% in seven years. Resorption is more often at the buccal surface of the bone crest and although the authors have showed that gingival crest width is enough to receive implants after this period, they would have to be placed more lingually than ideal.⁸ Another alternative would be carrying out bone graft. Since the patient presented with bimaxillary protrusion, extraction of #14, #24 and #35 teeth was considered as being more favorable.

TREATMENT PROGRESS

Treatment was carried out as planned. After extraction of #14, #24 and #35 teeth, the fixed appliance was bonded to both arches. Subsequently, alignment and leveling were carried out with the use of NiTi and 0.020-in SS archwires. As a result of the use of those archwires, maxillary canines, first premolars and mandibular canines were retracted with elastomeric chain connected to second molars. After complete retraction of premolars and canines, retraction 0.019 x 0.026-in

SS archwires with vertical teardrop loops were manufactured for space closure in both arches. An additional lower archwire with unilateral T-loop was rendered necessary for space closure finishing on the left side. Once space closure was complete, 0.019 x 0.026-in SS archwires were placed for finishing. The use of Class II bilateral intermaxillary elastics, especially on the left side, was rendered necessary for a few months. Treatment was concluded within the estimated time of 24 months (Fig 5).

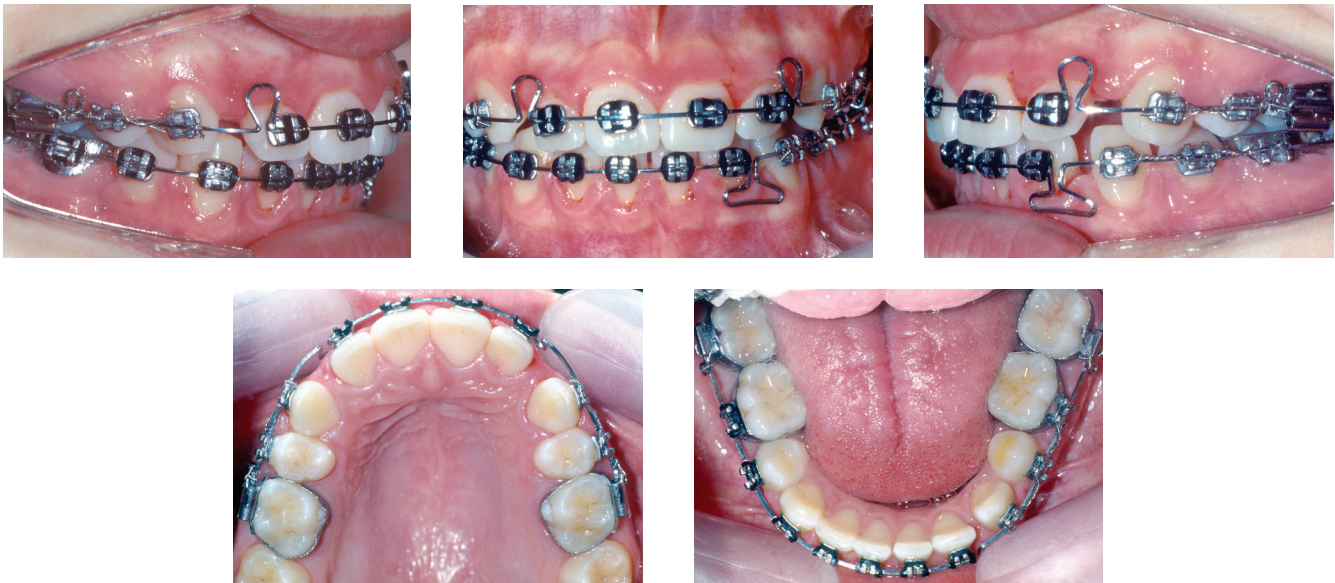


Figure 5 - Intermediate photographs (incisors retraction).

RESULTS

Facial analysis carried out after orthodontic appliance removal suggested significant improvement in facial profile, which became straight by the end of treatment. The patient reported herein achieved spontaneous lip seal and a highly pleasing smile, with corrected smile line, showing 100% of anteriorsuperior teeth (Fig 7).

Intraoral assessment revealed excellent intercuspation with molars and canines positioned in correct Class I relationship. Overbite and overjet correction

was achieved and dental midlines were coinciding with each other and with the facial midline. Spaces and dental rotation were eliminated in both arches. Second molars were well positioned and in correct occlusion (Figs 6 and 7).

Final radiographs revealed root parallelism and absence of significant root resorption. It was also noted that due to extractions carried out during treatment, enough spaces were created, so as to allow eruption of all four third molars within natural time (Fig 8).

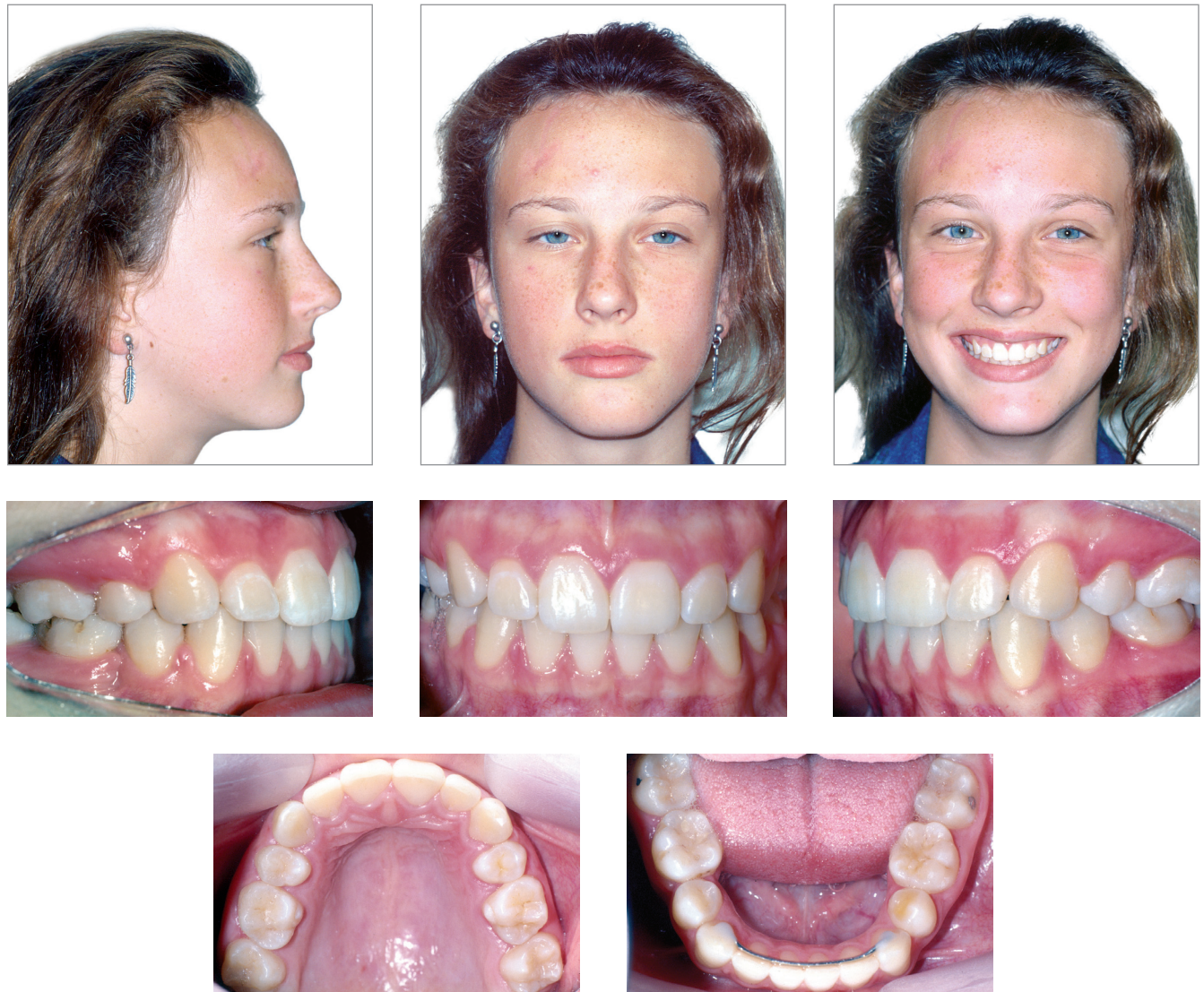

Figure 6 - Final facial and intraoral photographs.

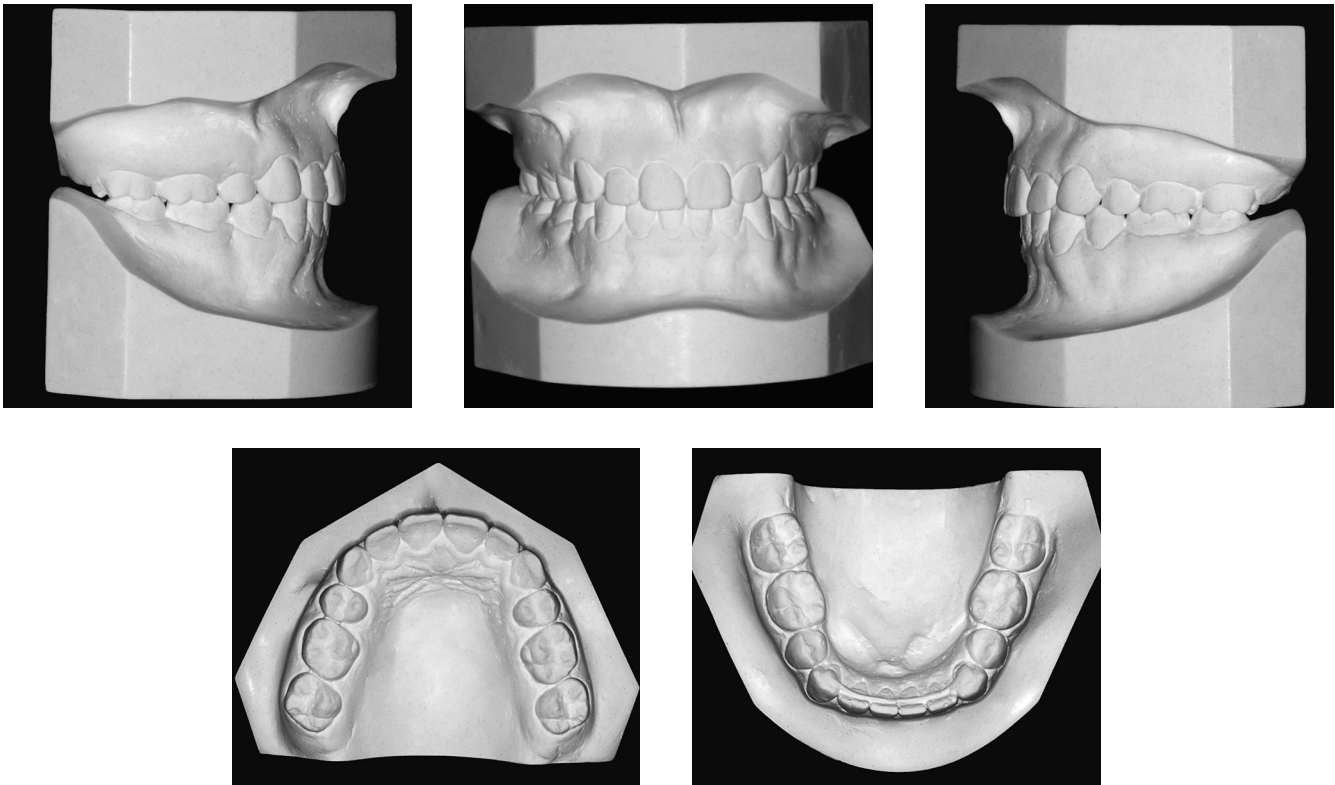


Figure 7 - Final casts.

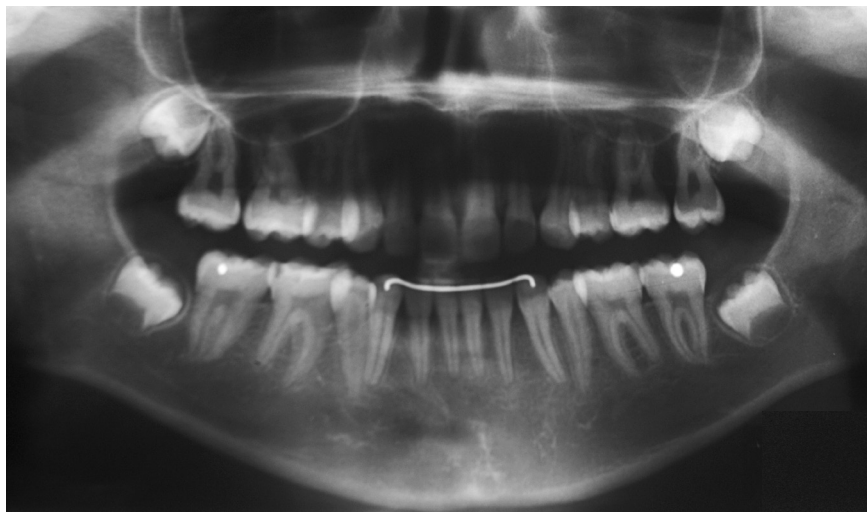


Figure 8 - Final panoramic radiograph.

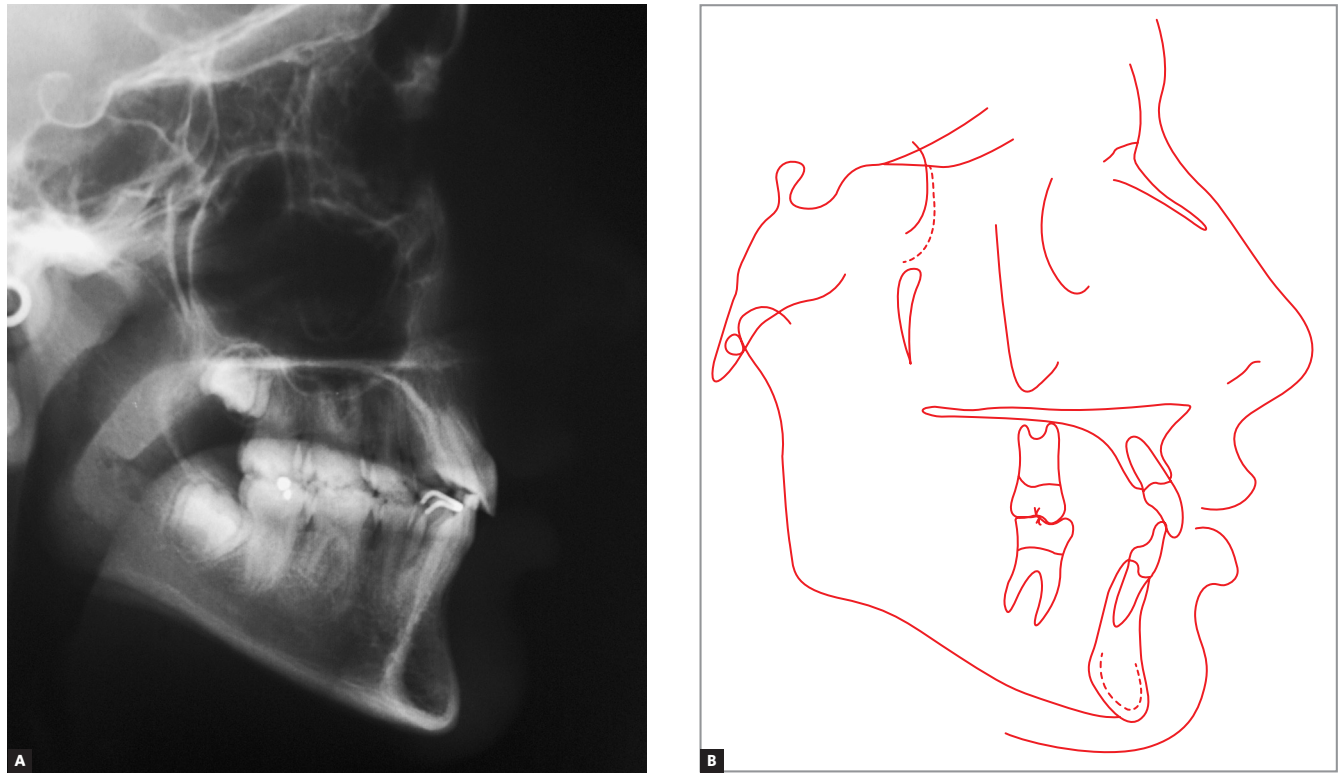


Figure 9 - Final lateral cephalogram (A) and cephalometric tracing (B).

Cephalometric analysis suggested that Class II skeletal pattern remained unchanged ($ANB = 5^\circ$), in addition to a slightly decrease in predisposition to vertical facial growth ($FMA = 28^\circ$, $Y\text{-axis} = 62^\circ$). Moreover, bimaxillary protrusion was eliminated and lower and upper lips remained 0.5 and 1mm forward in relation to the S-line, respectively ($1.NA = 3\text{mm}$, $1.NB = 3\text{mm}$, and $IMPA = 92^\circ$) (Fig 9).

Analysis of initial and final cephalometric tracings superimposition revealed that the patient presented satisfactory growth pattern, incisors were relocated, especially the maxillary ones, and molars were in mesial position as a result of extractions carried out during treatment (Fig 10).

TEN YEARS AFTER TREATMENT

Records obtained ten years after orthodontic treatment conclusion revealed complete stability of achieved results. Third molars erupted in occlusion, except for #38 tooth, which remained semi-impacted, thus needing to be uprighted for further disimpaction (Figs 11 and 12).

Radiographic assessment revealed healthy teeth and supporting structures (Fig 13). Additionally, cephalometric analysis revealed that treatment results remained unchanged, whereas cephalometric tracings superimposition evinced that the patient presented considerable facial growth after orthodontic treatment completion (Figs 14 and 15).

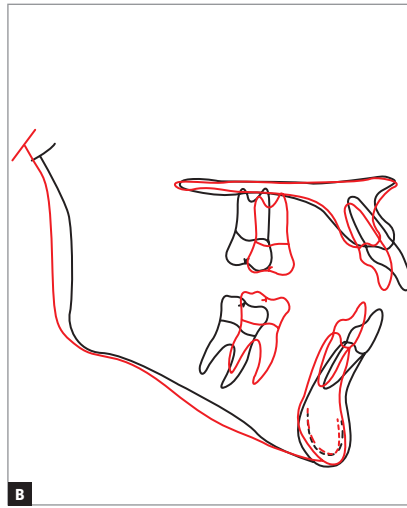
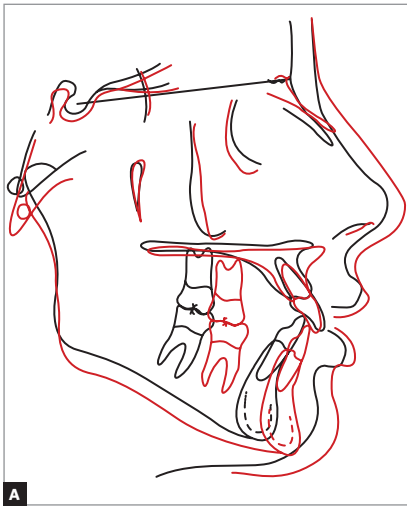


Figure 10 - Total (A) and partial (B) cephalometric superimpositions of initial (black) and final (red) tracings.

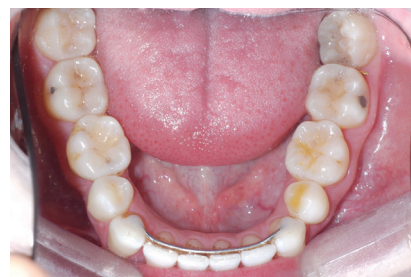
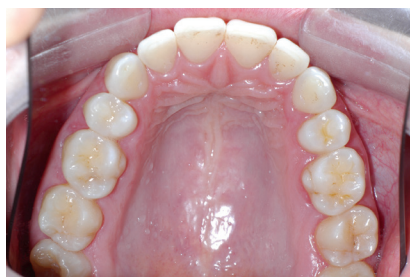
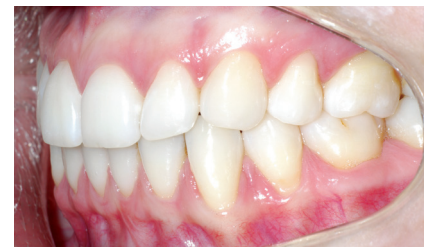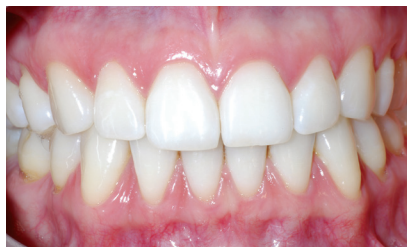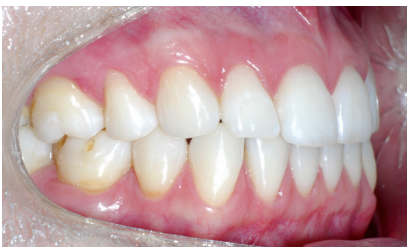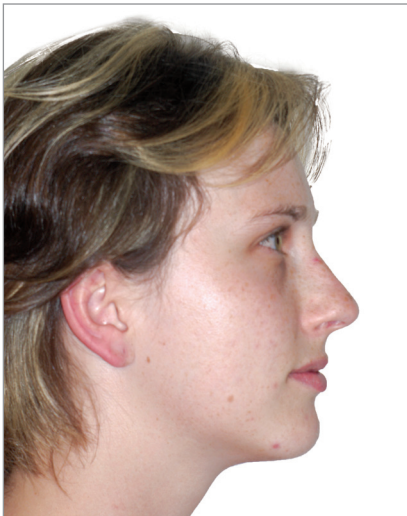Figure 11 - Facial and intraoral photographs ten years after orthodontic treatment.

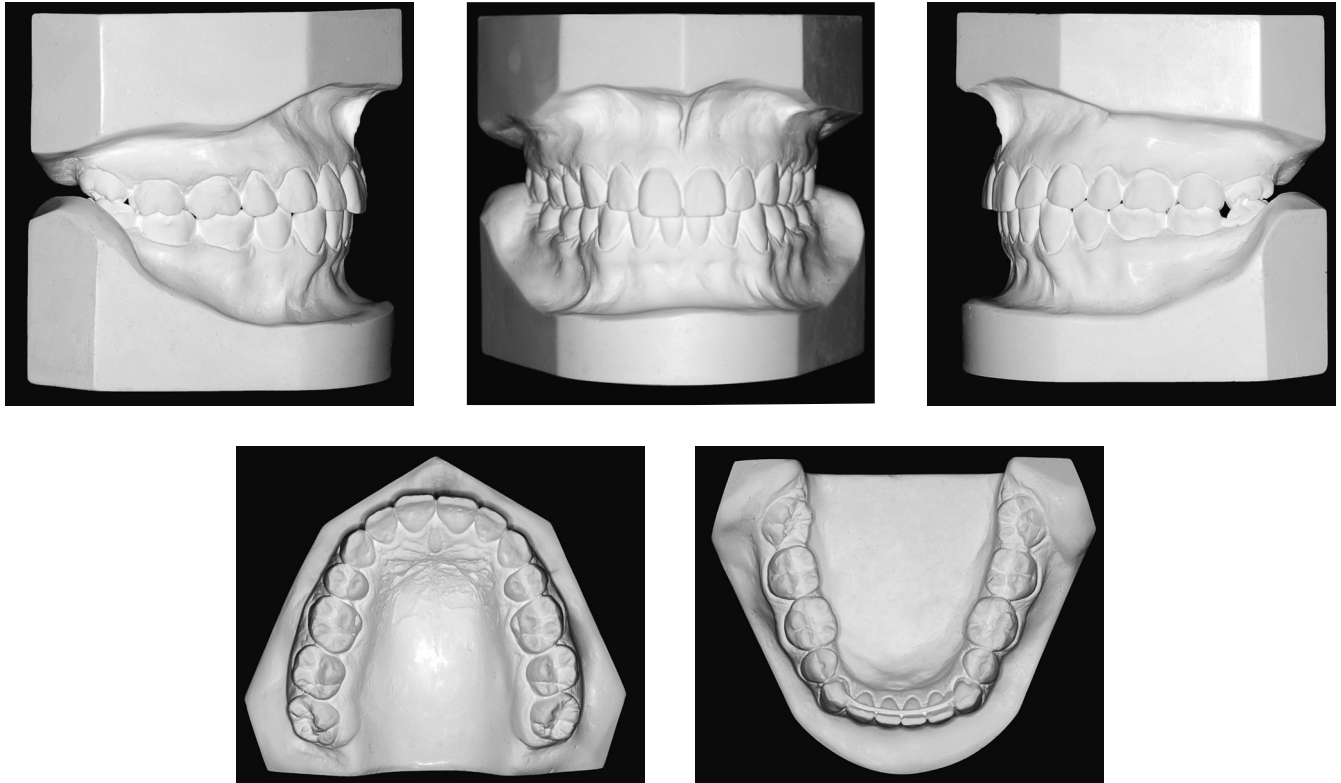


Figure 12 - Casts obtained ten years after orthodontic treatment.

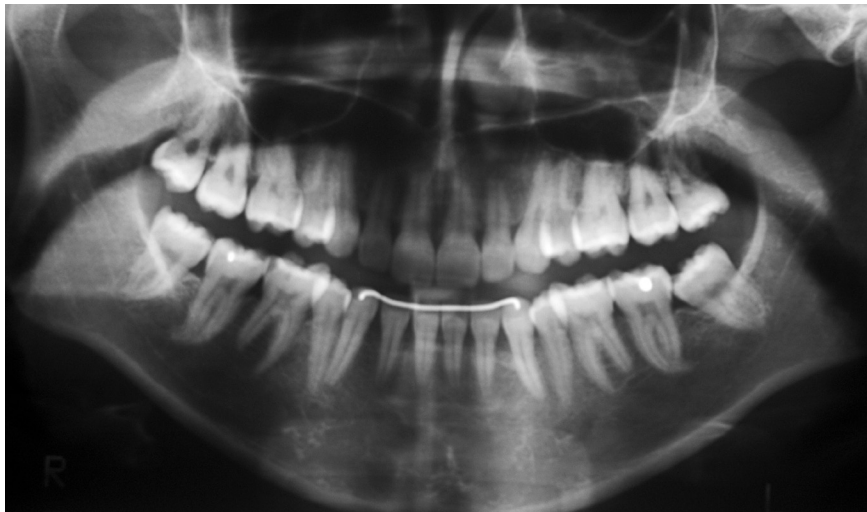


Figure 13 - Panoramic radiograph obtained ten years after orthodontic treatment.

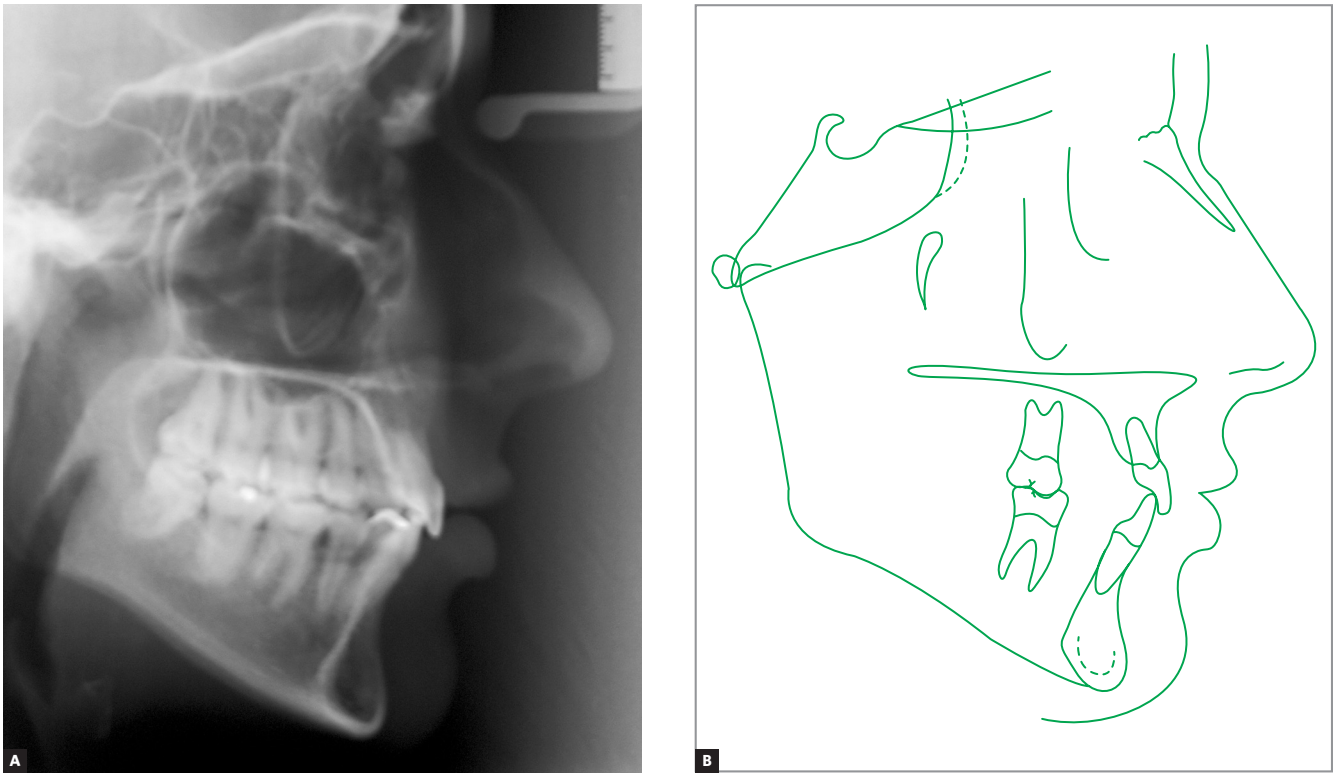


Figure 14 - Lateral cephalogram (A) and cephalometric tracing (B) obtained ten years after orthodontic treatment.

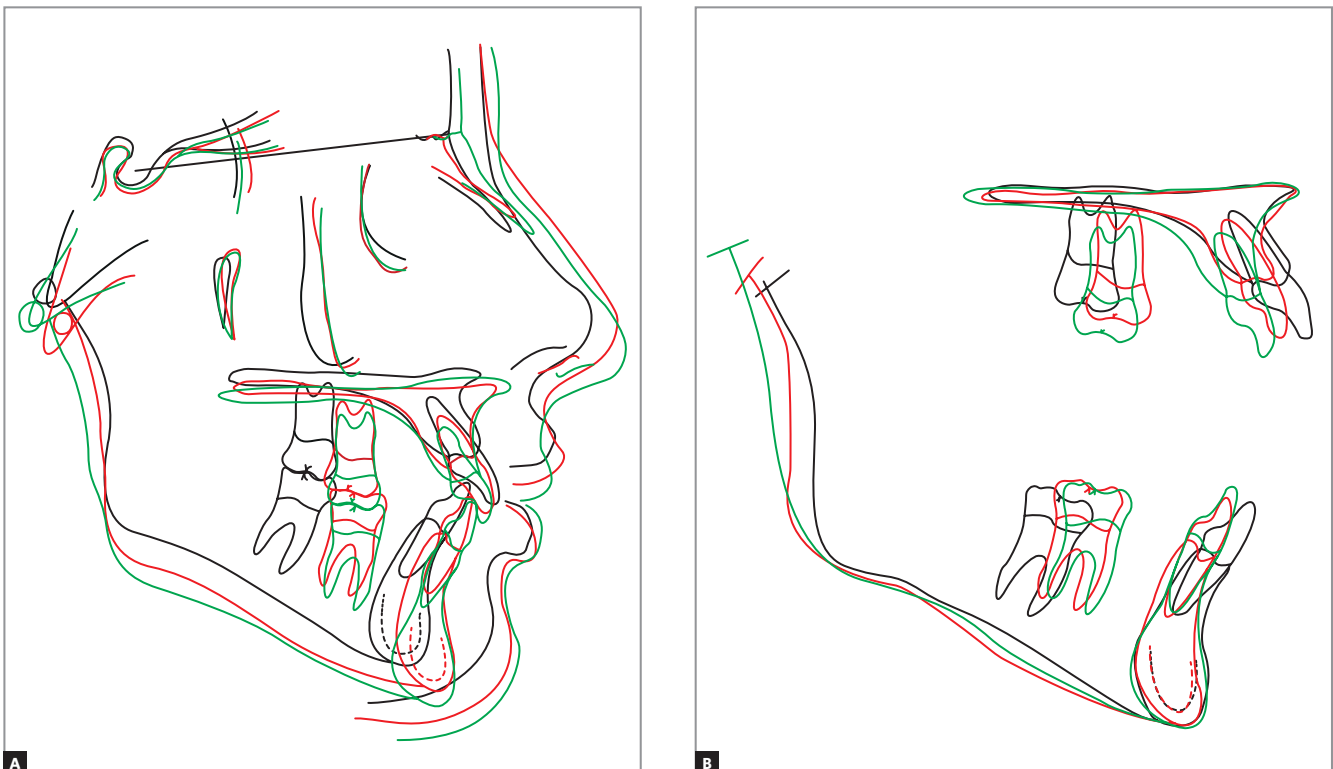


Figure 15 - Total (A) and partial (B) cephalometric superimpositions of initial (black) and final (red) tracings as well as tracings obtained ten years after orthodontic treatment (green).

Table 1 - Initial (A), final (B) and ten years after orthodontic treatment (C) cephalometric values..

Measurements		Normal	A	B	C	A/B diff.
Skeletal pattern	SNA (Steiner)	82°	87°	89°	88°	2
	SNB (Steiner)	80°	82°	84°	83°	2
	ANB (Steiner)	2°	5°	5°	4°	0
	Wits (Jacobson)	♀ 0 ±2 mm ♂ 1 ±2 mm	+3mm	+1mm	3mm	2
	Angle of convexity (Downs)	0°	11°	9°	11°	2
	Y-axis (Downs)	59°	64°	62°	67°	2
	Facial angle (Downs)	87°	85°	84°	88°	1
	SN-GoGn (Steiner)	32°	28°	29°	29°	1
	FMA (Tweed)	25°	29°	28°	27°	1
Dental pattern	IMPA (Tweed)	90°	98°	92°	91°	6
	⊥NA (degrees) (Steiner)	22°	31°	21°	21°	10
	⊥NA (mm) (Steiner)	4 mm	4mm	3mm	3mm	1
	⊥NB (degrees) (Steiner)	25°	32°	24°	23°	8
	⊥NB (mm) (Steiner)	4 mm	3mm	3mm	3mm	0
	$\frac{1}{1}$ - Interincisal angle (Downs)	130°	113°	129°	132°	16
Profile	⊥APo (Ricketts)	1 mm	4mm	1mm	2mm	3
	Upper lip – S-line (Steiner)	0 mm	3mm	1mm	-2mm	2
	Lower lip – S-line (Steiner)	0 mm	2mm	0,5mm	0mm	1,5

FINAL CONSIDERATIONS

Orthodontic treatment with extraction of maxillary first premolars and left mandibular second premolar proved to be a viable treatment option for this case of agenesis of mandibular second premolar, on the right side and bimaxillary protrusion. Results revealed improved facial profile and aesthetics as a whole, in addition to satisfactory occlusion which remains stable ten years after treatment.

REFERENCES

- Gedrange T, Boening K, Harzer W. Orthodontic implants as anchorage appliances for unilateral mesialization: a case report. *Quintessence Int.* 2006 June;37(6):485-91.
- Bergstrom K. An orthopantomographic study of hypodontia, supernumeraries and other anomalies in school children between the ages of 8-9 years. An epidemiological study. *Swed Dent J.* 1977;1(4):145-57.
- Rolling S. Hypodontia of permanent teeth in Danish schoolchildren. *Scand J Dent Res.* 1980 Oct;88(5):365-9.
- Mamopoulou A, Hägg U, Schröder U, Hansen K. Agenesis of mandibular second premolars. Spontaneous space closure after extraction therapy: a 4-year follow-up. *Eur J Orthod.* 1996 Dec;18(6):589-600.
- Zimmer B, Schelper I, Seifi-Shirvande N. Localized orthodontic space closure for unilateral aplasia of lower second premolars. *Eur J Orthod.* 2007 Apr;29(2):210-6.
- ADA Council on Scientific Affairs. Dental endosseous implants: an update. *J Am Dent Assoc.* 2004 Jan;135(1):92-7.
- Ostler M, Kokich V. Alveolar ridge changes in patients congenitally missing mandibular second premolars. *J Prosthet Dent.* 1994 Feb;71(2):144-9.
- Kokich V, Spear FM. Guidelines for managing the orthodontic-restorative patient. *Semin Orthod.* 1997 Mar;3(1):3-20.