

Images in Clinical Hematology

Acute megakaryoblastic leukemia in a pediatric patient



Bernhard Strasser *, Alexander Haushofer

Institute of Clinical Chemistry and Laboratory Medicine, Klinikum Wels-Grieskirchen, Wels, Austria

ARTICLE INFO

Article history:

Received 30 September 2023

Accepted 9 November 2023

Available online 11 December 2023

A 6-month-old patient was referred to our hospital due to abdominal discomfort and additional nonspecific symptoms, including restlessness and refusal of nourishment. Differential blood count analysis yielded marked leukocytosis with 60,000 G/L leukocytes and thrombocytopenia. Reactive causes of this altered hematological and clinical state were excluded, and a leukemic disease was suspected, primarily acute lympho-

blastic leukemia (ALL) as this entity is the most common leukemia of childhood.¹ Microscopic investigation of the peripheral blood confirmed acute leukemia with 29 % blasts; however, unexpectedly, the blasts did not appear as typical ALL blasts. Immunophenotyping confirmed megakaryoblastic leukemia as these blasts were positive for CD13, CD33, CD41, and CD61.²

[Figure 1](#)

* Corresponding author at: Grieskirchnerstraße 42, 4600 Wels, Austria.

E-mail address: Bernhard.Strasser@klinikum-wegr.at (B. Strasser).

<https://doi.org/10.1016/j.htct.2023.11.001>

2531-1379/© 2023 Associação Brasileira de Hematologia, Hemoterapia e Terapia Celular. Published by Elsevier España, S.L.U. This is an open access article under the CC BY-NC-ND license (<http://creativecommons.org/licenses/by-nc-nd/4.0/>).

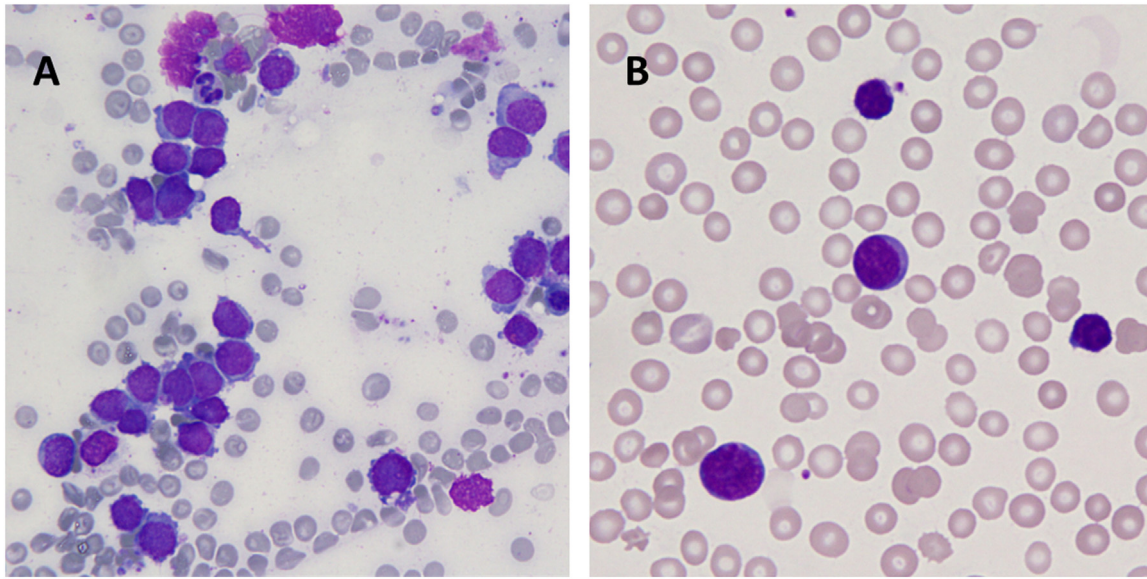


Figure 1 – In bone marrow investigation the megakaryoblasts were enlarged with basophilic cytoplasm, distinctive pseudo-pods (“blebs”), and cytoplasmic projections. In addition, clusters of megakaryoblasts were detected (A). In peripheral blood the megakaryoblasts showed scant cytoplasm and dark stained nuclei (B).

Conflicts of interest

The authors declare no conflicts of interests.

REFERENCES

1. das Chagas PF, de Sousa GR, Kodama MH, de Biagi Junior CAO, Yunes JA, Brandalise SR, et al. Ultraconserved long non-coding

- RNA uc.112 is highly expressed in childhood T versus B-cell acute lymphoblastic leukemia. *Hematol Transfus Cell Ther.* 2021;43(1):28–34.
2. Agrawal S, Kumar K, Singh M, Chandra H. Megakaryocytic blast crisis in chronic myeloid leukemia: an uncommon presentation in a common neoplasm. *Hematol Transfus Cell Ther.* 2022;44(2):264–8.