





## Review article

## Dental consensus on HSCT – Part II: dental Care during HSCT



Marcella Ferreira Gobbi <sup>a</sup>, Mariana Henriques Ferreira <sup>a</sup>,  
Danielle Lima Corrêa de Carvalho <sup>a</sup>, Geisa Badauy Lauria Silva <sup>b</sup>,  
Karina Silva Moreira Macari <sup>c</sup>, Lilian de Jesus Neves <sup>c</sup>,  
Paulo Sérgio da Silva Santos <sup>d</sup>, Luiz Alberto Valente Soares Junior <sup>e</sup>,  
Walmyr Ribeiro Melo <sup>f</sup>, Héilton Spíndola Antunes <sup>g</sup>,  
Leandro Dorigan De Macedo <sup>h,i</sup>, Fernanda de Paula Eduardo <sup>a</sup>,  
Leticia Mello Bezinelli <sup>a,\*</sup>

<sup>a</sup> Hospital Israelita Albert Einstein, São Paulo, SP, Brazil

<sup>b</sup> Serviço de Odontologia do Hospital Araújo Jorge/Associação de Combate ao Câncer em Goiás, Goiânia, Goiás, Brazil

<sup>c</sup> Departamento de Odontologia, Hospital de Câncer Infantojuvenil de Barretos do Hospital de Amor, Barretos, SP, Brazil

<sup>d</sup> Departamento de Cirurgia, Estomatologia, Patologia e Radiologia da Faculdade de Odontologia de Bauru, Universidade de São Paulo, Bauru, Brazil

<sup>e</sup> Divisão de Odontologia Instituto Central, Hospital das Clínicas da Faculdade de Medicina-USP

<sup>f</sup> Hospital Samaritano Higienópolis

<sup>g</sup> Divisão de Pesquisa Clínica, Instituto Nacional de Câncer (INCA), Rio de Janeiro, Brazil

<sup>h</sup> Serviço de Odontologia e Estomatologia do Hospital das Clínicas da Faculdade de Medicina de Ribeirão Preto, Brazil

<sup>i</sup> Faculdade de Medicina de Ribeirão Preto da Universidade de São Paulo, Brazil

## ARTICLE INFO

## Article history:

Received 24 March 2023

Accepted 17 April 2023

Available online 30 May 2023

## Keywords:

Hematopoietic stem cell

transplantation

Oral mucositis

Opportunistic infections

Oral microbiota

Oral alterations

## ABSTRACT

During the state of immune vulnerability in hematopoietic stem cell transplantation (HSCT), the patient has an increased risk of developing a vast number of complications, including severe problems in the oral cavity. These situations require professional oral care to act in the diagnosis and treatment of these conditions, as well as to develop prevention protocols to minimize patient's complications. Oral mucositis, opportunistic infections, bleeding, specific microbiota, taste, and salivary alterations are complications that can occur during HSCT and interfere with various aspects, such as pain control, oral intake, nutrition, bacteremia and sepsis, days of hospitalization and morbidity. Several guidelines have been published to address the role of professional oral care during the HSCT, we describe a consensus regarding these recommendations.

© 2023 Associação Brasileira de Hematologia, Hemoterapia e Terapia Celular. Published by Elsevier España, S.L.U. This is an open access article under the CC BY-NC-ND license (<http://creativecommons.org/licenses/by-nc-nd/4.0/>).

\* Corresponding author at: Centro de Pesquisa Clínica, Instituto Israelita de Ensino e Pesquisa Albert Einstein, Av. Albert Einstein, 627/520 São Paulo, São Paulo, CEP 05651-901, Brazil.

E-mail address: [leticia.bezinelli@einstein.br](mailto:leticia.bezinelli@einstein.br) (L.M. Bezinelli).

<https://doi.org/10.1016/j.htct.2023.04.003>

2531-1379/© 2023 Associação Brasileira de Hematologia, Hemoterapia e Terapia Celular. Published by Elsevier España, S.L.U. This is an open access article under the CC BY-NC-ND license (<http://creativecommons.org/licenses/by-nc-nd/4.0/>).

### Statement of clinical relevance

The complications in the oral cavity may increase mortality and morbidity in the different phases of the hematopoietic stem cell transplantation. There is no Brazilian guideline that support the dentist in the assistance of patients subjected to HSCT. This second part of the consensus offers guidance towards dental care during HSCT.

## Introduction

Hematopoietic stem cell transplantation (HSCT) is a rising therapeutic modality used for a wide range of diseases, including malignant and benign hematologic neoplasms, certain autoimmune and immune disorders, some hereditary diseases, among others.<sup>1</sup>

In HSCT, the bone marrow is destroyed by the pre-transplantation conditioning, which consists of high doses of chemotherapy (CT), radiation therapy (RT) or the combination of both. This conditioning does not interfere only with the hemostasis of malignant cells, but also with normal cells, and can result in several oral complications, which impact patient's health condition and increases hospital costs. For this reason, the integration of a dental surgeon (DS) into the multidisciplinary team is fundamental for the diagnosis, prevention and treatment of these complications.<sup>2,3</sup>

In the light of the reported, a group of oral medicine experts was invited by the Brazilian Society of Cellular Therapy and Bone Marrow Transplantation (SBTMO) to prepare a guideline for dental care for HSCT patients, taking into consideration the oral health characteristics of our population.

This is the second article in a series of 3 that will discuss the dental management in HSCT population. These papers intend to provide continuing education to fellow dental surgeons on this specific area of care and, consequently, facilitating HSCT patient's access to dental care.

## Objective

The aim of this part II of the consensus is to clarify which are and how to manage the main aggravations that affect the oral cavity during HSCT.

## Review methods

A narrative review was conducted on the database MEDLINE/PubMed and Embase for papers published from the period of January 2010 to December of 2020. The primary outcome was to retrieve original data on relevant articles containing dental protocols in patients undergoing the HSCT. All original studies in English, Spanish or Portuguese assessing oral health, oral complications and dental procedures in adult and pediatric patients submitted to HSCT were reviewed by the group of oral medicine experts. Papers in duplicate, written in different

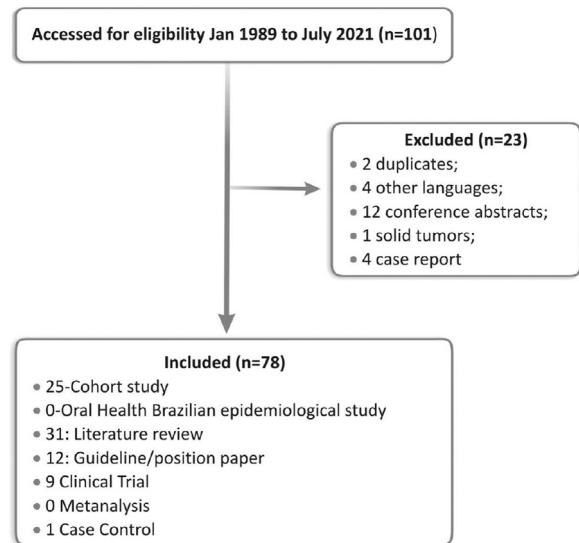


Figure 1 – Flowchart of the study.

languages than the ones mentioned above, conference abstracts, case reports and including solid tumors were excluded.

The panel of experts reviewed the selected papers and then discussed the most important aspects involving oral health through virtual reunions. Thus, the recommendations in these 3 steps guide were obtained based on literature information and in the clinical experience of the experts.

For these second part, the following descriptors were used separately or in combination: hematopoietic stem cell transplantation; oral care; oral mucositis; opportunistic infections; oral microbiota; oral alterations; oral complications; saliva; salivary alteration and taste (Figure 1).

## Review/results and discussion

### Oral care

As addressed in Part I, the adequacy of oral care prior to HSCT is fundamental and the maintenance of a good oral health condition should be checked immediately before the start of the conditioning. As well as it should be discussed the need of special attention due to untreated oral pathology.

Before mentioning the main aggravations, it is important to reinforce the importance of oral care during HSCT, once at this point the patient will be in bone marrow aplasia, immunocompromised and extremely susceptible to infections and systemic unbalances. It is worth noting that it is important that the oral hygiene (OH) instructions are followed only after the DS assessment, because oral care should be studied and individualized according to the time of transplantation, the patient's age, general health condition, oral health, and oral complications.<sup>4</sup>

As a general recommendation, it is indicated that the patient performs appropriate mechanical and chemical control of the dental biofilm, through tooth brushing, dental floss and alcohol-free mouthwash. Traditionally, the mechanical

control of bacterial plaque is given through the use (after meals) of toothbrushes and dental floss/tape.<sup>4,5</sup> The use of dental floss or other devices, such as inter-dental brush, might be recommended to complement the removal of dental and tongue biofilm, however, they should be handled with caution and when the patient masters the technique of use to prevent trauma in gingival and mucous membranes. If the patient has removable prosthesis, it is indicated likewise the mechanical removal of residues and chemical removal through disinfectant solutions.<sup>5</sup> The use of toothpaste containing fluoride is recommended as well given the high probability of salivary alterations and consequent decrease in the protection against caries development. It is worth remembering that toothpastes with sodium lauryl sulfate should be prescribed carefully if the patient uses products containing chlorhexidine digluconate, because of the interaction of both substances, decreasing the antimicrobial effectiveness of chlorhexidine if it is immediately used after brushing.<sup>6</sup>

Likewise in adults, children OH should never be interrupted, it should be adequate to the current clinical situation. Moreover, it is necessary to instruct parents regarding the use of toothpaste containing fluoride since the eruption of the first tooth, in the amount recommended by the DS. Biofilm control should be performed through mechanical and chemical methods. Depending on the age range, an adult should obligatorily perform it or supervise it directly. In some situations, OH and use of cleaning solution should be performed by the dentistry team. The degree of independence, motor coordination, risk for aspiration and the clinical situation of the child should be considered.<sup>7</sup>

Children with hyposalivation rarely complain about dry mouth, so it is recommended to pose some questions focusing on daily situations that could reveal signs and symptoms suggestive of xerostomia. Mouthwashes must not contain alcohol and should be used as a complement to tooth brushing in children who are able to perform oral rinse without risk of swallowing and/or aspirating. If indicated, topical use on the mucous membranes using gauze should be recommended to guardians or the nursing team.

Among children, the prevalence of dental caries is higher than in adults and this may lead to significant damages, mainly in immunocompromised children. In HSCT, the due to a specific diet (often with a high grade of sugars and carbohydrates), and with pasty consistency, the risk of developing caries is particularly increased.

Dry mouth and lips are also a very common complication at this stage of treatment; it can lead to disruption of the mucosal barrier and microorganism's translocation, with a higher risk of infectious conditions in this period of immunosuppression. The use of lip balms and conditioners, such as purified lanolin-based products, should be indicated for controlling and treating those ulcerations and for giving patients some comfort as well. Enzymatic agents and saliva substitutes (moisturizing gel/spray) can also be prescribed.<sup>4,5</sup>

Regarding the use of mouthwashes, given all salivary alterations in the oral mucosa, the use of alcohol-free solutions is indicated after tooth brushing during the whole HSCT. There are options such as enzymatic solutions (with antimicrobial action by the action of lactoferrins, lysozymes and lactoperoxidase), which are highly effective, however at a

higher cost.<sup>8</sup> Auxiliary antimicrobial agents such as 0.12% chlorhexidine digluconate are indicated when the patient develops oral infections in general. This substance is broadly indicated for the reduction of oral pathogenic microorganisms, such as for example in gingivitis, post-operative situation or infections in the oral cavity. However, it is not recommended for the purpose of prevention or treatment of oral mucositis.<sup>4</sup>

### Oral mucositis and microbiota

Oral mucositis (OM) is considered an inflammatory process resulting from the cytotoxic action of some chemotherapeutics and the ionizing radiation. CT and RT treatments also affect oral and intestinal microbiota.<sup>9,10</sup> OM can be characterized clinically by the presence of erythema, pseudomembrane and/or ulcerations in non-keratinized layers of the oral cavity. The rupture of the epithelial barrier integrity is an inflammatory process, but it may also allow the access of microorganisms to inner layers of the epithelial tissue and to the blood stream, which in immunosuppressed patients might mean higher vulnerability to local secondary infections, bacteremia (by translocation) and sepsis.<sup>10,11</sup>

The unbalance in this ecosystem, or dysbiosis, changes the established relationships and leads to the diversification of the present (exogenous) species, which can be potentially more pathogenic for the host.<sup>12</sup> This altered state elevates the level of inflammatory cells. In HSCT, the patient is subjected to conditioning regimes that can include both therapeutic modalities and immunosuppressive agents. Current studies suggest that there is a reduction of commensal bacteria in patients undergoing HSCT after the conditioning regimen, as well as the changes in microbial diversity (mostly a decrease).<sup>9,11–13</sup>

Recently, it has been discussed the role that oral microbiome (including bacteria, viruses, and fungi) plays not only in the colonization of lesions already established in the oral cavity, but in its pathogenesis and modification of the disease course,<sup>14</sup> more specifically, bacteria present in the periodontium and mucosa, herpes simplex virus (HSV) and *Candida albicans*.<sup>13</sup> This was mainly influenced by the discovery of changes in the pattern of this microbiome in patients subjected to CT and by the influence that the already known intestinal microbiota exerts on conditions such as gastrointestinal mucositis.<sup>10</sup> We should consider the existing differences between the intestinal mucosa and OM; however, we cannot rule out completely that the microbiome may influence mucositis in a similar way in these two environments.<sup>15</sup>

Dysbiosis, in turn, is capable of activate or influence innate immune response and the  $\kappa\beta$  nuclear factor pathway (NF- $\kappa\beta$  – transcription factor), a key factor to trigger the process of OM initiation. Altered oral microbiota generates metabolites that increase inflammatory response and activate several signaling pathways (with emphasis on polyamine pathway).<sup>9</sup> Therefore, the dysbiosis of the oral microbiota may exacerbate and/or extend the OM course. The depletion of commensal bacteria was also related to OM severity.<sup>13</sup>

It puts forward the hypothesis that inflammatory processes, such as periodontal disease, which are modulated by

microbiota, leave the patient more vulnerable to ulcerative OM.<sup>16</sup>

Most studies confirm the decrease of the diversity of oral microbiota species after HSCT,<sup>9,11,12</sup> and many articles report a recovery to the initial composition after a few months. In addition to species reduction, alterations of the Shannon index (diversity index based on bacterial species) and the presence of bacteria with higher pathogenic potential were noticed a few days after conditioning, which may increase the chance of developing ulcerative OM.<sup>9</sup>

Bacteremia caused by the translocation of bacteria from the oral cavity is also a concern in this profile of patients, particularly after conditioning, once in many cases these bacteria can be resistant to antibiotic prophylaxis regimens.

The pathogenesis of mucositis, broadly known and accepted, involves three major processes: cell death directly induced by CT or RT, the formation of reactive oxygen species (oxidative stress) and activation of the innate immune response. As the mucosa injury process progresses, changes in the microflora in the oral and intestinal cavity were observed. The origin of these changes may be attributed to CT regimen, immunosuppression period, xerostomia, antibiotic therapy and a series of variables of the own patient and treatment.<sup>10</sup> It is also well established that the myelosuppression caused by chemotherapy influences the oral microbiota and leads to later dysbiosis.<sup>13,14</sup>

Sonis' model briefly explains OM pathogeny through the contact of chemotherapy and ionizing radiation agents which triggers molecular events in the mucosa and submucosa. These events are explained in five phases: initiation, message generation, signaling and amplification; ulceration and healing. Beginning with signaling loss among epithelial cells and cells of the conjunctive tissue of the mucosa, mainly fibroblasts and endothelial cells, which generates unbalance in both tissue compartments. This unbalance culminates in the loss of cellular proliferation and high apoptosis rate in both compartments. The clinically observed ulceration, for instance, results from the absence of epithelial renewal and the high rate of death of epithelial cells. Erythema, in turn, is the clinical manifestation of the vasodilation present in the inflammation that develops in the conjunctive system.<sup>17,18</sup>

Mucositis may manifest as dysphagia, pain, inflammation, diarrhea, and bleeding. This process may affect both the oral cavity and the esophageal and gastrointestinal tract. OM can affect about 60 to 85% of patients under HSCT.<sup>19</sup>

**Table 1 – WHO Scale – Classification of the World Health Organization, 1979.**

Grade 0	absence of lesions
Grade 1	erythema and discomfort, with or without painful symptomatology
Grade 2	presence of ulcers, erythema, solid diet tolerated
Grade 3	presence of oral ulcers, liquid diet only
Grade 4	presence of oral ulcers, oral alimentation impossible

**Table 2 – Oral Mucositis Assessment Scale (OMAS), 1999.**

Sites	Ulceration	Erythema
Upper and lower lip mucosa	0 = absent	0 = absent
Right and left jugal mucosa	1 = <1cm <sup>2</sup>	1 = mild
Tongue (dorsum and body, lateral sides)	2 = 1 to 3 cm <sup>2</sup>	2 = intense/severe
Mouth floor	3 = >3cm <sup>2</sup>	
Hard and soft palate		

Each site is individually graded both for ulceration and erythema (range from 0 to 5), using the scales below; one should also write down if there is any difficulty to swallow or eat solid food. The value is obtained by summing the erythema and ulceration sub scores at each site.

Some studies points to differences in the microbiome of patients presenting OM, in comparison to patients that did not present it, and suggest the relationship between some bacterial and fungal species and ulcerative OM in patients subjected to HSCT, such as *Porphyromonas gingivalis* (present in periodontal disease), *Enterococcus* sp., *Staphylococcus* sp., Proteobacteria, and *Candida* sp.<sup>14,20–24</sup>

OM severity can be clinically classified based on several grading systems through visual inspection.<sup>25</sup> The most currently used assessment criteria are described in Tables 1 and 2.<sup>26</sup>

The most used scale is the one by the World Health Organization (WHO), once it is easier to perform. The Oral Mucositis Assessment Scale (OMAS) is more complex and complete, because it considers the site of oral lesions, the area of ulcerations, and intensity of erythema.<sup>25</sup> Other scale broadly used for being very comprehensive is the Common Terminology Criteria for Adverse Events (CTCAE), illustrated in Table 3, in which it is possible to classify oral mucositis separately from the symptom of dysphagia (difficulty in swallowing), based mainly on the symptoms reported by the patient.<sup>27</sup> Dysphagia, often followed by severe oropharyngeal pain, may occur

**Table 3 – Common Terminology Criteria for Adverse Events (CTCAE) Scale, version 5.0, with a specific cut to grade OM and dysphagia (gastrointestinal disorders), 2017.**

CTCAE Term	Grade 1	Grade 2	Grade 3	Grade 4	Grade 5
Mucositis - oral	Asymptomatic or mild symptoms; intervention not indicated	Moderate pain or ulcer that does not interfere with oral intake; modified diet indicated	Severe pain; interfering with oral intake	Life-threatening consequences; urgent intervention indicated	Death
Dysphagia	Symptomatic, able to eat regular diet	Symptomatic and altered eating/swallowing	Severely altered eating/swallowing; tube feeding, TPN, or hospitalization indicated	Life-threatening consequences; urgent intervention indicated	Death

TPN, Total parenteral nutrition.

even in the absence of ulcerations in the oral cavity and cause important alterations in the diet pattern during HSCT.

The use of photobiomodulation (PBM) with low power laser (LPL) is one of the strategies for OM prevention and treatment with well-established results by the literature.<sup>28,29</sup> Studies show that when the LPL protocol is performed in a daily basis in HSCT, from conditioning to neutrophilic engraftment, the risk of the patient presenting severe mucositis is 13 times lower. The irradiation protocol may range between 1 and 3 J per point, at red wavelength (660 nm), depending on the therapeutic aim (OM prevention or treatment).<sup>30</sup> It was also shown that PBM is a short- and long-term safe therapy, it does not increase the risk of developing secondary neoplasia and it collaborates to patient's higher survival.<sup>31</sup>

Other broadly used therapeutic resource in OM prevention is cryotherapy, which consists in the application of intraoral ice or rinse with cold water; it will decrease the mucosal temperature, promoting vasoconstriction that will reduce the circulation of the drug in the oral mucosa. In other words, it stops the chemotherapeutic agent from getting to mouth tissues at high doses, reducing toxicity and consequently damages to mucosa. Cryotherapy is currently indicated when short half-life drugs such as melphalan are prescribed in the HSCT conditioning regimen.<sup>28,32,33</sup> According to the guidelines and more recent studies, cryotherapy is performed during the melphalan infusion, it can be administrated up to 5 min before the beginning of the drug infusion and prolonged up to 30 min after.<sup>28,32</sup>

### Salivary alterations

Salivary alterations and dysfunctions in major salivary glands (SG) may occur in HSCT patients. Saliva is a fluid composed of water, ions and proteins and it has several functions, such as antimicrobial action and defense mechanisms, thus, alterations, such as the decrease of salivary flow and secretion of antimicrobial factors during HSCT, might be associated with OM severity.<sup>34</sup>

The main symptom that the patient may present due to alteration of the salivary flow is xerostomia (dry mouth sensation), which can be or not a sign of hyposalivation (decrease in salivary flow).<sup>35</sup> Damages in the mucosa and SG might increase the risk of infections, caries disease processes, difficulty in chewing, swallowing and speech, as well as weight loss.<sup>39</sup> Salivary alterations may occur immediately after HSCT and persist until the SG defense mechanism recovers around the sixth month after HSCT.<sup>36</sup>

In addition to the chemotherapeutic agents used in HSCT conditioning, the antiemetic, antihypertensive and antidepressant drugs that the patient receives during HSCT may cause hyposalivation and alterations in salivary function.<sup>37</sup>

The SG main alterations resulting from HSCT are alterations in salivary flow, rate of salivary immunoglobulins, in salivary enzymatic and protein components, in salivary ionic components, alterations in the SG volume and histopathological features.<sup>38,39</sup>

The chart below (Table 5) shows the alterations found during HSCT in the literature.<sup>36,38,39</sup>

There is also reactive oxygen species (ROS) leading to damages to the deoxyribonucleic acid (DNA) of the epithelium and oral submucosa, causing clinical and histological alterations both in oral mucosa and periodontal tissues and in gland dysfunction. The antioxidant potential of saliva is composed of enzymes (lysozyme, immunoglobulin A [IgA] and salivary amylase) and antioxidants (peroxidase, superoxide dismutase [SOD], and uric acid), responsible for approximately 70% of this function. The increase in SOD concurs with the onset of OM, which could be a salivary defense mechanism against the oxidative stress produced by chemotherapy (CT), as well as uric acid showed a decrease in the same phase, favoring the severity of oral mucositis.<sup>39</sup>

Saliva has been also used for the evaluation of the concentration of some CTs, such as busulfan (BU), in which a correlation with OM severity and a conversely proportional correlation between salivary SOD and catalase activity were observed, there might be a correlation between OM severity and duration with salivary levels of busulfan.<sup>35,40</sup>

### Taste alterations

Taste disorders are common in HSCT patients and may present as loss of sense of taste (ageusia), changes (dysgeusia) or increased (hypergeusia) or decreased (hypogeusia) sensitivity. Such impact in this population leads to the reduction of interest in food, decrease of oral intake, nutritional impairment and weight loss, in addition to negative impact on the quality of life.<sup>41</sup>

Patients subjected to HSCT showed a significant worsening in up to 29 times of the sense of taste after the beginning of the conditioning. About 30% of patients showed taste alteration on day 100 and 44%, until 6 years after transplantation.<sup>37,42</sup> One of the mostly accepted hypotheses to justify the taste alteration in patients with onco-hematological diseases is that systemic therapy causes cytotoxic damages in taste receptor cells, which have a high turnover. These specialized cells have a relatively short lifespan of 10 days. The injury to these receptors may alter or interrupt neural coding.<sup>43</sup> In addition, several drugs prescribed during HSCT, as prophylaxis for infections or treatment of comorbidities, stimulate the development of dysgeusia for their effects on the sensory system. Anti-inflammatories and antibiotics may also exacerbate taste alteration.<sup>44</sup>

Zinc sulfate can be beneficial to prevent CT and RT-induced taste alterations; nonetheless, the studies still have limitations and conflicting results. Therefore, at present, no consensus is possible regarding efficient treatment for taste alterations in HSCT patients, (Table 4).

### Oral infections, coagulation disorders or thrombocytopenia

In HSCT, the bone marrow is destructed by the so-called conditioning, which leads the patient to pancytopenia, increasing the risk of bleeding and infections. Within normality parameters, any patient presenting less than 150.000 platelets/mm<sup>3</sup> is considered thrombocytopenic. In HSCT, it is common that patients present even lower indices, often below 10.000 platelets/mm<sup>3</sup>. Therefore, episodes of spontaneous oral bleeding may appear, even in patients with higher platelet numbers.<sup>45</sup>

**Table 4 – Methods for OM prevention and treatment according to the last published guidelines.**<sup>3,26–31</sup>

	Agent name	Administration route	Indication	Level of evidence	More effective action in OM	Determination Current Guideline	Note
<b>Anti-inflammatory</b>	Benzydamine	Mouthwash	T	III	Analgesia	No	Suggested for other profile of patients (RT)
<b>Analgesics</b>	Morphine	Mouthwash	T	III	Analgesia and Repair	No	Morphine as mouthwash at the concentration of 0.2%
	Doxepin	Mouthwash	T	IV	Analgesia	Yes	It is suggested that Doxepin at 0.5% as mouthwash can be effective for pain management in OM
	Fentanyl	Transdermal	T	III	Analgesia	Yes	It is suggested that transdermal Fentanyl can be effective for pain management in OM
<b>Antimicrobial</b>	Methadone	Sublingual	T	V	Analgesia	No	
	Clarithromycin	Oral	P	III	Antibiotic and immunomodulation	No	
	Isegaran	Topical and systemic, Mouthwash	P	II	Antibiotics	Contraindicated	
<b>Mucoadherent</b>	Sucralfate	Mouthwash and systemic	P and T	I	Antiulcer	Contraindicated	
<b>Supplement</b>	Glutamine	Oral	P	III	Anti-inflammatory	No	More effective for HSCT according to the guideline
		Parenteral	P	I	Anti-inflammatory	Contraindicated	Glutamine through parenteral route is not recommended for OM prevention in HSCT patients
<b>Growth factors and cytokines</b>	Palifermin (KGF-1)	Intravenous	P	I	Maintenance of epithelial barrier	Yes	The use of KGF-1 IV is recommended for preventing oral mucositis in patients subjected to HSCT in conditioning regimens that include high doses of CT and TBI
		GM-CSF	Subcutaneous	P	III	Maintenance of epithelial barrier	No
<b>Antioxidant</b>	Amifostine	Mouthwash, topical	P	II	Maintenance of epithelial barrier	Contraindicated	
		.	.	.	.	No	Efficacy was not proved for this patient group
	Zinc	Oral	P	II	anti-inflammatory	No	Efficacy was not proved
	N-acetyl cysteine (NAC)	Systemic	P	II	antioxidant	No	
	Vitamin E		T	III	antioxidant	No	

**Table 4 (continued)**

Agent name	Administration route	Indication	Level of evidence	More effective action in OM	Determination Current Guideline	Note
<b>Physical agents</b>						
I (P)	Rinse and swallow			Photobiomodulation	intraoral	P and T Recommended by the guideline
	Biomodulation, Analgesia, Anti-inflammatory	Yes				
Cryotherapy	intraoral	P	II	Vasoconstriction	Yes	The guideline recommends the use of oral cryotherapy to prevent OM in HSCT patients when conditioning includes high doses of Melphalan
<b>Natural agents</b>	Chamomile	topical	P	III	Anti-inflammatory	No

OM: oral mucositis; RT: radiation therapy; GM-CSF: Granulocyte and Macrophage Colony Stimulating Factor; P: prevention; T: treatment.

**Table 5 – Salivary alterations during HSCT.**

HSCT	ALTERATIONS FOUND
Autologous HSCT	↑Albumin
Autologous HSCT D + 7	↓ IgAs
Allogeneic HSCT	↑Albumin ↑Lactoferrin ↑Secretory Leukocyte Protease Inhibitor ↑ β <sub>2</sub> microglobulin ↑ proinflammatory proteins ↑TNF-α ↑ Il-1
Allogeneic HSCT From D + 8	↓ iP and Uric Acid ↑ Na, Cl and SOD
1 month after allogeneic HSCT (non-stimulated saliva)	↓ IgAs
1 month after allogeneic and autologous HSCT (>14 years/stimulated saliva)	↑ IgA and IgG
D + 80 Allogeneic HSCT	↑ Na, Cl and K

IgA-s = Secretory Immunoglobulin A; TNF-α = tissue necrosis factor alpha; Il-1 = Interleukin 1; iP = Inorganic Phosphorus; Na = Sodium; Cl = chlorine; SOD = superoxide dismutase; K = Potassium; IgG = Immunoglobulin G.

<sup>47</sup> In addition, the oral cavity shows unique and peculiar characteristics, such as the presence of the oral biofilm. Periodontal disease, especially gingivitis, are potential triggers for the onset of oral bleeding (bleeding gums).<sup>47,48</sup> Some oral findings, such as petechiae and “spontaneous” bleedings in periodontal tissue, are commonly found in this group of patients. Active and intense bleedings, as well as malformed blood clots, are classical characteristics in patients under HSCT conditioning and immediate post-HSCT.<sup>48–50</sup>

In terms of dental management, it is recommended to do the mouth preparation before HSCT (Consensus – Part 1), mitigating dental situations that contribute to bleeding, and daily clinical follow-up advising the patient to not manipulate the clot, which is often reabsorbed after platelet transfusion. If necessary, invasive procedures can be performed during the thrombocytopenia phase with the appropriate medical support.<sup>51</sup>

To determine if the procedure involves higher or lower risk of bleeding, an equation must be developed with the following elements: dental procedure’s extension, opportune timing to perform the procedure, hematologic parameters, blood transfusion support available, local hemostatic measures available.

An accurate surgical technique performed or supervised by an experienced and qualified professional is needed as well as the appropriate local hemostatic method. Within the set of local hemostatic methods, the local control of fibrinolysis and appropriate suture, are key factors for success. The topical use of antifibrinolytics agents, such as tranexamic acid and/or aminocaproic acid, on the bleeding site, are extremely important either dressing in the liquid form (rinses and compresses) or macerated in the form of compressive dressing. Suture, whenever possible, should be performed using non-absorbable suture for a better control of the permanence of tissue approximation and surgical edges.<sup>47</sup> The chosen technique is simple interrupted stitch with appropriate spacing. Other hemostatic methods suitable to be used in these situations are collagen or cellulose sponges and fibrin sealant according to their indications and adequate technique.<sup>47,48</sup>

OM, apart from being debilitating in terms of pain and entrance door for infections, is a risk factor for the onset of bleeding. In this situation, the approach should be multifactorial both for bleeding control and for OM itself.<sup>51,52</sup>

As mentioned before, the white series is also affected during HSCT, leading patients to a period of neutropenia, leaving them susceptible to the development of infections, including oral infections, with a high potential of evolving to more severe conditions, such as sepsis.

### Bacterial infections

The integrity of the oral mucosa is particularly affected during HSCT, which directly reflects on dental biofilm conditions. Concurrently, there are alterations in salivary flow and constituents, leading to states of xerostomia that may predispose to the increase of the amount biofilm and modifications of bacterial flora.<sup>9,36</sup> Patients may even manifest necrotizing ulcerative gingivitis, in which the marginal gingiva shows extensive areas of necrosis, with whitish pseudomembrane and spontaneous bleeding or at manipulation.<sup>53</sup> In addition to odontogenic infections, other bacterial infections may affect patients subjected to HSCT, such as

- Actinomycosis: is caused by *Actinomyces* sp., gram-positive facultative anaerobic bacillus usually found in the oral cavity. *Actinomyces israelii* is the most common species causing oral lesions, restricting mostly to soft tissues, mainly in the cervicofacial region.<sup>54</sup>
- *Pseudomonas aeruginosa*: is a gram-negative flagellated bacteria found in the soil, water, surface of plants and animals. It causes nosocomial infections and has high affinity with the periodontal tissue. These infections start with purplish coloration areas on marginal gingiva, rapidly evolving to gums and bone necrosis. It is highly resistant to antibiotics and antimicrobials<sup>55,56</sup>

In addition to systemic antibiotics for both infections, antimicrobial photodynamic therapy (aPDT) can be used. The most published protocols are with methylene blue dye 0.01% or 0.05%, for 3–5 min, flowed by LPL irradiation, at red wavelength or Light-Emitting Diode (LED) (475–660 nm, 40–100 mW), 1–4 J per point. These combined therapies has shown to be very effective, decreasing the need to adopt more invasive approaches such as the debridement of necrotic tissue.<sup>55,56</sup>

### Fungal infections

Patients subjected to HSCT in the neutropenic phase and/or in use of antibiotics are more susceptible to oral fungal infections. Therefore, medical teams often prescribe prophylactic protocols with systemic antifungals during the period neutropenia.<sup>11</sup> Nonetheless, the surveillance to diagnose oral fungal infections should be carried out by the DS in a regular basis.<sup>57,58</sup>

The most common fungal infection is oral candidiasis, which is subdivided mainly into pseudomembranous, erythematous, and angular cheilitis, caused by the species *Candida albicans* or other members of the genus *Candida*. *C. albicans* is present in the oral microbiota of 20–50% of the population.<sup>12</sup> Dental prostheses (dentures) may predispose the patient to oral candidiasis.<sup>57,59</sup>

In general, the diagnosis is based on clinical exam, but exfoliative cytology (scraping) can show the microorganism more precisely. It is important to determine the *Candida* species due to higher association of *C. glabrata* and *C. krusei* with candidemia, which significantly increases these patient's mortality.<sup>57,59</sup>

The treatment depends on the extension of the infection, ranging from the prescription of a topical antifungal to the use of the systemic antifungal (oral or intravenous) in therapeutic dosage, mainly when there is any suspicion of esophageal, tracheal or other mucosae candidiasis.<sup>57–59</sup>

Topical treatment can be made with rinses and intake of nystatin in oral suspension 100,000 UI/ml, 4–6 ml 4x/day, miconazole 20 mg oral gel 4x/day, keeping the gel in mouth as longer as possible and swallowing after, or even clotrimazole tablet for 7 to 14 days.<sup>57</sup>

Cases of invasive oral fungal infections, such as aspergillosis and mucormycosis, have also been described in immunosuppressed patients,<sup>57–59</sup> they might occur as well in the neutropenic phase of HSCT, particularly in allogeneic HSCT. Nonetheless, invasive fungal infections are more frequent in lung, paranasal sinuses, eyes, central nervous system, and bones.<sup>57–59</sup>

Aspergillosis is caused by species of the genus *Aspergillus*, which are present in the soil, water or organic remains in decomposition. Resistant spores are released in the air and may be inhaled by the patient. Aspergillosis is the second most common opportunistic fungal infection and uses to reach the lung first; it may cause cough, chest pain, and fever. It is possible to detect aspergillosis earlier through the galactomannan research in a blood test or diagnose it through the biopsy of oral lesion where there is already invasive infection.<sup>58,59</sup>

The treatment of aspergillosis in oral cavity may need surgical intervention and administration of systemic antifungals (amphotericin B, voriconazole, and isavuconazole) available in the service and conform to the discussion with the medical team, once the oral cavity can be one of the sites affected by aspergillosis.<sup>57–59</sup>

Mucormycosis or zygomycosis has the major genus involved: *Rhizopus*, *Mucor*, *Lichtheimia* (previously classified as *Absidia*), *Cunninghamella*, *Rhizomucor*, *Apophysomyces*, and *Saksenaia*, found in organic materials in decomposition, and *Cunninghamella* is more associated with patients' mortality. Imaging tests, such as computed tomography (with differential diagnosis of malignant lesions), may present clues for diagnosis, but a biopsy (showing large non-septate fungal hyphae) is mandatory for a conclusion. Mucormycosis uses to reach paranasal sinuses first and reaches oral mucosa subsequently. When the maxillary sinus is affected, the initial presentation may be manifested as increased intraoral volume of the upper alveolar ridge and/or palate. If the disease progresses, there might be massive tissue destruction with necrosis and blackened areas.<sup>57–59</sup>

The treatment of mucormycosis in the oral cavity requires radical surgical debridement of the affected tissue and systemic administration of amphotericin B at high doses and combined therapies (echinocandins and isavuconazole). However, voriconazole should be avoided given its hepatotoxicity potential and drug interactions; it may increase the



concentration of certain drugs in the organism, even leading to a prolongation of the chemotherapy intervals.<sup>57,58</sup>

### Viral infections

The most frequent oral infections in individuals undergoing HSCT are caused by the Herpes simplex virus (HSV) type 1, affecting 50 to 75% of patients and increasing morbimortality. The clinical characteristics of infections triggered by HSV are atypical in relation to oral manifestations in non-immunocompromised individuals; therefore, it is common that they reach non-keratinized and keratinized mucosa, mainly the hard palate, dorsum of the tongue and attached and marginal gingiva; they are extremely painful and multiple, characterized by ulcerated lesions with a fibrinous background, elevated edges, and confluent ulcers.<sup>60,61</sup> The clinical diagnosis is often conclusive, but complementary tests are important and can be performed through exfoliative cytology, where one will find viral inclusion cells using the Tzanck method or gold standard test, which is scraping with scarification of the lesion and Polymerase Chain Reaction test (PCR) for HSV.<sup>60</sup> Positive tests implicate in discussion with the transplanting physician about therapeutic measures regarding the type and dose of antiviral drugs, due to the possibility of systemic infection. PBM and aPDT are highly useful options for the DS for treating pain, reducing the amount of active viruses in lesions, and accelerate ulcer repair. HSV infections might affect patients not only during transplantation (in association with OM), but after HSCT or in association with the oral manifestations of graft-versus-host disease (GVHD).<sup>24,25,61,62</sup>

The infection through Varicella Zoster Virus (VZV) reactivation affects approximately 30% of patients in the period of one year after HSCT, but such incidence has decreased significantly with prophylaxis measures using antiviral drugs. The manifestation in the oral cavity is not frequent and when it manifests, it might affect the branches of the trigeminal nerve, apart from manifestations with vesicular and ulcerated lesions associated with intense pain. The treatment should use antiviral drugs and potent analgesia.<sup>24,59,61</sup>

Cytomegalovirus (CMV) infections can affect up to 50% of patients at post-transplantation, it might be present in SG and endothelial tissue. Oral manifestations of CMV infection are rare and, when they manifest, they have clinical characteristics of deep, isolated or multiple ulcers, with purplish background, elevated edges, non-specific pain and they must be part in the GVHD differential diagnosis through biopsy and PCR, once they can have a positive result without CMV detection in blood yet.<sup>61,62</sup> Treatment should be carried out with the use of a potent antiviral, indicated by the transplanting physician.<sup>58</sup>

Oral infections can be a drastic problem before, during or after HSCT, therefore, accuracy in diagnosis and establishment of a rapid treatment will reduce possible systemic complications resulting from these infections.<sup>57–59</sup>

### Conclusion

The knowledge of the major oral cavity alterations in the patient submitted to HSCT is essential to early diagnosis and

reduction of morbidity and significant side effects during treatment.

It is key that the professional can identify the right moment to intervene according to the HSCT phase and bone marrow aplasia, and to conduct the surveillance of signs and symptoms of side effects in the oral cavity. The presence of resistant microorganisms and opportunistic infections should be early diagnosed and treated with the aim of preventing severe complications and more debilitating late treatments. In addition, preventive measures should be implemented for daily oral care, prevention and treatment of oral mucositis, pain management and patient's nutrition in order to reduce complications during HSCT, preserve quality of life, and contribute to patient's better prognosis.

### Conflicts of interest

None.

### Funding information

This research did not receive any specific grant from funding agencies in the public, commercial or not-for-profit sectors.

### Acknowledgements

We thank the Brazilian Bone Marrow Transplantation Society (SBTMO) for the support and trusting in our team. We also thank Nathalia Cristine André for her assistance.

### REFERENCES

1. Or R, et al. Allogeneic stem cell transplantation for the treatment of diseases associated with a deficiency in bone marrow products. *Springer Semin Immunopathol.* 2004;26:133–42.
2. Bezinelli LM, et al. Cost-effectiveness of the introduction of specialized oral care with laser therapy in hematopoietic stem cell transplantation. *Hematol Oncol.* 2014;32:31–9.
3. Sonis, B.S.T. et al. Oral mucositis and the clinical and economic outcomes of hematopoietic stem-cell transplantation. 19, 2201–2205 (2001).
4. Hong CHL, et al. Systematic review of basic oral care for the management of oral mucositis in cancer patients and clinical practice guidelines. *Support Care Cancer.* 2019;27:3949–67.
5. Elad S, et al. Basic oral care for hematology–oncology patients and hematopoietic stem cell transplantation recipients: a position paper from the joint task force of the Multinational Association of Supportive Care in Cancer/International Society of Oral Oncology (MASCC). *Support Care Cancer.* 2015;23:223–36.
6. Barkvold P, Rolla G, Svendsen AK. Interaction between chlorhexidine digluconate and sodium lauryl sulfate in vivo. *J Clin Periodontol.* 1989;16:593–5.
7. American Academy of Pediatric Dentistry. American Academy of Pediatric Dentistry. Fluoride therapy. The reference manual of pediatric dentistry. 288–91 Preprint at (2020).
8. Tenovuo J. Clinical applications of antimicrobial host proteins lactoperoxidase, lysozyme and lactoferrin in xerostomia: efficacy and safety. *Oral Dis.* 2002;8:23–9.

9. Shouval R, et al. Patterns of salivary microbiota injury and oral mucositis in recipients of allogeneic hematopoietic stem cell transplantation. *Blood Adv.* 2020;4:2912–7.
10. Vasconcelos RM, et al. Host-microbiome cross-talk in oral mucositis. *J Dent Res.* 2016;95:725–33.
11. Badia P, et al. Improving oral health and modulating the oral microbiome to reduce bloodstream infections from oral organisms in pediatric and young adult hematopoietic stem cell transplantation recipients: a randomized controlled trial. *Biol Blood Marrow Transplant.* 2020;000:1–7.
12. Oku S, et al. Disrupted tongue microbiota and detection of nonindigenous bacteria on the day of allogeneic hematopoietic stem cell transplantation. *PLoS Pathog.* 2020;16:1–18.
13. Lee A, et al. Association of HSV-1 and reduced oral bacteriota diversity with chemotherapy-induced oral mucositis in patients undergoing autologous hematopoietic stem cell transplantation. *J Clin Med.* 2020;9:1090.
14. Laheij AMGA, et al. Microbial changes in relation to oral mucositis in autologous hematopoietic stem cell transplantation recipients. *Sci Rep.* 2019;9:1–11.
15. Laheij AMGA, de Soet JJ. Can the oral microflora affect oral ulcerative mucositis? *Curr Opin Support Palliat Care.* 2014;8:180–7.
16. Khaw A, Logan R, Keefe D, Bartold M. Radiation-induced oral mucositis and periodontitis - proposal for an inter-relationship. *Oral Dis.* 2014;20:e7–e18.
17. Sonis ST. A biological approach to mucositis. *J Support Oncol.* 2004;2:21–32.
18. Bowen J, et al. The pathogenesis of mucositis: updated perspectives and emerging targets. *Support Care Cancer.* 2019;27:4023–33.
19. Bezinelli LM, et al. Quality of life related to oral mucositis of patients undergoing haematopoietic stem cell transplantation and receiving specialised oral care with low-level laser therapy: a prospective observational study. *Eur J Cancer Care.* 2016;25:668–74.
20. Laheij AMGA, et al. Oral bacteria and yeasts in relationship to oral ulcerations in hematopoietic stem cell transplant recipients. *Support Care Cancer.* 2012;20:3231–40.
21. Osakabe L, et al. Influence of oral anaerobic bacteria on hematopoietic stem cell transplantation patients: oral mucositis and general condition. *Transplant Proc.* 2017;49:2176–82.
22. de Mendonça RMH, et al. Prospective evaluation of HSV, *Candida* spp., and oral bacteria on the severity of oral mucositis in pediatric acute lymphoblastic leukemia. *Support Care Cancer.* 2012;20:1101–7.
23. Mougeot JLC, et al. Lasting Gammaproteobacteria profile changes characterized hematological cancer patients who developed oral mucositis following conditioning therapy. *J Oral Microbiol.* 2020;12.
24. Muro M, et al. Unusual oral mucosal microbiota after hematopoietic cell transplantation with glycopeptide antibiotics: potential association with pathophysiology of oral mucositis. *Folia Microbiol.* 2018;63:587–97.
25. Peterson DE, Boers-Doets CB, Bensadoun RJ, Herrstedt J. Management of oral and gastrointestinal mucosal injury: ESMO Clinical Practice Guidelines for diagnosis, treatment, and follow-up. *Ann Oncol.* 2015;26:v139–51.
26. World Health Organization. *Handbook for Reporting Results of Cancer Treatment*; 15–22.
27. *Common Terminology Criteria for Adverse Events (CTCAE) Version 5.* US Department of Health and Human Services, National Institutes of Health Published: November 27. National Cancer Institute; 2017 Preprint at.
28. Correa MEP, et al. Systematic review of oral cryotherapy for the management of oral mucositis in cancer patients and clinical practice guidelines. *Support Care Cancer.* 2020;28:2449–56.
29. Schubert MM, et al. A phase III randomized double-blind placebo-controlled clinical trial to determine the efficacy of low level laser therapy for the prevention of oral mucositis in patients undergoing hematopoietic cell transplantation. *Support Care Cancer.* 2007;15:1145–54.
30. Antunes HS, et al. Low-power laser in the prevention of induced oral mucositis in bone marrow transplantation patients: a randomized trial. *Blood.* 2007;109:2250–5.
31. Bezinelli LM, et al. Long-term safety of photobiomodulation therapy for oral mucositis in hematopoietic cell transplantation patients: a 15-year retrospective study. *Support Care Cancer.* 2021;29:6891–902.
32. de Paula Eduardo F, et al. Efficacy of cryotherapy associated with laser therapy for decreasing severity of melphalan-induced oral mucositis during hematological stem-cell transplantation: a prospective clinical study. *Hematol Oncol.* 2015;33:152–8.
33. Eduardo FDP, et al. Oral mucositis in pediatric patients undergoing hematopoietic stem cell transplantation: clinical outcomes in a context of specialized oral care using low-level laser therapy. *Pediatr Transplant.* 2015;19:316–25.
34. Pimenta Amaral TM, et al. Effect of salivary stimulation therapies on salivary flow and chemotherapy-induced mucositis: a preliminary study. *Oral Surg Oral Med Oral Pathol Oral Radiol.* 2012;113:628–37.
35. Bezinelli LM, et al. Therapeutic salivary monitoring of IV busulfan in patients undergoing hematopoietic stem cell transplantation: a pilot study. *Bone Marrow Transplant.* 2017;52:1384–9.
36. van Leeuwen SJM, Potting CMJ, Huysmans M-CDNJM, Blijlevens NMA. Salivary Changes before and after hematopoietic stem cell transplantation: a systematic review. *Biol Blood Marrow Transplant.* 2019;25:1055–61.
37. Boer CC, Correa MEP, Miranda ECM, de Souza CA. Taste disorders and oral evaluation in patients undergoing allogeneic hematopoietic SCT. *Bone Marrow Transplant.* 2010;45:705–11.
38. Boer CC, Correa MEP, Tenuta LMA, Souza CA, Vigorito AC. Post-allogeneic Hematopoietic Stem Cell Transplantation (HSCT) changes in inorganic salivary components. *Support Care Cancer.* 2015;23:2561–7.
39. Bachmeier E, et al. Mucositis and salivary antioxidants in patients undergoing bone marrow transplantation (BMT). *Med Oral Patol Oral Cir Bucal.* 2014; e444–50. <https://doi.org/10.4317/medoral.19062>.
40. de Paula Eduardo F, et al. Is salivary busulfan the cause of oral mucositis and the changes in salivary antioxidant enzymes after hematopoietic cell transplantation? *Ther Drug Monit.* 2020;42:565–71.
41. van der Werf A, Rovithi M, Langius JAE, de van der Schueren MAE, Verheul HMW. Insight in taste alterations during treatment with protein kinase inhibitors. *Eur J Cancer.* 2017;86:125–34.
42. Epstein JB, Smutzer G, Doty RL. Understanding the impact of taste changes in oncology care. *Support Care Cancer.* 2016;24:1917–31.
43. van Oort S, Kramer E, de Groot JW, Visser O. Taste alterations and cancer treatment. *Curr Opin Support Palliat Care.* 2018;12:162–7.
44. Hovan AJ, et al. A systematic review of dysgeusia induced by cancer therapies. *Support Care Cancer.* 2010;18:1081–7.
45. Visentin GP, Liu CY. Drug-induced thrombocytopenia. *Hematol Oncol Clin North Am.* 2007;21:685–96.
46. Aster RH, Bougie DW. Drug-induced immune thrombocytopenia. *N Engl J Med.* 2007;357:580–7.
47. Villaça P, Soares Jr L. *Medicina Bucal: A Prática Na Odontologia Hospitalar.* Santos: Distúrbios da coagulação; 2012. p. 221–4.
48. Saúde Ministério da, de S, Saúde Atenção à. D. de A. E. *Manual De Tratamento Das Coagulopatias Hereditárias.* MS; 2006.

49. Gupta A, Epstein JB, Cabay RJ. Bleeding disorders of importance in dental care and related patient management. *J Can Dent Assoc.* 2007;73:77–83.
50. Sindet-Pedersen S, Ramström G, Bernvil S, Blombäck M. Hemostatic effect of tranexamic acid mouthwash in anticoagulant-treated patients undergoing oral surgery. *N Engl J Med.* 1989;320:840–3.
51. Antunes HS, PSS S. Manejo do paciente onco-hematológico e em quimioterapia. *Diretrizes Para Atendimento Odontológico De Pacientes Sistemicamente Comprometidos.* Quintessence; 2019. p. 134–8.
52. Roldan CJ, Nouri K, Chai T, Huh B. Methylene blue for the treatment of intractable pain associated with oral mucositis. *Pain Pract.* 2017;17:1115–21.
53. Steffens JP, Marcantonio RAC. Classificação das Doenças e Condições Periodontais e Peri-implantares 2018: guia Prático e Pontos-Chave. *Rev Odontol UNESP.* 2018;47:189–97.
54. Ferry T, et al. Actinomycosis: etiology, clinical features, diagnosis, treatment, and management. *Infect Drug Resist.* 2014;183. <https://doi.org/10.2147/IDR.S39601>.
55. Eduardo FP, et al. Severe oral infection caused by *Pseudomonas aeruginosa* effectively treated with methylene blue-mediated photodynamic inactivation. *Photodiagnosis Photodyn Ther.* 2019;26:284–6.
56. Mikulska M, del Bono V, Viscoli C. Bacterial infections in hematopoietic stem cell transplantation recipients. *Curr Opin Hematol.* 2014;21:451–8.
57. Lombardi A, Ouanounou A. Fungal infections in dentistry: clinical presentations, diagnosis, and treatment alternatives. *Oral Surg Oral Med Oral Pathol Oral Radiol.* 2020;130:533–46.
58. Sahin U, Toprak SK, Atilla PA, Atilla E, Demirer T. An overview of infectious complications after allogeneic hematopoietic stem cell transplantation. *J Infect Chemother.* 2016;22:505–14.
59. Bays DJ, Thompson GR. Fungal infections of the stem cell transplant recipient and hematologic malignancy patients. *Infect Dis Clin North Am.* 2019;33:545–66.
60. Dadwal SS. Herpes virus infections other than cytomegalovirus in the recipients of hematopoietic stem cell transplantation. *Infect Dis Clin North Am.* 2019;33:467–84.
61. Eduardo Fernanda de Paula, Bezinelli LM, Corrêa L. *Odontologia hospitalar - Manuais de especialização - Albert Einstein.* In: *Odontologia hospitalar - Manuais de especialização - Albert Einstein;* 2019. p. 221–52.
62. Cho S-Y, Lee D-G, Kim H-J. Cytomegalovirus infections after hematopoietic stem cell transplantation: current status and future immunotherapy. *Int J Mol Sci.* 2019;20:2666.