

Images in Clinical Hematology

Persistent platelet satellitism despite normal platelet counts



Stijn Van Hees ^{a,b,c,*}, Frederic Winnock ^a, Paul Meuleman ^a

^aLaboratory for clinical biology, Algemeen Stedelijk Ziekenhuis Aalst, Aalst, Belgium

^bLaboratory for clinical biology, Ghent University Hospital, Ghent, Belgium

^cLaboratory of Experimental Medicine and Pediatrics, University of Antwerp, Antwerp, Belgium

ARTICLE INFO

Article history:

Received 31 May 2022

Accepted 12 August 2022

Available online 19 September 2022

Keywords:

Platelets

Satellitism

Hematologist

Images in clinical hematology

We here present a case of massive Platelet Satellitism (PS) around neutrophils in a 91-year old man with a normal thrombocyte count, detected through an incidental abnormal white blood cell scattergram flag on the Sysmex XN—L550 cell counter (Figure 1a-b).¹ Using the basic principles of flow-cytometry, a scattergram depicts the blood cell formula based on the sideward scatter (SSC; X-axis) and the side fluorescence light (SFL; Y-axis). The SSC represents the size of the cell, the SFL represents its metabolic activity. Compared to a normal white blood cell scattergram (Figure 1a) the scattergram of the current case showed an increased SSC and FSL in

the neutrophil cloud (Figure 1b). The SSC rise can be ascribed to sticking of the platelets to neutrophils, resulting in larger cells; the FSL rise can be ascribed to the chronic inflammatory state of the patient (he was under treatment for prostate carcinoma). Since platelets stick to neutrophils *in vitro*, but not *in vivo* in patients with PS, it is often suggested as a possible cause of pseudothrombocytopenia.¹

PS was not observed around other cell types (Figure 1c and 1d). Retrospective review of all blood smears performed for this patient revealed the presence of PS in a sample dating from five months earlier as well.

Hematologists should be aware that PS can persist for several months and may also occur in patients with normal platelet counts.

* Corresponding author at: Laboratory of Experimental Medicine and Pediatrics, University of Antwerp, Universiteitsplein 1, 2610 Antwerp, Belgium.

E-mail address: Stijn.vanhees@uantwerpen.be (S. Van Hees).

<https://doi.org/10.1016/j.htct.2022.08.003>

2531-1379/© 2022 Associação Brasileira de Hematologia, Hemoterapia e Terapia Celular. Published by Elsevier España, S.L.U. This is an open access article under the CC BY-NC-ND license (<http://creativecommons.org/licenses/by-nc-nd/4.0/>).

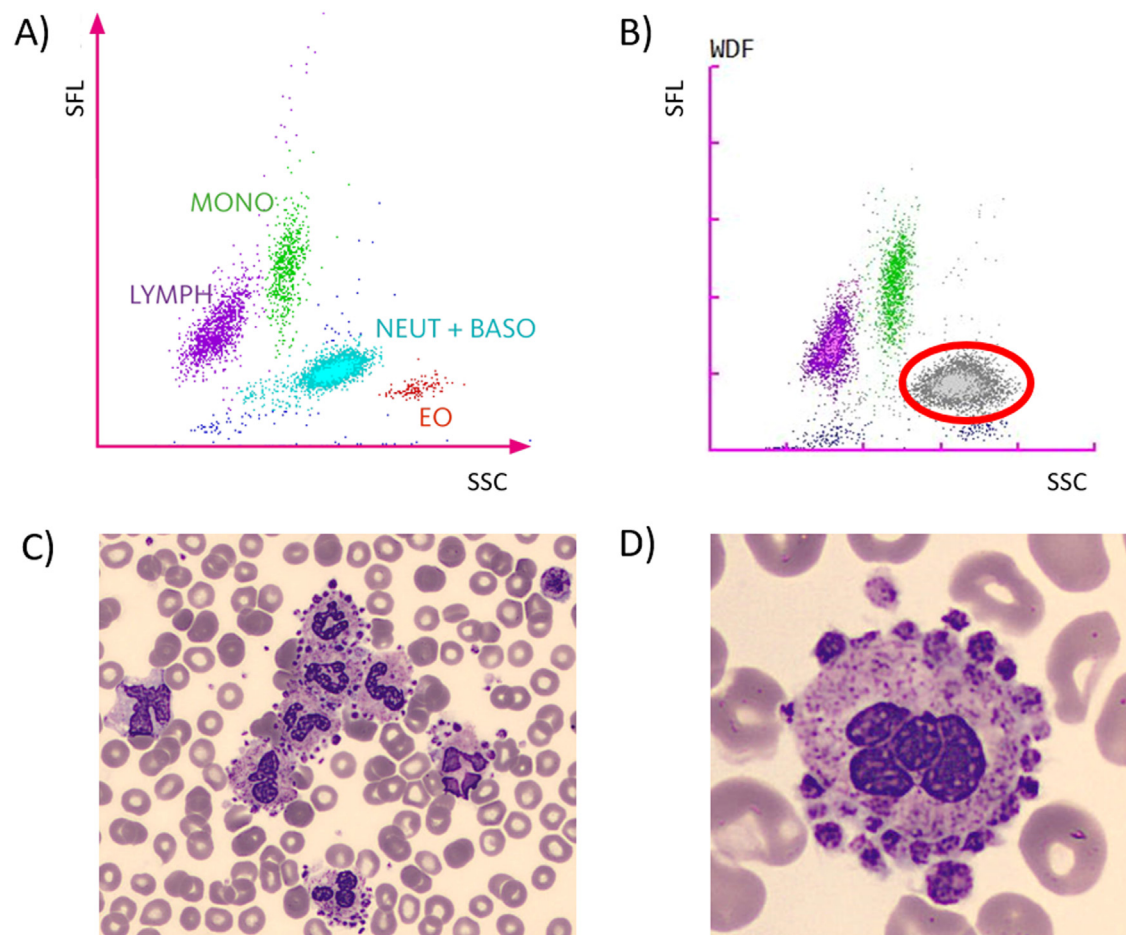


Figure 1 – Incidental finding of platelet satellitism upon blood smear review. Normal peripheral blood scattergram (A). Abnormal White Blood Cell scattergram flag on the Sysmex Cell counter; the grey cloud with red circle represents the abnormal white blood cells (b). Platelet satellitism with clustering of neutrophils (c). Close-up of a neutrophil surrounded by platelets (d). SFL: Side Fluorescence Light; SSC: Sideward Scatter; MONO: monocytes; LYMPH: lymphocytes; NEUT + BASO: Neutrophils + Basophils; EO: Eosinophils.

Conflicts of interest

The authors declare no conflicts of interest.

REFERENCES

1. Bobba RK, Donald C, Doll CD. Platelet satellitism as a cause of spurious thrombocytopenia. *Blood*. 2012;119:4100.