


Images in Clinical Hematology

Palatal superficial mucoceles associated with chronic graft-versus-host disease



Bilal Al Masri, Linda M. Perry, Eric T. Stoopler *

Penn Dental Medicine, Philadelphia, PA, USA

ARTICLE INFO

Article history:

Received 4 July 2021

Accepted 26 September 2021

Available online 29 November 2021

A 23-year-old woman with history of acute myelogenous leukemia post Busulfan and Cytosan conditioned 10/10 sibling donor peripheral blood stem cell transplant day +336 post-transplant and chronic graft-versus-host disease (cGVHD) with mild hepatic and cutaneous involvement complained of symptomatic palatal lesions consistent with superficial mucoceles (Figure 1). Following unsuccessful treatment with topical corticosteroids, symptomatic improvement was achieved with dissolved budesonide powder in water rinses three times daily.

Symptomatic superficial mucoceles are an uncommon manifestation of oral cGVHD and appear as translucent vesicles on the palate or labial mucosae.^{1,2} Topical or injectable corticosteroids are commonly used for management.^{1,2}

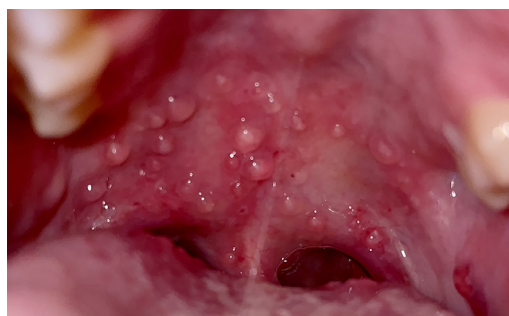

Figure 1 – Multiple translucent vesicles with inflammation on soft palate consistent with superficial mucoceles.

Conflicts of interest

The authors declare no conflicts of interest.

REFERENCES

1. Balasubramaniam R, Alawi F, DeRossi S. Superficial mucoceles in chronic graft-versus-host disease: a case report and review of the literature. *Gen Dent.* 2009;57(1):82–8.
2. Deutsch A, McLellan BN. Topical tacrolimus for refractory superficial mucoceles in a patient with chronic graft versus host disease. *JAAD Case Rep.* 2020;6(5):426–7.

* Corresponding author at: Penn Dental Medicine, 240 South 40th Street, Philadelphia, PA 19104, USA.

E-mail address: ets@upenn.edu (E.T. Stoopler).

<https://doi.org/10.1016/j.htct.2021.09.014>

2531-1379/© 2021 Associação Brasileira de Hematologia, Hemoterapia e Terapia Celular. Published by Elsevier España, S.L.U. This is an open access article under the CC BY-NC-ND license (<http://creativecommons.org/licenses/by-nc-nd/4.0/>).