

Case Report

Small bowel intussusception from an underlying MALT Lymphoma: A double rarity case report



Mariana Dias Coelho *, Cristiana Sequeira , Ricardo Freire,
Ana Paula Oliveira

Gastroenterology Department, Hospital de São Bernardo, Centro Hospitalar de Setúbal, Rua Camilo Castelo Branco 175, Setúbal 2910-549, Portugal

ARTICLE INFO

Article history:

Received 15 May 2022

Accepted 31 August 2022

Available online 19 November 2022

Introduction

Intussusception relates to the invagination of a segment of bowel into the lumen of a distally adjacent segment. It is rarely seen in adults, representing only 5% of all cases of intussusception and only 1-5% of all causes of intestinal obstruction.¹ Of all adult intussusceptions, up to 90 % involve a pathologic lead point, 65-70 % of which are malignancies.^{1,2} Presenting symptoms in adults are often non-specific and long-standing, making it difficult to diagnose. We report a case of a small bowel intussusception induced by a MALT lymphoma.

Case report

A 78-year-old man with a history of hypertension, type 2 diabetes mellitus and previous stroke with no subsequent deficits, medicated with insulin, amlodipine and clopidogrel, was referred to Gastroenterology consultation due to a 3-month

history of intermittent abdominal pain relieved by the passage of loose stools, with no blood, mucus or pus, as well as sporadic vomiting and loss of 15% of his body weight. On physical examination he presented good general condition, the abdomen was not distended, had normal bowel sounds, was non-tender and no masses or organomegalies were noted.

Laboratory tests showed complete and differential blood count, blood chemistry and urinalysis within the normal range. Esophagogastroduodenoscopy and colonoscopy with terminal ileoscopy were performed, both without relevant findings. Abdominal and pelvic computerized tomography (CT) showed slight bowel distension, with no identified obstacles.

On follow-up consultation, his clinical condition deteriorated, namely the weight loss and the abdominal pain, which was more frequent, intense and accompanied by abdominal distension and vomiting. On physical examination he maintained good general condition, stable vital signs and his abdomen was now slightly distended, with visible peristaltic bowel movements, intense gurgling and diffusely tender. The hernial orifices were continent and digital rectal examination was normal.

* Corresponding author.

E-mail address: dcoelho.mariana@gmail.com (M.D. Coelho).

<https://doi.org/10.1016/j.htct.2022.08.010>

2531-1379/© 2022 Associação Brasileira de Hematologia, Hemoterapia e Terapia Celular. Published by Elsevier España, S.L.U. This is an open access article under the CC BY-NC-ND license (<http://creativecommons.org/licenses/by-nc-nd/4.0/>).

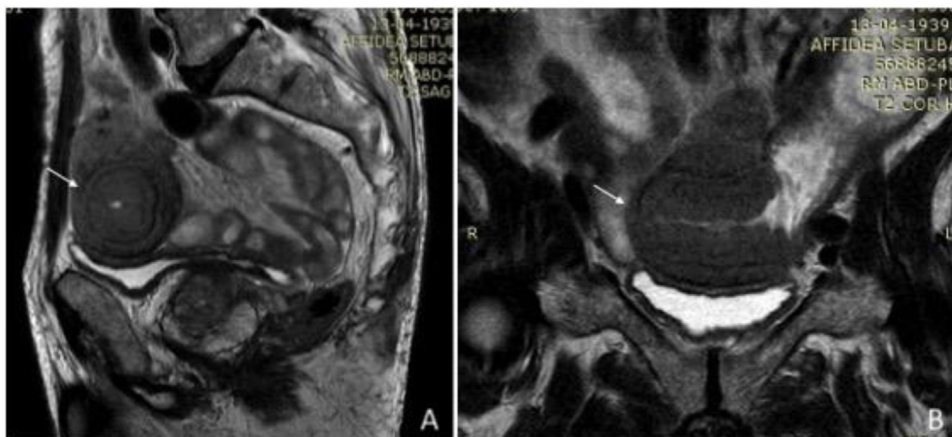


Figure 1 – Enteroenteric intussusception with an intraluminal lesion (arrow) in abdominal MRI sagittal (A) and coronal (B) views.

A magnetic resonance imaging (MRI) scan was made, showing an enteroenteric intussusception, probably ileoileal, with an intraluminal lesion in the same location, and proximal small bowel dilation (shown in Figure 1A and 1B).

An exploratory laparotomy was undertaken, identifying a small bowel neoplasm with mesenteric adenomegalies. Segmental resection with lymphadenectomy was performed. Pathological analysis showed a small bowel segment with lymphocytic infiltrate of the whole intestinal wall, featuring small lymphocytes diffusely disposed, lymphoepithelial lesions and an immunohistochemistry panel positive for CD20 and Bcl2, negative for CD3, CD5, CD10, Bcl6, CD23 and cyclin D1, with low Ki-67 (30%), compatible with low grade

MALT lymphoma, affecting some of the resected lymph nodes (shown in Figure 2 A to F).

He was referred to the Hematology department, having completed 6 cycles of R-CHOP (rituximab, cyclophosphamide, vincristine and prednisone), with clinical remission.

Discussion

Intussusception in adults is rare, accounting for only 5% of all intussusception cases. In contrast to pediatric populations, where 95% are idiopathic, the vast majority of adult patients have an underlying etiology.³ According to a recent meta-

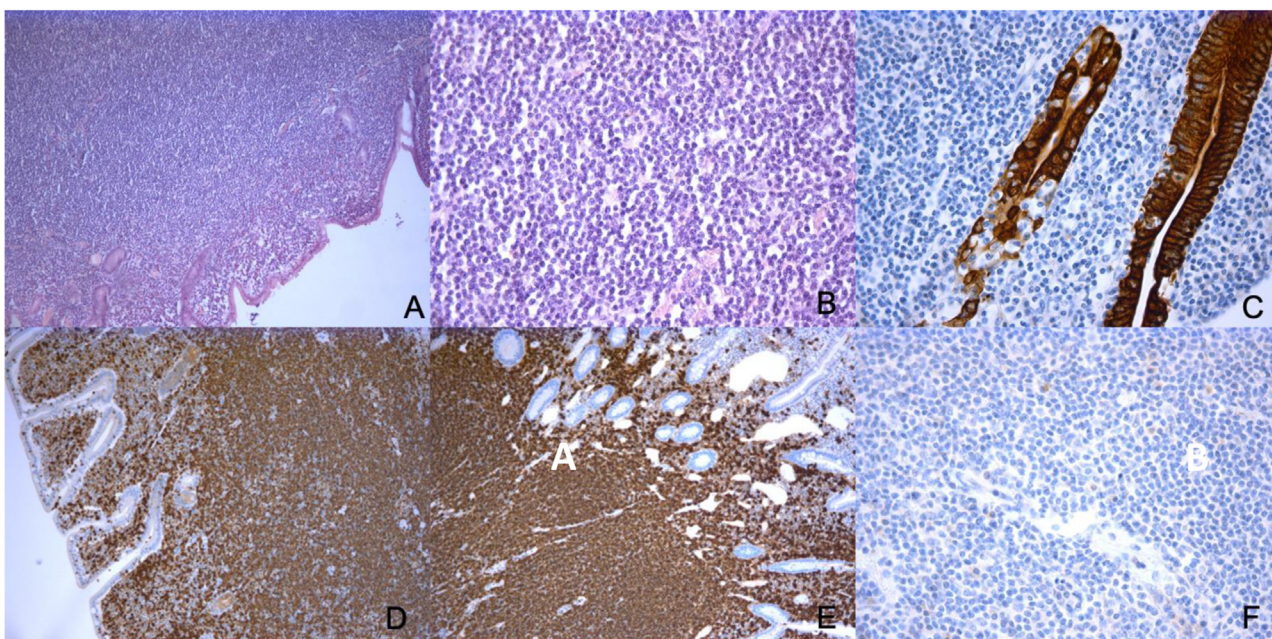


Figure 2 – A - Hematoxylin and eosin (HE) staining featuring small bowel with a dense and diffuse lymphocytic infiltrate; B – HE detail of the infiltrate with small lymphocytic cells; C – AE1/AE3 featuring lymphoepithelial lesion; D – Bcl2 positive; E – CD20 positive; F – CD10 negative.

analysis of intussusception in adults, only 15.1% are idiopathic, 32.9% are related to malignant tumors and 37.4% to benign tumors.¹ Owing to its nonspecific and usually long-standing presentation, diagnosis is often challenging and delayed. Various imaging modalities have been described as valuable diagnostic tools, abdominal CT being one of the methods of choice, given not only its availability, but also a sensitivity of 71,4-87,5% and a specificity of 100%.³ In our case report, CT did not identify any signs of intussusception, which might be attributable to its dynamic behavior. In view of the high incidence of underlying abnormalities, surgery is often required and sometimes is the ultimate diagnostic and therapeutic tool.

Unlike gastric MALT lymphomas, which are relatively frequent, representing 60-75% of all primary gastric lymphomas, have a strong association with *Helicobacter pylori* and a more favorable prognosis once its eradication is attained, non-gastric MALT lymphomas are much less frequent and the relation with *H. pylori* infection, as occurs in the stomach, is still controversial.⁴⁻⁶ Other pathogens, such as *Campylobacter jejuni* and *Chlamydia psittaci*, have been postulated, but the supporting evidence is scarce, and testing for these organisms is still not recommended for disease workup or management.^{4,5}

Clinical presentation of gastrointestinal lymphoma is usually nonspecific. Abdominal pain is present in approximately 45-65% of cases, due to mass effect or bowel obstruction; other symptoms, like fever, diarrhea, hematochezia and weight loss are also frequent.⁶ Presentation as intestinal intussusception has been rarely described in adults, with only three published reports, two as ileocecal intussusception and only one as an ileoileal intussusception.⁷⁻⁹ Since small bowel lymphoma is a rare condition (10-30% of all small bowel tumors³), definitive treatment has not yet been established, but a combination of surgery and chemotherapy may be an option.⁶

In conclusion, small bowel MALT lymphoma presenting as intussusception is a combination of two rare conditions, with only another published case in the literature with an ileoileal presentation. Given the dynamic behavior of intussusception, abdominal CT may be misleading and a high index of suspicion may be required to allow an early diagnosis.

Statement of ethics

This study did not require informed consent or review approval by the appropriate ethics committee.

Authors' contributions

All authors contributed to the study conception and design. Mariana Coelho performed the material preparation, data collection, and first draft of the manuscript. All authors read and approved the final manuscript.

Funding sources

The authors declare no funding on this work.

Conflicts of interest

The authors declare no conflict of interest.

REFERENCES

- Hong KD, Kim J, Ji W, Wexner SD. Adult intussusception: a systematic review and meta-analysis. *Tech Coloproctol.* 2019;23(4):315–24.
- Bellio G, Cipolat Mis T, Kaso G, Dattola R, Casagrande B, Bortol M. Small bowel intussusception from renal cell carcinoma metastasis: a case report and review of the literature. *J Med Case Rep.* 2016;10(1):222.. Published 2016 Aug 11.
- Potts J, Al Samaraee A, El-Hakeem A. Small bowel intussusception in adults. *Ann R Coll Surg Engl.* 2014;96(1):11–4.
- Cai ZS, Chen MJ, Chu CH, Wang HY, Chang CW. Small bowel mucosa-associated lymphoid tissue lymphoma: a case report and literature review. *Adv Dig Med.* 2019;6(2):73–6.
- Abbas H, Niazi M, Makker J. Mucosa-Associated lymphoid tissue (MALT) lymphoma of the colon: a case report and a literature review. *Am J Case Rep.* 2017;18:491–7. Published 2017 May 4.
- Shirwaikar Thomas A, Schwartz M, Quigley E. Gastrointestinal lymphoma: the new mimic. *BMJ Open Gastroenterol.* 2019;6(1):e000320. Published 2019 Sep 13.
- Murino A, Despott E, Hansmann A, Heath P, Fraser C. A rare case of small bowel intussusception. *Endoscopy.* 2012;44. (S 02).
- Adams KM, Roe NM. A rare case of MALT lymphoma underlying ileocecal intussusception. *J Am Osteopath Assoc.* 2016;116(8):e37–40.
- Jayabackthan L, Murgi SB, Graham S, Kini RG. A rare case of primary lymphoma of the caecum presenting as intussusception. *J Lab Phys.* 2013;5(2):118–20.