



Images in Clinical Hematology

Hungry megakaryocytes on the hunt? An unusual case of extensive megakaryocyte emperipolesis



S. Vijaya Devi ^a, Richa Gupta ^{b,*}

^a Maulana Azad Medical College, New Delhi, India

^b University College of Medical Sciences, Delhi, India

ARTICLE INFO

Article history:

Received 27 August 2020

Accepted 3 December 2020

Available online 21 December 2020

Keywords:

Megakaryocyte

Emperipolesis

Immune thrombocytopenic purpura

An 11-year-old female presented with fever and thrombocytopenia (Platelet count - $25 \times 10^9/L$). Bone marrow smears revealed hyperplasia and emperipolesis in all megakaryocytes containing intact lymphocytes and neutrophils. (Figs. 1 and 2) No etiology was found. The patient was given intravenous immunoglobulin and steroids on presumption of Immune thrombocytopenia, to which she responded well (Platelet count after 4 months - $108 \times 10^9/L$).

Some emperipolesis may be seen in various disorders, including Immune thrombocytopenia.^{1,2} Aslan D postulated that, in ITP, emperipolesis contributes to megakaryocyte dysfunction and poor response to therapy.³ This is an unusual case where all megakaryocytes show extreme degree of emperipolesis, yet the patient responded well.

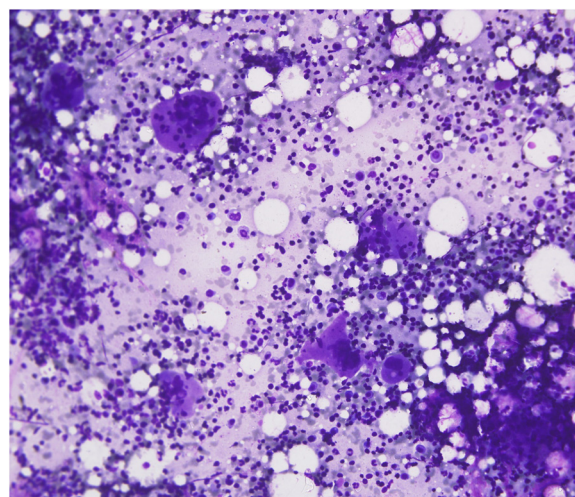


Figure 1 – Bone marrow aspirate showing megakaryocytic hyperplasia with extensive emperipolesis; Geimsa stain, 400x.

* Corresponding author at: Room 427, Department of Pathology, University college of Medical Sciences, Dilshad Garden, Delhi 110095, India.

E-mail address: richagupta0209@gmail.com (R. Gupta).

<https://doi.org/10.1016/j.htct.2020.12.001>

2531-1379/© 2020 Associação Brasileira de Hematologia, Hemoterapia e Terapia Celular. Published by Elsevier Editora Ltda. This is an open access article under the CC BY-NC-ND license (<http://creativecommons.org/licenses/by-nc-nd/4.0/>).

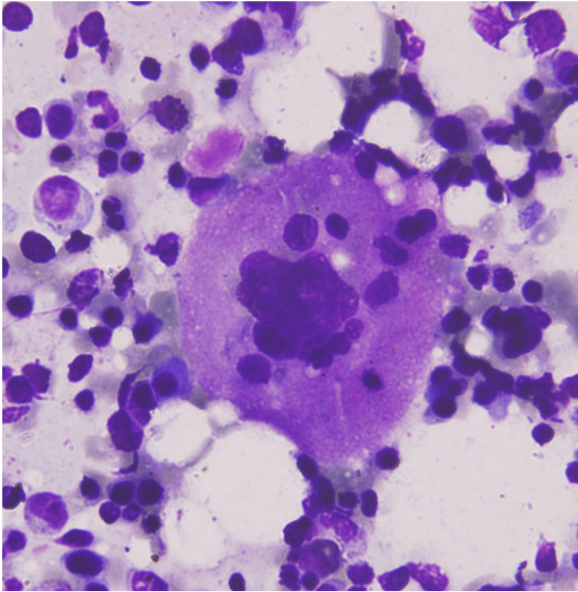


Figure 2 – Bone marrow aspirate showing a megakaryocyte with engulfed neutrophils and lymphocytes; Geimsa stain, 1000 \times .

Conflicts of interest

The author declares no conflicts of interest.

REFERENCES

1. Cashell AW, Buss DH. Frequency and significance of megakaryocytic emperipolesis in myeloproliferative and reactive states. *Ann Hematol.* 1992;64:273–6.
2. Rai S, Sharma M, Muhary M, Naik R, Sinha R. Increased emperipolesis in megakaryocytes in a case of idiopathic thrombocytopenic purpura. *Indian J Pathol Microbiol.* 2015;52:4523.
3. Aslan D. Emperipolesis in immune thrombocytopenic purpura. *Indian J Pathol Microbiol.* 2009;52:289–90.